



Available online at www.sciencedirect.com

ScienceDirect

journal homepage: www.elsevier.com/locate/gie



LITERATURE REVIEW/REVISIONE DELLA LETTERATURA

Modern technologies in Endodontics



Moderne tecnologie in Endodonzia

Alfredo Iandolo^{a,*}, Giuseppe Iandolo^b, Mariano Malvano^c,
Giuseppe Pantaleo^a, Michele Simeone^a

^a Department of Neurosciences, Reproductive and Odontostomatological Sciences, University of Naples Federico II, Naples, Italy

^b Medical Director, ASL Avellino 2, Avellino, Italy

^c Private Practice in Naples, Italy

Received 23 September 2015; accepted 11 December 2015

Available online 15 January 2016

KEYWORDS

Irrigation solutions;
Activation;
Microscope;
Ultrasonic tips.

Abstract

Aim: In Endodontics, a complete chemo-mechanical cleansing of the root canal system is essential to achieving success, which is gained through adequate tridimensional obturation of the endodontic space.

Materials and methods: Today, thanks to modern technologies as Operative Microscope, ultrasonic tips, M-Wire Files, devices to activate irrigation and tridimensional obturation performed with thermo plasticized gutta-percha, satisfactory results can be obtained.

Results: This study shows all the technologies that are available today to increase the chemo-mechanical cleansing and obturation of the entire and complicated endodontic system.

Conclusions: The positive results highlighted by these clinical cases demonstrate how the use of modern technologies are essential to avoid iatrogenic injury, and guarantee, on the other hand, safe and reproducible results.

© 2015 Società Italiana di Endodonzia. Production and hosting by Elsevier B.V. All rights reserved.

* Corresponding author at: DDS, University of Naples Federico II, via S. Pansini 5, 80131 Naples, Italy.

E-mail: iandoloalfredo@libero.it (A. Iandolo).

Peer review under responsibility of Società Italiana di Endodonzia.



Production and hosting by Elsevier

PAROLE CHIAVE

Soluzioni irriganti;
Attivazione;
Microscopio;
Punte ultrasoniche.

Riassunto

Obiettivo: In Endodonzia una completa detersione chemio-meccanica del complesso sistema dei canali radicolari è fondamentale per il raggiungimento del successo, il quale viene mantenuto attraverso un'adeguata otturazione tridimensionale dello spazio endodontico.

Materiali e metodi: Oggi, grazie alle moderne tecnologie, Microscopio Operatorio, Punte ultrasoniche, Files in lega M-Wire, dispositivi per l'attivazione degli irriganti e all'otturazione tridimensionale eseguita con guttaperca termoplastificata si possono ottenere risultati ben più che soddisfacenti.

Risultati: L'articolo che segue mette in risalto tutte le tecnologie che oggi abbiamo a disposizione per aumentare il grado di detersione chemio-meccanica e otturazione tridimensionale del complicato e intero sistema endodontico.

Conclusioni: Gli esiti positivi, evidenziati da questi casi clinici, dimostrano come l'utilizzo delle moderne tecnologie siano indispensabili nell'evitare danni iatrogeni e garantire, invece, risultati sicuri e riproducibili.

© 2015 Società Italiana di Endodonzia. Production and hosting by Elsevier B.V. Tutti i diritti riservati.

Introduction

The long-term success of endodontic treatment is closely linked to adequate cleansing, shaping and then to a complete tridimensional obturation of the complex root canal system.¹⁻³ Probably, a significant percentage of failures is caused by the presence of residual pulp tissue and to an insufficient cleansing of the roots canals.⁴ The endodontic system is composed by spaces easily accessible to hand and rotary files (main canals) and, as demonstrated by many clinical and histological studies,^{5,6} by not easily accessible or inaccessible spaces (isthmus, delta, loop, lateral and accessory canals and dentinal tubules) (Figs. 1 and 2).⁷

Root canal shaping is not able to reach all areas of the root canal system, regardless of the technique used; so not all sections of canal are treated.⁸ For this reason it is necessary the endodontic biochemistry cleansing (accessible and not accessible spaces); once cleaned, it can be filled and obtured with gutta percha and cement during obturation.⁹

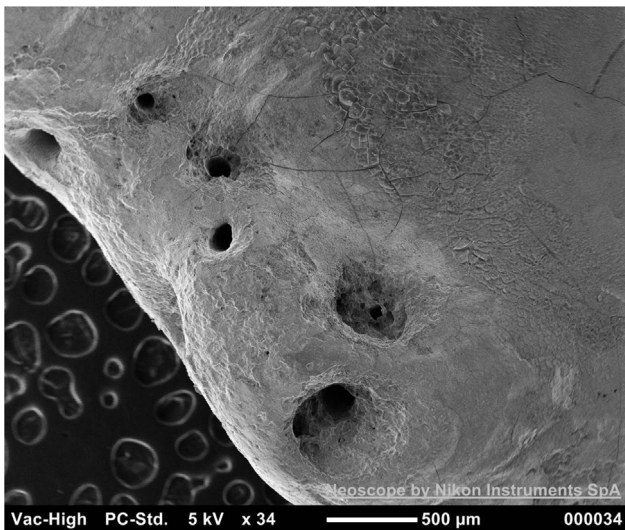


Figure 1 Root apex of the mesial root of a lower first molar at SEM: a lot of exits are shown.

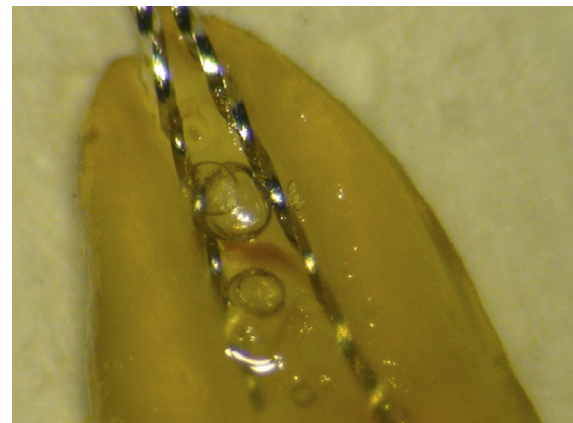


Figure 2 Diaphanization of a lower central incisor: an isthmus between the two root canals is shown.

The outcomes of current endodontic treatments are based on old working methods (operators without experience, treatments performed without the aid of the operating microscope, chemo-mechanical preparation performed with normal Ni-Ti files, use of irrigants without activation)^{10,11};

In the endodontic treatment we can distinguish different phases:

- The pulp chamber opening, the most difficult phase in accordance with literature, because an error during this phase could compromise the treatment. The opening of the pulp chamber should be performed under constant magnification and lighting^{4,12-16};
- The shaping phase with the new modified NiTi instruments¹⁷⁻¹⁹;
- The cleansing phase, where irrigants are activated and enhanced²⁰⁻²²;
- The obturation phase, where in addition to modern systems using thermoplastic gutta percha, new root canals filling materials are proposed.²³⁻²⁷

Of course, the treatment has to be concluded with an appropriate post-endodontic restoration.

After a careful analysis of the case that has to be treated, by X-ray and clinical examinations, it is possible to proceed with the endodontic treatment.

Materials and methods

Modern technologies

The pulp chamber opening

First step that has to be performed is the isolation of the operative field with a dental dam, than under constant magnification and lighting we have to proceed with the opening of the pulp chamber with rotary instruments and ultrasonic tips.

The main aid of the operating microscope (Fig. 3) is the increase of the PDR, or power of resolution, namely the ability to see distant two points that are very close together. The human eye, in fact, it's not able to distinguish between two points separated by a minimum distance of 0.1 mm (PDR: 0.1 mm),^{28,29} it will sum them as a single image. By using the operating microscope, the power of resolution increases from 0.1 mm to 0.005 mm equal to 5 micron, thus making the human eye able to observe more details.

The ultrasonic instruments which are now available in dentistry include various types of tips that have different kind of shapes, length and construction materials (Fig. 4). Furthermore, with the introduction of new advanced sources of ultrasound, it was possible to optimize the use of each type of tip with the option to control the frequency and the amplitude of vibration. The ultrasonic tips guarantee a great cutting accuracy thanks to their reduced dimensions that allow greater view of the operating field than the rotary instruments, greater view that increases the use of magnification systems as the operating microscope.^{4,30}

So, only after root canal entrances identification (Fig. 5), it is possible to proceed with the phases of shaping, cleansing and tridimensional obturation.¹²⁻¹⁴



Figure 3 Operating microscope.



Figure 4 Endodontic ultrasonic tips.

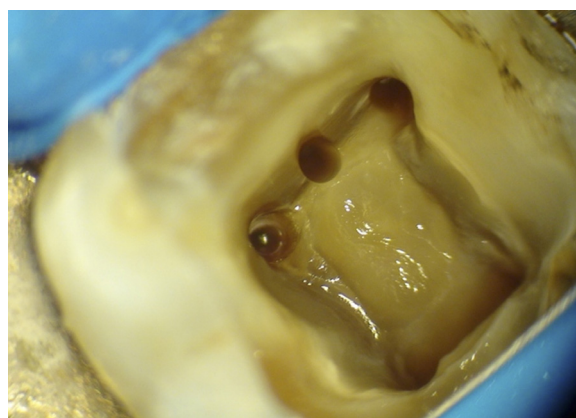


Figure 5 Opening the pulp chamber in a lower first molar performed under constant magnification and illumination, using ultrasonic tips.

The shaping phase with the new modified NiTi instruments

The use of Ni-Ti represented a turning point in the history of Endodontics, in fact it allowed the construction and production of new manual and rotary endodontic instruments with characteristics that were superior to stainless steel instruments, obtaining more effective and reproducible therapies.^{31,32} The Ni-Ti alloys used in dentistry have an equal atomic composition of Ni and Ti, corresponding to 55% by mass of Ni and 45% by mass of Ti.³³

The main properties of Ni-Ti are the shape memory and superelasticity (or pseudoelasticity), although in Endodontics the first characteristic is not used.

The superelasticity or pseudoelasticity on the other hand, is particularly useful because it lends to the alloy the ability to bend and adapt to the shape of the canal, allowing to shape the canal with a movement of rotation, keeping a centered position even in the presence of accentuated curvatures, in that way the restoring force and its negative




Figure 6 ProTaper Next.

effects (perforations, obstructions and stripping) on the original trajectory of the canal are minimized, typical of steel instruments.^{34,35} The superelastic or pseudoelastic behavior depends on a change of crystalline organization. Despite of the use of the Ni-Ti involves a number of advantages, the use of these rotary instruments in Endodontics, could increase the risk of fracture compared to the use of the steel files.^{33,35,36}

The fracture of a rotating instrument depends most often by torsional and bending stress.^{33,37–39} There are many Ni-Ti instruments available in dentistry today, in this study we wanted to test a new set of NiTi rotary instruments, the ProTaper Next, as their use in endodontic treatment is very effective (Fig. 6).

ProTaper Next characteristics

The ProTaper Next are fifth generation instruments, they are built according to modern M-Wire technology,^{17–19} with a rectangular section and a center of asymmetrical rotation. This instrument, rotating in the canal, has in the space a cutting surface greater than that which one with same caliber, with square section and symmetrical center of rotation.

The rectangular section and the asymmetrical center of rotation reduce the contact of the blades with the walls, ensuring more space for the debris and flexibility increasing.

Moreover, the new M-Wire alloy increases resistance to cyclic fatigue of the instruments, allowing to work with greater safety even in canals with severe curvatures (Figs. 7–10).

As demonstrated in literature, Files are not able to contact all the endodontic spaces, for this reason, it is necessary an active cleansing, in order to cleanse as much as possible the complex endodontic system.^{3,4,9}

Active cleansing phase (3D cleansing)

The most commonly irrigant used for the cleansing phase is sodium hypochlorite.

Several authors have described various techniques to improve the effectiveness of sodium hypochlorite as irrigant, including the use of greater amounts of irrigant and its preheating.^{40,41}

The heated sodium hypochlorite has a greater ability to dissolve the pulp tissue and clean the canal.^{41,42} The speed at

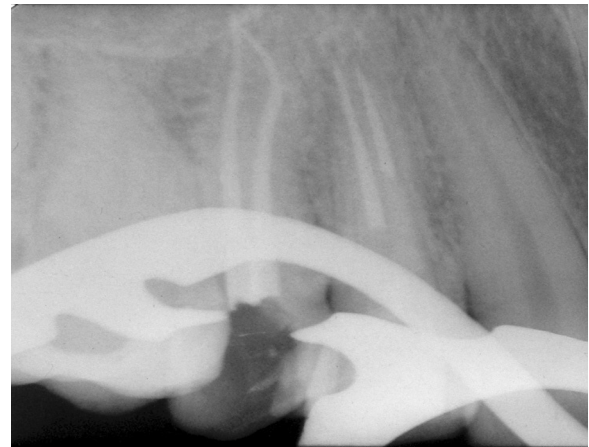


Figure 7 Post-operative radiograph of 1.5. Shaping obtained with ProTaper Next.

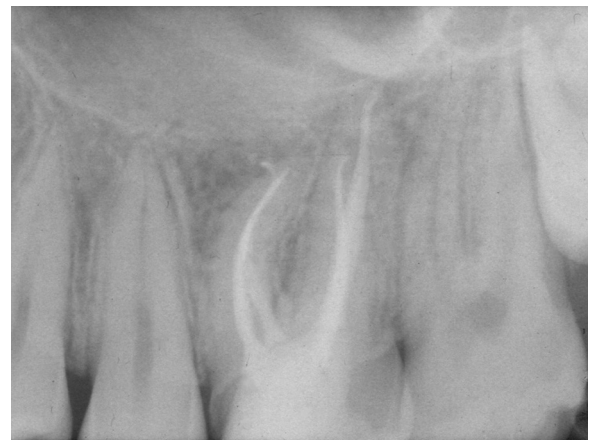

Figure 8 Post-operative radiograph of 2.6. Shaping was obtained with ProTaper Next.

which a chemical reaction occurs increases with the increase of temperature, pressure, excitement and concentration.

Since the pressure inside the root canal system cannot be increased, it is possible to accelerate the cleansing by increasing the concentration, heating and excite it.

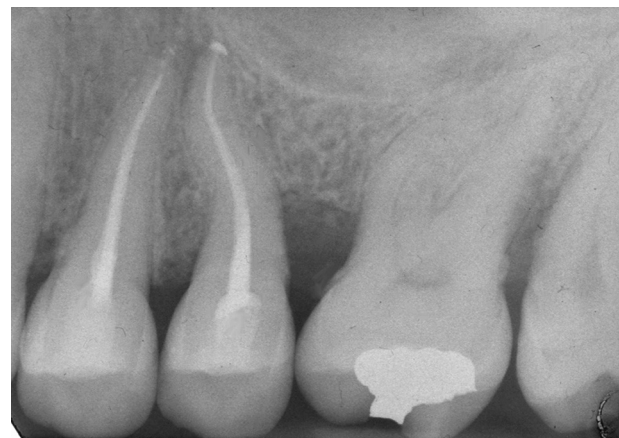

Figure 9 Post-operative radiograph of 2.4 and 2.5. Shaping was obtained with ProTaper Next.

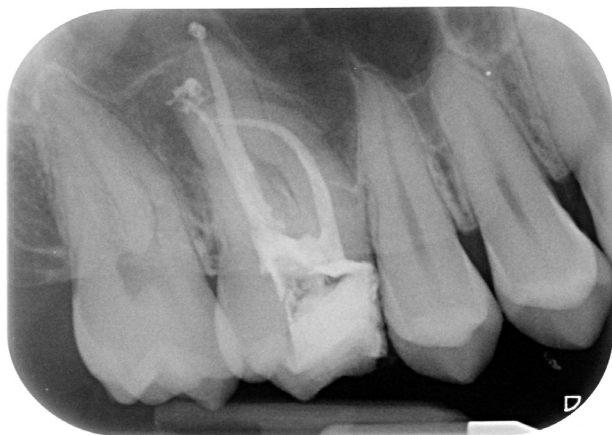

Figure 10 Post-operative radiograph of 1.6. Shaping was obtained with Files in M-Wire alloy.

The excitement is easily achieved by sonic or ultrasonic sources⁴³ (Figs. 11 and 12). The solutions concentration available today on the market, to prevent possible irritant reactions, does not exceed 6%. Finally we can consider the heating.

Normally the solution is pre-heated outside of the tooth to a temperature of 50°.⁴⁴

The preheated solutions have limited utility, since they stabilize rapidly at a temperature included between body and ambient temperature.

New technique for the sodium hypochlorite heating: operating protocol

Sodium hypochlorite has a boiling temperature included between 96° and 120°.

We use a heat carrier (System-B or similar). The temperature of the heat carrier is set to 150°.

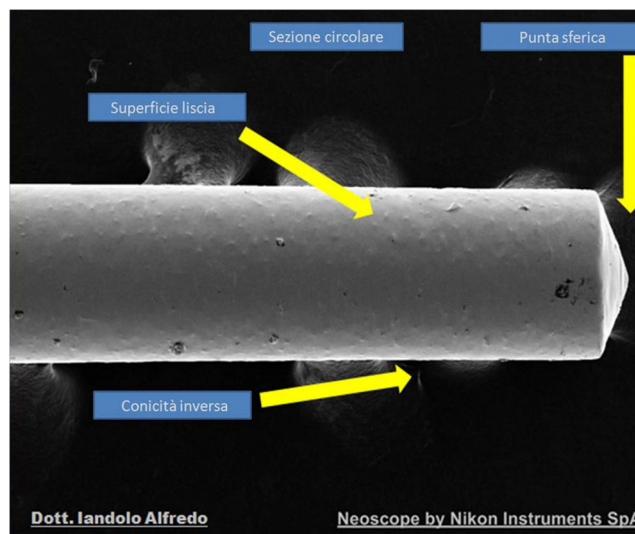


Figure 11 IG-File (landolo Gauging File), Ni-Ti instrument designed exclusively for the measurement of apical diameter and for the sonic activation of the irrigants.

The heat carrier used will be the 30/04, so that the income from 3 mm working length can be easily achieved without excessive preparations.

The root canal is filled with sodium hypochlorite through the endodontic needle. The heat carrier is used cold approximately 3 mm from the working length, and subsequently activated.

Each cycle of activation of the heat-carrier lasts 5 s with a further 5 s intervals.

During activation, the heat carrier makes brief excursions up and down of few millimeters to shake the irrigant.

The most important aspect is not to take contact with the canal walls during the activation of the heat carrier.

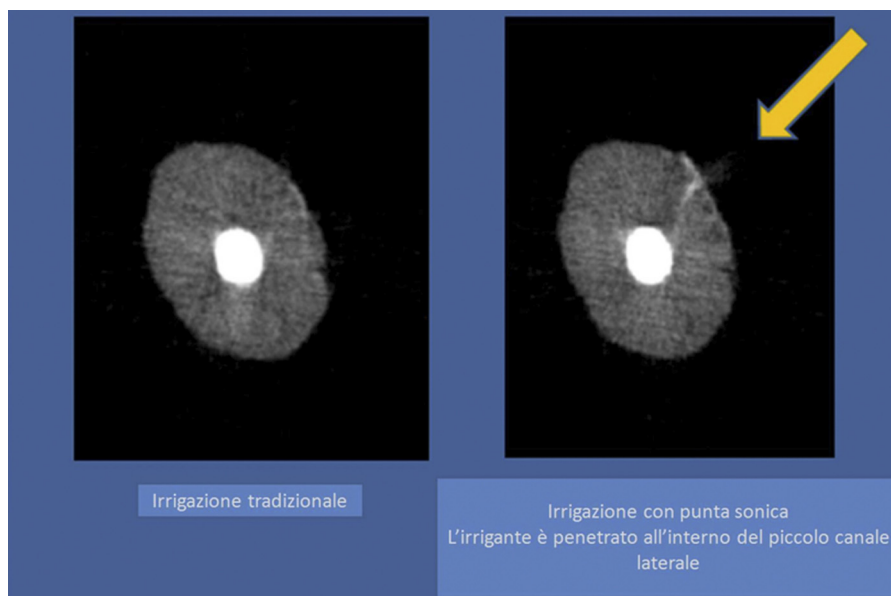


Figure 12 MicroCT photo shows how, thanks to the sonic activation, we had a good penetration of the irrigant in a small lateral canal in the middle third of a root canal.

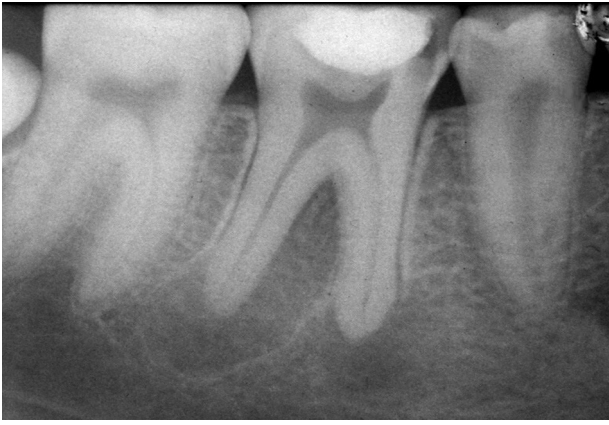

Figure 13 Preoperative radiograph of 4.6, there is a big periapical lesion of the distal and mesial root.

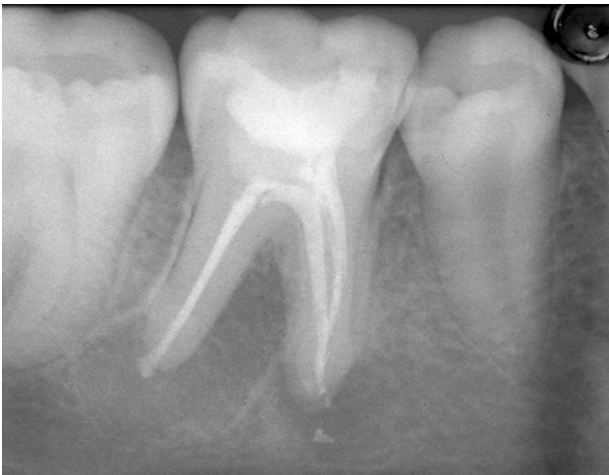

Figure 14 Post-operative radiograph of 4.6. Obturation with thermoplasticized guttapercha after activation and heating of irrigants.

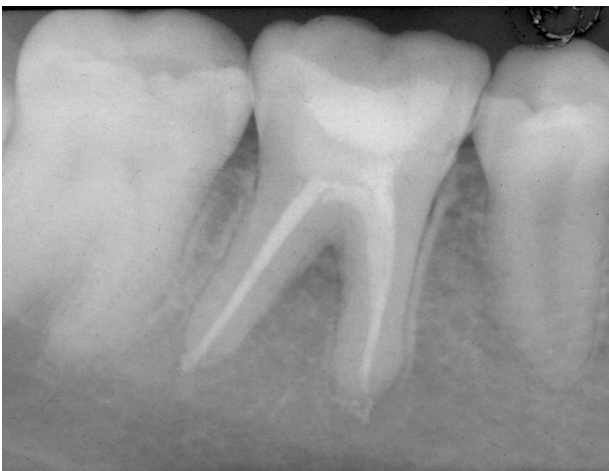

Figure 15 X-ray follow up at 6 months of 4.6. We can notice the successful healing with the disappearance of periapical lesions.

After each cycle the irrigant is replaced with fresh solution so as to have increasingly greater amount of hypochlorite with active chlorine.

The activation cycle is repeated 5 times. During each activation of the irrigant, the vapors are sucked by a cannula.

A parameter used was the heating of the outer surface of the root, at the third coronal level, middle, apical and foramen level. During activation of the irrigant with an infrared thermometer (resolution: 0.1°) the temperatures on the outer surface of the root were measured. Using the values exposed in the operating protocol, there were not detected external temperature higher than 42.5° . So temperatures close to 47° were avoided, dangerous for the cells of the periodontal ligament, avoiding medico-legal consequences.^{45–47} After chemo-mechanical cleansing (Figs. 13–15), fundamental for the achievement of clinical success, we proceed to tridimensional obturation with thermo-plasticized guttapercha.

Root canal obturation phase

As obturation technique, if continuous wave of condensation is used, it is important to underline that the heat carrier, must be brought to about 3 mm from the working length, to obtain adequate thermoplasticization of apical guttapercha.⁴⁸

For the obturation techniques spread by carrier available on the market today we find Guttacore Pink obturators, with a gutta percha crosslinked core.²⁴

In addition, recent studies, are proposing new materials for the filling of root canals, with remarkable results.⁴⁹

Conclusions

The positive results highlighted by these clinical cases demonstrate how the use of modern technologies, operating microscope, ultrasonic tips, rotary files of new generation, systems enhancing cleansing and methods used to obtain a valid tridimensional seal, are essential to avoid iatrogenic damage and ensure, however, safe and reproducible results.

Of course, to confirm what we have described, further research and scientific studies are needed, however, the clinical cases performed with these technologies and techniques have proved very satisfactory results, especially in the treatment of endodontic teeth that have large osteolytic lesions and canals with accentuated curvatures.

Conflict of interest

The authors have no conflict of interest.

References

1. Paduano S, Uomo R, Amato M, Riccitiello F, Simeone M, Valletta R. Cyst-like periapical lesion healing in an orthodontic patient: a case report with five-year follow-up. *G It Endod* 2013;27(2): 95–104.
2. Silvani M, Brambilla E, Cerutti A, Amato M, Gagliani M. Root canal treatment quality in undergraduate program: a preliminar report on NiTi reciprocating files. *G It Endod* 2013;27:33–7.

3. Ametrano G, Riccitiello F, Amato M, Formisano A, Muto M, Grassi R, et al. μ CT analysis of mandibular molars before and after instrumentation by Reciproc files. *Recenti Progressi Medicina* 2013;104:420–4.
4. Iandolo A. Reperimento del canale mesiale mediano nei primi molari inferiori. *Il Dentista moderno* 2011;18:269.
5. Carratù P, Amato M, Riccitiello F, Rengo S. Evaluation of leakage of bacteria and endotoxins in teeth treated endodontically by two different techniques. *J Endod* 2002;28(4):272–5.
6. Spagnuolo G, Ametrano G, D'Antò V, Formisano A, Simeone M, Riccitiello F, et al. Microcomputed tomography analysis of mesio-buccal orifices and major apical foramen in first maxillary molars. *Open Dent J* 2012;6:118–25.
7. Riccitiello F, Di Caprio MP, D'Amora M, Pizza NL, Vallone G, D'Ambrosio C, et al. Repair of a root perforation by using MTA: a case report. *Recenti Progressi Medicina* 2013;104:453–8.
8. Spagnuolo G, Ametrano G, D'Antò V, Rengo C, Simeone M, Riccitiello F, et al. Effect of autoclaving on the surfaces of TiN-coated and conventional nickel-titanium rotary instruments. *Int Endod J* 2012;45(12):1148–55.
9. Santarcangelo F, Castellucci A. L'irrigazione canalare nell'Endodonzia moderna: casi semplici. Blog in odontoiatria: www.zerodonto.com, sezione Endodonzia.
10. Friedman S, Abitbol S, Lawrence HP. Treatment outcome in endodontics: the Toronto Study. Phase 1: initial treatment. *J Endod* 2003;29(December (12)):787–93.
11. Ng YL, Mann V, Gulabivala K. A prospective study of the factors affecting outcomes of nonsurgical root canal treatment: part 1: periapical health. *Int Endod J* 2011;44(July (7)):583–609.
12. Das S, Warhadpande MM, Redij SA, Jibhkate NG, Sabir H. Frequency of second mesiobuccal canal in permanent maxillary first molars using the operating microscope and selective dentin removal: a clinical study. *Contemp Clin Dent* 2015;6(January–March (1)):74–8.
13. de Toubes KM, Córtes MI, Valadares MA, Fonseca LC, Nunes E, Silveira FF. Comparative analysis of accessory mesial canal identification in mandibular first molars by using four different diagnostic methods. *J Endod* 2012;38(April (4)):436–41.
14. Rampado ME, Tjäderhane L, Friedman S, Hamstra SJ. The benefit of the operating microscope for access cavity preparation by undergraduate students. *J Endod* 2004;30(December (12)):863–7.
15. Wu D, Shi W, Wu J, Wu Y, Liu W, Zhu Q. The clinical treatment of complicated root canal therapy with the aid of a dental operating microscope. *Int Dent J* 2011;61(October (5)):261–6.
16. Lo Giudice G, Lo Giudice R, Matarese G, Isola G, Cicciù M, Terranova A, et al. Evaluation of magnification systems in restorative dentistry. An in-vitro study. *Dent Cadm* 2015;83(5):296–305.
17. Ferrara G, Taschieri S, Corbella S, Ceci C, Del Fabbro M, Machtou P. Comparative evaluation of the shaping ability of two different nickel-titanium rotary files in curved root canals of extracted human molar teeth. *J Investig Clin Dent* 2015;(September).
18. Berutti E, Alovise M, Pastorelli MA, Chiandussi G, Scotti N, Pasqualini D. Energy consumption of ProTaper Next X1 after glide path with PathFiles and ProGlider. *J Endod* 2014;40(December (12)):2015–8.
19. Capar ID, Arslan H, Akcay M, Ertas H. An in vitro comparison of apically extruded debris and instrumentation times with ProTaper Universal, ProTaper Next, Twisted File Adaptive, and HyFlex instruments. *J Endod* 2014;40(October (10)):1638–41.
20. Schmidt TF, Teixeira CS, Felipe MC, Felipe WT, Pashley DH, Bortoluzzi EA. Effect of ultrasonic activation of irrigants on smear layer removal. *J Endod* 2015;41(August (8)):1359–63.
21. Sahar-Helft S, Sarp AS, Stabholtz A, Gutkin V, Redenski I, Steinberg D. Comparison of positive-pressure, passive ultrasonic, and laser-activated irrigations on smear-layer removal from the root canal surface. *Photomed Laser Surg* 2015;33(March (3)):129–35.
22. Rodríguez-Figueroa C, McClanahan SB, Bowles WR. Spectrophotometric determination of irrigant extrusion using passive ultrasonic irrigation, EndoActivator, or syringe irrigation. *J Endod* 2014;40(October (10)):1622–6.
23. Buchanan LS. Endodontic obturation techniques. The state of the art in 2015. *Dent Today* 2015;34(3):94–5. 90, 92.
24. Li GH, Niu LN, Selem LC, Eid AA, Bergeron BE, Chen JH, et al. Quality of obturation achieved by an endodontic core-carrier system with crosslinked gutta-percha carrier in single-rooted canals. *J Dent* 2014;42(September (9)):1124–34.
25. Keleş A, Alcin H, Kamalak A, Versiani MA. Micro-CT evaluation of root filling quality in oval-shaped canals. *Int Endod J* 2014;47(December (12)):1177–84.
26. Paul ML, Mazumdar D, Vyavahare NK, Baranwal AK. Healing of the periapical lesion in posterior teeth with mineral trioxide aggregate using orthograde technique – two case reports. *Contemp Clin Dent* 2012;(September).
27. Yoo JS, Chang SW, Oh SR, Perinpanayagam H, Lim SM, Yoo YJ, et al. Bacterial entombment by intratubular mineralization following orthograde mineral trioxide aggregate obturation: a scanning electron microscopy study. *Int J Oral Sci* 2014;6(December (4)):227–32.
28. Amato M, Scaravilli MS, Farella M, Riccitiello F. Bleaching teeth treated endodontically: long-term evaluation of a case series. *J Endod* 2006;32(4):376–8.
29. Riccitiello F, Maddaloni G, D'Ambrosio C, Amato M, Rengo S, Simeone M. Operating microscope: diffusion and limits. *G It Endod* 2012;26(2):67–72.
30. Lambertini G, editor. *Anatomia umana- Piccin, Padova*. 1978.
31. Iandolo A. L'utilizzo degli ultrasuoni per una maggiore predici-bilità nella rimozione delle calcificazioni. *G It Endod* 2009;23:3.
32. Pettiette MT, Metzger Z, Phillips C, Trope M. Endodontic complications of root canal therapy performed by dental students with stainless-steel K-files and nickel-titanium hand files. *J Endod* 1999;25:230–4.
33. Sonntag D, Guntermann A, Kim SK, Stachniss V. Root canal shaping with manual stainless steel files and rotary NiTi files performed by students. *Int Endod J* 2003;36:248–55.
34. Bonaccorso A, Tripi RT. Il Nichel Titanio in Endodonzia. *Edizione Martina Bologna* 2006;4:10–9.
35. Spagnuolo G, Desiderio C, Rivieccio V, Amato M, Rossetti DV, D'Antò V, et al. In vitro cellular detoxification of triethylene glycol dimethacrylate by adduct formation with N-acetylcysteine. *G Dent Mater* 2013;29(8):e153–60.
36. Cantatore G, Ceci A. L' Endodonzia verso il duemila, Preparazione canalare con strumenti Ni-Ti Evoluzione delle tecniche. *Dental Cadmos* 1996;2:21–8.
37. Suter B, Lussi A, Sequeira P. Probability of removing fractured instruments from root canals. *Int Endod J* 2005;38:114–23.
38. Sattapan B, Nervo GJ, Palamara JE, Messer HH. Defects in rotary nickel-titanium file after clinical use. *J Endod* 2000;26(3):161–5.
39. D'Antò V, Valletta R, Amato M, Schweikl H, Simeone M, Paduano S, et al. Effect of nickel chloride on cell proliferation. *Open Dent J* 2012;6:177–81.
40. Abou Rass M, Oglesby SW. The effects of temperature, concentration and tissue type on the solvent ability of sodium hypochlorite. *J Endod* 1981;7:376–7.
41. Cunningham WT, Joseph SW. Effect of temperature on the bactericidal action of sodium hypochlorite endodontic irrigant. *Oral Surg Oral Med Oral Pathol* 1980;50:569–71.
42. Cunningham WT, Balekjian AY. Effect of temperature on collagen-dissolving ability of sodium hypochlorite endodontic irrigant. *Oral Surg Oral Med Oral Pathol* 1980;49:175–7.
43. Iandolo A, Ametrano G, Amato M, Rengo S, Simeone M. IG-File: un nuovo strumento per l'ottimizzazione della detersione

- canalare e per la misurazione del diametro apicale. *G It Endod* 2011.
44. Berutti E, Marini R. A scanning electron microscopic evaluation of the debridement capability of sodium hypochlorite at different temperatures. *J Endod* 1996;22:467–70.
 45. Simeone M, Valletta A, Giudice A, Di Lorenzo P, Iandolo A. The activation of irrigation solutions in endodontics: a perfected technique. *G It Endod* 2015 [in press].
 46. Di Lorenzo P, Niola M, Pantaleo G, Buccelli C, Amato M. On the comparison of age determination methods based on dental development radiographic studies in a sample of Italian population. *Dent Cadm* 2015;83:38–45.
 47. Di Lorenzo P, Niola M, Buccelli C, Re D, Cortese A, Pantaleo G, et al. Professional responsibility in dentistry: analysis of an interdepartmental case study. *Dent Cadm* 2015;83:324–40.
 48. Simeone M, De Santis R, Panico G, Riccitiello F, Rengo S. Valutazione del profilo termico dell'otturazione canalare a caldo mediante l'utilizzo del system-B. *G It Endo* 2004;18(4):179–83.
 49. Vitti RP, Prati C, Silva EJ, Sinhoreti MA, Zanchi CH, de Souza e Silva MG, et al. Physical properties of MTA Fillapex sealer. *J Endod* 2013;39(July (7)):915–8.