



First evidence of intersex condition in extensively reared mullets from Sardinian lagoons (central-western Mediterranean, Italy)

Elisabetta Antuofermo, Roberta Ariu, Giovanni Pietro Burrascano, Marta Polinas, Marina Antonella Sanna, Giuseppe Esposito, Marino Prearo & Antonio Pais

To cite this article: Elisabetta Antuofermo, Roberta Ariu, Giovanni Pietro Burrascano, Marta Polinas, Marina Antonella Sanna, Giuseppe Esposito, Marino Prearo & Antonio Pais (2017) First evidence of intersex condition in extensively reared mullets from Sardinian lagoons (central-western Mediterranean, Italy), Italian Journal of Animal Science, 16:2, 283-291, DOI: [10.1080/1828051X.2016.1264260](https://doi.org/10.1080/1828051X.2016.1264260)

To link to this article: <http://dx.doi.org/10.1080/1828051X.2016.1264260>



© 2016 The Author(s). Published by Informa UK Limited, trading as Taylor & Francis Group.



Published online: 12 Dec 2016.



[Submit your article to this journal](#)



Article views: 196



[View related articles](#)



[View Crossmark data](#)

First evidence of intersex condition in extensively reared mullets from Sardinian lagoons (central–western Mediterranean, Italy)

Elisabetta Antuofermo^a, Roberta Ariu^a, Giovanni Pietro Burrari^a, Marta Polinas^a, Marina Antonella Sanna^a, Giuseppe Esposito^a, Marino Prearo^b and Antonio Pais^c

^aDipartimento di Medicina Veterinaria, University of Sassari, Sassari, Italy; ^bLaboratorio Specialistico di Ittiopatologia, Istituto Zooprofilattico Sperimentale del Piemonte, Liguria and Aosta Valley, Torino, Italy; ^cLaboratorio di Acquacoltura e Gestione delle Risorse Acquatiche, Sezione di Scienze Zootecniche, Dipartimento di Agraria, University of Sassari, Sassari, Italy

ABSTRACT

The term intersex describes alterations in gonadal development with the simultaneous presence of male and female reproductive stages in the same gonad of a gonochoristic species. In coastal and estuarine environments, euryhaline fish living in polluted waters such as Mugilidae can frequently show these sexual anomalies. In this work, we analysed adult specimens of three species of euryhaline mullets (*Chelon labrosus*, *Liza aurata* and *Mugil cephalus*) from two Sardinian lagoons (Marceddi and San Teodoro) devoted to extensive aquacultural practices, in order to identify putative alterations in gonads and in gamete development. Overall, 13 of the 158 mullets examined (8.2%) were affected by gonadal disorders: four subjects (one *C. labrosus*, two *L. aurata* and one *M. cephalus*) exhibiting an intersex condition were found in the Marceddi lagoon and the other nine (five *C. labrosus*, two *L. aurata* and two *M. cephalus*) in the San Teodoro lagoon. Twelve of these gonads were classified as testis-ova (TOs) and one, belonging to a *C. labrosus* specimen, was a mixed gonadal tissue (MGT). Intersex condition was evaluated using an intersex index and all the recorded values showed a mild Ovotestis Severity Index (OSI). However, our findings suggest that fish gonadal disorders may be underestimated in extensive reared fish species, particularly in coastal brackish environments polluted by intensive agriculture and animal husbandry activities.

ARTICLE HISTORY

Received 23 August 2016
Revised 16 November 2016
Accepted 21 November 2016

KEYWORDS



Brackish water aquaculture; fish; gonadal disorders; histopathology; Mugilidae

Introduction

The family Mugilidae is one of the most ubiquitous in coastal waters of the world (Crosetti & Blaber 2016). These fishes, generally known as mullets, are widely distributed in all temperate and tropical seas and live in several habitats, including river, estuarine and inland brackish waters. A number of species belonging to this teleost family are economically important for fisheries and aquacultural activities, as they are a major food source in several regions worldwide. Mulletts are cultured in semi-intensive and intensive systems in many areas of the world, but especially in extensive systems such as confined coastal lagoons in the Mediterranean basin. In this geographical area, wild fry of different euryhaline species [(i.e. *Liza aurata* (Risso, 1810), *L. ramada* (Risso, 1827), *L. saliens* (Risso, 1810), *Chelon labrosus* (Risso, 1827) and *Mugil cephalus* Linnaeus, 1758)] usually move in large schools from the sea into inland transitional waters, where they find more

favourable trophic conditions (Crosetti & Blaber 2016). They spend here most of the growing phase before migrating to sea to spawn in surface waters. Like other species, however, mullets tolerate polluted habitats and are sensitive to several contaminants, also to those which can cause intersex conditions in fish (Ortiz-Zarragoitia et al. 2014; Tancioni et al. 2015, 2016).

The term intersex describes alterations in gonadal development with the simultaneous presence of male and female reproductive stages in the same gonad of a gonochoristic species. This condition also indicates the occurrence of testicular oocytes, testicular follicles, testis-ova or ovotestes (Hecker et al. 2006; Bahamonde et al. 2013). In particular, the presence of oocytes in the testes of adult or sub-adults males (i.e. the testicular oocytes, TOs) represents the most commonly reported intersex condition in fish (Abdel-moneim et al. 2015 and references therein). Histological examination can

CONTACT Dr Elisabetta Antuofermo  eantuofermo@uniss.it  Dipartimento di Medicina Veterinaria, University of Sassari, Via Vienna 2, 07100 Sassari, Italy

© 2016 The Author(s). Published by Informa UK Limited, trading as Taylor & Francis Group.

This is an Open Access article distributed under the terms of the Creative Commons Attribution-NonCommercial License (<http://creativecommons.org/licenses/by-nc/4.0/>), which permits unrestricted non-commercial use, distribution, and reproduction in any medium, provided the original work is properly cited.

play a key role to evaluate gonadal alterations by detecting the presence of TOs (Stentiford et al. 2003; Feist et al. 2015). Furthermore, different levels of intersex condition in fish initially evidenced by several authors (Jobling et al. 1998; Van Aerle et al. 2001) were subsequently calculated using the Ovotestis Severity Index (OSI), a ranking system developed by Bateman et al. (2004).

Sexual disorders in fish have been principally attributed to many chemical contaminants, as the endocrine disrupting compounds (EDCs) that can produce effects similar to sex steroids (although EDCs can also influence additional mechanisms not directly oestrogen dependent involved in the development of intersex condition in fish; e.g. see Bahamonde et al. 2013). The EDCs are a wide range of chemical compounds that can affect, among others, the Hypothalamic–Pituitary–Gonad–Liver (HPGL) axis of fish (Hachfi et al. 2012). These substances include both natural oestrogens and several synthetic chemicals such as pesticides, polychlorinated biphenyls (PCBs), phthalates and alkylphenols (Allen et al. 1999 and references therein). In particular, the 17 α -ethinylestradiol (EE2) is a strong endocrine disruptor which mimics the effects of endogenous 17- β -estradiol (E2) (Blewett et al. 2014). It has been observed that EE2 can cause altered oogenesis in females and intersex in males, with production of vitellogenin (the female specific yolk protein precursor in oviparous species) and early-stage eggs in their testes (Tyler et al. 1998; Kidd et al. 2007).

Fish are among the most studied organisms for the effects of chemical contaminants on the development and reproductive processes. A high rate of intersex conditions and other gonadal disorders have been actually detected in many freshwater and marine species from habitats exposed to domestic and industrial wastewaters (Abdel-moneim et al. 2015). In coastal and estuarine environments, in particular, euryhaline fish living in polluted waters such as Mugilidae frequently show sexual alterations and are considered as sentinels of exposure to EDCs (Ortiz-Zarragoitia et al. 2014). In the Mediterranean Sea, extensive mullet culture is still based on the collection of wild fry born in offshore marine waters (as their hatchery production is still not practiced at a commercial level) which return to coastal brackish waters within few months after hatching.

The aim of the present work was to evaluate for the first time the occurrence of intersex condition in cultured Mugilidae from Sardinia (Italy), an insular region in which the extensive farming of these euryhaline fishes is a traditional activity

(Cataudella et al. 2015). Consequently, adult specimens of several mullet species were sampled in two different lagoons devoted to extensive aquacultural practices, in order to identify putative alterations in gonads and in gamete development.

Materials and methods

Study area

Sardinia island (central–western Mediterranean Sea, Italy) is characterised by approximately 80 wetlands covering a surface of about 15.000 hectares. Extensive aquaculture is a typical activity in many of these biotopes, mainly for euryhaline fish such as mullets (Cannas et al. 1998). In this study, two of these brackish habitats were examined (a) the Marceddi lagoon (central–western Sardinia, Figure 1), which is part of the Oristano Lagoon Gulf-system, a wetland area traditionally devoted to fishing and aquacultural practices (Cataudella et al. 2015); and (b) the San Teodoro lagoon (north-eastern Sardinia, Figure 1) in which extensive fish farming have been developed since 1980s.

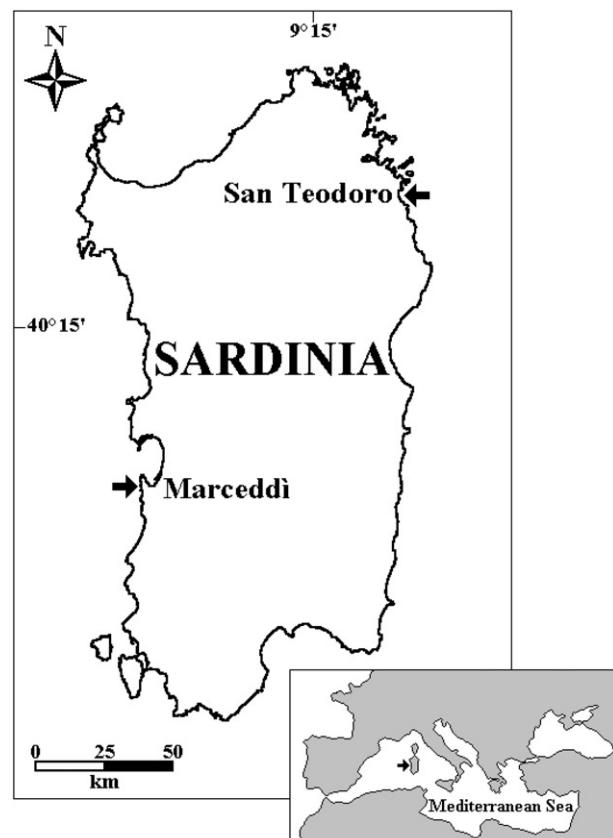

Figure 1. Study area and sampling locations.

Sampling

One hundred and fifty-eight adult fish belonging to the family Mugilidae were sampled before 11.00 a.m. in the capture chambers of fixed traps (lavorieri; Cataudella et al. 2015) placed respectively at Marceddì (8 *C. labrosus*, 48 *L. aurata* and 4 *M. cephalus*) and San Teodoro (24 *C. labrosus*, 53 *L. aurata* and 21 *M. cephalus*) lagoons in late summer 2014. Fish were immediately euthanized by overexposure to Tricaine Methanesulfonate (MS-222), kept on tanks with ice and transported to the laboratory within 2 h after capture. All the specimens were classified at species level following Farrugio (1977), weighed for total weight, measured for total length and photographed. Afterwards, a necropsy of each subject was carried out and, after weighing, gonads were grossly observed, photographed and fixed in 10% neutral buffered formalin for 48 h for subsequent histological analysis.

Histology

Samples taken from anterior, middle and posterior part of both right and left fixed gonads of each specimen were dehydrated in graded alcohol, cleared with xylene and paraffin embedded. Three sections (approximately taken at one third of each portion) were cut at 3-micron-thickness, stained with haematoxylin-eosin and subsequently observed at light microscopy (Nikon Eclipse 80i).

Gonadal maturation stages were assessed using the classification described by McDonough et al. (2005). Oocyte development was classified into five distinct reproductive stages: immature stage (F1), with previtellogenic oocytes (<80 µm), no evidence of atresia and ovary wall is very thin; developing stage (F2), where oocytes are greater than 120 µm and vitellogenesis occurs after they reach 180 µm in size, showing yolk globules and reaching more than 600 µm; running stage (F3), where vitellogenesis is completed and the whole cytoplasm is filled with yolk granules; atretic stage (F4), in which oocytes undergone degeneration; and inactive stage (F5), where there are previtellogenic oocytes with only traces of atresia. Furthermore, spermatogenic stages were classified as follows: immature stage (M1), with spermatogonia and little or no spermatocytic development; developing stage (M2), with predominance of primary and secondary spermatocytes; running stage (M3), with predominance of spermatozoa; spent stage (M4), in which no spermatogenesis occurs with some residual spermatozoa; and inactive stage (M5), with little or no spermatocytic development and empty lobules. If different development stages

were observed in the same gonad, the sexual maturity of each mullet was classified in relation to the most advanced stage of maturation found.

When a gonadal disorder was observed, the intersex condition was evaluated following the method illustrated by Hecker et al. (2006). In particular, if single or clustered oocytes were present in testicular tissue the condition was termed testis-ova (TOs). For each gonad section, photomicrographs were acquired with a Nikon Digital Sight DS-U1 camera, and number, development stage (previtellogenic, cortical alveolar, vitellogenic) and distribution of oocytes (focal, diffuse, cluster, zonal) throughout testis were evaluated. This was done to calculate the so-called OSI, a ranking system for assigning a severity rating to each intersex fish:

$$OSI = \left[\frac{\sum (D_1 \times D_2)}{X} \right]$$

where D_1 is the most advanced development stage of oocytes within a field of view (score 1–5), D_2 is the distribution of oocytes within a field of view (score 1–4) and X is the total number of fields of view examined (Bateman et al. 2004 and references therein). 10 fields of each tissue section were examined at 10× magnification. In detail, the development stages of oocytes were scored as follows: stage 1 (oogonia), stage 2 (oocytes in early perinucleolus stage), stage 3 (oocytes in late perinucleolus stage), stage 4 (oocytes in cortical stage) and stage 5 (oocytes in mature vitellogenic stage). The distribution of oocytes were instead scored as follows: stage 1 or focal distribution (when a single oocyte was present within a field of view), stage 2 or diffuse distribution (when a number of distinct oocytes were observed in a field), stage 3 or cluster distribution (when more than one but less than five associated oocytes were present in a field) and stage 4 or zonal distribution (when multiple closely groups of oocytes were seen within a field).

Results

Different stages of sexual development were observed in the three mullet species from the two lagoons (Table 1, Figures 2 and 3). When examined macroscopically, immature female gonads were pinkish and translucent, with a circular cross section of about 0.5 cm. Mature female gonads, instead, had a yellowish-orange colour, with a round cross section from 1 to 2.5 cm. Immature male gonads appeared filiform, pinkish and translucent with a cross section of about 1–2 mm, whereas mature male gonads had a whitish-milky aspect, with a triangular cross section of about

1–1.5 cm (Figure 2). Microscopically, gonads were classified as follows: six females (all at F1 stage) and one male (M2) of *C. labrosus*, 42 females (13 at F1, five at F2 and 24 at F3) and four males (one at M2, three at M3) of *L. aurata*, one female (F1) and two males (one at M1 and one at M2) of *M. cephalus* were found in the Marceddì lagoon. On the other hand, 12 females (11 at F1 and one at F2) and 7 (all at M1) males of *C. labrosus*, 35 females (23 at F1, two at F2 and 10 at F3) and 15 males (two at M1, six at M2 and seven at M3) of *L. aurata*, 8 females (two at F1, four at F2 and two at F3) and 11 males (one at M1, one at M2 and nine at M3) of *M. cephalus* were found in the San Teodoro lagoon. Only an *L. aurata* female specimen sampled at this latter lagoon was not microscopically evaluated. The other mullets examined (13 out of 158; 8.2% of the total) were affected by an intersex condition of the gonads [12 classified as TOs and one as mixed gonadal tissue (MGT) following Hecker et al. (2006)]. In detail, four subjects with gonadal disorders [(one *C. labrosus* (MGT, Figure 4), two *L. aurata* and one *M. cephalus*)] were found in the Marceddì lagoon

Table 1. Female, male and intersex gonadal stages of mullets sampled in the two lagoons.

Site	Species	Females			Males			Intersex	
		F1	F2	F3	M1	M2	M3	TOs	MGT
Marceddì	<i>C. labrosus</i>	6	–	–	–	1	–	–	1
	<i>L. aurata</i>	13	5	24	–	1	3	2	–
	<i>M. cephalus</i>	1	–	–	1	1	–	1	–
San Teodoro	<i>C. labrosus</i>	11	1	–	7	–	–	5	–
	<i>L. aurata</i>	23	2	10	2	6	7	2	–
	<i>M. cephalus</i>	2	4	2	1	1	9	2	–

and the other nine (five *C. labrosus*, two *L. aurata* and two *M. cephalus*) in the San Teodoro lagoon (Table 2). Macroscopically, almost all of these fish had gonads showing an aspect similar to those of immature males. The only exception was represented by two *M. cephalus* specimens (sampled at Marceddì and San Teodoro, respectively), which gonads were comparable in colour and form to those of mature males (Figure 2). Microscopically, the male component of the 12 TOs observed was classified as follows: one at M1 and one at M2 stage *L. aurata*, and one at M3 *M. cephalus* at the Marceddì lagoon; one at M1 and one at M3 stage *L. aurata*, four at M1 and one at M2 *C. labrosus* and two at M3 *M. cephalus* were instead found at the San Teodoro lagoon (Figure 3). It is also worth mentioning that the *C. labrosus* specimen sampled at the Marceddì lagoon (MR37, Table 2) showing a monolateral MGT had one gonad with a normal ovary tissue and the other with several primary oocytes within a testicular tissue (Figure 4). As far as OSI is concerned, it varied from a minimum of 0.1 to a maximum of 2.4. Thus, all the recorded values were included in the stage 1 (i.e. OSI score = $0 \div 5$) of severity categories proposed by Bateman et al. (2004).

Discussion

In this study, we reported for the first time the occurrence of intersex condition in extensively reared mullets from two lagoons of the central-western Mediterranean Sea. In the Marceddì lagoon, we found intersex gonads in four fish out of 60 sampled

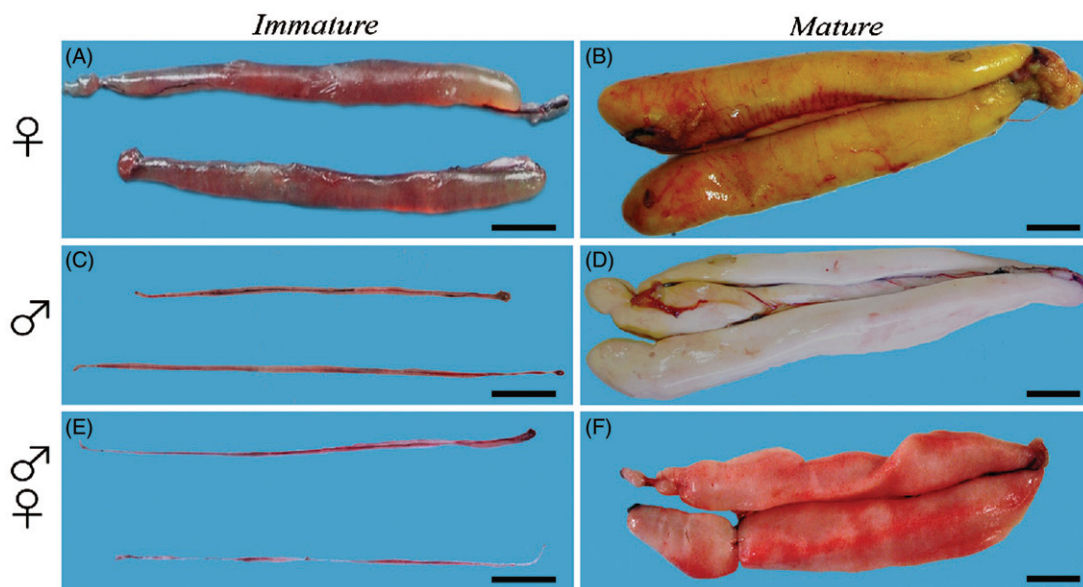


Figure 2. *M. cephalus*. Gross structure of immature and mature females (A, B), males (C, D) and intersex (E, F) gonads (bar = 10 mm).

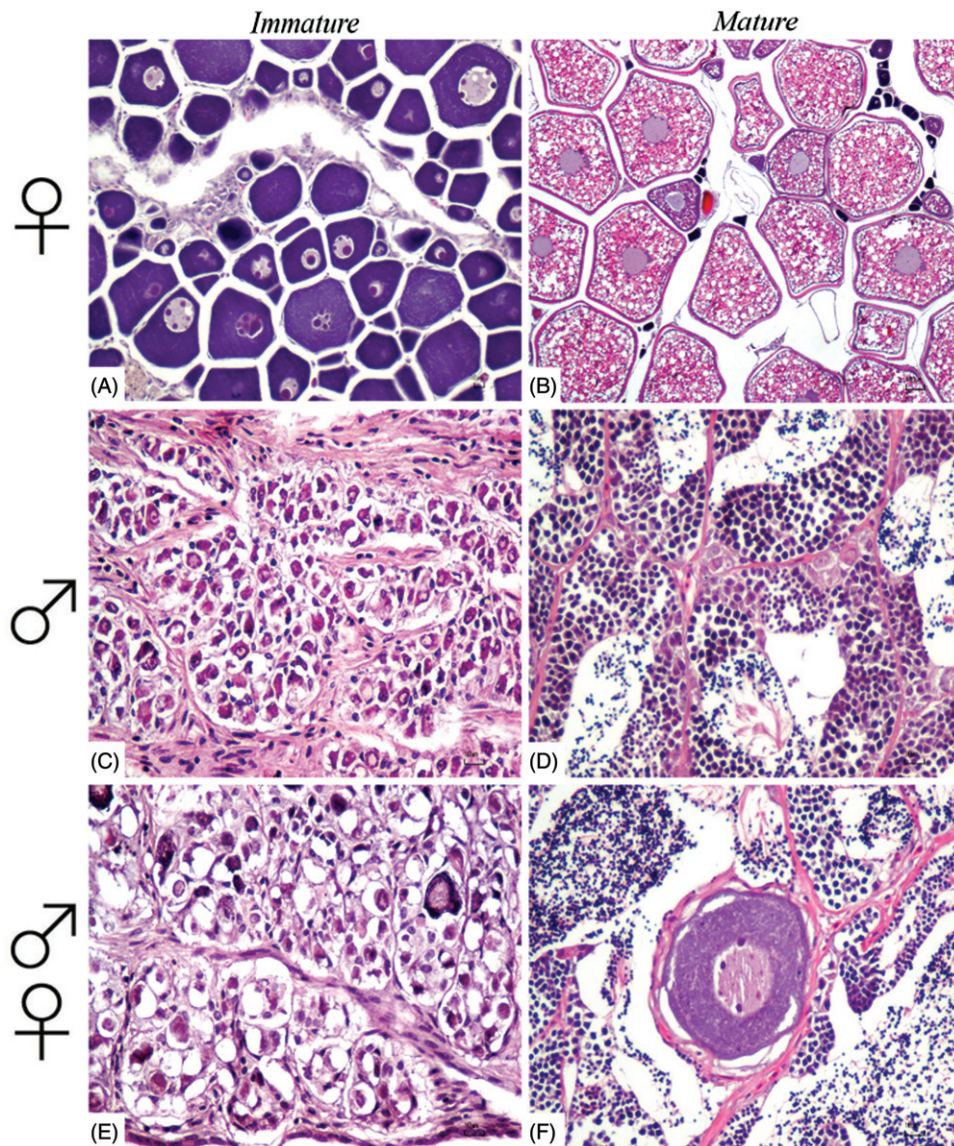


Figure 3. *M. cephalus*. Microscopic features of: immature and mature female gonads (A = previtellogenic oocytes, HE 20 \times ; B = vitellogenic oocytes, HE 10 \times); immature and mature male gonads (C = seminiferous lobules with high prevalence of spermatogonia, HE 40 \times ; D = seminiferous lobules with different maturation stages of testis germ cells, HE 40 \times) and TO gonads (E = previtellogenic oocyte at chromatin nucleolus stage within immature testicular tissue, HE 40 \times ; F = previtellogenic oocyte at cortical alveoli stage within mature testicular tissue, HE 40 \times).

(6.7% of the total; 12.5% in *C. labrosus*, 4.2% in *L. aurata* and 25% in *M. cephalus*, respectively), while in the San Teodoro lagoon this gonadal disorder was observed in nine of 98 subjects examined (9.2% of the total; 20.8% in *C. labrosus*, 3.8% in *L. aurata* and 9.5% in *M. cephalus*, respectively).

In the aquatic habitat, there are numerous contaminants (the so-called EDCs) that are able to interfere with the endocrine system with damaging effects on growth, behaviour, reproductive and immune system of aquatic organisms. Morphological modification and abnormal development of the gonads, including

intersex, have been observed in a number of fish species living in polluted waters (Jobling et al. 1998; Puzzi et al. 2005), and have been linked to exposure to EDCs (Scholz & Klüver 2009) and other chemicals released with human and industrial discharges (Van Aerle et al. 2001; Tetreault et al. 2011). In particular, gonadal disorders have been reported worldwide for several mullet species: *C. labrosus* was studied by Puy-Azurmendi et al. (2013) and Bizarro et al. (2014) at the Bay of Biscay (Spain); *L. ramada* by Bayhan and Acarli (2006) at the Homa Lagoon (Turkey) and Tancioni et al. (2015, 2016) at the Tiber estuary (Italy); and

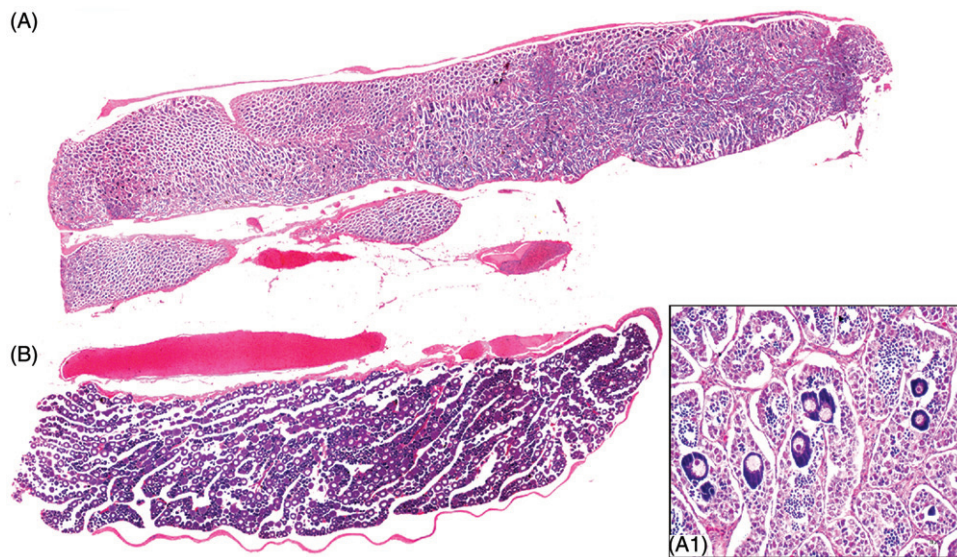


Figure 4. *C. labrosus*. Monolateral MGT: A = testis with previtellogenic oocytes within the seminiferous lobules (A1, HE 40 \times); B = immature female gonad with previtellogenic oocytes (HE 2 \times).

Table 2. Biometric features and Intersex Index of the mullets affected by intersex condition.

Case #	ID #	Species	Total length, cm	Total weight, g	Gonad weight, g	Intersex Index
1	MR37	<i>C. labrosus</i>	40.4	755.3	1.2	–
2	STA48	<i>C. labrosus</i>	25.1	162.9	nd	0.6
3	STA62	<i>C. labrosus</i>	28.6	222.7	0.1	2.4
4	STA65	<i>C. labrosus</i>	29.8	268.4	0.2	1.8
5	STA66	<i>C. labrosus</i>	30.9	271.4	0.1	0.8
6	STA86	<i>C. labrosus</i>	34.2	401.2	0.2	0.1
7	MR68	<i>L. aurata</i>	27.7	224.0	0.1	2.0
8	MR78	<i>L. aurata</i>	26.3	174.7	0.2	0.1
9	STA3	<i>L. aurata</i>	28.7	196.2	0.1	0.6
10	STA9	<i>L. aurata</i>	24.2	109.0	0.1	0.7
11	MR89	<i>M. cephalus</i>	38.7	571.6	1.3	0.2
12	STA114	<i>M. cephalus</i>	46.2	1101.2	5.7	0.5
13	STA117	<i>M. cephalus</i>	41.6	812.0	0.4	0.1

MRn: Marceddi; STAn: San Teodoro.

M. cephalus by Ferreira et al. (2004) at the Douro estuary (Portugal) and Aoki et al. (2010) in the Korean and Japanese coastal waters.

To the best of our knowledge, this is the first report of cases of gonadal disorder in *L. aurata* (two specimens at Marceddi and two at the San Teodoro lagoon) which highlights the susceptibility to contaminants also for this species. Thus, as different mullet species can inhabit the same coastal brackish environment [in particular, the lagoons of the Mediterranean basin, Cataudella et al. (2015)], because they are able to use the *pabulum* by directly grazing the bottom mud or using plant-detritus (Crosetti & Blaber 2016), the outcomes of our work evidenced the simultaneous presence of gonadal abnormalities (TOs) in several mullet species cohabiting in two different aquatic biotopes. In particular, it is important to note that the Marceddi lagoon is located near an area of intensive agricultural and zootechnical activities which wastewaters can be

a potential source of chemicals that contribute to intersex formation in fish. Until the early 1990s, mining was also present in the drainage basin of the Marceddi lagoon where high concentrations of heavy metals [which can also contribute to intersex formation; see e.g. Hinck et al. (2007)] have been found in sediments (Magni et al. 2006). The San Teodoro lagoon, instead, receives municipal wastewaters from the small town of San Teodoro (one of the most important tourist centre in north-eastern Sardinia), and nutrient-rich freshwater from two little rivers which sometimes discharge into it untreated wastewaters from the surrounding area (Antuofermo et al. 2016).

In our results, TOs (12 of the 13 gonadal abnormalities observed) were the most represented intersex condition in mullets, as previously reported by several authors for fish and amphibians (Abdel-moneim et al. 2015 and references therein). Only one specimen (*C. labrosus* from Marceddi) showed a monolateral MGT

which may be considered as an example of rudimentary hermaphroditism (because male and female gonads were present in the same fish; Hecker et al. 2006), whose origin could be related to natural or exogenous factors.

In fish, testes have to be examined histologically to detect cases of intersex because the testicular tissues can often appear normal at gross examination. In mullets, a high rate of intersex gonads (23.1% of the fish examined) was found by Tancioni et al. (2016) in a wild population of thinlip grey mullet *L. ramada* from a polluted estuary in central Italy. Similar rates of intersex gonads were observed in other mullets sampled from other polluted environments: 21% in flathead grey mullet (*M. cephalus*) from the Douro estuary in northern Portugal by Ferreira et al. (2004), and up to 50% in thicklip grey mullet (*C. labrosus*) from the Bay of Biscay in northern Spain (Puy-Azurmendi et al. 2013; Bizarro et al. 2014).

Several studies have evidenced that intersexuality can vary from mild to severe stages according to the number, maturity and distribution of oocytes within the normal testicular tissue (Bateman et al. 2004 and references therein). For this reason, we decided to attribute a score to each intersex specimen according to the OSI proposed by Bateman et al. (2004). This index ranges from a stage 1 indicating mild intersex (based on the presence of few previtellogenic oocytes within a normal testis) to a stage 3 showing a severe abnormality of the testicular tissue, which is replaced by numerous oocytes in advanced stage of development. All TOs found in our study were classified as stage 1 of OSI (intersex individuals exhibited a mild grade of intersex condition corresponding to testis with scarce previtellogenic oocytes) (Jobling et al. 1998; Ferreira et al. 2004). The application of OSI was not suitable only in one case of intersex in which we observed an MGT (*sensu* Hecker et al. 2006), as suggested by Bateman et al. (2004).

Only few recent studies have reported the severity of the intersex condition in mullets. For example, according to the classification proposed by Jobling et al. (1998), Bizarro et al. (2014) and Sardi et al. (2015) observed mild to moderate severity values in *C. labrosus* from the Basque coast (Spain). Several authors reported that mild severities of gonadal intersex (i.e. stage 1 of OSI) are generally not associated with impairments in the reproductive activity of fish (Abdelmoneim et al. 2015 and references therein), although adverse reproductive effects are likely when severity of intersex condition increases (Jobling et al. 1998, 2002; Harris et al. 2011). At this regard, a direct correlation between the incidence and the severity of sexual

disruption in fish, and natural or synthetic chemicals (EDCs) in the waters was already evidenced by Jobling et al. (2006). In view of this, the timing of exposure to these compounds can be critical as fish seem to be most susceptible to EDCs just after hatching or as juveniles before sex differentiation (Jobling et al. 1998; Bateman et al. 2004). In particular, there is a sensitivity period occurring during the first few months of larval development (Devlin & Nagahama 2002) in which a transitory exposure to xenobiotics can feminise male fish (Ortiz-Zarragoitia et al. 2014). This period is usually spent offshore by the fry of mullets, and the consequent sexual differentiation (corresponding to juvenile recruitment into estuarine waters) can be affected by high concentrations of EDCs (Ortiz-Zarragoitia et al. 2014).

However, a low level of gonadal intersex (<5%) may naturally occur in a number of gonochoristic fish species (Blazer et al. 2007 and references therein). Although a relatively high percentage of intersex was observed at Marceddì and San Teodoro lagoons (6.7 and 9.2%, respectively), we cannot completely exclude a natural phenomenon (not related to EDCs exposure) due to innate physiological drivers giving rise for generally low grade intersex condition. In fact, even if Tancioni et al. (2015) affirmed that the prevalence of natural hermaphroditism in mullets is non-existent or very low, some cases were previously reported for *M. cephalus* (Franks et al. 1998) and *L. ramada* (Bayhan & Acarli 2006). Thus, it is also possible that there is a general lack of information on this specific topic for migratory fish such as mullets, conversely to other more studied species (Bahamonde et al. 2013).

In any case, the incidence of intersex condition in mullets can vary with the season. In fact, a seasonal pattern was evidenced in wild *L. ramada* by Tancioni et al. (2015) with high values recorded during the spawning and gonad development periods. Analogously, Ferreira et al. (2004) and Aoki et al. (2010) observed the same phenomenon in *M. cephalus*. For this reason, to improve the assessment of the impact of environmental pollution on the reproductive status of wild fish, it would be better sampling two or to three weeks before their spawning season (Barrett & Munkittrick 2010). Unfortunately, in this study we considered only one sampling period (late summer 2014), when the availability of different species of extensive reared mullets in the capture chambers of fixed traps (Iavorieri; Cataudella et al. 2015) placed in the two lagoons mouths was maximum.

The percentage of intersex and the values of intersex severity index we found in mullets at both Marceddì and San Teodoro lagoons were lower in

comparison with the previous cited works seems to drive our results to naturally intersex conditions. Nevertheless, Mugilidae can be considered as sentinel species in coastal biomonitor investigations (Waltham et al. 2013) and in particular of exposure to EDCs in coastal and estuarine polluted environments (Ortiz-Zarragoitia et al. 2014 and references therein). The study of their gonadal alterations should be further developed to evaluate anthropogenic threats (especially those linked to urban and industrial activities) to species of interest in aquaculture (Tancioni et al. 2016).

Conclusions

Due to their economic importance, several problems linked to the extensive rearing of mullets have been studied in Sardinia in the last few years (Merella & Garippa 2001; Murgia et al. 2002; Antuofermo et al. 2016). In fact, in this island, mullets are cultured not only for direct human consumption, but also for the preparation of a gourmet delicacy called 'bottarga' (fish roe, in particular of *M. cephalus* and *C. labrosus*).

Our findings suggest that a suitable management of this resource in extensive aquaculture activities have to take into account fish gonadal disorders. In fact, these sexual abnormalities may be underestimated also in other extensive reared fish species, particularly in coastal brackish environments polluted by intensive agriculture and animal husbandry practices.

Acknowledgments

The authors are grateful to the Marceddì and San Teodoro fishermen's cooperatives for their assistance in sample collection. This work was supported by Fondazione Banco di Sardegna Prot. n. 6409 (RF 2014-1115) and is part of EA PhD thesis. Comments and suggestions from two anonymous reviewers improved the quality of the manuscript.

Disclosure statement

The authors report no conflicts of interest. The authors alone are responsible for the content and writing of this article.

Funding

This work was supported by Fondazione Banco di Sardegna Prot. n. 6409 (RF 2014-1115) and is part of EA PhD thesis.

References

Abdel-moneim A, Coulter DP, Mahapatra CT, Sepulveda MS. 2015. Intersex in fishes and amphibians: population implications, prevalence, mechanisms and molecular biomarkers. *J Appl Toxicol.* 35:1228–1240.

- Allen Y, Scott AP, Matthiessen P, Haworth S, Thain JE, Feist S. 1999. Survey of estrogenic activity in United Kingdom estuarine and coastal waters and its effects on gonadal development of the flounder *Platichthys flesus*. *Environ Toxicol Chem.* 18:1791–1800.
- Antuofermo E, Pais A, Polinas M, Cubeddu T, Righetti M, Sanna MA, Prearo M. Forthcoming 2016. Mycobacteriosis caused by *Mycobacterium marinum* in reared mullets: first evidence from Sardinia (Italy). *J Fish Dis.* doi: 10.1111/jfd.12515.
- Aoki JY, Nagae M, Takao Y, Hara A, Lee YD, Yeo IK, Lim BS, Park CB, Soyano K. 2010. Survey of contamination of estrogenic chemicals in Japanese and Korean coastal waters using the wild grey mullet (*Mugil cephalus*). *Sci Total Environ.* 408:660–665.
- Bahamonde PA, Munkittrick KR, Martyniuk CJ. 2013. Intersex in teleost fish: are we distinguishing endocrine disruption from natural phenomena? *Gen Comp Endocrinol.* 192:25–35.
- Barrett TJ, Munkittrick KR. 2010. Seasonal reproductive patterns and recommended sampling times for sentinel fish species used in environmental effects monitoring programs in Canada. *Environ Rev.* 18:115–135.
- Bateman KS, Stentiford GD, Feist SW. 2004. A ranking system for the evaluation of intersex condition in European flounder (*Platichthys flesus*). *Environ Toxicol Chem.* 23:2831–2836.
- Bayhan B, Acarli D. 2006. Hermaphrodite thinlip mullet *Liza ramada* (Risso, 1810) (Teleostei: Mugilidae) from Homa Lagoon (Izmir Bay-Aegean Sea). *Aquacult Res.* 37:1050–1052.
- Bizarro C, Ros O, Vallejo A, Prieto A, Etxebarria N, Cajaraville MP, Ortiz-Zarragoitia M. 2014. Intersex condition and molecular markers of endocrine disruption in relation with burdens of emerging pollutants in thicklip grey mullets (*Chelon labrosus*) from Basque estuaries (South-East Bay of Biscay). *Mar Environ Res.* 96:19–28.
- Blazer VS, Iwanowicz LR, Iwanowicz DD, Smith DR, Young JA, Hedrick JD, Foster SW, Reeser SJ. 2007. Intersex (testicular oocytes) in smallmouth bass from the Potomac River and selected nearby drainages. *J Aquat Anim Health.* 19:242–253.
- Blewett TA, Chow TL, MacLachy DL, Wood CM. 2014. A species comparison of 17- α -ethynylestradiol uptake and tissue-specific distribution in six teleost fish. *Comp Biochem Physiol.C Toxicol Pharmacol.* 161:33–40.
- Cannas A, Cataudella S, Rossi R. 1998. Gli stagni della Sardegna. Quaderni Acquacoltura. Cagliari: C.I.R.S.P.E.
- Cataudella S, Crosetti D, Massa F. 2015. Mediterranean coastal lagoons: sustainable management and interactions among aquaculture, Capture Fisheries and the Environment. FAO General Fisheries Commission for the Mediterranean, Studies and Reviews, 95. Rome, Italy.
- Crosetti D, Blaber S. 2016. Biology, ecology and culture of grey mullets (Mugilidae). Boca Raton, FL: CRC Press.
- Devlin RH, Nagahama Y. 2002. Sex determination and sex differentiation in fish? An overview of genetic, physiological, and environmental influences. *Aquaculture.* 208:191–364.
- Farrugio H. 1977. Clés commentées pour la détermination des adultes et des alevins de Mugilidae de Tunisie. *Cybiun.* 2:57–73.

- Feist SW, Stentiford GD, Kent ML, Ribeiro Santos A, Lorance P. 2015. Histopathological assessment of liver and gonad pathology in continental slope fish from the northeast Atlantic Ocean. *Mar Environ Res.* 106:42–50.
- Ferreira M, Antunes P, Gil O, Vale C, Reis-Henriques MA. 2004. Organochlorine contaminants in flounder (*Platichthys flesus*) and mullet (*Mugil cephalus*) from Douro estuary, and their use as sentinel species for environmental monitoring. *Aquat Toxicol.* 69:347–357.
- Franks JS, Brown-Peterson NJ, Wilson DP, Russell RJ, Welker JK. 1998. Occurrence of a synchronous hermaphroditic striped mullet, *Mugil cephalus*, from the northern Gulf of Mexico. *Gulf Res Rep.* 10:33–40.
- Hachfi L, Couvray S, Simide R, Tarnowska K, Pierre S, Gaillard S, Richard S, Coupé S, Grillasca JP, Prévot-D'Alvise N. 2012. Impact of endocrine disrupting chemicals (EDCs) on hypothalamic-pituitary-gonad-liver (HPGL) axis in fish. *World J Fish Marine Sci.* 4:14–30.
- Harris CA, Hamilton PB, Runnalls TJ, Vinciotti V, Henshaw A, Hodgson D, Coe TS, Jobling S, Tyler CR, Sumpter JP. 2011. The consequences of feminization in breeding groups of wild fish. *Environ Health Perspect.* 119:306–311.
- Hecker M, Murphy MB, Coady KK, Villeneuve DL, Jones PD, Carr JA, Solomon KR, Smith EE, Van Der Kraak G, Gross T, et al. 2006. Terminology of gonadal anomalies in fish and amphibians resulting from chemical exposures. *Rev Environ Contam Toxicol.* 187:103–131.
- Hinck JE, Blazer VS, Denslow ND, Echols KR, Gross TS, May TW, Anderson PJ, Coyle JJ, Tillitt DE. 2007. Chemical contaminants, health indicators, and reproductive biomarker responses in fish from the Colorado River and its tributaries. *Sci Total Environ.* 378:376–402.
- Jobling S, Nolan M, Tyler CR, Brighty G, Sumpter JP. 1998. Widespread sexual disruption in wild fish. *Environ Sci Technol.* 32:2498–2506.
- Jobling S, Coey S, Whitmore JG, Kime DE, Van Look KJW, McAllister BG, Beresford N, Henshaw AC, Brighty G, Tyler CR, et al. 2002. Wild intersex roach (*Rutilus rutilus*) have reduced fertility. *Biol Reprod.* 67:515–524.
- Jobling S, Williams R, Johnson A, Taylor A, Gross-Sorokin M, Nolan M, Tyler CR, van Aerle R, Santos E, Brighty G. 2006. Predicted exposures to steroid estrogens in U.K. rivers correlate with widespread sexual disruption in wild fish populations. *Environ Health Perspect.* 114(Suppl 1):32–39.
- Kidd KA, Blanchfield PJ, Mills KH, Palace VP, Evans RE, Lazorchak JM, Flick RW. 2007. Collapse of a fish population after exposure to a synthetic estrogen. *Proc Natl Acad Sci USA.* 104:8897–8901.
- Magni P, De Falco G, Falugi C, Franzoni M, Monteverde M, Perrone E, Sgro M, Bolognesi C. 2006. Genotoxicity biomarkers and acetylcholinesterase activity in natural populations of *Mytilus galloprovincialis* along a pollution gradient in the Gulf of Oristano (Sardinia, western Mediterranean). *Environ Pollut.* 142:65–72.
- McDonough CJ, Roumillat WA, Wenner CA. 2005. Sexual differentiation and gonad development in striped mullet (*Mugil cephalus* L.) from South Carolina estuaries. *Fish Bull.* 103:601–619.
- Merella P, Garippa G. 2001. Metazoan parasites of grey mullets (Teleostea: Mugilidae) from the Mistras Lagoon (Sardinia, Western Mediterranean). *Sci Mar.* 65:201–206.
- Murgia R, Tola G, Archer SN, Vallerga S, Hirano J. 2002. Genetic identification of grey mullet species (Mugilidae) by analysis of mitochondrial DNA sequence: application to identify the origin of processed ovary products (Bottarga). *Mar Biotechnol.* 4:119–126.
- Ortiz-Zarragoitia M, Bizarro C, Rojo-Bartolomé I, Diaz de Cerio O, Cajaraville MP, Cancio I. 2014. Mugilid fish are sentinels of exposure to endocrine disrupting compounds in coastal and estuarine environments. *Mar Drugs.* 12:4756–4782.
- Puy-Azurmendi E, Ortiz-Zarragoitia M, Villagrasa M, Kuster M, Aragon P, Atienza J, Puchades R, Maquieira A, Dominguez C, Lopez de Alda M, et al. 2013. Endocrine disruption in thicklip grey mullet (*Chelon labrosus*) from the Urdaibai Biosphere Reserve (Bay of Biscay, Southwestern Europe). *Sci Total Environ.* 443:233–244.
- Puzzi C, Bottero S, Cevasco A, Massari A, Monteverde M, Pedemonte F, Bertolotti R, Viganò L, Mandich A. 2005. Fish community characterization in two stretches upstream and downstream of the Lambro River confluence with the Po River. *Ann NY Acad Sci.* 1040:439–443.
- Sardi AE, Bizarro C, Cajaraville MP, Ortiz-Zarragoitia M. 2015. Steroidogenesis and phase II conjugation during the gametogenesis of thicklip grey mullet (*Chelon labrosus*) from a population showing intersex condition. *Gen Comp Endocrinol.* 221:144–155.
- Scholz S, Klüver N. 2009. Effects of endocrine disruptors on sexual, gonadal development in fish. *Sex Dev.* 3:136–151.
- Stentiford GD, Longshaw M, Lyons BP, Jones G, Green M, Feist SW. 2003. Histopathological biomarkers in estuarine fish species for the assessment of biological effects of contaminants. *Mar Environ Res.* 55:137–159.
- Tancioni L, Caprioli R, Al-Khafaji AHD, Mancini L, Boglione C, Ciccotti E, Cataudella S. 2015. Gonadal disorder in the thinlip grey mullet (*Liza ramada*, Risso 1827) as a biomarker of environmental stress in surface waters. *Int J Environ Res Public Health.* 12:1817–1833.
- Tancioni L, Caprioli R, Al-Khafaji AHD, Mancini L, Boglione C, Ciccotti E, Cataudella S. 2016. Anthropogenic threats to fish of interest in aquaculture: gonad intersex in a wild population of thinlip grey mullet *Liza ramada* (Risso, 1827) from a polluted estuary in central Italy. *Aquacult Res.* 47:1670–1674.
- Tetreault GR, Bennett CJ, Shires K, Knight B, Servos M, McMaster ME. 2011. Intersex and reproductive impairment of wild fish exposed to multiple municipal wastewater discharges. *Aquat Toxicol.* 104:278–290.
- Tyler CR, Jobling S, Sumpter JP. 1998. Endocrine disruption in wildlife: a critical review of the evidence. *Crit Rev Toxicol.* 28:319–361.
- Van Aerle R, Nolan M, Jobling S, Christiansen LB, Sumpter JP, Tyler CR. 2001. Sexual disruption in a second species of wild cyprinid fish (the Gudgeon, *Gobio gobio*) in United Kingdom freshwaters. *Environ Toxicol Chem.* 20:2841–2847.
- Waltham NJ, Teasdale PR, Connolly RM. 2013. Use of flathead mullet (*Mugil cephalus*) in coastal biomonitor studies: review and recommendations for future studies. *Mar Pollut Bull.* 69:195–205.