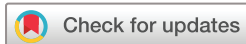

Neonatal acute scrotum: do not forget Amyand hernia

Edoardo Guida,¹ Irene Del Rizzo,² Francesca Galdo,³ Flora Maria Murru,⁴ Jurgen Schleeff,¹ Francesco Maria Rizzo,³ Egidio Barbi,^{2,5} Ingrid Rabach⁵

To cite: Guida E, Del Rizzo I, Galdo F, et al. Neonatal acute scrotum: do not forget Amyand hernia. *World Jnl Ped Surgery* 2020;**3**:e000139. doi:10.1136/wjps-2020-000139

Received 25 April 2020
Revised 17 June 2020
Accepted 18 June 2020



© Author(s) (or their employer(s)) 2020. Re-use permitted under CC BY-NC. No commercial re-use. See rights and permissions. Published by BMJ.

¹Department of Pediatric Surgery, IRCCS Materno Infantile Burlo Garofolo, Trieste, Friuli-Venezia Giulia, Italy

²Clinical Department of Medical Surgical and Health Sciences, University of Trieste, Trieste, Friuli-Venezia Giulia, Italy

³Department of Neonatology and Neonatal Intensive Care Unit, IRCCS Materno Infantile Burlo Garofolo, Trieste, Friuli-Venezia Giulia, Italy

⁴Department of Pediatric Radiology, IRCCS Materno Infantile Burlo Garofolo, Trieste, Friuli-Venezia Giulia, Italy

⁵Pediatric Department, IRCCS Materno Infantile Burlo Garofolo, Trieste, Friuli-Venezia Giulia, Italy

Correspondence to

Dr Irene Del Rizzo; idr8991@gmail.com

A 15-day-old full-term newborn was admitted to the emergency department for right scrotal swelling, irritability and poor feeding that started 12 hours earlier, without fever or vomiting. Parents reported that his last defecation occurred 3 days before admission. Physical examination was remarkable for a swollen, erythematous and tender right hemiscrotum (figure 1).

Scrotal ultrasonography showed an inguinal hernia with an air-filled tubular structure that seemed somehow different from a typical intestinal loop; the plain radiography confirmed this finding.

Emergency surgical exploration of the right groin and scrotum revealed an external right inguinal hernia with an inflamed vermiform appendix in the herniary sac (figure 2), leading to the diagnosis of Amyand hernia with an inflamed appendix.

Amyand hernia consists of the presence of the vermiform appendix in an inguinal

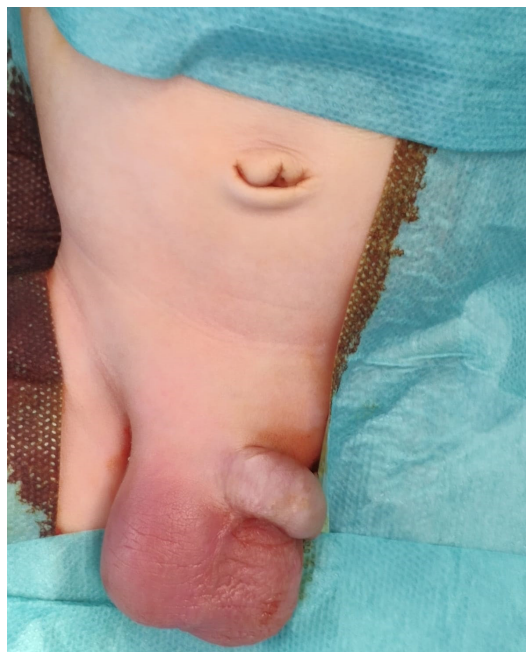

Figure 1 Erythema and swelling of the right hemiscrotum.

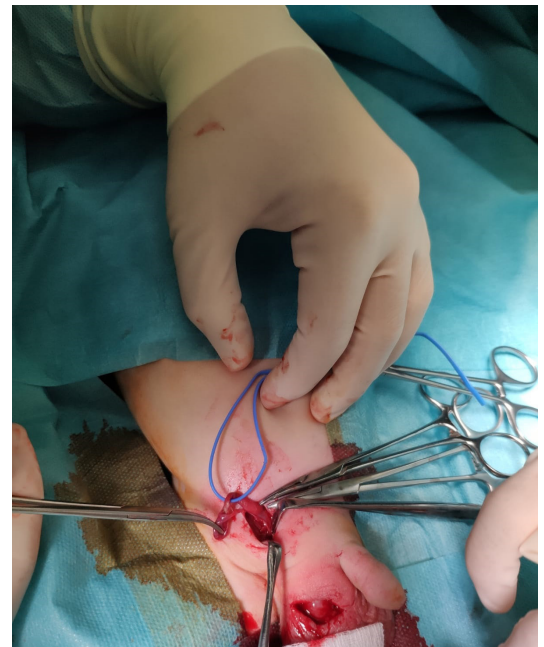


Figure 2 Intraoperative finding of acute appendicitis into the right groin. The right testicle appeared macroscopically normal.

herniary sac and is an unusual finding in both children and adults (1% of all hernia cases in adults). In contrast, the inguinal hernia is a common congenital anomaly, with an incidence ranging from 0.8% to 5% in full term, up to 30% in premature and low birthweight newborns. Newborns have a 3%–16% risk of incarceration, which rises up to 31% in preterm infants.¹

Amyand hernia with appendicitis is a sporadic event (0.1%), and it is possibly due to the incarceration of the appendix into the herniary sac.^{2–4} Although rare, it should be considered in newborns with incarcerated hernia since early perforation and peritonitis are quite frequent in neonatal appendicitis. Therefore, a delayed diagnosis can be life threatening.⁵

Acknowledgements The authors would like to thank Martina Bradaschia, MD, for the English revision of the manuscript.



Contributors GE, DRI and RI prepared the manuscript, with comments and review from all authors. GF, MFM, SJ, RFM and BE provided critical review of the manuscript. All authors approved the draft.

Funding The authors have not declared a specific grant for this research from any funding agency in the public, commercial or not-for-profit sectors.

Competing interests None declared.

Patient consent for publication Parental/guardian consent obtained.

Ethics approval Approved by hospital ethics committee.

Provenance and peer review Not commissioned; externally peer reviewed.

Data availability statement All data relevant to the study are included in the article or uploaded as supplementary information. All clinical data are included in the manuscript.

Open access This is an open access article distributed in accordance with the Creative Commons Attribution Non Commercial (CC BY-NC 4.0) license, which

permits others to distribute, remix, adapt, build upon this work non-commercially, and license their derivative works on different terms, provided the original work is properly cited, appropriate credit is given, any changes made indicated, and the use is non-commercial. See: <http://creativecommons.org/licenses/by-nc/4.0/>.

REFERENCES

- 1 Marzuillo P, Germani C, Krauss BS, *et al*. Appendicitis in children less than five years old: a challenge for the general practitioner. *World J Clin Pediatr* 2015;4:19–24.
- 2 Erginel B, Soysal FG, Celik A, *et al*. Neonatal perforated appendicitis in incarcerated inguinal hernia in the differential diagnosis of testis torsion. *Pediatr Int* 2017;59:831–2.
- 3 Yodoshi T, Hurt TL. Gas in the right hemiscrotum? Amyand's hernia in a neonate. *BMJ Case Rep* 2018;2018:1–2.
- 4 Guida E, Pederiva F, Codrich D, *et al*. Vermiform appendix inside the sac: uncommon case of inguinal hernia. *Indian J Pediatr* 2014;81:523.
- 5 Abdulhai SA, Glenn IC, Ponsky TA. Incarcerated pediatric hernias. *Surg Clin North Am* 2017;97:129–45.