

CLINICAL REPORT

Primary Subcutaneous B-cell Lymphoma: Case Report and Literature Review

Mauro ALAIBAC¹, Matteo BORDIGNON¹, Natale PENNELLI², Savina AVERSA³, Cleto VELLER FORNASEA¹ and Vanna CHIARION³

¹Unit of Dermatology, ²Unit of Pathology, and ³Unit of Oncology, University of Padua, Padua, Italy

Primary cutaneous B-cell lymphomas are defined as malignant B-cell proliferations presenting with cutaneous involvement alone and no evidence of extracutaneous manifestations when complete staging has been performed. It has been shown that the infiltrate in some cases could involve the underlying subcutaneous tissues, but primary localization in this compartment has been rarely reported. We describe here the case of a 53-year-old woman who noticed a nodular lesion on the left shoulder that rapidly enlarged in a few months. The histological and immunophenotypical features were compatible with a subcutaneous B-cell lymphoma. The tumoural mass was confined predominantly to the subcutaneous compartment, as confirmed by computed tomography. No other tumour localizations were found. Thus, primary B-cell lymphoma of the subcutis was diagnosed. We report a review of the literature indicating that B-cell lymphomas that are primarily localized to the subcutaneous tissue represent a very rare modality of presentation with a biological behaviour different from conventional cutaneous B-cell lymphoma. Key words: cutaneous lymphoma; B-cell; skin cancer.

(Accepted August 20, 2007.)

Acta Derm Venereol 2008; 88: 151–154.

Mauro Alaibac, MD, PhD, Unit of Dermatology, University of Padua, Via Cesare Battisti 206, IT-35128 Padua, Italy. E-mail: mauro.alaibac@unipd.it

B-cell lymphomas comprise approximately 25% of all cutaneous lymphomas (1). In contrast to T-cell lymphomas, they show a relatively homogeneous clinical course (1). Primary cutaneous B-cell lymphomas (CBCL) are defined as malignant B-cell proliferations presenting with cutaneous involvement alone and no evidence of extracutaneous manifestations when complete staging has been performed (2). The European Organization for Research and Treatment of Cancer (EORTC)–Cutaneous Lymphoma Project Group and the World Health Organization (WHO) recently proposed a new classification for primary cutaneous lymphomas (3). The subtypes of CBCL included in this classification are the following: cutaneous follicle-centre lymphoma, cutaneous marginal zone B-cell lymphoma, diffuse large B-cell lymphoma leg

type and cutaneous diffuse large B-cell lymphomas that do not belong to the other subtypes. In this last category, the following B-cell lymphomas are included: anaplastic or plasmablastic subtypes, T-cell/histiocyte rich large B-cell lymphoma, cutaneous intravascular large B-cell lymphoma.

Clinically, a solitary tumoural nodule is usually present, but multiple tumours can be observed and, normally, there are no extracutaneous manifestations for either cutaneous follicle-centre lymphomas or cutaneous marginal zone B-cell lymphomas (4). Consequently, mortality rates tend to be low (5). In contrast, cutaneous diffuse large B-cell lymphomas are characterized by an aggressive clinical course and a higher mortality rate (5). In CBCL the infiltrate can involve the underlying subcutaneous tissues, but its primary localization in this compartment has rarely been reported (6–8).

In this article, we describe a case of primary subcutaneous B-cell lymphoma and present a brief review of the literature.

CASE REPORT

In May 2004, a 53-year-old woman noticed a nodular lesion on the left shoulder that rapidly enlarged in a few months. The first biopsy performed in another unit was consistent with the diagnosis of “mild superficial perivascular phlogosis”. The patient was referred to us in February 2005 due to rapid enlargement of the lesion. Physical examination revealed a large bluish-reddish plaque, which covered almost all the cutaneous surface of the left shoulder and presented wide necrotic and bleeding ulcerations (Fig. 1). A second, deeper cutaneous biopsy was performed, which revealed the presence of a non-Hodgkin’s lymphoma. Neoplastic cells were confined in the subcutaneous compartment and there was no invasion of the dermis. Only few islands of neoplastic cells were observed in the deeper portion of the dermal compartment. These cells showed a centrocytic-like morphology (Fig. 2). Immunohistochemistry performed on both paraffin and frozen tissue showed the following main phenotypical characteristics: CD19 (+), CD20 (+) (Fig. 3), BCL2 (–), BCL6 (weak positivity) (Fig. 4), CD5 (+), CD43 (+), CD3 (–), Epstein-Barr-virus-latent membrane protein (–),

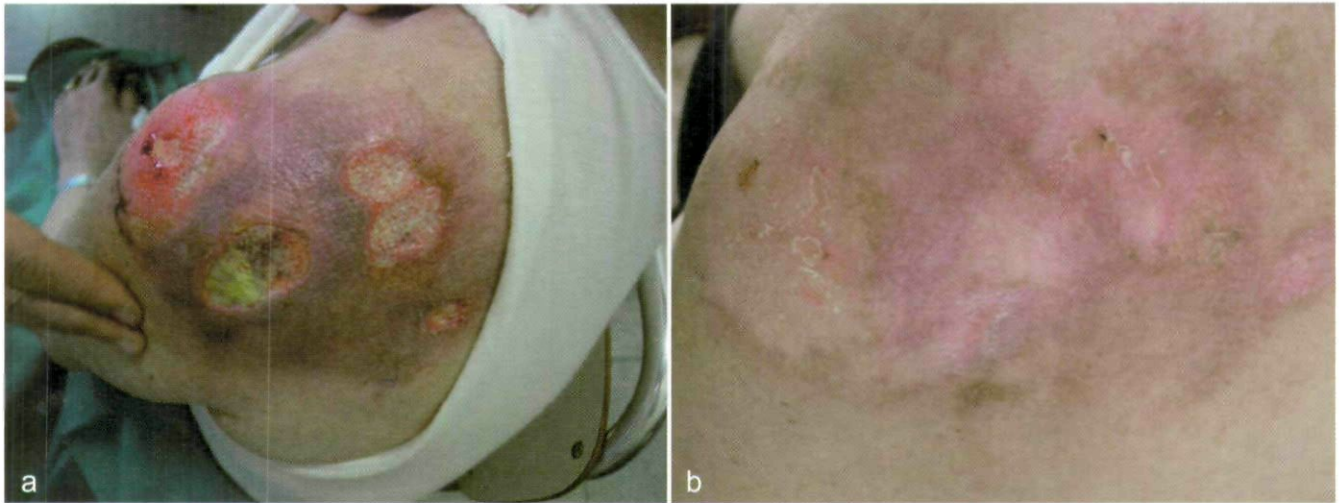

Fig. 1. Clinical presentation of the patient with a large ulcerated tumour on the left shoulder (a) at admission and (b) after chemotherapy.

cyclin D1 (+). Subsequently, the patient was properly staged and no other tumour localizations were found. In particular, a bone marrow biopsy was negative and white cell differential count and immunophenotyping of blood and bone marrow excluded a B-cell chronic lymphocytic leukaemia. Molecular investigations for clonal Ig gene rearrangements did not provide reproducible results. A total body computed tomographic (CT) scans excluded localization in other sites. CT scans of the shoulder showed that the tumoural mass was confined to the subcutaneous tissue and reached the underlying bone structures with osseous defects localized on left acromion and left scapula (Fig. 5). On the basis of the clinical, histological, immunophenotypical and radiological data, primary subcutaneous B-cell lymphoma was diagnosed. The clinical and immunohistological features did not allow the classification of this case according to the WHO-EORTC classification for cutaneous lymphomas. The patient underwent 8 courses of CHOP-rituximab (CHOP: cyclophosphamide, do-

xorubicin, vincristine, prednisone) chemotherapy and complete remission was achieved (Fig. 1b). Adjuvant radiotherapy was also performed in correspondence of the affected area. After 15 months of follow-up, the patient is still without any evidence of disease.

DISCUSSION

CBCL are a well-defined group among cutaneous lymphoproliferative disorders. Primary localized tumours generally involve the skin, whereas concurrent and secondary tumours, as well as relapses of primary cases, tend to involve the subcutis (2). The primary localization in the subcutaneous tissues has been rarely described and, to the best of our knowledge, so far just 3 primary subcutaneous B-cell lymphoma have been reported (Table I). The first case was presented by Kazakov et al. (6), who reported a primary subcutaneous follicular centre cell lymphoma with involvement of the galea aponeurotica. The second case was presented by

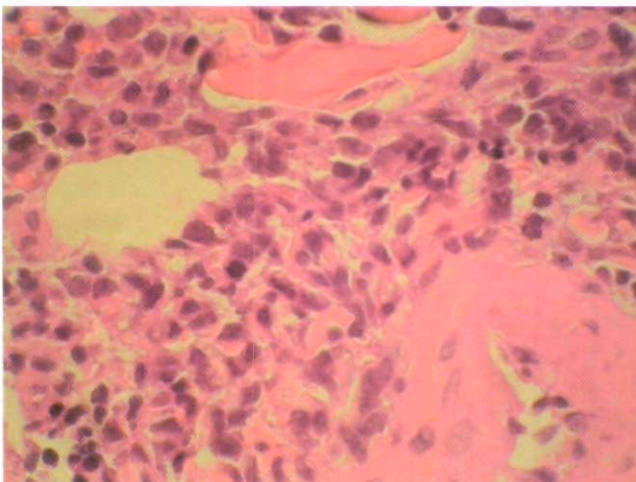


Fig. 2. Histological examination showing the centrocytic-like morphology.

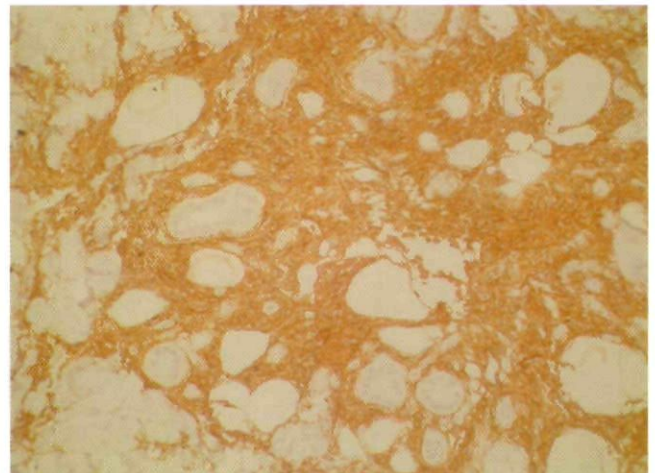


Fig. 3. CD20-positive cells infiltrating the adipose tissue.

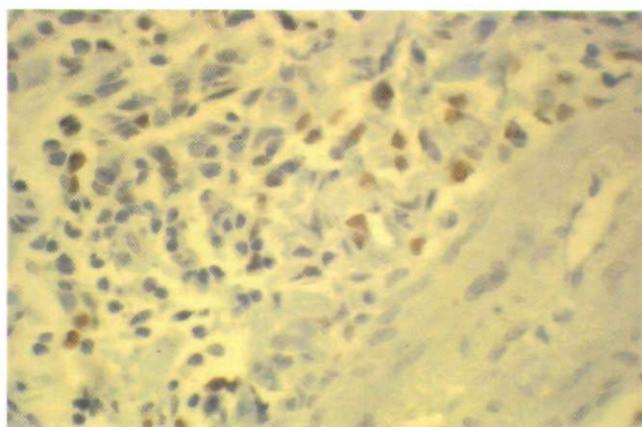


Fig. 4. BCL-6 positive cells.

Hisatake et al. (7), who described a multiple primary subcutaneous mantle-cell lymphoma of the face and trunk. The third case was presented by Takahashi et al. (8), who reported a multiple primary subcutaneous CD5-positive large B-cell lymphoma of the trunk and buttocks. Here we describe a new case of primary subcutaneous B-cell lymphoma localized at the left shoulder. The histological and immunophenotypical features did not allow us to classify the lymphoma according to the WHO-EORTC classification for cutaneous lymphomas.

Although there are differences in single/multiple presentation and in clinical characteristics, between our case and the other reported cases, common features could be detected: localization in the subcutaneous tissue; absence of other localizations or systemic involvement; sparing of dermis and epidermis; and rapid growth. The cases have been treated by surgical removal combined with radiotherapy or with solely chemotherapy, with complete remission and no reported disease recurrence.

The clinical course is particularly noteworthy, because the cutaneous correspondents of the presented cases have a different clinical behaviour. Whereas radiotherapy or surgical excision are normally satisfactory therapies for conventional CBCL, they have been successfully performed in just one case of subcutaneous B-cell lymphoma (6). In our case and in the other 2

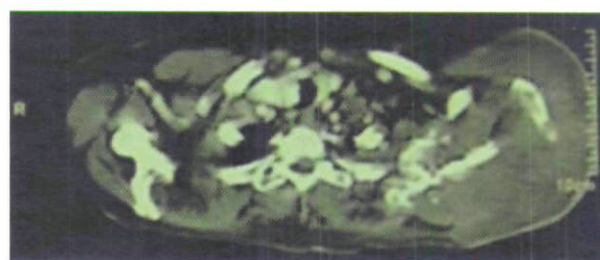


Fig. 5. Computed tomographic scan showing the subcutaneous mass in correspondence of the shoulder involving the underlying bone structures with osseous destruction.

cases, chemotherapy was necessary to achieve complete remission (7, 8).

Subcutaneous B-cell lymphomas seem to have a characteristic rapid growth, although complete remission was achieved in all cases. This is in contrast with the clinical behaviour of conventional primitive CBCL. These forms are characterized by plaques and nodules with a very slow growth pattern and limited local aggressiveness. They tend to have a very good prognosis and treatment is generally successful also with skin directed therapy. Subcutaneous B-cell lymphomas are characterized by rapid growth of the lesion, which can cause damage to the dermal and epidermal compartment with wide necrosis of the cutaneous surface, as in the reported case. This feature is normally absent in conventional CBCL and could be responsible for pain and infective complications. The differential diagnosis between a primary subcutaneous B-cell lymphoma and a secondary subcutaneous involvement of a nodal B-cell lymphoma is only possible by means of the data obtained by the staging procedures. Because of the rarity of subcutaneous B-cell lymphomas there are no specific histological, immunophenotypical and/or molecular features that may help to distinguish this form from conventional CBCL and secondary localization of nodal B-cell lymphoma.

In conclusion, the existence of subcutaneous B-cell lymphoma should prompt physicians to perform a deeper biopsy involving the subcutaneous tissue, if the results of a first biopsy disagree with the clinical features

Table I. Summary of the reported primary subcutaneous B-cell lymphomas, including our case

Case	Age (years)/sex	Localization	Histological diagnosis	Therapy and outcome
Kazakov et al. (6)	54/F	Galea aponeurotica	Primary subcutaneous follicular centre cell lymphoma	Surgical removal + radiotherapy Complete remission at 7 years follow-up
Hisatake et al. (7)	73/M	Face and trunk	Primary subcutaneous mantle cell lymphoma	THP-COP Complete remission at 17 months follow-up
Takahashi et al. (8)	74/F	Trunk and buttocks	Primary subcutaneous CD5+ diffuse large B-cell lymphoma	Modified CHOP Complete remission at 8 months follow-up
Present case	53/F	Left shoulder	Primary subcutaneous B-cell lymphoma	CHOP-rituximab + local radiotherapy Complete remission at 15 months follow-up

CHOP: cyclophosphamide, doxorubicin, vincristine, prednisone; THP-COP: pirarubicin, cyclophosphamide, vincristine (Oncovin), prednisone.

of the lesions. Early detection of this lymphoma is necessary to tackle the rapid local course of the disease.

REFERENCES

1. Willemze R, Jaffe ES, Burg G, Cerroni L, Berti E, Swerdlow SH, et al. WHO-EORTC classification for cutaneous lymphomas. *Blood* 2005; 105: 3768–3785.
2. Bogle MA, Riddle CC, Triana EM, Jones D, Duvic M. Primary cutaneous B-cell lymphoma. *J Am Acad Dermatol* 2005; 53: 479–484.
3. Slater DN. The new World Health Organization-European Organization for Research and Treatment of Cancer classification for cutaneous lymphomas: a practical marriage of two giants. *Br J Dermatol* 2005; 153: 874–1380.
4. Demierre MF, Kerl H, Willemze R. Primary cutaneous B-cell lymphomas: a practical approach. *Hematol Oncol Clin North Am* 2003; 17: 1333–1350.
5. Zinzani PL, Quaglino P, Pimpinelli N, Berti E, Baliva G, Rupoli S, et al. Prognostic factors in primary cutaneous B-cell lymphoma: the Italian Study Group for Cutaneous Lymphomas. *J Clin Oncol* 2006; 24: 1376–1382.
6. Kazakov DV, Burg G, Dummer R, Palmedo G, Muller B, Kempf W. Primary subcutaneous follicular centre cell lymphoma with involvement of the galea: a case report and short review of the literature. *Br J Dermatol* 2002; 146: 663–666.
7. Hisatake J, Kawakami K, Nakamaki T, Hino K, Tomoyasu S. Primary subcutaneous mantle cell lymphoma treated successfully with THP-COP therapy. *Rinsho Ketsueki* 2002; 43: 384–388.
8. Takahashi T, Kazama Y, Shimizu H, Yoshimoto M, Tsujisaki M, Imai K. De novo CD5-positive diffuse large B-cell lymphoma solely presenting as multiple subcutaneous nodules. *Acta Haematol* 2002; 107: 230–233.

Copyright of Acta Dermato-Venereologica is the property of Society for Publication of Acta Dermato-Venereologica and its content may not be copied or emailed to multiple sites or posted to a listserv without the copyright holder's express written permission. However, users may print, download, or email articles for individual use.