

Surgical approach and etiopathogenetic considerations to the umbilical tumefactions in cattle: Case review in twenty years (2000/2020)

Filippo Spadola^a, Veronica Cristina Neve^{a,b,*}, Giovanna L. Costa^a, Marcello Musicò^a, Angelo Spadaro^c, Francesco Antoci^b, Orazio Cavallo^d, Giuseppe Cascone^b

^a Department of Veterinary Sciences, University of Messina, Viale Palatucci, 13, Messina 98168, Italy

^b Experimental Zooprophyllactic Institute of Sicily "A. Mirri", Palermo, Italy; Via Gino Marinuzzi, 3, Palermo 90129, Italy

^c Department of Veterinary Prevention, ASP Ragusa Via S. Giovanni Bosco n. 6, Ragusa 97100, Italy

^d Department of Veterinary Prevention, ASP Siracusa; Traversa La Pizzuta, Siracusa 96100, Italy

ARTICLE INFO

Keywords:

Cattle
Abdominal hernias
Omphalocele
Surgery
Abdominal surgery

ABSTRACT

Objective: Our investigation was conducted to evaluate the incidence of umbilical pathologies and the result of related surgical interventions in Sicilian cattle.

Study design: 320 (214 females, 106 males) cattle with umbilical lesions were collected, anesthetized, operated on and follow-up recorded. We evaluated the injury incidence rate.

Population: The animals considered were: high productivity dairy cattle (Holstein Friesian and Brown Swiss); meat breeds (Charolaise and Limousine) and some crosses.

Results: The highest injury rate was simple omphalocele, followed by purulent omphalitis. A high percentage was found in young cattle. Friesians are the most prone to navel diseases. The dairy breeds, compared to the meat breeds, and double aptitude and crosses, were the most affected. The most common was simple omphalocele, with a small hernial port (1 to 3 cm), while the rest was greater than 3 cm, with severe organs or complications.

Methods: the most commonly used surgery was herniorrhaphy with autologous reinforcement, while classic sutures and mesh sutures were used in the remaining cases. Follow-up demonstrated healing in most of the treated subjects.

Conclusions: The study aimed to estimate some surgical clinical cases in Sicilian cattle. Most injuries are lower abdomen injuries, mostly simple or complicated umbilical hernias. Young dairy females were the most affected.

Meaning/Impact: Radical surgery is the treatment of choice in the vast majority of symptomatic or asymptomatic umbilical diseases; moreover, the correct management and the choice of an appropriate surgical approach allow to obtain an effective treatment of the lesions.

Simple summary: In cattle farm, the correct management of births is a fundamental step for the future of the breeding. In fact, there are numerous critical factors in this phase: calving area management, umbilical disinfection, correct administration of colostrum, management of individual pens. Generally, after a few hours from birth, the calf is transferred in individual pens, the walls of this box allow visual and tactile contact but avoid the possibility of mutual sucking of the umbilical region, a risk factor, in that area, of infections and hernias. In the study have been collected umbilical interventions carried out over twenty years by a team operating in south-eastern Sicily: Ragusa. Out of a total of 320 cases, have been reported: the prevalence of types of umbilical tumefactions, anesthetic techniques and surgical techniques performed. The purpose of the work was to highlight any predispositions of race, sex, age regarding the lesion considered and above all, the effectiveness of the surgical therapy.

1. Introduction

In newborn calves, the navel is made up of the urachus and the

remains of the umbilical vessels; usually, after birth, these structures contract until they almost completely disappear. If the area remains open, even slightly, or one of the navel structures becomes infected, the

* Corresponding author.

E-mail address: [vенеve@unime.it](mailto:veneve@unime.it) (V.C. Neve).

<https://doi.org/10.1016/j.vas.2022.100258>

contents can herniate (Baird, 2016; Dennis & Leipold, 1997; Steerforth & Van Winden, 2018).

A hernia is the protrusion of the abdominal contents through an opening of the peritoneal wall. Umbilical hernia is a congenital defect and is the most common lesion among ruminant hernias; it consists in the dislocation of the viscera, or part of them, from the abdominal cavity through a natural opening of the navel (Smith, 2009). Classically, simple umbilical hernias contain the small intestine (enterocele) or simply oment (epiplocele) and are easily reduced with digital pressure (Baird, 2016). The umbilical hernia is commonly secondary to the failure of the normal closure of the umbilical ring: it can also become very massive, although not reducible, with subsequent complications such as incarceration or strangulation (sometimes with the presence of adhesions, edema or necrosis) conditions, these, life-threatening (Radostits et al., 2007).

Many studies have confirmed that umbilical hernia etiology has a genetic component in dominant or recessive mode (Labik et al., 1977; Herrmann et al., 2001, 2000; Distl et al., 2002). Other factors than genetics, however, can be important. Calves over one-month-old with cord infection, and consequential slowing of umbilical scarring are more prone to the onset of umbilical hernia (Herrmann et al., 2001). Several studies have confirmed, indeed, that there is a relationship between infection and umbilical hernia, this can occur as a local or secondary infection to systemic pathologies. Furthermore, excess traction on an oversized fetus or umbilical cord cutting too close to the abdominal wall are other possible causes (Radostits et al., 2007; Herrmann et al., 2000; Steenholdt & Hernandez, 2004; Mazakazu, 2005; Haile et al., 2017; Sultana et al., 2017).

Several studies have shown that umbilical hernias are the most common congenital pathologies in Holstein Friesian calves, between 4% and 15% (Herrmann et al., 2000; Steenholdt & Hernandez, 2004; Haile et al., 2017; Rings, 1995; Virtala et al., 1996). Other authors report that umbilical pathology, and in particular omphalocele, are a very common event in calves aged no more than a week (Virtala et al., 1996). In several retrospective carried out on cattle of different ages, sexes, breeds and housing, an increased frequency of umbilical hernia was seen in calves younger than three months and rarely more than five months (Radostits et al., 2007; Haile et al., 2017; Sultana et al., 2017; Jettennavar et al., 2010; Salim et al., 2015). Regarding sex, the literature disagrees with those who state a higher prevalence in females (Mazakazu, 2005; Virtala et al., 1996; Sutradhar et al., 2009), others that indicate it in males (Sultana et al., 2017; Salim et al., 2015) and those who do not believe that there are differences substantial between the two sexes (Steenholdt & Hernandez, 2004; Haile et al., 2017; Rings, 1995).

Regarding breeding system, some authors have shown a higher prevalence among intensively reared animals than in other management systems (Haile et al., 2017; Salim et al., 2015). This difference may be due to contamination through the deeper layers of the litter; so farrowing on clean pastures is safer than on litter (Baird, 2016). In some studies, it has been stated that twins have a higher incidence of umbilical hernia (Rieck & Finger, 1973), in other the opposite (Herrmann et al., 2000). Premature birth also appears to influence the presence of umbilical hernias. A general test of offspring for congenital defects in calves would be desirable (Rieck & Finger, 1973; Kassem et al., 2014).

Omphalitis, which can also be concomitant with a hernia, are to be considered infections of the umbilical components and sometimes of the vessels and urachus. Usually, the omphalitis occurs in the first month of age, due to the non-closing of the navel. The umbilical area is swollen, hot and painful on palpation, such inflammation often evolves with the production of pus. Sometimes, some intra-abdominal structures may be involved and the infection can progress to septicemia (Baird, 2016; Dennis & Leipold, 1997; Steerforth & Van Winden, 2018; Madigan, 2009). The omphalitis contributes significantly to neonatal morbidity in cattle (Steerforth & Van Winden, 2018; Miessa et al., 2003).

The aims of our study include a general evaluation of umbilical

tumefaction in Sicilian cattle's farms, highlighting the prevalence of omphalocele, identifying any predispositions based on breed, sex and age, and simultaneously investigating the effectiveness of the surgical treatment used in individual cases.

2. Materials and methods

This study was conducted retrospectively on 320 cattle surgically operated for a swelling in the umbilical region in the two decades 2000 – 2020 in Sicily and in particular in the Ragusa area.

The animals considered were: high productivity dairy cattle (Holstein Friesian and Brown Swiss); meat breeds (Charolaise and Limousines) and some crosses. All the animals were housed in intensive and semi-extensive farms; on clinical examination they presented umbilical swelling (Figs. 1 and 2). Cattle affected by diseases not strictly related to the navel and all other paratopias of the abdominal wall were excluded from this study.

2.1. Clinical examination

The subjects were placed in pre-operative fasting of 24/48 hours, with watering suspended from the evening before. Before the surgery, the medical history was collected and a general objective examination was carried out; all the animals have undergone a thorough pre-anesthesiological examination and the particular physical examination of lesion involved an accurate palpation of the umbilical swelling. Palpation, performed in dorsal decubitus, favored the reducibility of the lesions, when possible, also allowing to obtain deeper palpations even beyond the hernial portal (Baird, 2016; Spadola et al., 2017). The lesions revealed, in most cases, a swelling of variable volume, generally round or ovoid and regular in shape, usually not hot and painless. In chronic cases, in which inflammation and sclerosis phenomena cause an alteration of the anatomical relationships of the various structures, it was still possible to palpate the lesion without painful reactions on the part of the animal, but the reducibility was compromised (Baird, 2016; Spadola et al., 2017). In cases complicated by secondary lesions and in omphalitis, in addition to a state of general suffering, the lesion was hot, very painful and intractable. Palpation thus made it possible to classify the lesions as reducible, partially reducible or non-reducible. When reducible or partially reducible, the hernial ring was evaluated to formulate a diagnosis; for non-reducible swellings the diagnosis was directed towards purulent omphalitis, later confirmed by a centesis (Fig. 3) (Baird, 2016; Spadola et al., 2017; Steiner & Lejeune, 2009). Sometimes in some chronicized umbilical abscesses, the walls were so thick, frequently chambered, and the pus is so dense that centesis did not provide significant data (Spadola et al., 2017).

2.2. Anesthetic protocol and intraoperative monitoring

Each patient received a dose of Romifidine hydrochloride (Sedivet 1%, Boehringer, Ingelheim am Rhein, Germany) at 0.08 mg / kg IM, or Xylazine (Rompun2%, Bayer, Leverkusen, Germany), at 0.3 mg / kg. kg IM; Lidocaine (Lidocaine 2%, Esteve, Girona, Spain) for infiltration 10-15 ml per layer and Tramadol (Altadol or Contramal, 5% Formenti, Savona, Italy), at 1 mg / kg. Respiratory rate (thoracic excursions in one minute), heart rate and non-invasive systolic pressure were assessed and recorded both before and during surgery (Multiparametric monitor. AMI Italia srl, Leonardo model, Milan, Italy). These parameters were also taken into consideration for the assessment of intraoperative analgesia: in agreement with Anderson and Edmondson (2013) and Costa et al. (2021) changes in the above parameters greater than 20%, compared to the values recorded after sedation, were addressed with the administration of Flunixin Meglumine (Finadyne.- Schering- Aratro, Oss, Il Netherlands), 50 mg / ml 3.3 mg / kg IV (Costa et al., 2019, 2021; Anderson & Edmondson, 2013).

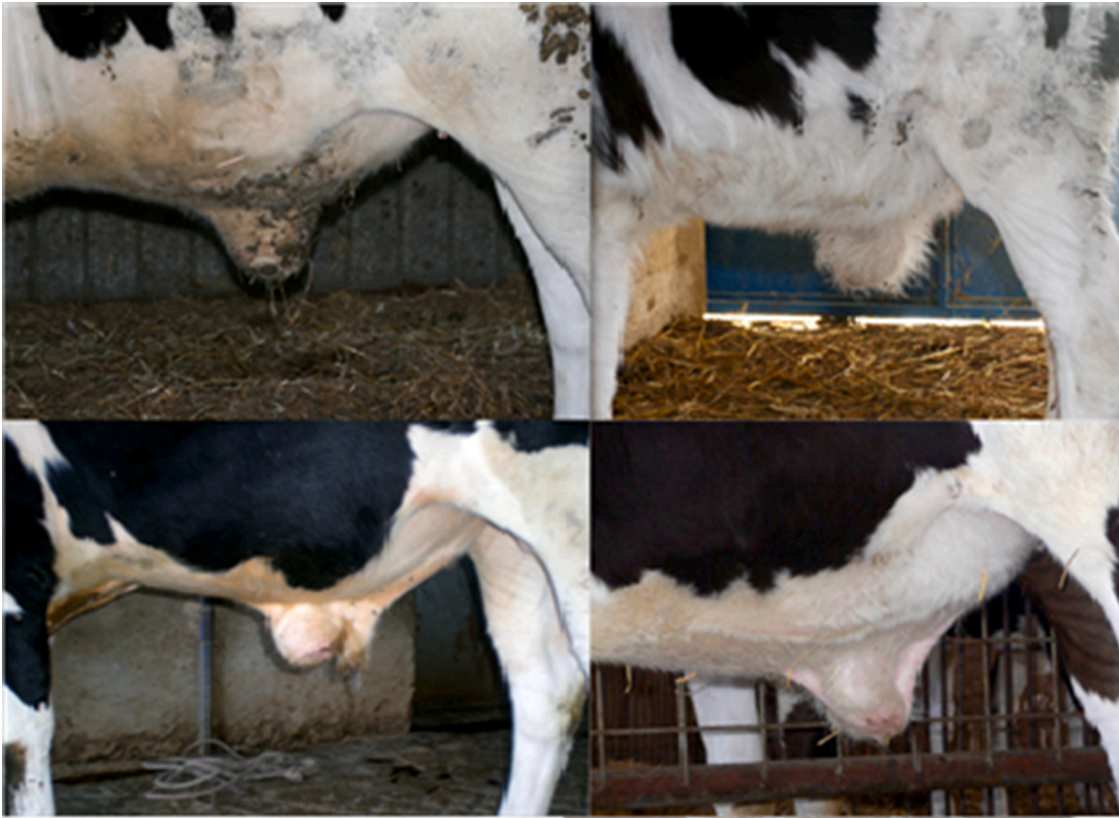

Fig. 1. Young Friesian calves with simple umbilical hernia.



Fig. 2. Calves of beef breeds with umbilical hernia.

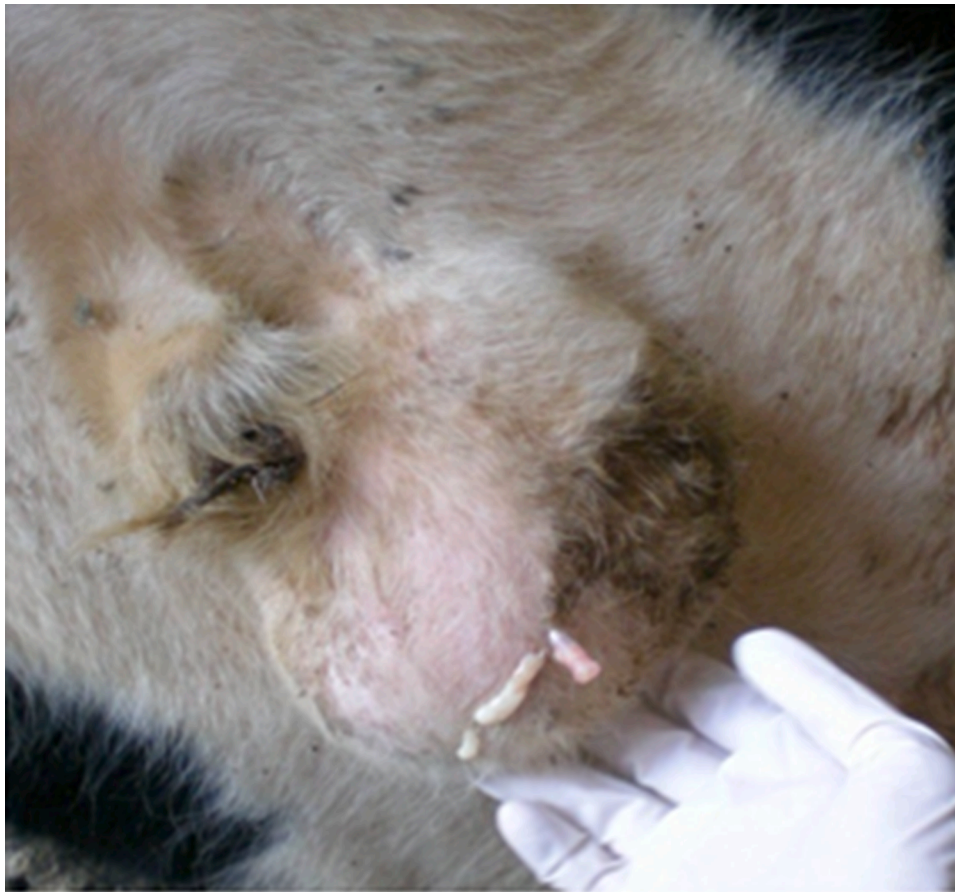

Fig. 3. Puncture of purulent omphalitis in a young Friesian male.

2.3. Surgical approach

The surgical preparation of the operating field was performed according to surgical technique, with the animal placed in the dorsal recumbence. Upon reaching the dorsal decubitus, after having cannulated the jugular vein; for the entire duration of the operation, the intravenous access was kept open via drip (NaCl 0.9) (Spadola et al., 2017; Costa et al., 2019, 2015; Interlandi et al., 2017). The surgery began, in all cases, with a further assessment of the size, the skin covering and the relationship with the adjacent structures. The skin was then incised in a half-moon shape; the surgery continued with the insulation of the herniary sac, with the aid of scissors or bluntly, with fingers. The hernial sac was cut, thus highlighting the hernial door and its contents. The dislocated organs were detached from the fibrinous adhesions which, although in variable extent, were almost always present and, therefore, appropriately repositioned through the hernial door.

After cruceading the margins, the traditional herniorrhaphia was performed, with detached knotty points, in vicryl 0 or 1 or 2, depending on the size of the animal (Baird, 2016; Salim et al., 2015). In some cases, the hernial sac was incised and shaped to form a real autologous vascular flap (Fig. 4).

The subcutaneous layer was also sutured with "X or 8" shaped stitches, while the skin was sutured with knotty detached points. Other cases were treated with the apposition, on the suture of the hernia, of a heterologous prosthesis consisting of a vicryl mesh, used as reinforcement (Fig. 5) (Kassem et al., 2014; Giusto et al., 2016; Williams et al., 2014).

At this stage, the proper muscles and the neurovascular bundles of the regions have been highlighted and respected. The dislocated organs were disconnected from the phybrinose adhesions which were almost always present and, therefore, properly repositioned through the hernial

door.

As far as the purulent omphalitis, after having carried out the differential diagnosis by means of centesis, we proceeded with drainage or, when possible, by removing the lesion with all the surrounding capsule, according to the surgical indications. In complicated cases, with omphalocele and purulent omphalitis, the first step was taking care of the omphalitis and then performing surgery on the hernias. The autologous flap was then used, by apposition and fixation, to reinforce the suture, with detached knotty stitches, also in vicryl. Some cases were treated with the classic technique of herniorrhaphy (without apposition of autologous flap) with continuous suture. The choice of the surgical technique to be performed was based on the characteristics of the lesion, and mainly on its severity, proceeding with the affixing autologous or heterologous reinforcements in all cases of complicated hernias or with large hernia door. All the surgeries ended with the suture of the overlying layers (muscles and skin). The animals were all subjected to general antibiotic therapy with broad-spectrum drugs and wound disinfection twice daily.

3. Results

The series considered includes a total of 320 animals, which underwent surgical treatment of the umbilical region. The results obtained show that 55 subjects were affected by purulent omphalitis (17.19%), while 265 subjects (82.81%) were affected by umbilical hernias; in particular, as regards animals who presented umbilical hernias, 208 had simple omphalocele (65%), 45 had omphalocele with bowels (14.06%), 8 omphalocele complicated by omphalitis (2.5%), 2 omphalocele complicated (0.63%) and 2 omphalocele with laparocele (0.63%) (Graphic 1).

The caseload has shown an higher number of female subjects,

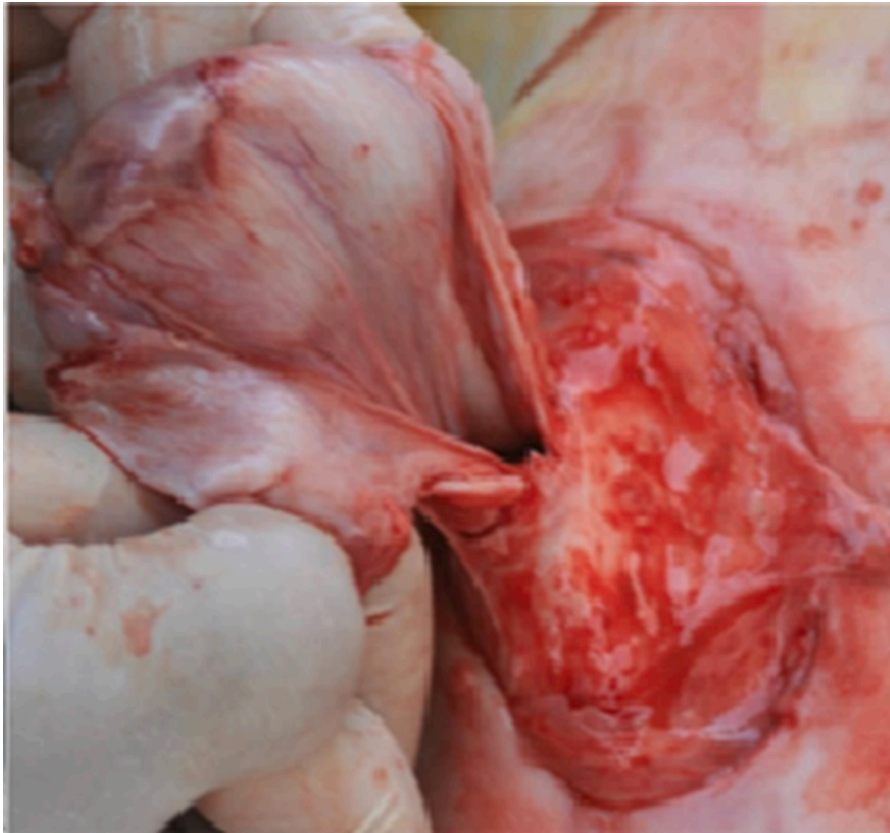


Fig. 4. Isolation of the hernial sac and preparation of the autologous prosthesis.

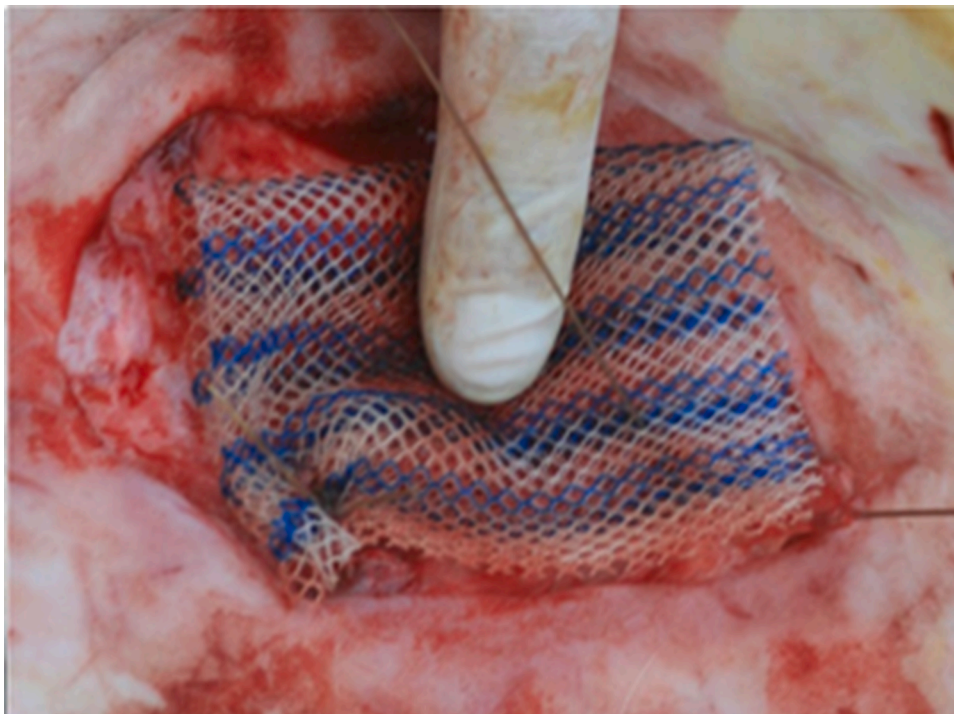
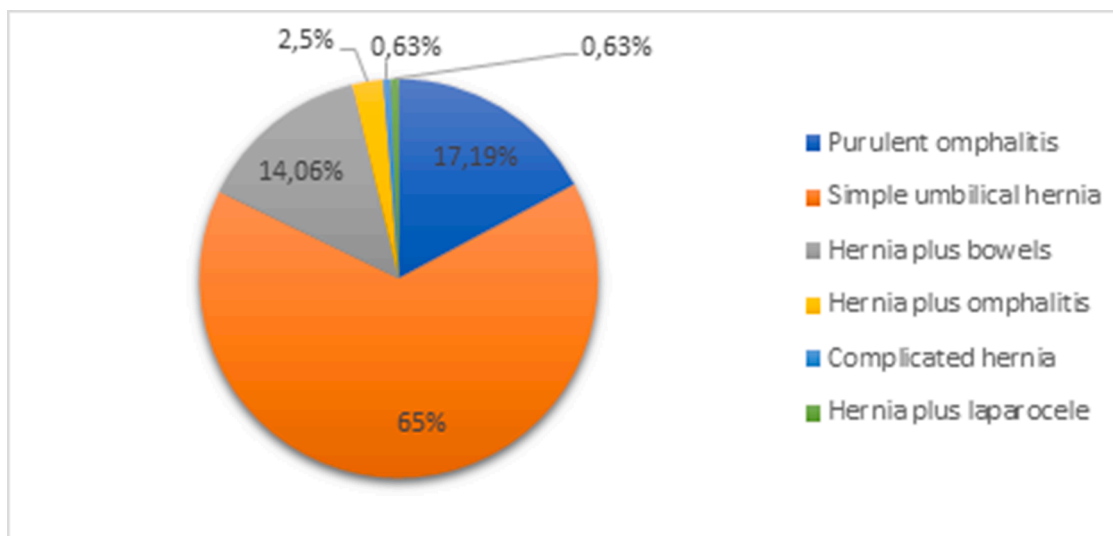


Fig. 5. Apposition and suturing of the vicryl mesh heterologous prosthesis.

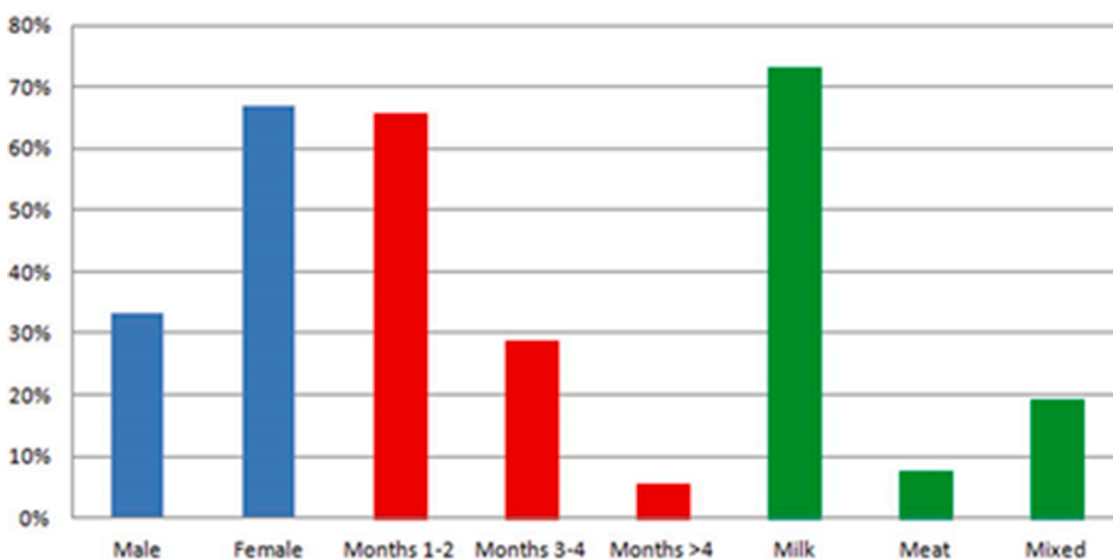
66.88%, compared to males, 33.12%. Concerning age, a very high percentage was found in young cattle in the first months of life, 65.62%. Concerning aptitude, a greater predisposition is shown in dairy breeds 73,12% (Friesian Holstein and Brown Swiss), followed by breeds with

dual aptitude 19,37% (cross and other) and finally by meat breeds 7,5% (Charolaise and Limousine) (Graphics 2 and 3).

For breeds, Friesian is the most prone to navel diseases with a percentage of 69.37% and 222 clinical cases treated (Graphic 3). The cases



Graphic 1. The percentage graph of lesion types.



Graphic 2. Percentage graph of lesion types by sex, age/weight, and aptitude.

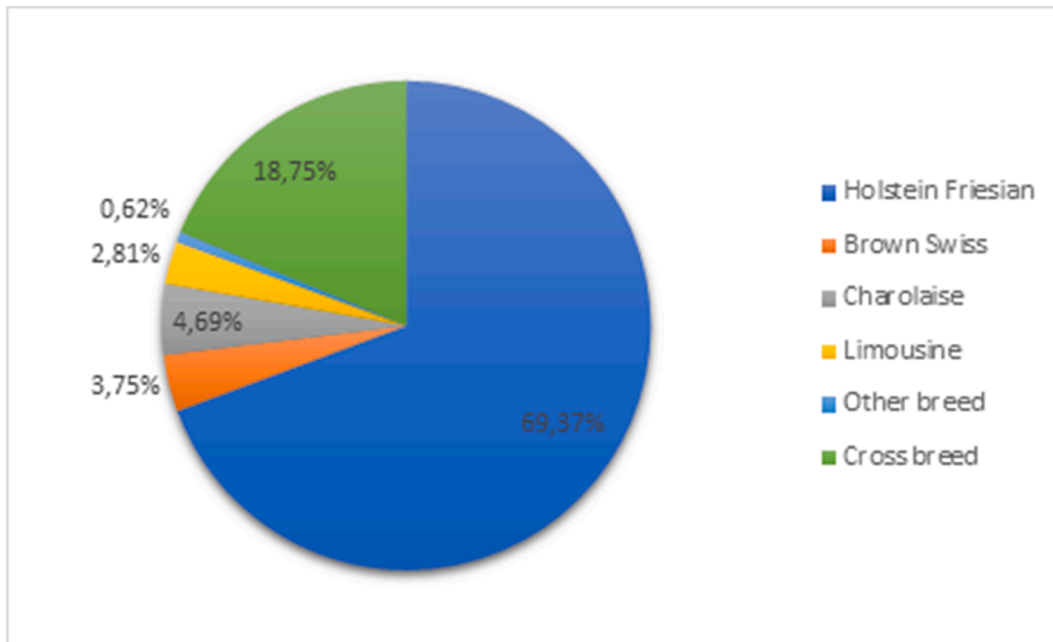
we treated surgically were affected either by simple omphalocele, or complicated, or with the presence of abdominal organs. As depicted in Graphic 4: 66.04% of the subjects had a very small hernial port, equal to 1-3 cm, while the rest, 33.96%, had hernial rings with a diameter of more than 3 cm and 14.68% with the presence of organs or more severe complications such as throttling. The surgical procedures used were mainly addressed to a herniorrhaphia with autologous reinforcement (76.6%). The follow-up demonstrated excellent effectiveness of techniques used with healing in 95.47% of treated subjects. In a single female subject, weighing more than 250 kg, with omphalocele containing bowels and omphalitis, the dehiscence of the suture occurred and the animal, as recommended in the literature, underwent further surgery (Bouckaert & Demoor, 1965; Trent, 2022).

4. Discussion

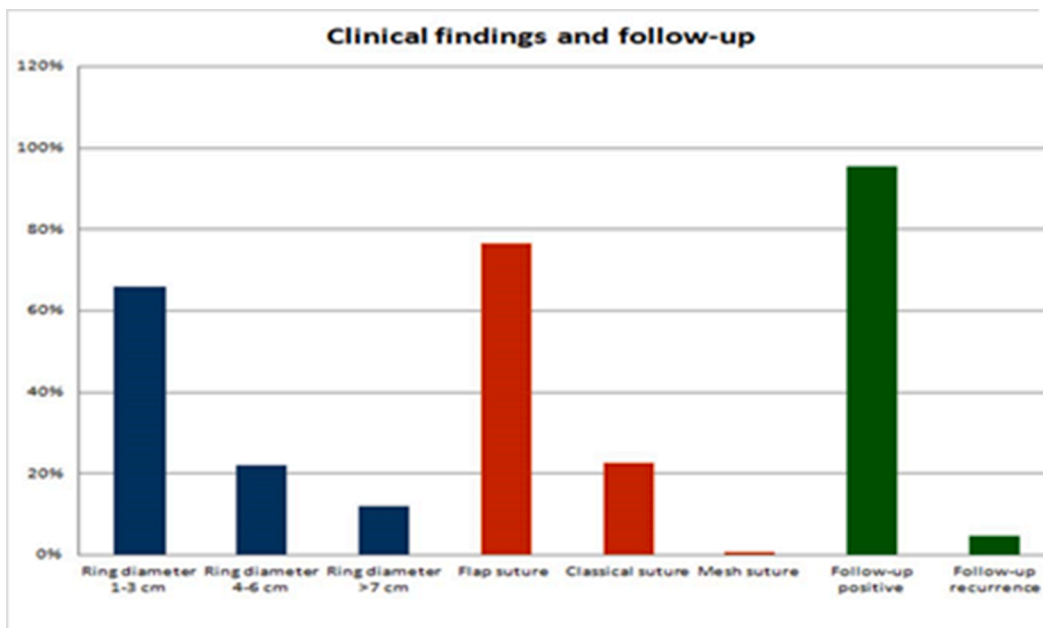
As reported by several Authors, also this study confirms a higher prevalence of Friesian breed in umbilical pathology (Herrmann et al., 2000; Steenholdt & Hernandez, 2004; Rings, 1995; Virtala et al., 1996; Haile et al., 2017). It was associated this pattern to two factors: the first,

to the number of Friesian cattle present in the geographical area considered (Ragusa), compared to other species and the type of intensive breeding (Graphics 2 and 3) (Salim et al., 2015; Haile et al., 2017), the second, to genetic selection of the breed that probably leads to genetics tare such as hernias (Labik et al., 1977; Herrmann et al., 2001, 2000; Distl et al., 2002). It is necessary to remember that the affected animals should be excluded from the reproduction, as this lesion is a communicable hereditary factor, although this is not put into practice in most cases (Labik et al., 1977; Herrmann et al., 2001, 2000; Distl et al., 2002). In surgical therapy of the hernia, it is necessary to consider some aspects of paramount importance. The first is undoubtedly the timelines of the intervention, that allows to greatly reducing the state of distress of the animal and the exacerbation of the same injury. During the differential diagnosis, it should be necessary to identify the organs present in the tumefaction, any collections of exudation and relationships with the abdominal cavity; in some cases, the ultrasound examination could be of great help (Steiner & Lejeune, 2009).

According to this experience, according to other Authors, umbilical surgery can be performed successfully with local anesthesia and sedation or general anesthesia. The method chosen depends on the



Graphic 3. Percentage graph of lesion types by breed of cattle.



Graphic 4. The percentage graph of the types of lesions by type of clinical findings, type of surgery performed and follow-up.

operator's preference, taking into account the age, weight and temperament of the animal and the expected difficulty. Usually, the umbilical surgical procedures are performed in the field, so general anesthesia is particularly complicated (Baird, 2016; Rings, 1995; Salim et al., 2015; Sutradhar et al., 2009; Spadola et al., 2017; Costa et al., 2019, 2015; Interlandi et al., 2017; Williams et al., 2014).

The application of an autologous prosthesis has derived from a dual consideration: meanwhile, the great stress to which the tissues are subjected, especially in a large animal, require the application of a reinforcement that remains stable at least for the first fortnight in the postoperative period; moreover, the strong and well-vascularized hernial sac provides excellent guarantees of tissue compatibility and, thanks to the constant blood supply, ensures the presence of cellular elements of defense and reaction, with the formation of a tenacious

"adhesive" layer of fibrin. It was, then, natural to think of exploiting these characteristics for the flap to fulfill the functions of a prosthesis but eliminating the unwanted effects of the heterologous material (Spadola et al., 2017). If, however, there is doubt of poor suture sealing, for example in very large animals or if the abdominal walls are altered by the chronicization of the lesion, some authors suggest to apply a mesh of synthetic re-absorbable material, like polypropylene, which is affixed to the suture of the hernial port, in order to reinforce the latter (Rieck & Finger, 1973; Interlandi et al., 2017; Giusto et al., 2016; Williams et al., 2014).

In this regard, since the value of these alloprotheses in the success of the intervention is recognized, although their costs are high, in two of our cases they have been used successfully. Some surgeons suggest to perform herniorrhaphias in a covered way rather than opening the

peritoneal cavity (Jettennavar et al., 2010; Williams et al., 2014). This option is only possible if there are no concomitant omphalitis or complicated hernias. In our opinion, this technique is feasible to correct small simple umbilical hernias that are easily reduced, such as epiplocele. The technique postulates to reduce the hernial sac in the abdominal cavity and the subsequent suture of the ring, after the elliptical incision of the skin. A good reason for using this technique is the potential peritoneal contamination (Williams et al., 2014). It should be highlighted, however, like other authors, instead, suggest the classical surgical technique supporting a superior result (Sutradhar et al., 2009). As far as reoffending is concerned, we have seen that a crucial role is given by postoperative treatment. The subjects suffering indiscriminately from serious or very simple diseases have relapsed when careful postoperative therapy has not been followed and the hygiene of the shelter stables has not been taken care of. With reference to the only case of suture dehiscence, the animal, as recommended in the literature, underwent further surgery (Bouckaert & Demoor, 1965; Potter, 2007); the excellent follow-up result obtained in our study supports the latter theory.

5. Conclusions

This manuscript has confirmed what has already been reported in the literature about the etiopathogenesis of umbilical lesions, highlighting the high predisposition of dairy breeds (Herrmann et al., 2000; Steenholdt & Hernandez, 2004; Rings, 1995; Virtala et al., 1996; Haile et al., 2017), probably attributable to the increasing genetic selection, together with intensive breeding methods (Labik et al., 1977; Herrmann et al., 2001, 2000; Distl et al., 2002; Salim et al., 2015; Haile et al., 2017).

In any case, it is confirmed that the surgical approach for the resolution of this type of paratope remains the most appropriate therapy (Sutradhar et al., 2009; Spadola et al., 2017).

In this regard it is evident how effective and economically valid is our technique of the autologous flap for herniorrhaphy; in fact, the use of such prosthesis facilitates and speeds up the healing process (Spadola et al., 2017; Chavez & Demoor, 2012).

It is necessary, however, to further emphasize how good hygiene, although sometimes difficult to achieve, is essential during childbirth to prevent ascending umbilical cord infections (Baird, 2016). Therefore, constant cooperation between veterinary doctors and breeders would be particularly useful in reducing the predisposing and triggering factors for umbilical diseases, at the same time as good planning of surgical procedures related to the severity of the injury to be treated (Herrmann et al., 2000; Trent, 2022).

Funding and Institutional review board statement

This research did not receive external funding. This study was conducted over 20 years in the context of: the teaching activity of the Veterinary Surgery Clinic Sector - University of Messina - Department of Veterinary Sciences and the epidemiological-diagnostic activity of the Experimental Zooprophyllactic Institute of Sicily.

Ethics information

Ethical review and approval were waived for this study because no type of experimentation has been done on the research subjects. Each clinical case treated in this study is a real clinical case, where individual animals were treated for the purpose be cured and avoid sometimes lethal consequences. Each farmer has signed the informed consent. After the operation, animals returned to their initial conditions of well-being.

CRedit authorship contribution statement

Filippo Spadola: Conceptualization, Methodology, Data curation,

Writing – review & editing. **Veronica Cristina Neve:** Methodology, Writing – review & editing, Project administration. **Giovanna L. Costa:** Software, Formal analysis. **Marcello Musicò:** Writing – original draft. **Angelo Spadaro:** Validation, Investigation. **Francesco Antoci:** Visualization. **Orazio Cavallo:** Resources. **Giuseppe Cascone:** Supervision, Funding acquisition.

Declaration of Competing Interest

The authors declare no conflict of interest.

References

- Anderson, D. E., & Edmondson, M. A. (2013). Prevention and management of surgical pain in cattle. *The Veterinary Clinics of North America: Food Animal Practice*, 29(1), 157–184. <https://doi.org/10.1016/j.cvfa.2012.11.006>
- Baird, A. N. (2016). Surgery of the umbilicus and related structures. *The Veterinary Clinics of North America: Food Animal Practice*, 32(3), 673–685. <https://doi.org/10.1016/j.cvfa.2016.05.008>
- Bouckaert, J. H., & Demoor, A. (1965). Surgical treatment of umbilical infections in calves. *The Veterinary Record*, 3(77), 771–775.
- Chavez, J. H., & Demoor, A. J. (2012). Surgical treatment of umbilical infection in calves. *The Veterinary Record*, 77, 771–774.
- Costa, G. L., Cristarella, S., Quartuccio, M., & Interlandi, C. (2015). Anti-nociceptive and sedative effects of romifidine, tramadol and their combination administered intravenously slowly in ponies. *Veterinary Anaesthesia and Analgesia*, 42(2), 220–225. <https://doi.org/10.1111/vaa.12210>
- Costa, G. L., Nastasi, B., Spadola, F., Leonardi, F., & Interlandi, C. (2019). Effect of levobupivacaine, administered intraperitoneally, on physiological variables and on intrasurgery and postsurgery pain in dogs undergoing ovariohysterectomy. *Journal of Veterinary Behavior*, 30, 33–36. <https://doi.org/10.1016/j.jveb.2018.11.003>
- Costa, G. L., Spadola, F., Lentini, L. E., & Leonardi, F. (2021). Comparison of analgesia and ataxia degree obtained between three dosages of tramadol in cattle. *Large Animal Review*, 27(27), 65–68.
- Dennis, S. M., & Leipold, D. G. (1997). Congenital hernia in calves. *Journal of American Veterinary Medicine*, 152, 999–1003.
- Distl, O., Herrmann, R., Utz, J., Doll, K., & Rosenberger, E. (2002). Inheritance of congenital umbilical hernia in German Fleckvieh. *Journal of Animal Breeding and Genetics*, 119(4), 264–273. <https://doi.org/10.1046/j.1439-0388.2002.00346.x>
- Giusto, G., Bellino, C., Casalone, M., Caramello, V., Comino, F., & Gandini, M. (2016). Mesh repair of a large ventral hernia with interposition of omentum in a calf: a case report. *Veterinárni Medicína*, 61(No. 10), 590–593. <https://doi.org/10.17221/272/2015-VETMED>
- Haile, Y., Velappa, R., & Asrat, M. (2017). A study on the prevalence of umbilical hernia in calves in and around Gondar Town, North Gondar, North West Ethiopia. *International Journal of Veterinary Sciences and Animal Husbandry*, 2(2), 11–15.
- Haile, Y., Velappa, R., & Asrat, M. (2017). A study on the prevalence of umbilical hernia in calves in and around Gondar Town, North Gondar, North West Ethiopia. *International Journal of Veterinary Sciences and Animal Husbandry*, 2(2), 11–15.
- Herrmann, R., Utz, J., Rosenberger, E., Doll, K., & Distl, O. (2001). Risk factors for congenital umbilical hernia in German Fleckvieh. *Veterinary Journal*, 162(3), 233–240. <https://doi.org/10.1053/vjvl.2000.0567>
- Herrmann, R., Utz, J., Rosenberger, E., Wanke, R., Doll, K., & Distl, O. (2000). Investigations on occurrence of congenital umbilical hernia in German Fleckvieh. *Zuchtungskunde*, 72, 258–273.
- Interlandi, C., Nastasi, B., Morici, M., Calabrò, P., & Costa, G. L. (2017). Effects of the combination romifidine/tramadol drug administration on several physiological and behavioral variables in calves. *Large Animal Review*, 23(2), 51–54.
- Jettennavar, P. S., Kalmath, G. P., & Anilkumar, C. J. (2010). Ventral abdominal hernia in cattle. *Veterinary World*, 3(2), 93.
- Kassem, M. M., El-Kammar, M. H., Korittum, A. S., & Abdel-Wahed, A. A. (2014). Using of polypropylene mesh for hernioplasty in calves. *Alexandria Journal of Veterinary Sciences*, 40(1), 112–117.
- Labik, K., Horin, P., Mikulas, L., & Havrankova, J. (1977). Hereditarily conditioned cases of atresia ani, hernia umbilicalis and syndactylia in cattle. *Acta Veterinaria Brno*, 46, 111–133.
- Madigan, J. E. (2009). *Patent urachus, omphalitis, and other umbilical abnormalities* (4th ed.). St Louis Mosby Elsevier Co.
- Mazakazu, S. (2005). Umbilical hernia in Japanese black calves: A new technique and hereditary back ground. *Live Medicine*, 507, 543–547.
- Miessa, L. C., Silva, A. A., & Botteon, R. (2003). Morbidity and mortality by umbilical cord inflammation in dairy calves. *A Hora Veterinária*, 23, 16–18.
- Potter, T. (2007). Clinical: Umbilical masses in calves. *Livestock*, 12(3), 47–51. <https://doi.org/10.1111/j.2044-3870.2007.tb00098.x>
- Radostits, O., Clevin, C. G., Kensch, W., & Hinchcliff, P. O. (2007). *Large and small animal medicine* (10th ed.). Saunders P.
- Rieck, G. W., & Finger, K. H. (1973). Untersuchungen zur teratologischen Populationsstatistik und zur Ätiologie der embryonalen Entwicklungsstörungen beim Rind. *Giefener Beiträge zur Erbpathologie und Zuchtthygiene*, 5, 71–138.
- Rings, D. M. (1995). Umbilical hernias, umbilical abscesses, and urachal fistulas. *The Veterinary Clinics of North America: Food Animal Practice*, 11(1), 137–148. [https://doi.org/10.1016/S0749-0720\(15\)30512-0](https://doi.org/10.1016/S0749-0720(15)30512-0)

- Salim, M. D., Abul Hashim, M., Juyena, N. S., et al. (2015). Prevalence of hernia and evaluation of herniorrhaphy in calves. *International Journal of Natural and Social Sciences*, 2(4), 35–43.
- Smith, B. P. (2009). *Large animal internal medicine* (3rd ed.). Mosby-Elsevier Publishing.
- Spadola, F., Costa, G., Morici, M., Nastasi, B., Interlandi, C., & Musicò, M. (2017). Autologous prosthesis for the surgery of two simultaneous hernias in a calf. *Large Animal Review*, 23(5), 195–197.
- Steenholdt, C., & Hernandez, H. (2004). Risk factors for umbilical hernia in Holstein heifers during the first two months after birth. *Journal of the American Veterinary Medical Association*, 224(224), 431–437.
- Steerforth, D. D., & Van Winden, S. (2018). Development of clinical sign-based scoring system for assessment of omphalitis in neonatal calves. *The Veterinary Record*, 182(19). <https://doi.org/10.1136/vr.104213>, 549–549.
- Steiner, A., & Lejeune, B. (2009). Ultrasonographic assessment of umbilical disorders. *The Veterinary Clinics of North America: Food Animal Practice*, 25(3), 781–794. <https://doi.org/10.1016/j.cvfa.2009.07.012>
- Sultana, S., Ali, M., & Hassan, M. (2017). Prevalence of umbilical hernia of calves and its risk factors at Tangail Sadar of Bangladesh. *Asian-Australasian Journal of Bioscience and Biotechnology*, 2017, 154–158.
- Sutradhar, B. C., Hossain, M. F., Das, B. C., Kim, G., & Hossain, M. A. (2009). Comparison between open and closed methods of herniorrhaphy in calves affected with umbilical hernia. *Journal of Veterinary Science*, 10(4), 343. <https://doi.org/10.4142/jvs.2009.10.4.343>
- Trent, A. M. (2022). Management of umbilical mass in calves. In *Minnesota dairy health conference* (pp. 153–156).
- Virtala, A. M. K., Mechor, G. D., Gröhn, Y. T., & Erb, H. N. (1996). The effect of Calthood diseases on growth of female dairy calves during the first 3 months of life in New York State. *Journal of Dairy Science*, 79(6), 1040–1049. [https://doi.org/10.3168/jds.S0022-0302\(96\)76457-3](https://doi.org/10.3168/jds.S0022-0302(96)76457-3)
- Williams, H. J., Gillespie, A. V., Oultram, J. W., Cripps, P. J., & Holman, A. N. (2014). Outcome of surgical treatment for umbilical swellings in bovine youngstock. *The Veterinary Record*, 174(9). <https://doi.org/10.1136/vr.101736>, 221–221.