

CLINICAL REPORT

Cutaneous Vascular Alterations in Psoriatic Patients Treated with Cyclosporine

Giuseppe STINCO¹, Stefano LAUTIERI¹, Francesca VALENT² and Pasquale PATRONE¹

¹Institute of Dermatology, Department of Clinical and Experimental Pathology and Medicine, University of Udine School of Medicine, and ²Institute of Hygiene and Epidemiology, University Hospital of Udine, Udine, Italy

Videocapillaroscopy can be used to assess cutaneous microcirculation modifications *in vivo*, and therefore allows assessment of variations in the microvascular architecture in psoriatic subjects during treatment. The aim of this study was to observe and quantify the modifications of the superficial capillary bed in psoriatic plaques during treatment with cyclosporin A. Twelve patients with psoriasis vulgaris were treated with an initial dose of 4 mg/kg/day cyclosporin A over a period of 3 months with periodic clinical and capillaroscopic assessments. Clinical resolution of the lesions and a reduction in microcirculatory alterations was observed in 70% of patients, although none returned to a normal capillaroscopic pattern. Key words: capillaroscopy; cyclosporin A; microcirculation; psoriasis.

(Accepted October 20, 2006.)

Acta Derm Venereol 2007; 87: 152–154.

Giuseppe Stinco, Institute of Dermatology, University of Udine, Ospedale "San Michele" di Gemona, piazza Rodolone 1; IT-33013 Gemona del Friuli (Udine), Italy. E-mail: giuseppe.stinco@uniud.it

Cutaneous microcirculation in psoriasis presents considerable alterations compared with healthy skin. The dermal papillae appear oedematous, containing tortuous and dilated capillary loops that lose their normal hairpin direction and twist once or twice, arranged horizontally in a sinuous manner, thereby taking on a glomerular aspect (1). Extravasated erythrocytes are often present. Even the blood flow in the capillaries of the psoriatic plaque is increased compared with the vessels of healthy skin in psoriatic or healthy subjects (2–3). Moreover, various studies have demonstrated that the vascular alterations appear during the initial stages of psoriatic plaque development, even before epidermal hyperplasia is observable histologically (4–5).

The vascular alterations can be observed *in vivo* using a simple method, such as video-capillaroscopy, which uses microcameras connected to a personal computer. The capillaroscopic pattern that can be observed in the psoriatic plaque consists of capillary loops arranged horizontally with an extremely convoluted tendency that assume a basket-weave aspect, whereas in the

healthy perilesional skin a typical mesh-like aspect can be observed (6, 7).

Cyclosporin A (CyA) is a drug that has been used for some time in dermatology to treat psoriasis. The vascular alterations following therapy with CyA have been studied at the periungual fold level in patients who have undergone kidney transplants and have taken the drug for immunosuppressive treatment (8). To our knowledge, there are no studies that verify the behaviour of the papillary capillary loops in the psoriatic plaque following treatment with CyA. Thus, the aim of this study was to observe and quantify modifications in the superficial capillary bed in the psoriatic plaque during treatment with CyA.

MATERIALS AND METHODS

Twelve patients (11 men and 1 woman, age range 23–83 years) with psoriasis vulgaris with Psoriasis Area and Severity Index (PASI) exceeding 24 were recruited. Patients with heart disease or severe liver diseases, kidney disorders, non-controlled arterial hypertension, tumours, systemic infections ongoing and those who were pregnant or breastfeeding were excluded from the study.

None of the patients had been taking other systemic treatments for psoriasis 2 months prior to the beginning of the study. The use of any topical or systemic treatment for psoriasis, including phototherapy, was prohibited during the study. Only treatments already in course for other pre-existing pathologies were allowed and not discontinued. The 12 patients were treated with an initial dose of 4 mg/kg/day of CyA, which was maintained for the first 8 weeks and then reduced by 0.5 mg/kg/day every 4 weeks. At the initial visit (T0) a PASI score was calculated and the plaque object of the study was chosen by selecting precise anatomical points. A clinical image of the corporeal region to be studied was acquired, as was a capillaroscopic image of the centre of the plaque. From each capillaroscopic image of the centre of the plaque the diameter of 3 different "baskets" was measured and the mean was then calculated and taken as the patient's reference value.

The duration of the study was 3 months: the same measurements carried out during the T0 were repeated using the noted reference points on the same site after 4 weeks (T1), 8 weeks (T2) and 12 weeks (T3), accompanied by the clinical images at all times.

Full medical examinations were carried out at each time point, blood pressure was measured and the laboratory parameters were recorded to monitor the CyA treatment adequately.

A digital capillaroscope (Dermascope[®], Medicimedical Srl, Castelfranco Emilia, Modena, Italy) was used for imaging, comprising a central body with a 100 Watt cold halogen lamp

fitted with a manual luminous intensity control device, a probe consisting of a 2 m long flexible cable enclosing an optical fibre bundle, a video signal processing unit, and a connection cable between the video signal processing unit and the optical terminal. In turn, the terminal comprised a colour microcamera and a support to hold the various 300× "contact" type lenses used. Before carrying out the capillaroscopic test, a drop of citron oil was applied to the point where the probe was going to be applied, in order to eliminate any reflections of light and to allow the topmost layers of the epidermis to be seen.

To assess clinical improvement in the plaque, a score between 0 and 9 was given. This was calculated by adding the values from 0 to 3 assigned to the erythema, scaling and infiltration of the plaque in question.

Statistics

The Friedman test was used to assess the variability of the capillaroscopic values between the 3 "baskets" measured. The mean and standard deviation (SD) of the basket reductions were calculated and the Wilcoxon signed rank test was used to check whether reductions in the microcirculatory alterations were statistically significant.

RESULTS

The mean PASI score was 29.66 (24.3–46.2) at the beginning of the study and 1.24 (0–3.3) at T3.

The 12 psoriatic plaques studied were localized on the upper limbs. At the time of recruiting, a psoriatic-type capillaroscopic pattern was observed (Fig. 1a) at the centre of the plaque in all 12 patients, with convoluted "basket"-like capillaries. The capillaroscopic values of the 3 baskets measured at each time were not significantly different (*p*-value of Friedman's test was 0.1738 at the time of recruitment, 0.5580 at T1, and 0.2053 at T3).

At the time of recruiting, the mean diameter of capillaries was 68.8 µm (SD 17.23) and superficial capillary plexus was not observable. The clinical assessment of the plaque expressed a score with mean value of 6.83 (SD 0.71).

At subsequent visits, the 12 patients showed clinical improvement in the plaques studied, with a reduction in erythema, scaling and infiltration, showing a score of 4.58 (SD 0.66) at T1, and of 2.58 (SD 0.51) at T2. When

visualized with the capillaroscope, a glomerular aspect persisted in the centre of the plaque with a reduction in the mean dimensions of the basket T1 38.58 µm (SD 12.11) and T2 29.9 µm (SD 10.73).

At T3, 8 of the 12 patients had healed clinically, whereas the remaining 4 had slight erythema with a mean score of 0.33 (SD 0.49), and in the centre of the plaque a further reduction in the "basket" dimensions was noted (24.16 µm, SD 9.93) without, however, returning to a normal capillaroscopic pattern (Table I, Fig. 1b). The reduction in the dimensions of the capillaries at the centre of the plaque (on average 44.5 µm) was statistically significant (*p*-value of Wilcoxon signed rank test: 0.0005).

DISCUSSION

CyA is a drug that has been shown to be particularly active in treating psoriasis, essentially exploiting 4 mechanisms of action: the capacity to modulate proliferation and differentiation of the keratinocytes, modulation of phlogosis, modulation of cellular-mediated immune response and modulation of angiogenesis (9). All 4 mechanisms may, in some way, be responsible for the effects of CyA on the microcirculation. CyA reduces the keratinocyte metabolic demand by inhibiting the synthesis and release of cytokines that stimulate proliferation and the differentiation of the keratinocytes and normalization of the expression of the α -2 chain of the basal membrane laminin. Therefore, compensatory neo-angiogenetic stimulus of the microcirculation can be assumed. Furthermore, CyA directly modulates neo-angiogenesis by inhibiting the expression of adhesive molecules on the cellular membrane of endotheliocytes (ICAM and VCAM), the synthesis and release of pro-angiogenetic factors and stimulation of the synthesis and release of anti-angiogenetic factors. The angiostatic activity of CyA has been demonstrated in a study by Norrby in 1992 (10) whereby neoangiogenesis provoked by an intraperitoneal saline solution injection in rats treated with 4 mg/kg/day of CyA was inhibited, contrary to what occurred in non-treated rats.

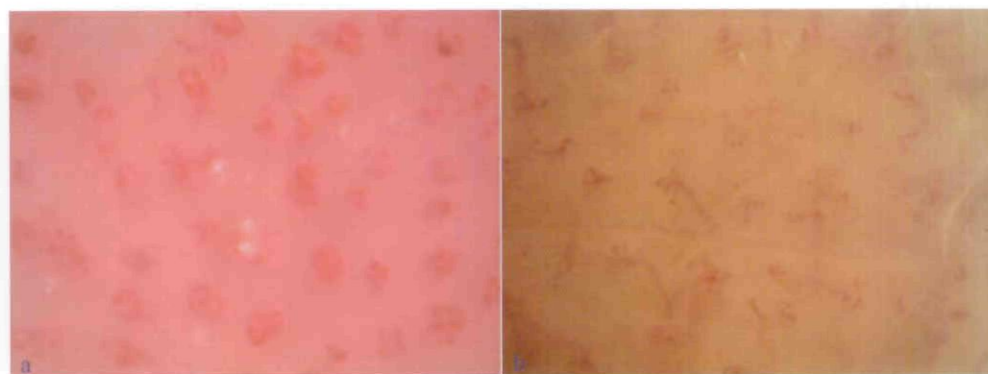


Fig. 1. Capillaroscopic pattern at the centre of a psoriatic plaque, (a) at the beginning and (b) at the end of the study.

Table I. Diameters of the "baskets" and clinical score following treatment with CyA

| Time from start of study | Capillaroscopic evaluation | Clinical evaluation |
|--------------------------|--|---------------------------------|
| | "Basket" diameter (μm) Mean \pm SD | Clinical score Mean \pm SD |
| T0 - baseline | 68.66 \pm 17.63 | 6.83 \pm 0.71 |
| T1 - 4 weeks | 38.58 \pm 12.11 | 4.58 \pm 0.66 |
| T2 - 8 weeks | 29.86 \pm 10.73 | 2.58 \pm 0.51 |
| T3 - 12 weeks | 24.16 \pm 9.93 | 0.33 \pm 0.49 |

In the present study, the activity of CyA on the microcirculation of the psoriatic plaque was demonstrated by an average reduction by 64.8% in the "basket" diameter. Modification of the capillaroscopic aspects took place in a progressive manner in all the patients studied in relation to the duration of the treatment (Fig. 2). Initially, the reduction in the "basket" diameter took place more rapidly compared with the clinical improvement, but after 3 months from starting treatment with CyA, while the psoriatic plaques had clinically disappeared in 8 patients, the capillaroscopic pattern had not normalized in any of the cases. This observation indicates that the cutaneous microcirculation remains altered for a longer period. It is likely that, since the vascular alterations precede epidermal hyperplasia (4-5), even when the lesions are resolved, the microcirculation is slower to return to its original aspect. This datum could depend on a marked sensitivity of the endothelial cells to inflammatory mediators that are able to maintain the angiogenetic stimulus, which could still be present due

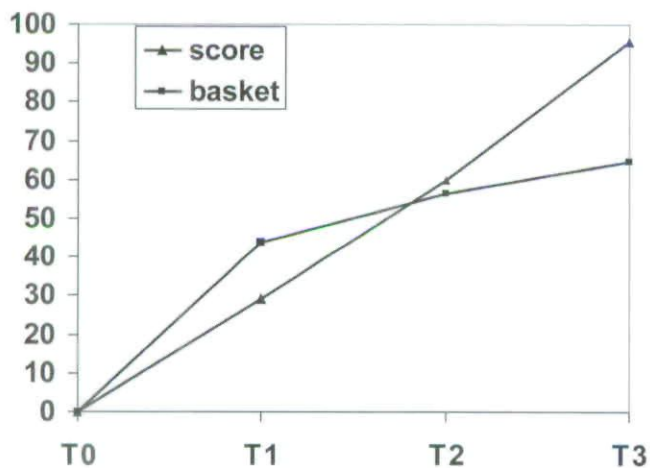


Fig. 2. Mean improvement in clinical score and mean reduction in basket diameter at the psoriatic plaque during treatment at each time-point as a percentage of baseline values.

to the alterations in the keratinocyte proliferation, but which are not evident macroscopically.

In some studies carried out in our clinic we have observed the same dissociation between clinical and microcirculatory alterations, using other systemic drugs, such as etanercept or acitretin (unpublished data), or topical products, such as mometasone furoate (unpublished data) and tacalcitol (11).

It seems clear that without a return of the microcirculation to normality, psoriasis cannot be said to be in remission. Therefore, it is not appropriate to prescribe short-term CyA therapy, i.e. for a period of 3 months, as after such a period it is probable that there will be a rebound effect and the psoriatic plaques will recur. In a future study, we intend to assess how long it takes CyA to effect capillaroscopic healing of a plaque and whether microcirculatory normality is in some way correlated with the duration of remission of the illness.

Conflict of interest: No conflict of interest is reported.

REFERENCES

- Braverman IM, Yen A. Ultrastructure of the capillary loops in the dermal papillae of psoriasis. *J Invest Dermatol* 1977; 68: 53-60.
- Ferguson EH, Epstein WL. Clearance of I131 injected intralesionally in patients with psoriasis. *J Invest Dermatol* 1961; 37: 441-445.
- Hern S, Stanton AW, Mellor R, Levick JR, Mortimer PS. Control of cutaneous blood vessels in psoriatic plaques. *J Invest Dermatol* 1999; 113: 127-132.
- Telner P, Fekete Z. The capillary responses in psoriatic skin. *J Invest Dermatol* 1961; 36: 225-230.
- Goodfield M, Hull SM, Holland D, Roberts G, Wood E, Reid S, et al. Investigations of the 'active' edge of plaque psoriasis: vascular proliferation precedes changes in epidermal keratin. *Br J Dermatol* 1994; 131: 808-813.
- Fuga GC, Marmo W, Acierno F, Bassetti F, Leonetti F, Pampanelli LM, et al. Cutaneous microcirculation in psoriasis. A videocapillaroscopic morphofunctional study. *Acta Derm Venereol* 1994; suppl 186: 138.
- De Angelis R, Bugatti L, Del Medico P, Nicolini M, Filosa G. Videocapillaroscopic findings in the microcirculation of the psoriatic plaque. *Dermatology* 2002; 204: 236-239.
- Bongard O, Weimer D, Lemoine R, Bolle JF, Leski M, Bounameaux H. Cyclosporine toxicity in renal transplant recipients detected by nailfold capillaroscopy with Na-fluoresceine. *Kidn Int* 2000; 58: 2559-2563.
- Espósito M, Diluvio L, Nisticò S, Chimenti S. Cyclosporine A in the therapy of psoriasis. *Trends Med* 2003; 3: 57-65.
- Norrby K. Cyclosporine is angiostatic. *Experientia* 1992; 48: 1135-1138.
- Stinco G, Lautieri S, Patrone P. Videocapillaroscopic study in psoriatic patients treated with tacalcitol. *G Ital Dermatol Venereol* 2006; 141: 227-231.

Copyright of Acta Dermato-Venereologica is the property of Society for Publication of Acta Dermato-Venereologica and its content may not be copied or emailed to multiple sites or posted to a listserv without the copyright holder's express written permission. However, users may print, download, or email articles for individual use.