



IMAGE IN CARDIOLOGY

Cardiac metastasis from colorectal cancer: To be or not to be...



Metástase cardíaca do cancro colorretal: ser ou não ser...

Daniele Pontillo^a, Giordano Zampi^{b,*}, Amedeo Pergolini^c, Vincenzo Polizzi^c,
Denitza Tinti^d, Paolo Spadaccia^a

^a Department of Cardiomyopathies and Heart Failure, Belcolle Hospital, Montefiascone Facility, Montefiascone, (VT), Italy

^b U.O.C. Cardiologia, UTIC ed Emodinamica, Division of Cardiology, Belcolle Hospital, Viterbo, Italy

^c Department of Cardiovascular Sciences, "S. Camillo-Forlanini" Hospital, Rome, Italy

^d Department of Heart and Great Vessels "A. Reale", Policlinico Umberto I, Sapienza, Università di Roma, Italy

Received 15 January 2014; accepted 2 February 2014

Available online 1 September 2014

In this image presentation, we briefly describe a relatively infrequent clinical situation: cardiac metastasis from colon cancer.

A 70-year-old Caucasian woman was referred to our outpatient clinic for preoperative cardiac evaluation before undergoing elective knee replacement. Transthoracic echocardiography (TTE) showed a homogeneous ovoid mass about 2 cm in diameter (Figure 1a) extending from a dilated inferior vena cava (IVC) to the right atrium (RA) (Figure 1b), swinging in synchrony with systole (Movie Clip 1) and not causing right ventricular inflow obstruction. The patient was in good clinical condition, with no signs or symptoms of congestive heart failure. Her past medical history was remarkable for colorectal adenocarcinoma diagnosed seven years before the referral, treated with left hemicolectomy and standard chemotherapy. Serial computed tomography (CT) scans and clinical assessment performed every six months during follow-up were consistent with freedom from disease. To obtain a better definition of the right-sided mass and to exclude any other cause of cardiac

invasion besides primary tumor in the presence of a history of cancer, we decided to perform transesophageal echocardiography (TEE), which confirmed the homogenous appearance of the mass and showed a thin attachment of the mass itself to the inferoposterior RA wall (Figure 1c and d, Movie Clip 2). Caval involvement was also confirmed; all other findings were unremarkable. In order to perform a prompt differential diagnosis between atypical RA myxoma and metastatic invasion of the heart, the patient was immediately admitted to our hospital, where CT showed diffuse metastatic involvement of the lungs and liver with total disruption of the right hepatic lobe architecture (Figure 2a) and invasion of the IVC proceeding towards and entering the right atrium (Figure 2b). Peritoneal carcinomatosis was also noted.

The patient did not undergo surgery due to diffuse metastatic disease, and was treated with standard medical therapy.

The case is self-explanatory in highlighting the many pitfalls of differential diagnosis of cardiac masses with ultrasonography. In the presence of a history of cancer we favor "old-fashioned" CT imaging as the best complementary technique to obtain comprehensive information and characterization of the neoplastic disease.

* Corresponding author.

E-mail address: giordano.zampi@alice.it (G. Zampi).

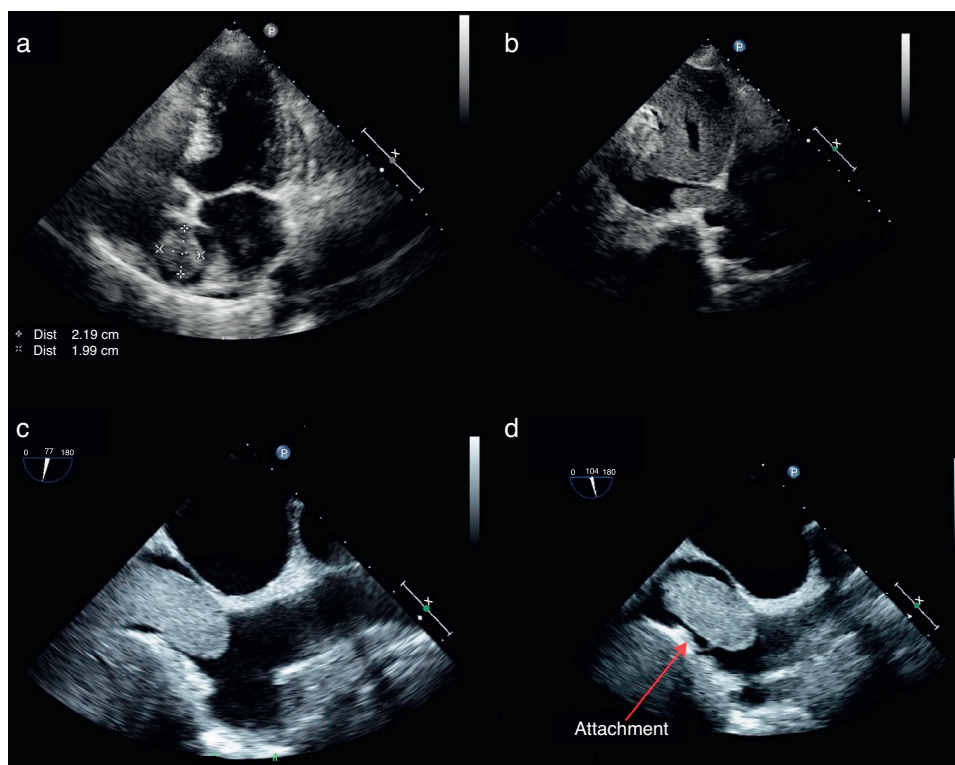


Figure 1 (a) Transthoracic echocardiography, apical 4-chamber view, showing a homogenous ovoid mass; (b) transthoracic echocardiography, subcostal view, showing the mass extending from the inferior vena cava to the right atrium; (c) transesophageal echocardiography, off-axis bicaval view, showing invasion of the inferior vena cava; (d) transesophageal echocardiography, bicaval view, showing the thin attachment of the mass to the right atrial inferoposterior wall.

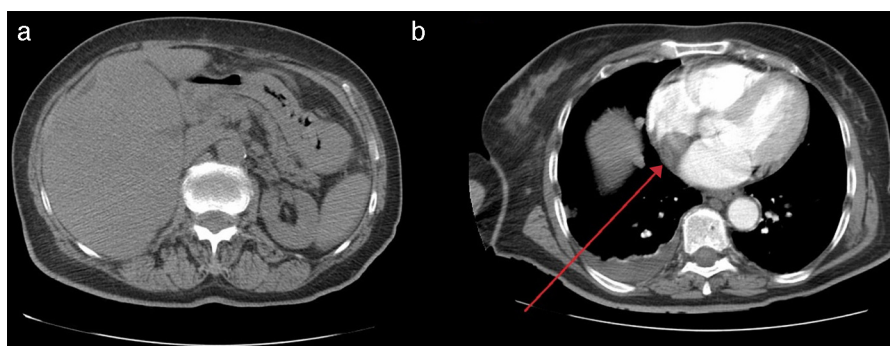


Figure 2 Total body computed tomography scan: (a) large metastatic mass in the right hepatic lobe; (b) thoracic level, the arrow indicating the RA filling defect.

Ethical disclosures

Protection of human and animal subjects. The authors declare that no experiments were performed on humans or animals for this study.

Confidentiality of data. The authors declare that no patient data appear in this article.

Right to privacy and informed consent. The authors declare that no patient data appear in this article.

Conflicts of interest

The authors have no conflicts of interest to declare.

Appendix A. Supplementary data

Supplementary data associated with this article can be found, in the online version, at [doi:10.1016/j.repc.2014.02.022](https://doi.org/10.1016/j.repc.2014.02.022).