

**INCIDENTAL FINDINGS SUGGESTIVE OF COVID-19 IN ASYMPTOMATIC PATIENTS UNDERGOING
NUCLEAR MEDICINE PROCEDURES IN A HIGH PREVALENCE REGION**

Domenico Albano¹, Francesco Bertagna¹, Mattia Bertoli², Giovanni Bosio², Silvia Lucchini², Federica Motta²,
Maria Beatrice Panarotto², Alessia Peli², Luca Camoni², Frank M. Bengel³, Raffaele Giubbini¹.

¹Nuclear Medicine, University of Brescia and Spedali Civili Brescia, Brescia, Italy.

²Nuclear Medicine, Spedali Civili Brescia, Brescia, Italy.

³ Department of Nuclear Medicine, Hannover Medical School, Hannover, Germany.

Corresponding author:

Domenico Albano, M.D.

Nuclear Medicine, Spedali Civili di Brescia, P.le Spedali Civili, 1 25123 Brescia, Italy

e-mail: doalba87@libero.it

Tel.: +39-30-3995468

Fax: +39-30-3995420

Word count: 2490

Short title: incidental pneumonia COVID-19

ABSTRACT

Infection with the novel coronavirus SARS-CoV-2 may remain asymptomatic, leading to under-recognition of the related disease, COVID-19, and to incidental findings in nuclear imaging procedures performed for standard clinical indications. Here, we report about our local experience in a region with high COVID-19 prevalence and dynamically increasing infection rates.

Methods: Within the 8 day period of March 16-24, 2020, hybrid imaging studies of asymptomatic patients who underwent ^{18}F -FDG-PET/CT or ^{131}I -SPECT/CT for standard oncologic indications at our institution in Brescia, Italy, were analyzed for findings suggestive of COVID-19. Presence, radiological features and metabolic activity of interstitial pneumonia were identified, correlated with subsequent short-term clinical course and described in a case series.

Results: Six of 65 patients (9%) that underwent PET/CT for various malignancies showed unexpected signs of interstitial pneumonia on CT and elevated regional FDG-avidity. Additionally, 1 of 12 patients who received radioiodine for differentiated thyroid carcinoma also showed interstitial pneumonia on SPECT/CT. 5/7 patients had subsequent proof of COVID-19 by RT-PCR. The remaining 2 patients were not tested immediately but underwent quarantine and careful monitoring.

Conclusion: Incidental findings suggestive of COVID-19 may not be infrequent in hybrid imaging of asymptomatic patients, in regions with expansive spread of SARS-CoV-2. Nuclear medicine services should prepare accordingly.

Keywords: COVID-19; PET/CT; pneumonia; nuclear medicine.

INTRODUCTION

An aggressive acute respiratory disease caused by SARS-CoV 2, a novel coronavirus of zoonotic origin, called COVID-19, occurred initially during December 2019 in Wuhan, China, and then spread globally, becoming a pandemic. Following the initial peak in China, Europe and especially Northern Italy were severely affected next, with a dramatic increase of cases of pneumonia and respiratory distress syndrome [1,2]. While a severe course of COVID-19 is thought to occur in only a subfraction of infected individuals, many may present with non-specific symptoms such as fever, cough and dyspnoea, and others may initially or entirely remain asymptomatic. The latter subjects are thought to be significant contributors to propagate infection in the population.

Several reports are present in literature [3-5] about the appearance of COVID-19 pneumonia on radiological scans, such as chest X-rays and computed tomography (CT). CT findings are typically characterized by ground-glass opacities (GGOs) or bilateral pulmonary consolidations in multiple lobular and sub-segmental areas [2,6]. Until now, reverse transcriptase-polymerase chain reaction (RT-PCR) from pharyngeal swabs is considered to be the gold standard for the diagnosis of COVID-19 infection, but a high false negative rate is reported, which can cause a miss or delay in the effective diagnosis and increase the risk of spread of the epidemic [7]. Explanation for false negative reports include the lack of shared and standard operation procedures and validation across different laboratories and hospitals, different stages of infection at time of examination, different viral loads and the potential mutation rate of the virus. For this reason, some authors suggest that a combination of clinical, imaging and laboratory results should be used for establishing final diagnosis[8,9].

While nuclear medicine procedures are unlikely to play a role in the primary diagnosis of COVID-19, there may be incidental detection in asymptomatic but infected cases undergoing scans for other indications, which may have relevant implications for further management. Patterns of COVID-19 pneumonia in fluorine-18-deoxyglucose positron emission tomography/CT (¹⁸F-FDG-PET/CT) have been anecdotally described in symptomatic patients recently [10-12]. The aim of the present case-series was to describe our local experience in Northern Italy, triggered by an increase of incidental detection of pneumonia suspicious for COVID-19 in our routine nuclear medicine services.

MATERIALS AND METHODS

Between March 16 and March 24, 2020, sixty-five ¹⁸F-FDG PET/CT studies were performed for routine oncological indications in our Department of Nuclear Medicine in Brescia / Italy. Owing to the concurrent high prevalence and increasing dynamics of coronavirus infections in the region, all patients were asymptomatic and carefully screened by a

triage before general access to the hospital, and again before entering the nuclear medicine service unit. Accordingly, no suspicion of viral infection was present at the time of PET/CT in any patient. According to standard operating procedures, ^{18}F -FDG PET/CT was performed after >6 hours fasting and with blood glucose levels <150mg/dl. An activity of 4.5 MBq/kg was administered intravenously and imaging was acquired 60 minutes after injection from skull base to the mid-thigh (4 minutes per bed; steps of 15 cm), using a Discovery ST or 690 scanner (General Electric, Milwaukee, WI). For both scanners, a standard non-contrast free-breathing helical CT was obtained for morphological correlation and attenuation correction. The D-ST acquisition parameters were: 120kV, fixed tube current 80 mA, 8 slices \times 3.75mm and 3.27mm interval, pitch 1:5, tube rotation 0.8s. The D-690 acquisition parameters were: 120kV, fixed tube current 80 mA, 64 slices \times 3.75mm and 3.27mm interval, pitch 0.984:1, tube rotation 0.5s. The lung CT images were reconstructed using a 512 \times 512 matrix and iterative reconstruction, 1.25mm(D-690) or 2.5mm(D-STE) slice thickness and 1.25mm interval, lung filter with a window setting with an 1600 Hounsfield units (HU) of window width and a -480 HU of window level.

During the same period, twelve patients were admitted for radioiodine ablation of thyroid remnant after thyroidectomy for differentiated thyroid carcinoma. All patients underwent whole body ^{131}I scintigraphy followed by single photon emission computed tomography/CT (SPECT/CT) 3–4 days after administration, using a dual-headed camera (Infinia Hawkeye II, GE Healthcare, Haifa Israel), equipped with 1 inch StarBriteTM crystals and a high energy collimator. The CT was acquired in free-breathing and the parameters were 140 kV, 2.5 mA, 30s rotation time in axial mode, 4 slices \times 5 mm thickness, 256 \times 256 matrix.

RESULTS

At PET/CT, 6/65 patients (9%) showed CT signs of interstitial pneumonia, suspicious for COVID-19. In all cases, areas of pneumonia were FDG avid. This frequency of incidental pneumonia was significantly higher when compared to PET/CT scans of the same period one year earlier (prior to the onset of the COVID-19 pandemic; only 2 of 80 PET/CT studies performed during 8 days of March 2019 had incidental pneumonia). Individual cases are described below:

CASE 1. An asymptomatic 56-year old woman underwent ^{18}F -FDG PET/CT for primary staging of anal cancer after recent primary surgical therapy (February 2020) Pre-surgery chest X-ray was negative (**Fig. 1A**). PET/CT identified FDG-avid inguinal nodal metastases, but also showed FDG-positive GGOs and consolidation in both lungs, most pronounced in inferior lobes (**Figure 1B-E**). RT-PCR testing for SARS-CoV 2 was initiated and confirmed the diagnosis of

COVID-19. Subsequent oncologic therapy was postponed and the patient started COVID-19 therapy with Hydroxychloroquine plus Ritonavir/Lopinavir

CASE 2. An asymptomatic 77-year old man underwent ^{18}F -FDG PET/CT for staging of laryngeal cancer prior to therapy. PET/CT showed increased FDG-uptake at the right epiglottis and local cervical nodes (**Fig. 2A**). Additionally, there was faint FDG-uptake in bilateral GGOs not suggestive of aspiration (**Fig. 2B-G**). RT-PCR testing was initiated immediately and confirmed the diagnosis of COVID-19. Subsequent surgical therapy was postponed and the patient started therapy with Hydroxychloroquine plus Ritonavir/Lopinavir.

CASE 3. An asymptomatic 55-year old woman with a history of invasive ductal breast carcinoma previously treated by surgery, chemotherapy and radiotherapy underwent ^{18}F -FDG PET/CT for restaging. A high-resolution chest CT two weeks earlier showed a suspicious retrosternal lymph node but no lung pathology (**Fig. 3A,B**). PET confirmed retrosternal FDG-avid nodal relapse and showed novel GGOs in the posterior segments of inferior lung lobes (**Fig. 3C-H**). The patient underwent quarantine for 15 days with daily body temperature measurements but remained asymptomatic during that time. She was subsequently scheduled for nodal biopsy.

CASE 4. An asymptomatic 55-year old woman with Hodgkin's lymphoma treated previously with two lines of chemotherapy underwent a chest CT positive for axillary nodes but without lung alterations (**Fig. 4A,B**). One week later, she underwent ^{18}F -FDG PET/CT confirming active lymphoma in axillary nodes and showing new interstitial opacities near the pleura of the right lung (**Fig. 4C-F**). The patient underwent immediate RT-PCR testing that was negative, but several days later, fever and dyspnoea appeared, leading to hospitalization and re-testing with proof of COVID-19.

CASE 5. An asymptomatic 65-year old man with a history of laryngeal cancer previously treated with surgery, underwent follow-up PET/CT that was negative for malignancy. Thoracic CT displayed several GGOs in the right lung (**Fig. 5A-F**) with increased radiotracer uptake (SUV_{max} 5.3). Being asymptomatic, the patient did not undergo pharyngeal swabs but was strictly monitored by his general physician, checking body temperature and clinical conditions for 15 days as suggested by national rules.

CASE 6. An asymptomatic 65-year old woman with a history of ovarian cancer previously treated with surgery plus chemotherapy, underwent follow-up PET/CT that was negative for ovarian malignancy but demonstrated interstitial pneumonia with consolidative areas in both lungs and increased FDG uptake (**Fig. 6A-F**). Moreover, some mediastinal nodes were demonstrated to be FDG-avid (**Fig. 6G-I**). RT-PCR testing was performed immediately and confirmed COVID-19. Her husband also tested positive for COVID-19.

CASE 7 (¹³¹I SPECT/CT). Among the 12 patients who received radioiodine for differentiated thyroid carcinoma, there was one case of a female with incidental interstitial pneumonia detected at SPECT/CT. This 79-year old woman with poorly differentiated thyroid carcinoma had a prior chest CT showing solid lung nodules suspicious for metastases. She received 3.7 GBq of iodine-131 for remnant ablation and assessment of radioiodine positivity of the lung nodules. The serum thyroid-stimulating hormone level was 100 mU/L, serum thyroglobulin was higher than 2500 ng/mL and serum thyroglobulin antibodies were 50,6 UI/ml. After 72 hours, planar radioiodine scintigraphy (**Fig. 7A anterior view, 7B posterior view**) showed high focal uptake in residual thyroid tissue and no other foci. SPECT-CT ruled out radioiodine avidity of bilateral solid lung nodules but CT also showed new, diffuse interstitial pneumonia with peripheral GGOs, without increased radioiodine uptake (**Fig. 7C,D**). Fever and cough appeared one day after the scan. RT-PCR testing was positive for COVID-19 and probatory therapy with Hydroxychloroquine plus Ritonavir/Lopinavir was started.

DISCUSSION

High-resolution chest CT is the routine-preferred tool for detection, diagnosis and monitoring of symptomatic COVID-19 pneumonia. CT findings of COVID-19 have been widely reported [2-6]. Usually in the early phases, single or multiple GGOs, nodules or plaques may appear. With the progression of disease, the lesions increase, occupying most of the lungs. The CT pattern is similar to other viral pneumonias like MERS and SARS [13]. The role of CT in screening for viral lung disease in asymptomatic subjects, however, is not well defined.

In our report, all lung lesions on CT were FDG-positive and in one case, even FDG-avid mediastinal nodes were identified. This metabolically active pattern of COVID-19 pneumonia in ¹⁸F-FDG PET/CT scans is so far supported only by a cases series and a case report [11-12]. Qin et al. [12] described 4 cases of suspected COVID-19 pneumonia with increased FDG-uptake but no RT-PCR confirmation. In our population, five of seven patients received RT-PCR that confirmed COVID-19. In the other cases, RT-PCR was not performed because it was not mandatory in the absence of symptoms according to national rules. Another difference to prior publications is that all our patients were asymptomatic at the time of imaging and in the two weeks before (because only patients without signs and symptoms related to COVID-19 for a 2 week period were allowed to access the hospital). This confirms that it is possible to have COVID-19 pneumonia without symptoms, increasing the risk to spread infection.

Because the CT in hybrid imaging sessions is mainly acquired for attenuation correction, its diagnostic quality is not entirely equivalent to dedicated chest CT. Specifically, a lack of full inspiration may contribute to higher density in posterior lung fields. But metabolic activity may help to distinguish infectious origin from artefact, and a more widespread

pattern of GGO across the lungs may also help to identify COVID more specifically. It should be noted, however, that our report is observatory in nature, and that a precise definition of the accuracy of PET findings of COVID would require prospective validation in larger cohorts.

Nevertheless, our observations on the one hand show that it is mandatory for healthcare personnel to employ hygienic measures, minimize patient contact and optimize distance, and use protective equipment for general clinical services in regions with high COVID prevalence. In our department, the healthcare personnel started to use individual protective equipment from the start of March, so no cases of infected staff were reported to date. Moreover, following our national laws, no swap test is indicated for asymptomatic staff who came into contact with COVID-19 positive patients.

On the other hand, it is important to consider potential COVID-19 related findings during reading, and to report such findings to the patient and his referring physicians immediately, for appropriate action. Depending on local and contemporary regulations, an asymptomatic patient may stay at home with adequate clinical monitoring; in case of clinical doubts, more aggressive measures may be appropriate with the risk to postpone oncological treatments potentially affecting survival. Thereby, the incidental detection of COVID-19 pneumonia in early stages may help to prevent further spread of the virus.

CONCLUSION

COVID-19 suspected pneumonia is FDG-avid and may be detected as incidental finding in asymptomatic patients undergoing nuclear medicine examinations for oncologic indications in regions with high COVID-19 prevalence. Nuclear medicine services should be prepared accordingly.

COMPLIANCE WITH ETHICAL STANDARDS

Conflict of interest: The authors declare they have no conflict of interest.

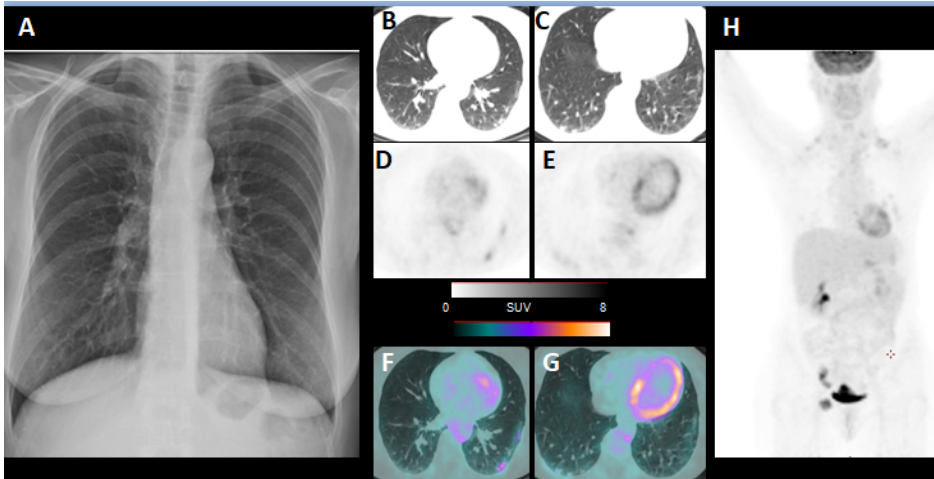
Ethical approval: All procedures performed in studies involving human participants were in accordance with the ethical standards of the institutional and/or national research committee and with the 1964 Helsinki declaration and its later amendments or comparable ethical standards. For this type of study, formal consent is not required.

Informed consent: Informed consent was obtained from all individuals prior to imaging procedures.

REFERENCES

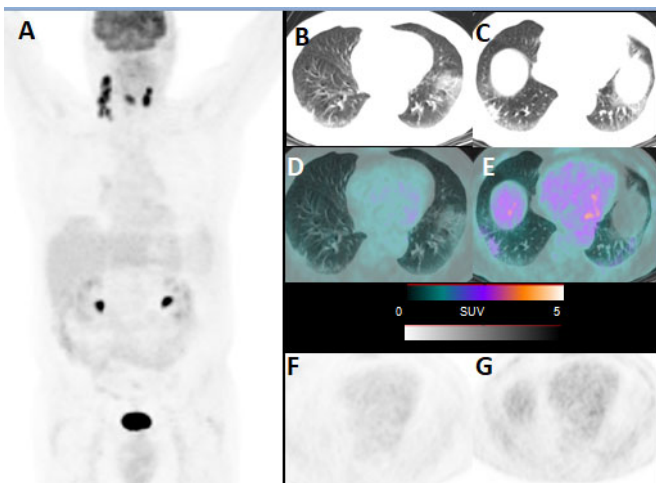
1. Park M, Thwaites RS, Openshaw PJM. COVID-19: lessons from SARS and MERS. *Eur J Immunol.* 2020;50(3):308–311.
2. Huang C, Wang Y, Li X, et al. Clinical features of patients infected with 2019 novel coronavirus in Wuhan, China. *Lancet.* 2020;395:497–506.
3. Kanne JP, Little BP, Chung JH, Elicker BM, Ketai LH. Essentials for radiologists on COVID-19: an update radiology scientific expert panel. *Radiology.* 2020;295(1):16–17.
4. Shi H, Han X, Jiang N, Cao Y, Alwalid O, et al. Radiological findings from 81 patients with COVID-19 pneumonia in Wuhan, China: a descriptive study. *Lancet Infect Dis.* 2020. [https://doi.org/10.1016/S1473-3099\(20\)30086-4](https://doi.org/10.1016/S1473-3099(20)30086-4)
5. Lee EYP, NgMY, Khong PL. COVID-19 pneumonia: what has CT taught us. *Lancet Infect Dis.* 2020. [https://doi.org/10.1016/S1473-3099\(20\)30134-1](https://doi.org/10.1016/S1473-3099(20)30134-1).
6. Chung M, Bernheim A, Mei X, et al. CT Imaging Features of 2019 Novel coronavirus (2019-nCoV). *Radiology.* 2020;200230. <https://doi.org/10.1148/radiol.2020200230>.
7. Lan L, Xu D, YeG, et al. Positive RT-PCR test results in patients recovered from COVID-19. *JAMA.* 2020. <https://doi.org/10.1001/jama.2020.2783>.
8. Fang Y, Zhang H, Xie J, et al. Sensitivity of chest CT for COVID-19: comparison to RT-PCR. *Radiology* 2020. doi.org/10.1148/radiol.2020200432
9. Xie, X, Zhong, Z, Zhao, W, Zheng, C, Wang, F, Liu, J. Chest CT for typical 2019-nCoV pneumonia: relationship to negative RT-PCR testing. *Radiology* 2020. doi.org/10.1148/radiol.2020200343.
10. Deng Y, Lei L, Chen Y, Zhang W. The potential added value of FDG PET/CT for COVID-19 pneumonia. *Eur J Nucl Med Mol Imaging* 2020 doi.org/10.1007/s00259-020-04767-1
11. Zou S, Zhu X. FDG PET/CT of COVID-19. *Radiology* 2020 doi.org/10.1148/radiol.2020200770
12. Qin C, Liu F, Yen TC, Lan X. 18F-FDG PET/CT findings of COVID-19: a series of four highly suspected cases. *Eur J Nucl Med Mol Imaging.* 2020. <https://doi.org/10.1007/s00259-020-04734-w>.
13. Koo HJ, Lim S, Choe J, et al. Radiographic and CT features of viral pneumonia. *Radiographics.* 2018;38:719–39.

Figure 1



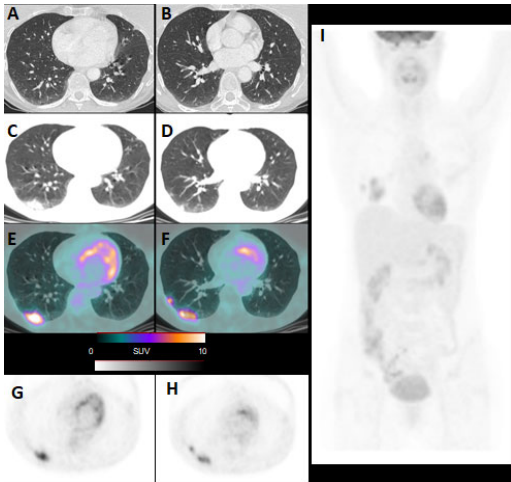
Chest X-rays without pathological findings (A). Subsequent axial CT (B,C), PET (D,E) and PET/CT fused images (F,G) showing pleuric consolidative areas FDG positive (SUVmax 3.6). Maximum intensity projection (MIP, H) showing hypermetabolic inguinal lesions.

Figure 2



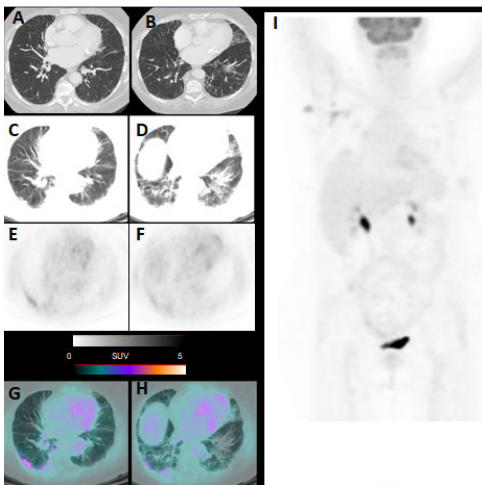
Maximum intensity projection (A) demonstrating FDG increased uptake at right epiglottis and cervical nodes. Axial CT (B,C), PET/CT fused (D,E) and PET images (F,G) showing interstitial pneumonia with GGOs FDG-avid (SUVmax 2).

Figure 3



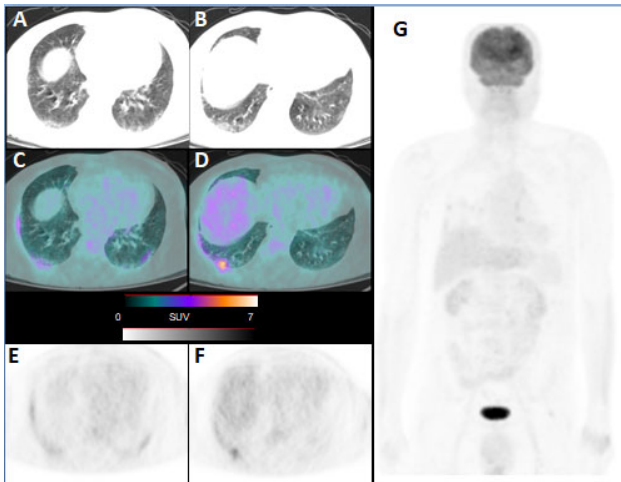
High resolution thoracic CT without no sign of pneumonia (**A,B**). PET/CT performed two weeks later, demonstrating GGOS and consolidative areas in the right inferior lobe at CT (**C,D**), PET/CT fused (**E,F**) and PET images (**G,H**) with SUVmax of 7.7. MIP (**I**) confirming pulmonary uptake.

Figure 4



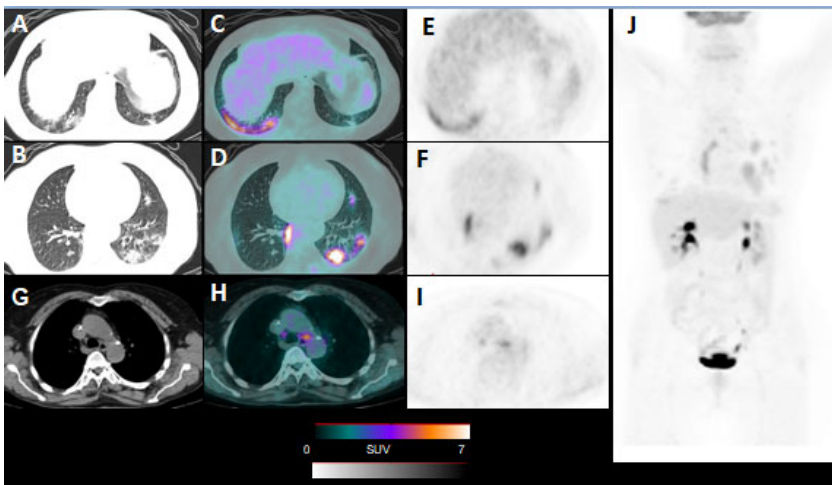
High resolution thoracic CT without no sign of pneumonia (**A,B**). PET/CT performed one week later, showing bilateral pneumonia with GGOS at CT (**C,D**), PET (**E,F**) and PET/CT fused images (**G,H**) with SUVmax of 5. MIP (**I**) showing axillary nodal lesion FDG positive.

Figure 5



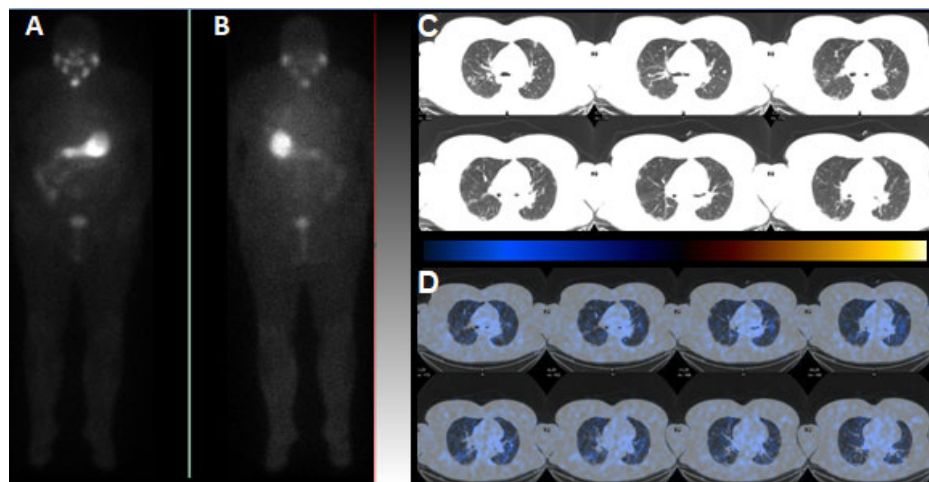
Axial CT (**A,B**), PET/CT fused (**C,D**) and PET images (**E,F**) detecting increased radiotracer uptake corresponding to interstitial lung alterations (SUVmax 5,3). MIP (**G**) showing all body.

Figure 6



Axial CT (**A,B**), PET/CT fused (**C,D**) and PET images (**E,F**) showing significant pneumonia with GOOS especially in the left lung (SUVmax 6.9) and FDG-avid mediastinal nodes (**G,H,I**). MIP (**J**) confirming lung and nodal alterations.

Figure 7



Whole body scintigraphy after radioiodine treatment showing focal uptake in the neck consistent of thyroid remnant (**A,B**).

Several axial CT (**C**) and SPECT/CT (**D**) fused slices characterized by various bilateral GGOs without radioiodine uptake.



The Journal of
NUCLEAR MEDICINE

INCIDENTAL FINDINGS SUGGESTIVE OF COVID-19 IN ASYMPTOMATIC PATIENTS UNDERGOING NUCLEAR MEDICINE PROCEDURES IN A HIGH PREVALENCE REGION

Domenico Albano, Francesco Bertagna, Mattia Bertolia, Giovanni Bosio, Silvia Lucchini, Federica Motta, Maria Beatrice Panarotto, Alessia Peli, Luca Camoni, Frank M. Bengel and Raffaele Giubbini

J Nucl Med.

Published online: April 1, 2020.

Doi: 10.2967/jnumed.120.246256

This article and updated information are available at:

<http://jnm.snmjournals.org/content/early/2020/04/01/jnumed.120.246256>

Information about reproducing figures, tables, or other portions of this article can be found online at:

<http://jnm.snmjournals.org/site/misc/permission.xhtml>

Information about subscriptions to JNM can be found at:

<http://jnm.snmjournals.org/site/subscriptions/online.xhtml>

JNM ahead of print articles have been peer reviewed and accepted for publication in *JNM*. They have not been copyedited, nor have they appeared in a print or online issue of the journal. Once the accepted manuscripts appear in the *JNM* ahead of print area, they will be prepared for print and online publication, which includes copyediting, typesetting, proofreading, and author review. This process may lead to differences between the accepted version of the manuscript and the final, published version.

The Journal of Nuclear Medicine is published monthly.
SNMMI | Society of Nuclear Medicine and Molecular Imaging
1850 Samuel Morse Drive, Reston, VA 20190.
(Print ISSN: 0161-5505, Online ISSN: 2159-662X)

© Copyright 2020 SNMMI; all rights reserved.