



# Mesenteric cystic lymphangioma mimicking an ileo-colic intussusception

Elisa Mina<sup>a,\*</sup>, Giulia Fusi<sup>a</sup>, Rossella Angotti<sup>a</sup>, Nicolò Nardi<sup>b</sup>, Mohamed Vincenti<sup>a</sup>,  
Mario Messina<sup>a</sup>, Francesco Molinaro<sup>a</sup>, Mirko Bertozzi<sup>b</sup>

<sup>a</sup> Division of Pediatric Surgery, Department of Medical, Surgical and Neurological Sciences, University of Siena, Le Scotte Polyclinic Hospital, Viale Bracci 14, 53100, Siena, Italy

<sup>b</sup> Pediatric Surgery Unit, Department of Surgical and Biomedical Sciences, University of Perugia, S. Maria della Misericordia Hospital, Piazzale Giorgio Menghini 1, 06129, Perugia, Italy

## ARTICLE INFO

### Keywords:

Mesenteric cystic lymphangioma  
Lymphangioma  
Intussusception  
Children  
Emergency  
Surgery  
Pediatric surgery

## ABSTRACT

Lymphangioma accounts for 5% of benign pediatric tumors and less than 1% is located in the abdomen. Indeed mesenteric cystic lymphangioma is a rare benign abdominal mass and its pathogenesis is still unknown.

Mesenteric cystic lymphangioma is often diagnosed incidentally. Nevertheless, in some cases its clinical presentation can mimic several common surgical pathologies. Here we describe a case of mesenteric cystic lymphangioma mimicking an ileo-colic intussusception.

## 1. Introduction

Mesenteric cystic lymphangioma (MCL) is a rare benign intra-abdominal anomaly with uncertain etiology, predominantly occurring in children [1]. In the pediatric age group, males seem to be more affected than females [2].

The diagnosis of MCL is often incidental and almost 60% are detected before the fifth year of life [3]. Most MCL patients are initially asymptomatic, with vague abdominal symptoms. Nevertheless, acute presentation due to complications may occur: torsion, rupture, hemorrhage, volvulus, compression of adjacent organs, intestinal ischemia and malrotation are reported in literature and they can be life-threatening [1,4].

The optimal treatment for mesenteric cystic lymphangioma is a surgical approach with resection of the mass, sometimes including resection of the adjacent bowel to achieve complete excision [4].

However, a complete resection of a MCL may be limited by the size and site of the lesion since this may require a too extensive bowel resection, resulting in a short bowel syndrome [2,5].

In this case report we describe a unique presentation of a MCL in children and its successful surgical treatment.

### 1.1. Case report

A 9-month-old boy presented at our emergency department with crampy colics. The physical examination revealed abdominal distension, abdominal tenderness with guarding and scarce bowel sounds.

Abdominal palpation resulted difficult due to the child's uneasiness. A little amount of red jelly stool was seen in the diaper. Laboratory results were normal.

Ultrasonography was carried out for further diagnosis showing multiple fluid-filled bowel loops without a clear visualization of the appendix or signs of intussusception. A "wait-and-see" policy was followed indeed.

After 4 hours of observation the patient presented with vomiting and the abdominal colicky pain got worse.

For these reasons we performed a barium enema with a suspicion of an intermittent ileo-colic intussusception. The barium enema showed a stop in the contrast progression at the hepatic flexure level apparently due to an intussusception (Fig. 1 A and B). Because of the failed resolution of the suspected intussusception at the barium enema and the worsened symptomatology, we decided to perform a surgical exploration.

\* Corresponding author.

E-mail addresses: [elisamina.mc@gmail.com](mailto:elisamina.mc@gmail.com) (E. Mina), [gf.giuliafusi@gmail.com](mailto:gf.giuliafusi@gmail.com) (G. Fusi), [rossella.angotti@ao-siena.toscana.it](mailto:rossella.angotti@ao-siena.toscana.it) (R. Angotti), [chirurgia.pediatrica@ospedale.perugia.it](mailto:chirurgia.pediatrica@ospedale.perugia.it) (N. Nardi), [dr.mohamed.vincenti@gmail.com](mailto:dr.mohamed.vincenti@gmail.com) (M. Vincenti), [mario.messina@unisi.it](mailto:mario.messina@unisi.it) (M. Messina), [francesco.molinaro@ao-siena.toscana.it](mailto:francesco.molinaro@ao-siena.toscana.it) (F. Molinaro), [mirkobertozzi@hotmail.com](mailto:mirkobertozzi@hotmail.com) (M. Bertozzi).

<https://doi.org/10.1016/j.epsc.2020.101461>

Received 28 February 2020; Received in revised form 27 March 2020; Accepted 4 April 2020

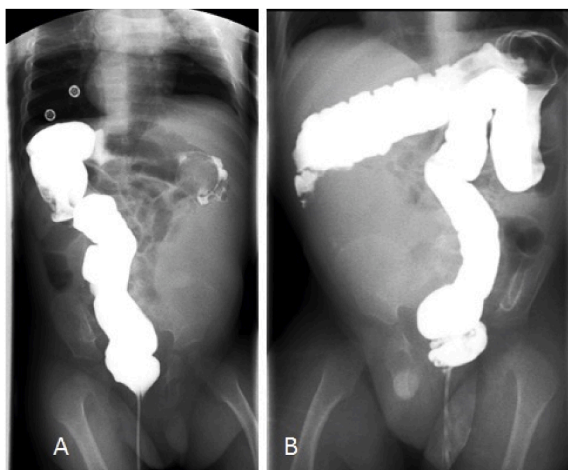
Available online 15 April 2020

2213-5766/© 2020 The Authors.

Published by Elsevier Inc.

This is an open access article under the CC BY-NC-ND license

(<http://creativecommons.org/licenses/by-nc-nd/4.0/>).



**Fig. 1.** A-B. Barium enema: Postero-anterior view showing the stop of the contrast in the right colic flexure. B. Barium enema: Antero-posterior view showing the same stop of the contrast.

Surprisingly, laparotomy showed a big multicystic mass starting from the mesentery, tightly adherent to the right colon and wrapping-around it (Fig. 2). The size of the multicystic mass was approximately 16x14x10 cm.

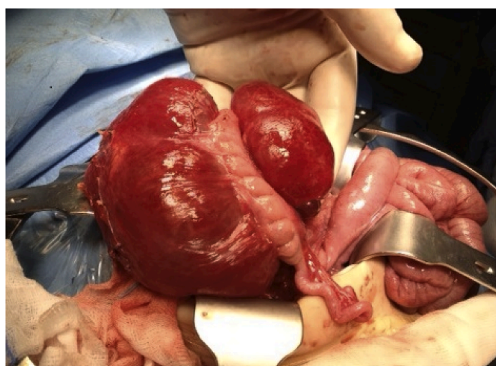
In order to preserve the entire right colon and the ileo-cecal valve together with the last ileal loop, a surgical enucleation of the mass was tried avoiding damage of the mesenteric blood supply. In this way we removed about the 95% of the mass. Complete resection was not possible without compromising the colon, because of diffusely spread lesions in its mesentery. Some very small cysts at the root of the mesentery were only incised and evacuated because of the risk of vessels damage.

The patient had an uneventful post-operative recovery and he was discharged after 7 days. No explanation for rectal bleeding was found. Histopathological examination of the specimen revealed a mesenteric cystic lymphangioma.

Follow-up by ultrasonography was scheduled. Ultrasound imaging at 3, 6 and 12 months showed some very little cysts at the root of the ileo-cecal mesentery. At the 24 months ultrasonography we observed a disappearance of the cysts. The absence of the cysts was also confirmed in the next three annual scheduled ultrasounds.

## 2. Discussion

MCL are rare with fewer than 200 detailed reports published in the English-language literature [6].



**Fig. 2.** B. MCL starting from the colic mesentery, tightly adherent to the right colon and wrapping-around it.

The etiology of MCL is unknown, though some believe that it might be associated with developmental anomalies of the lymphatics [7]. Other possible etiologies include bleeding or inflammation in the lymphatic channels, both leading to obstruction and subsequent lymphangioma formation [8–10] as well as chronic inflammation, neoplasm, trauma and degeneration of lymph nodes [11].

Pediatric lymphangioma accounts for 5% of all benign tumors in children and MCLs are responsible for 1/20.000 hospital admissions in the pediatric age group [12].

Among all lymphangiomas less than 1% affect the mesentery, greater omentum, and retroperitoneum [1,7,13]. Among the intra-abdominal locations, the mesocolon and the retroperitoneum are involved in 10% and 5% of cases respectively; the small bowel mesentery is more frequently affected [1,6,7].

In the pediatric age group, males seem to be predominantly affected with a reported male to female ratio of 1.5:1 up to 3:1 [2].

MCL is often an incidental finding during imaging studies performed for unrelated clinical conditions [1]. Most MCL patients are initially asymptomatic, with vague and obscure abdominal symptoms depending on the cyst's size and location [6]. Symptoms can be abdominal discomfort, pain and abdominal distention with or without vomiting [2,14]. Nevertheless, children present with acute complaints more frequently than adults [15]. Acute clinical pictures requiring emergency laparotomy include traumatic rupture, intracavitary or intra-abdominal bleeding, intestinal obstruction with necrosis, intestinal gangrene due to volvulus, and cyst infarction [6].

If a MCL is suspected, ultrasonography, MRI and CT can provide a high preoperative diagnostic accuracy [5,16]. When possible, we prefer to perform ultrasonography and MRI avoiding the disadvantages of irradiation in the developing children [17,18].

Nevertheless, in our case, the abdominal ultrasound investigation performed at the emergency department was not diagnostic. This may be due to the fact that ultrasonography is highly operator-dependant and it is particularly susceptible to errors when performed in emergency settings by non-dedicated radiologists [19]. Therefore, as in the case reported by Clement et al. [1], the cysts were not identified and were even falsely interpreted as fluid-filled bowel loops.

For this reason and for a suspect of intermittent ileo-colic intussusception a barium enema was performed. The clinical picture of acute abdomen, supported by the images of contrast enema interpreted as ileo-colic intussusception, lead us to decide for a surgical exploration.

Whether or not the diagnosis of MCL is obtained before the intervention the complete surgical resection is indicated, since this benign tumor tend to recur and invade neighboring structures [13] and the risk of complications increases with size [16].

Total removal of a lesion that invades potentially resectable intra-abdominal structures such as bowel, spleen, or pancreas is possible [20]. Nevertheless, high caution must be done during surgery because adhesions to vital structures such as major vessels and nerves can make resection hazardous or even impossible and a too extensive bowel resection could result in a possible short bowel syndrome [2,5].

In our case, we preferred to perform an accurate enucleation of the mass instead of a right colectomy, because this procedure should have included the removal of the ascending colon and the ileo-cecal valve without any guarantee of complete excision of the lymphangioma, since it was extended to the root of the mesentery and to the retroperitoneum. Therefore, we removed about 95% of the mass and the remaining millimetric cysts at the root of the mesentery were only incised and drained, even if in literature there is a lack of long-term results with this procedure [21]. In this way, although the procedure was not radical, we spared the ascending colon and the ileo-cecal valve.

In our patient, the 5-year follow-up testifies to the success of the surgical procedure performed.

### 3. Conclusion

MCL is a rare condition with a high percentage of possible misdiagnosis especially in the case of presentation with acute symptoms. Our case shows a new possible clinical picture mimicked by the MCL.

In the case of near total resection of the MCL due to the inclusion of major vessels, the remaining little cysts may be opened and evacuated with possibility of recovery.

### Patient consent

Consent to publish the case report was not obtained. This report does not contain any personal information that could lead to the identification of the patient.

### Funding

No funding or grant support.

### Authorship

All authors attest that they meet the current ICMJE criteria for Authorship.

### Declaration of competing interest

The following authors have no financial disclosures: M E, F G, A R, N N, V M, M M, M F, B M.

### References

- [1] Clement C, Snoekx R, Ceulemans P, Wyn I, Matheï J. An acute presentation of pediatric mesenteric lymphangioma: a case report and literature overview. *Acta Chir Belg* 2018 Oct;118(5):331–5.
- [2] Kim SH, Kim HY, Lee C, Min HS, Jung SE. Clinical features of mesenteric lymphatic malformation in children. *J Pediatr Surg* 2016 Apr;51(4):582–7.
- [3] Caro PA, Mahboubi S, Faerber EN. Computed tomography in the diagnosis of lymphangiomas in children. *Clin Imag* 1991 Jan-Mar;15(1):41–6.
- [4] Xu X, Zheng C, He X, Zhao Y, Hong T. Gastrointestinal: giant mesenteric cystic lymphangioma. *J Gastroenterol Hepatol* 2017 Feb;32(2):290.
- [5] Goh BK, Tan YM, Ong HS, Chui CH, Ooi LL, Chow PK, et al. Intra-abdominal and retroperitoneal lymphangiomas in pediatric and adult patients. *World J Surg* 2005 Jul;29(7):837–40.
- [6] Losanoff JE, Richman BW, El-Sherif A, Rider KD, Jones JW. Mesenteric cystic lymphangioma. *J Am Coll Surg* 2003 Apr;196(4):598–603.
- [7] Mayer M, Fartab M, Villiger A, Yurtsever H. Cystic lymphangioma of the transverse mesocolon. *Chirurg* 1994 Jun;65(6):561–3.
- [8] Niwa H, Sumita N, Ishihara K, Hoshino T, Iwase H, Kuwabara Y. A Case of Retroperitoneal Chylous cyst Developed after Cholecystectomy and Cholelecotomy. *Nihon Geka Gakkai Zasshi*. 89; 1988 Feb. p. 282–5. 2.
- [9] Gleason TJ, Yuh WT, Tali ET, Harris KG, Mueller DP. Traumatic cervical cystic lymphangioma in an adult. *Ann Otol Rhinol Laryngol* 1993 Jul;102(7):564–6.
- [10] Schmidt M. Intra-abdominal lymphangioma. *Kans Med* 1992 May;93(5):149–50.
- [11] Weeda VB, Booij KA, Aronson DC. Mesenteric cystic lymphangioma: a congenital and an acquired anomaly? Two cases and a review of the literature. *J Pediatr Surg* 2008 Jun;43(6):1206–8.
- [12] Méndez-Gallart R, Bautista A, Estévez E, Rodríguez-Barca P. Abdominal cystic lymphangiomas in pediatrics: surgical approach and outcomes. *Acta Chir Belg* 2011 Nov-Dec;111(6):374–7.
- [13] Hancock BJ, St-Vil D, Luks FI, Di Lorenzo M, Blanchard H. Complications of lymphangiomas in children. *J Pediatr Surg* 1992 Feb;27(2):220–4. ; discussion 224–6.
- [14] Luo CC, Huang CS, Chao HC, Chu SM, Hsueh C. Intra-abdominal cystic lymphangiomas in infancy and childhood. *Chang Gung Med J* 2004 Jul;27(7):509–14.
- [15] Merrot T, Chaumoitre K, Simeoni-Alias J, Alessandrini P, Guys JM, Panuel M. Abdominal cystic lymphangiomas in children. Clinical, diagnostic and therapeutic aspects: apropos of 21 cases. *Ann Chir* 1999;53(6):494–9.
- [16] Li Q, Ji D, Tu KS, Dou CW, Yao YM. Clinical analysis of intraperitoneal lymphangioma. *Chin Med J* 2015 Nov 20;128(22):3043–9.
- [17] Bertozzi M, Riccioni S, Valoncelli C, Appignani A. The diagnosis and management of ovarian cysts in children. *J Pediatr Adolesc Gynecol* 2017 Apr;30(2):265.
- [18] Bertozzi M, Magrini E, Bellucci C, Riccioni S, Appignani A. Recurrent ipsilateral ovarian torsion: case report and literature review. *J Pediatr Adolesc Gynecol* 2015 Dec;28(6):e197–201.
- [19] Pinto A, Pinto F, Faggian A, Rubini G, Caranci F, Macarini L, et al. Sources of error in emergency ultrasonography. *Crit Ultrasound J* 2013;5(Suppl 1):S1.
- [20] Stopinski J, Stephan S, Staib I. Intra-abdominal cystic lymphangioma and mesenteric cysts as a cause of abdominal discomfort. *Langenbecks Arch Chir* 1994; 379(3):182–7.
- [21] Mabrut JY, Grandjean JP, Henry L, Chappuis JP, Partensky C, Barth X, et al. Mesenteric and mesocolic cystic lymphangiomas. Diagnostic and therapeutic management. *Ann Chir* 2002 May;127(5):343–9.