



Medical Imagery

Secondary peritoneal echinococcosis causing massive bilateral hydronephrosis and renal failure

A 64-year-old Moroccan man was referred to our clinic for abdominal cystic echinococcosis (CE). He had undergone surgery for hepatic CE 29 years earlier, with no perioperative prophylaxis with albendazole. He presented with abdominal distension and abdominal pain. An ultrasound (US) showed multiple CE3b and CE4 cysts with calcifications and two echo-free collections 13 cm in diameter seen on paraumbilical scans (Figure 1a). The portal tract, pancreas, spleen, kidneys, and aorta were not visible on US. The bladder was compressed by a large cyst. Serology for *Echinococcus granulosus* was positive (indirect hemagglutination test titer 1/4096; Echinococcus IgG ELISA optical density 6.70).

A computed tomography (CT) scan showed disseminated peritoneal echinococcosis, multiple CE3b and CE4 cysts of up to 15 cm in diameter, and severe bilateral hydronephrosis, which looked like giant echinococcal cysts on US (Figure 1b). The patient had been on hemodialysis three times a week since 2008 due to worsening renal function and was on albendazole (400 mg twice daily). The surgeons refused an intervention for fear of exposing the patient to bleeding complications.

Disseminated peritoneal CE may result from fluid spillage during hepatic surgery for CE and its consequences may go beyond mechanical distension and impair vital organ function.¹ Failure to

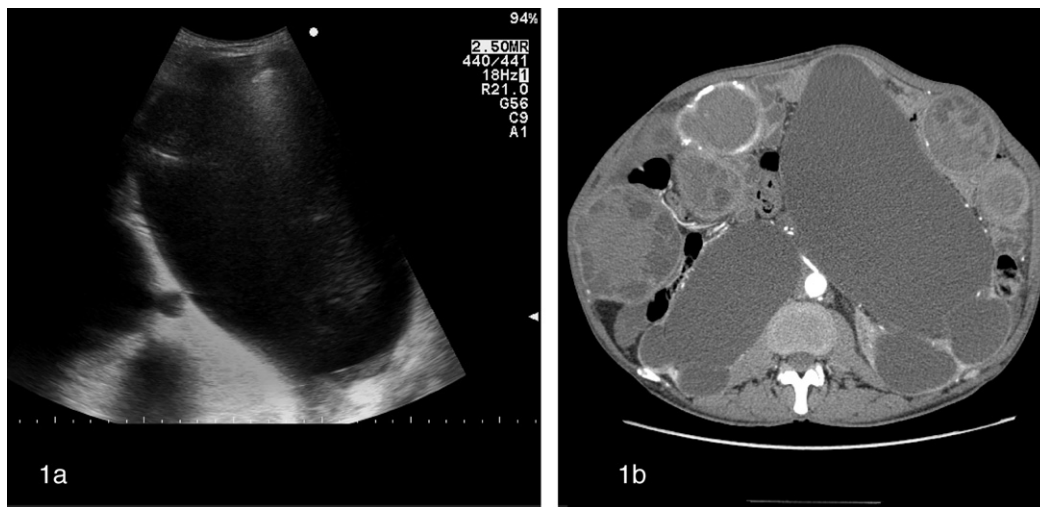


Figure 1. (a) US scan showing a giant fluid collection initially thought to be a CE1 cyst, but corresponding to extreme hydronephrosis due to severe compression on the ureters. (b) CT showing multiple peritoneal echinococcal cysts; the markedly dilated renal pelvis is visible bilaterally.

administer perioperative prophylaxis may have serious long-term consequences.

Conflict of interest: No conflict of interest to declare.

^aDepartment of Infectious Diseases, WHO Collaborating Centre for Clinical Management of Cystic Echinococcosis, University of Pavia, San Matteo Hospital Foundation, Pavia, Italy
^bNephrology and Dialysis Unit, ASL 13, Borgomanero, Italy

Reference

1. Majbar MA, Souadka A, Sabbah F, Raiss M, Hrorra A, Ahallat M. Peritoneal echinococcosis: anatomoclinical features and surgical treatment. *World J Surg* 2012;**36**:1030–5.

Raffaella Lissandrin^{a,*}
Silvano Agliata^b
Enrico Brunetti^a

*Corresponding author
E-mail address: raffaella.lissandrin@unipv.it
(R. Lissandrin).

Corresponding Editor: Eskild Petersen, Skejby, Denmark

Received 2 November 2012

Accepted 2 November 2012