

# Trichobezoars in children: therapeutic complications

*Tricobezoario nel bambino: complicanze terapeutiche*

A. Mariotto,<sup>1</sup> M. Peretti,<sup>1</sup> G. Scirè,<sup>1</sup> A. Mantovani,<sup>1</sup> S. Zambaldo,<sup>1</sup> E. Pani,<sup>1</sup> F. Saverio Camoglio,<sup>1</sup> L. Giacomello<sup>1</sup>

**Key words:** *Trichobezoar, endoscopy, abdominal pain*

## Abstract

Trichobezoars are concretions formed by the accumulation of hair or fibers in the gastrointestinal tract, usually associated with underlying psychiatric disorders in females between 13 and 20 years old. Endoscopy, the gold standard for diagnosis, brings some additional advantages: sample taking, size reducing and, rarely, mass removal. This study shows that endoscopy can cause severe complications resulting in a surgical emergency.

## Riassunto

Il tricobezoario è una concrezione formata dall'accumulo di capelli o fibre nel tratto gastrointestinale, solitamente associato a patologie psichiatriche in ragazze tra i 13 e i 20 anni. L'endoscopia, gold standard per la diagnosi, apporta alcuni vantaggi: il prelievo di un campione, la riduzione delle dimensioni e, raramente, la rimozione della massa. Questo studio dimostra che l'endoscopia può causare gravi complicanze che comportano un intervento chirurgico d'urgenza.

## Introduction

Bezoars are concretions formed in the gastrointestinal tract by gradual accumulation of non-absorbable food or fibers. There are dif-

ferent types of bezoars, according to their constitutive material: trichobezoar, phytobezoars, lactobezoars, or any indigestible material. Trichobezoars, hair or hair-like fibers, are associated with underlying psychiatric disorders<sup>1,2</sup> and most cases are reported in females, between 13 and 20 years of age.<sup>1</sup>

Clinical manifestations depend on the bezoar's location and size.<sup>3</sup> Affected patients can remain asymptomatic for many years, till the bezoar increases in size to the point of intestinal obstruction. Abdominal pain, nausea and vomiting, obstruction, and peritonitis are the most common presentation.<sup>1</sup>

In a lot of cases trichobezoar is confined within the stomach, but in some cases extends from the stomach to the small intestine (even colon). This is an unusual and rare form called Rapunzel syndrome.<sup>4</sup>

Endoscopy is the gold standard for diagnosis and brings some additional advantages: sample taking, size reducing and, rarely, mass removal. Laparotomy is still the treatment more frequently chosen, though.<sup>5</sup>

## Case report

A 10-year-old female, born at 40-week gestations, presented to the emergency room with a poorly localized abdominal pain from the morning.

She was alert and responsive, she had good general physical conditions, normal thoracic and cardiovascular examination, treatable abdomen, but mild abdominal tenderness in the right abdominal quadrants. A palpable mass of about 4x6 cm was recognized in the epigastrium. Peristalsis was present, liver and spleen within the limits. The rest of the physical examination was normal. Parents reported early satiety and no changes in her bowel habits. There was no history of acid reflux, diarrhea, increased flatulence, recent illnesses or fever.

The Pediatric Surgeon required urgent blood examination, plain radiograph and ultrasound (US) of the abdomen. Blood tests were normal. Plain radiograph of the abdomen showed a moderate dis-

<sup>1</sup> Unità Operativa di Chirurgia Pediatrica, Dipartimento di Chirurgia, Università di Verona, Verona

Indirizzo per la corrispondenza (Corresponding author):

Dott. Luca Giacomello

Unità Operativa di Chirurgia Pediatrica, Dipartimento di Chirurgia,

Università di Verona

Policlinico G.B. Rossi

P.Le L.A. Scuro, 10 - 37134 Verona

Fax: +39 045 8126757

E-mail: giacomelloluca@hotmail.com

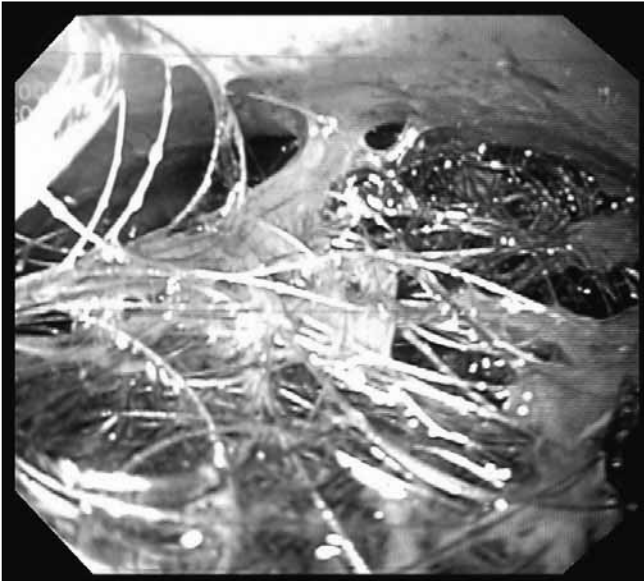


Figure 1.

Trichobezoar in the stomach seen at endoscopy

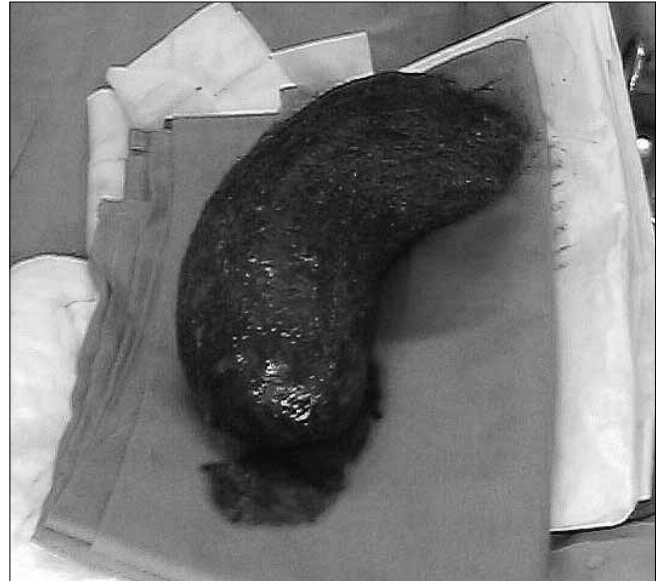

Figure 2.

Trichobezoar extracted from the stomach

tension of the stomach, almost completely occupied by a non-homogenous radio-opaque material. Insignificant air-fluid levels or subdiaphragmatic free air in standing. Although limited by meteorism, ultrasound did not show any abnormalities. Urgent abdominal computed tomography (CT) with contrast showed a 13x6x4 cm mass into the lumen of the stomach. An upper gastrointestinal endoscopy was performed to identify the origin of the mass, to try the reduction in size and to provide for its removal.[Figure 1] During the execution of the procedure, the endoscope wedged in the mass occupying the stomach. Therefore, a gastrotomy was performed in emergency to remove the tool manually. The foreign body was taken away in one piece without any other complications.[Figure 2] The histological examination described a brownish, hard consistent, 15x7x3.5 cm mass, including hair and food material. It confirmed the diagnosis of trichobezoar. From direct interview with parents and the anamnesis, a history of trichophagia and a picture of obsessive-compulsive disorder (OCD) emerged. The patient admitted that she liked eating hair. After surgery the patient was treated with antibiotics, analgesic drugs and TPN for 8 days; she was discharged home 10 days later, having recovered without complications. Psychiatric follow-up was arranged.

## Discussion

Bezoars are masses of non-absorbable food or fibers, progressively accumulated in the gastrointestinal tract.

The first case of human bezoar was described in 1779 during an autopsy of a patient who died from gastric perforation and peritonitis.<sup>1</sup>

Based on their composition, bezoars are classified into phytobezoars (composed of vegetable or fruit fibers), trichobezoars (balls of hair or hair-like fibers), diospyrobezoars (of persimmon), pharmacobe-

zoar (of pills), lactobezoars (of milk curd), lithobezoars (fragments of stones) or plasticobezoars (plastic).<sup>2,6,7</sup>

Gastric trichobezoar represents 50% of all bezoars, and the incidence in the general population varies from 0.4% to 1%. However, as the condition occurs mainly in patients with psychiatric disorders, it is possible that this incidence is underestimated.<sup>7</sup> Most cases of trichobezoar are reported in females, between 13 and 20 years of age.<sup>1</sup>

Bezoars are usually detected in patients with prior gastric surgery, because it reduces gastric motility and delays gastric emptying.<sup>3</sup> Otherwise, trichobezoars are associated with underlying psychiatric disorders, predominantly founded in emotionally disturbed or mentally retarded youngsters. Most patients with trichobezoars suffer from trichotillomania (an "impulse control disorder" characterized by an irresistible, intense urge to pull out hair) and trichophagia.<sup>1,6,8</sup> Rarely they chew hair from other sources, including hair from wigs.<sup>6,8</sup> Trichobezoar occurs in 1% of patients with trichophagia. It forms because hair escapes from peristaltic propulsion due to their slippery surface, and is retained in the folds of the gastric mucosa.<sup>1,2</sup> As hair accumulates, a single solid mass forms, assuming the shape of the stomach. The patient's breath acquires a putrid smell due to the decomposition and the fermentation of fats. The acid secretions of the stomach denature hair's proteins and make black the bezoar.<sup>1</sup>

Clinical manifestations depend on the location of the bezoar.<sup>3</sup> Reviews showed that epigastric pain (70.2%), epigastric mass (70%), nausea and vomiting (64%), hematemesis (61%), weight loss (38%), diarrhea and constipation (32%) are the most common symptoms; while other patients can remain asymptomatic.<sup>1</sup> Less frequently, it is associated with weight loss, anorexia, hematemesis, protein-losing enteropathy, iron deficiency, and megaloblastic anemia.<sup>1,7</sup>

When not recognized, the trichobezoar grows in size and weight, increasing the risk of gastric mucosal erosion, ulceration and stomach or small intestine perforation. These complications are caused by the reduction of the blood supply to the mucosa of the stomach

and part of the intestine. Acute pancreatitis, gastric emphysema and, less frequently, intussusception, obstructive jaundice and death, have been reported in the literature.<sup>1,4</sup> Small bowel obstruction is a rare complication caused by the migration of gastric bezoars to the small bowel by fragmentation of a portion, extension or total translocation or by a primary localized bezoars in the small bowel.<sup>2,3</sup> Usually, this circumstance occurs in association with underlying diseases such as diverticulum, stricture or tumor.<sup>3</sup>

In the early stages, most trichobezoars are not recognized, due to their nonspecific presentation or lack of symptoms. Severe halitosis, patchy alopecia, a previous history of trichotillomania and trichophagia may suggest a diagnosis of trichobezoar.<sup>6,7</sup> At the physical examination, an abdominal mass can be found. Imaging (X-ray, US, CT) may show a mass or filling defect, but the gold standard for diagnosis is upper gastrointestinal endoscopy. Besides direct visualization, this procedure allows sample taking to determine the composition of the mass, size reducing and potential therapeutic intervention.<sup>1,2</sup>

The adopted therapeutic approach (endoscopy, laparoscopy or laparotomy) depends on the bezoar consistence, size and location. Phytobezoars (vegetables made) and lactobezoars (milk-made) can be easily treated endoscopically, while trichobezoars, especially the very large ones (>20 cm), usually require a surgical intervention. Specialized medical devices can fragment trichobezoars, either mechanically or with acoustic waves, in order to facilitate their surgical or endoscopic removal.<sup>1,4</sup>

Surgery is indicated in Rapunzel syndrome, in case of very large size bezoars or when severe complications occur (perforation or hemorrhage). Laparoscopy is performed in case of small to moderate-size bezoars.<sup>1</sup>

Endoscopic removal is the most attractive choice for its treatment; however, successful endoscopic removals are remarkably scarce (5%).<sup>4,5</sup> The size, density and hardness of the mass often make the fragmentation impossible and endoscopy not a viable therapeutic option.<sup>4</sup> Various techniques are used to break up large and solid bezoar: bezotomes and bezotrippers, biopsy forceps, enzyme injection, high-pressure water spray and lithotripsy, paraffin, cellulose, acetylcysteine, Coca-Cola lavage, and even lasers.<sup>1-5,9</sup> However, the repeated introduction of the endoscope and its manipulation could bring severe complications, such as esophageal ulceration or perforation, esophagitis and intestinal obstruction due to the migrations of fragments.<sup>4,5</sup>

Nowadays laparoscopic removal is not a tempting therapeutic choice. Many disadvantages, as spilling contaminated hair fragments into the abdominal cavity and the difficulty to remove the mass, may undermine positive clinical resolution.<sup>4</sup> However, innovative laparoscopic techniques to treat gastric trichobezoar are at stake.<sup>5,10</sup> They consist in removing the mass laparoscopically through a gastrotomy in a water-impervious bag<sup>10</sup> or using a laparoscopic-assisted techniques to provide an excellent access to the stomach and remove as quick and safe as possible the mass.<sup>5</sup> These studies confirm the advantages of laparoscopic-assisted procedures in reducing the operative complications and the operative time, and in avoiding the risk of peritoneal contamination.<sup>5,10</sup> However, the lack of invasiveness of endoscopy or

laparoscopy does not outweigh the disadvantages and the complexity of these procedures.<sup>4</sup>

Laparotomy is the treatment more frequently chosen: it is 100% effective, rarely complicated and it allows a careful examination of the entire gastrointestinal tract.<sup>5</sup>

Besides dissolution or removal, treatment should focus on prevention of recurrence, since elimination of the mass will not alter the conditions contributing to bezoar formation.<sup>2</sup> For these reasons, in addition to the acute surgical treatment, parental counseling, neuropsychiatric treatment, follow-up and behavioral therapy are essential to prevent recurrence.<sup>1,4</sup>

## Conclusions

Trichobezoar is an under-diagnosed entity that has to be considered in the differential diagnosis of abdominal pain and a non-tender abdominal mass in young children.

Endoscopy is a valuable diagnostic modality. In some cases it can be a successful therapeutic approach, in others it can cause severe complications resulting in a surgical emergency.

## References

- Gonuguntla V, Joshi D-D. Rapunzel syndrome: a comprehensive review of an unusual case of trichobezoar. *Clin. Med. Res.* 2009 Sep;7(3):99-102.
- Santiago Sánchez CA, Garau Díaz P, Lugo Vicente HL. Trichobezoar in a 11-year old girl: a case report. *Boletín Asoc. Médica Puerto Rico.* 1996 Mar;88(1-3):8-11.
- Kim JH, Chang JH, Nam SM, Lee MJ, Maeng IH, Park JY, et al. Duodenal obstruction following acute pancreatitis caused by a large duodenal diverticular bezoar. *World J. Gastroenterol. Wjg.* 2012 Oct 14;18(38):5485-8.
- Gorter RR, Kneepkens CMF, Mattens ECJL, Aronson DC, Heij HA. Management of trichobezoar: case report and literature review. *Pediatr. Surg. Int.* 2010 May;26(5):457-63.
- Tudor ECG, Clark MC. Laparoscopic-assisted removal of gastric trichobezoar; a novel technique to reduce operative complications and time. *J. Pediatr. Surg.* 2013 Mar;48(3):e13-e15.
- Sehgal V, Srivastava G. Trichotillomania ± trichobezoar: revisited. *J. Eur. Acad. Dermatol. Venereol.* 2006;20(8):911-5.
- Santos Valenciano J, Nonose R, Bragattini Cruz R, Tiemi Sato D, Monteiro Fernandes F, Fabrício Nascimento E, et al. Tricholithobezoar causing gastric perforation. *Case Reports Gastroenterol.* 2012 Jan;6(1):26-32.
- Morales-Fuentes B, Camacho-Maya U, Coll-Clemente FL, Vázquez-Minero JC. Trichotillomania, recurrent trichobezoar and Rapunzel syndrome: case report and literature review. *Cir. Cir.* 2010 Jun;78(3):265-6.
- Ladas SD, Kamberoglou D, Karamanolis G, Vlachogiannakos J, Zouboulis-Vafiadis I. Systematic review: Coca-Cola can effectively dissolve gastric phytobezoars as a first-line treatment. *Aliment. Pharmacol. Ther.* 2013 Jan;37(2):169-73.
- Shami SB, Jararaa AAM, Hamade A, Ammori BJ. Laparoscopic removal of a huge gastric trichobezoar in a patient with trichotillomania. *Surg. Laparosc. Endosc. Percutan. Tech.* 2007 Jun;17(3):197-200.