

# Non-operative treatment of morton's interdigital neuroma with a foot orthosis

## Abstract

Morton's neuroma is a frequent cause of forefoot sharp pain associated with a burning sensation and paresthesias. Histologic findings of Morton's neuroma include perineural fibrosis of intermetatarsal nerve. Conservative measures are indicated to relieve symptoms and can also increase the gait parameters that require good function of the forefoot. For this study, we chose to use a drop-shaped metatarsal pad and a silicone orthosis, which are both found to be beneficial in treatment of Morton's Neuroma. The ultrasound image showed the disappearance of the anechogenous irregular area between third and fourth metatarsal head of left foot. We have demonstrated that the use of a ultrasound machine is a feasible alternative to conventional processes to validate the foot orthoses. The importance and originality of this study is to show a new effectiveness evaluation approach for the orthotic insoles. Patient reported benefit from foot orthosis, both during sport activity and in everyday life.

Volume 5 Issue 4 - 2018

Lorenzo Brognara, Simone Santarini  
University of Bologna, Italy

**Correspondence:** Lorenzo Brognara, University of Bologna, Biomedical and Neuromotor Sciences, University of Bologna, Bologna, Italy, Tel 00393493084580, Email Lorenzo.brognara2@unibo.it

**Received:** June 01, 2018 | **Published:** July 05, 2018

## Introduction

Morton's Neuroma is a relatively frequent cause of foot pain that can be characterized from both, pain similar to an "electric shock" and burning sensation, generally, at the intermetatarsal space. The interdigital plantar nerve, in the area of the metatarsal heads, is often the most affected and it is a common cause of foot pain. It is most probably a mechanically induced degenerative neuropathy which has a strong predilection for the third common digital nerve, especially in middle-aged women. This condition occurs mainly in adults aged 25 to 50 with a greater incidence in the female sex. Histologically it is possible to recognize the presence of perineural fibrin and hypertrophy of the interdigital nerve associated with a possible edema. The causes of this pathology can be traced back to traumatic factors and to biomechanical factors, due to the onset of deformities such as flatfoot, and/or to insufficiency of the first ray. The aim of this study is to verify whether a foot orthosis, besides helping treatment and rehabilitation of the primitive pathological deformities, can also reduce symptoms in Morton's interdigital Neuroma.<sup>1-9</sup>

The effectiveness has been developed by comparing the medical reports performed by the radiologist before and after the treatment with foot orthosis. The patient reported a general improvement in medical reports after 4 months, using the orthoses. Medical reports stated a general improvement in patients who used the orthoses for 4 months. Orthotics with drop metatarsal pads have proved useful in resolving the symptoms of patients. The plantar orthotic treatment has been associated with the use of digital orthoses created by the podiatrist. The scale (VAS) pre and post-treatment was used to monitor decreasing pain, reported by patients.<sup>9-14</sup>

## Case

### Female at the age of 67

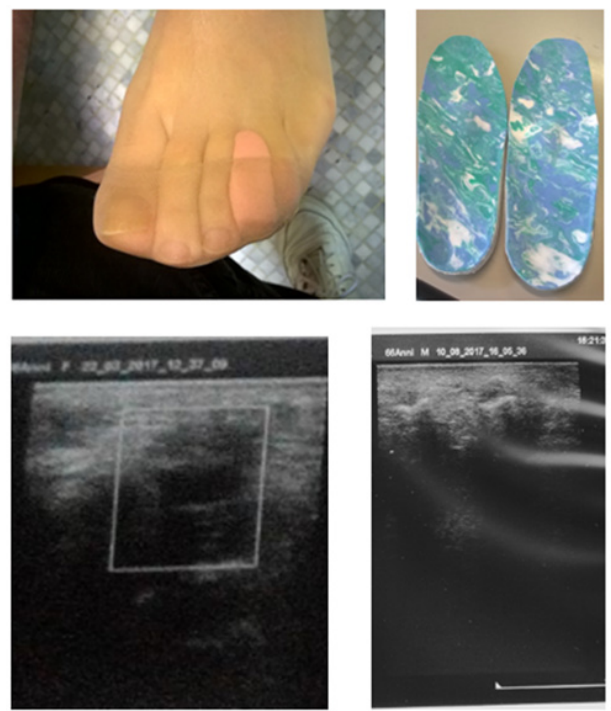
A patient comes to our attention complaining a severe pain associated with a burning sensation in the zone of at the third interdigital space of left foot which arises already from the very first steps: he has been suffering, any time he starts walking, for about two years. Patient reports that to ease the pain she needs to suspend

each activity with the need to massage the interested zone. A reduced sensitivity at the level of the third and fourth ray of the left foot has also recently appeared.

The patient assigns a score of 6/10 (severe pain) of the Visual Analogue Scale (VAS).

The objective examinations points out a bilateral hallux valgus, a flexible plantarflexed first ray and a positive Mulder's Test.

The orthostatic examination underlines a pathological pronation of subtalar joint more accentuated in the left foot (Figure 1).



**Figure 1** Digital and plantar orthotics with medical reports.

## Pre-treatment ecographic examination

The medical report shows the presence of anechogenous irregular area with a size of 10x6mm between third and fourth metatarsal head of left foot. It also highlights the presence of inflammation signs and thickening of capsule joint around IV metatarsal head. It also shows the presence of a thin liquid layer around the head of the IV metatarsal and thickening of the metatarsal-phalangeal joint capsule of the same rays.

In conclusion, there is an area compatible with Morton's localized on third intermetatarsal space of left foot. The orthotic produced has a resin core on which the drop-shaped metatarsal pad is applied. Furthermore, a custom-made silicone orthosis was designed to widen the painful intermetatarsal space.

## Discussion

The above-mentioned clinical case pointed out a pain improvement referred by the patient just after 4 months from the plantar and fingers orthotic therapy performed by the podiatrist (use of the orthotic-plantar and of the fingers therapy applied by the podiatrist).

A further confirmation has also been given by the ultrasound images, in fact, it can be noted that initially there is an anechogenous area of 10 x 6 mm compatible with Morton's Neuroma while in the ultrasound follow-up this area is no longer evident. Thanks to the use of the baropodometric platform, we found an excellent increase in the dynamic functioning of the patient during check-up, as evidenced by the force curves. The patient immediately felt relief in using the orthotic as regards the pain given by the neuroma; it is also important to report that there is a discomfort at the plantar fascia level, most likely due to a change in the foot movement during the step cycle. This discomfort disappeared just after first months of the treatment and the patient refers that later, she has found benefit with both, orthotics and finger orthoses.

## Acknowledgements

None.

## Conflict of interest

The author declares that there is no conflict of interest.

## References

1. RA Mann, JC Reynolds. Interdigital neuroma-a critical clinical analysis. *Foot Ankle*. 1983;3(4):238–243.
2. KK Wu. Morton's interdigital neuroma: a clinical review of its etiology, treatment, and results. *J Foot Ankle Surg*. 1996;35(2):112–119.
3. PP Shapiro, SL Shapiro. Sonographic evaluation of interdigital neuroma. *Foot Ankle Int*. 1995;16(10):606–606.
4. GL Bennett, CE Graham. Morton's interdigital neuroma: a comprehensive treatment protocol. *Foot Ankle*. 1995;16(12):760–763.
5. Sobiesk GA, Wertheimer SJ, Schulz R, et al. Sonographic evaluation of interdigital neuromas. *J Foot Ankle Surg*. 1997;36(5):364–366.
6. IJ Alexander, KA Johnson, JW Parr. Morton's neuroma: a review of recent concepts. *Orthopedics*. 1987;10(1):103–106.
7. TE Kilmartin, WA Wallace. Effect of pronation and supination orthosis on Morton's neuroma and lower extremity function. *Foot Ankle Int*. 1994;15(5):256–262.
8. S Jain, K Mannan The diagnosis and management of Morton's neuroma: a literature review. *Foot Ankle Spec*. 2013;6(4):307–317.
9. B Saygi, Y Yildirim, EK Saygi, et al. Morton neuroma: comparative results of two conservative methods. *Foot Ankle*. 2005;26(7):556–559.
10. EM Diez, SM Mas, JF Pi. Comparative results of two different techniques in the treatment of the Morton's neuroma. *The Foot*. 1999.
11. Di Caprio, F Meringolo, R Eddine, et al. Morton's interdigital neuroma of the foot: A literature review. *Foot and Ankle Surgery*. 2017;24(2):92–98.
12. Lee K, Hwang IY, Ryu CH, et al. Ultrasound-Guided Hyaluronic Acid Injection for the Management of Morton's Neuroma. *Foot Ankle Int*. 2018, 39(2):201–204.
13. Federer Andrew E, Tainter DM, Adams SB, et al. Conservative Management of Metatarsalgia and Lesser Toe Deformities. *Foot Ankle Clin*. 2018;23(1):9–20.
14. Gimber LH, Melville DM, Bocian DA, et al. Ultrasound evaluation of Morton neuroma before and after laser therapy. *AJR Am J Roentgenol*. 2017;208(2):380–385.