



Available online at [www.sciencedirect.com](http://www.sciencedirect.com)

ScienceDirect

journal homepage: [www.elsevier.com/locate/gie](http://www.elsevier.com/locate/gie)



ORIGINAL ARTICLE/ARTICOLO ORIGINALE

CONGRESSO INTERNAZIONALE PARMA 2014 VINCITORE PREMIO FRANCESCO RIITANO

# The impact of endodontic anatomy on clinical practice: a micro-CT study and tribute to Prof. Francesco Riitano



*L'impatto dell'anatomia endodontica sulla pratica clinica: studio micro-tomografico e tributo al Prof. Francesco Riitano*

Nicola Maria Grande<sup>a,\*</sup>, Gianluca Plotino<sup>b</sup>, Raffaele Sinibaldi<sup>c</sup>,  
Gianluca Gambarini<sup>b</sup>, Francesco Somma<sup>a</sup>

<sup>a</sup> *Università Cattolica del Sacro Cuore, Cattedra di Endodonzia, Italy*

<sup>b</sup> *Sapienza Università di Roma, Cattedra di Endodonzia, Italy*

<sup>c</sup> *Multimodal 3D Srl, Rome, Italy*

Received 26 March 2015; accepted 23 April 2015

Available online 12 June 2015

## KEYWORDS

NiTi;  
Mechanical  
instrumentation;  
Micro-tomographic  
analysis;  
Root canal  
instrumentation;  
Single file techniques.

## Abstract

**Aim:** To evaluate the quality of root canal preparation using two different mechanical NiTi systems.

**Methodology:** 40 maxillary and mandibular molars were selected. Specimens were randomly assigned to two groups and were scanned using a micro-computed tomography scanner before and after root canal preparation that was performed using ProFile instrument sequence and Reciproc single file technique. Each system was used to obtain an optimal apical size for each specimen, following common clinical guidelines. 3D models were reconstructed and evaluated for volume, areas and root canal axis. The total volume of dentine removed and the volume of the coronal, middle and apical thirds of each root canal were calculated, as well as the average deviation of the root canal axis at different levels and the values compared. Student *t*-test was

\* Corresponding author at: Via Calalzo 51, 00135 Roma, Italy.

Tel.: +39 3270081231; fax: +39 0688644341.

E-mail: [nmgrande@gmail.com](mailto:nmgrande@gmail.com) (N.M. Grande).

Peer review under responsibility of Società Italiana di Endodonzia.



Production and hosting by Elsevier

<http://dx.doi.org/10.1016/j.gien.2015.05.001>

1121-4171/© 2015 Società Italiana di Endodonzia. Production and hosting by Elsevier B.V. All rights reserved.

**PAROLE CHIAVE**

Nickel titanio;  
Preparazione canalare  
meccanica;  
Analisi micro-  
tomografica;  
Preparazione  
endodontica;  
Single file technique.

used to determine the difference between the two experimental groups ( $P < 0.05$ ). A qualitative evaluation of root canal preparation was also performed.

**Results:** No statistically significant differences were noted between the groups in the volume of dentine removed after root canal preparation, except for the volume of the coronal third ( $P < 0.05$ ) and the volume of the apical third ( $P < 0.05$ ) of the disto-buccal canal of maxillary molars and in the mesial canals of mandibular molars, where ProFile instruments produced significantly less enlarged canal volume in the apical third and more enlarged canal volume in the coronal third ( $P < 0.05$ ). No statistically significant differences were found in the root canal axis deviation.

**Conclusions:** Under the conditions of this study, both the systems analyzed were able to prepare molar teeth with similar amount of dentine removal and a relatively low risk of procedural errors.

© 2015 Società Italiana di Endodonzia. Production and hosting by Elsevier B.V. All rights reserved.

**Riassunto**

**Obiettivi:** L'obiettivo del presente lavoro è stato quello di rendere possibile mediante l'uso di un software realizzato dagli Autori la visualizzazione e la quantificazione delle modifiche prodotte da diverse tipologie di strumenti endodontici sull'anatomia originale dei canali radicolari, utilizzando una analisi alla micro-tomografia computerizzata (MCT).

**Materiali e metodi:** 40 elementi dentari sono stati analizzati mediante l'uso di uno scanner micro-tomografico prima e dopo due tipologie di preparazione canalare, sequenza di strumenti Profile in approccio crown-down e *Single Instrument Technique* Reciproc. Dopo l'acquisizione un algoritmo appositamente sviluppato ha reso possibile la precisa sovrapposizione delle scansioni, in modo da poter apprezzare e misurare l'influenza delle procedure. Un altro algoritmo ha permesso il preciso riconoscimento della componente endodontica, così da poter calcolare e misurare lo spostamento del centro di massa dei canali e del relativo asse, la quantità e la percentuale della dentina rimossa dalla strumentazione e la localizzazione delle zone di contatto strumento/canale.

**Risultati:** Non ci sono state differenze statisticamente significative tra i due gruppi per la maggior parte dei parametri analizzati, eccetto che per il volume nel terzo coronale e per il volume del terzo apicale delle radici disto-buccali dei molari superiori e delle radici mesiali dei molari inferiori analizzati, dove il gruppo dei ProFile ha prodotto una maggiore rimozione di dentina nel terzo coronale e una minore nel terzo apicale. Non sono state riscontrate differenze statisticamente significative per il grado di deviazione dell'asse originale del canale radicolare ( $P < 0.05$ ).

**Conclusioni:** Dai risultati emersi nel presente studio si evince che entrambi i sistemi analizzati sono in grado di realizzare preparazioni canalari adeguate e con un rischio relativamente basso di errori procedurali.

© 2015 Società Italiana di Endodonzia. Production and hosting by Elsevier B.V. Tutti i diritti riservati.

**Introduction**

Investigations and researches on root canal and radicular anatomy laid the foundations of modern endodontic science. These studies started in 19th century with pioneer researchers as Preiswerck, Hess and Keller who described with fine detail more than 100 years ago the real internal anatomy of the teeth and many of the possible variations that it can present.<sup>1,2</sup> Nevertheless the clinical practice in endodontics has often been influenced by the radiographical appearance and by clinical anecdotes more than by the observation of the real anatomy using a three-dimensional approach, as it has been underlined several times by Dr. Riitano during the last three decades.<sup>3-6</sup>

The aim of this paper has been to visualize and measure the effect of different root canal preparation procedures on the original endodontic anatomy using an innovative and original software conceived by the authors<sup>7</sup> to analyze the

$\mu$ CT data obtained from pre-operative and post-operative microtomographic non-destructive high definition scans of molar human teeth treated with different preparation techniques.

**Materials and methods**


20 extracted maxillary first and second molars and 20 mandibular first and second molars were collected. The specimens were externally cleaned with a manual scaler, disinfected in 0.5% sodium hypochlorite (NaOCl) for 20 min and then stored in saline solution at 5 °C before use. The pulp chambers were accessed conventionally. Scouting procedure was with C+files (Dentsply Maillefer, Ballaigues, Switzerland) size #10; ISO taper was performed up to 1 mm beyond the apical foramen to establish apical patency. The teeth without an apical patency were excluded from the study. Canal

lengths were determined using size 10 C+files and an apex locator (RayPex 6, VDW, Munich, Germany); the teeth were embedded in alginate and the working length (WL) was established using the Apex Locator connected to the scouting file and to the embedding media; the length was recorded and confirmed radiographically.

The 20 maxillary and 20 mandibular molars were divided in two groups and assigned to two different instrumentation techniques; the Group 1 was instrumented using a single instrument reciprocating file (Reciproc R25, VDW, Germany), following the manufacturer instruction as already reported in the literature<sup>8</sup>; when the apical dimension of the preparation was considered insufficient a bigger file (Reciproc R40, VDW, Germany) was used till the working length previously established.

Specimens of the Group 2 were prepared using ProFile (Dentsply Maillefer, Ballaigues, Switzerland) NiTi rotary files. A basic sequence of files used in crown-down approach was used to size of #25 taper.06 and then an apical preparation was performed to a size ranging from #30 taper.04 prep to #40 taper.04 according to the estimated anatomical apical size.

The specimens have been processed with a  $\mu$ CT scanner (SkyScan 1074) and scanned before and after the preparation with an isotropic voxel size of  $15\ \mu\text{m}$ , as already described in the literature by the authors.<sup>9</sup> The cross-section images obtained consisted of a series of axial sections of  $1024 \times 1024$  voxels (Fig. 1). An algorithm specifically developed by the authors permitted the exact co-registration, the visualization and the quantifications of the variables chosen as significant of an ideal root canal preparation. A particular attention has been given in the development of a user friendly but precise and efficient software for the co-registration of the different scans, because this is essential to appreciate the differences among the slices in the exact position and measure the impact of the root canal preparation procedures on the original untouched anatomy (Fig. 2). Another algorithm realizes the identification of the endodontic structures, and the recognition of the root canal axis, thus permitting the analysis of the deviation of the original root canal center of mass and the related root canal axis. Canal transportation was assessed from centers of mass that were calculated for each slice and connected along the vertical axis with a fitted line. Transportation was then calculated by comparing the centers of mass before and after treatment for the apical, middle, and coronal thirds of the canals. Moreover the volumes of canals pre-operatively, the volumes of dentin removed by the instruments,




**Figure 1** Axial micro-tomographic ( $\mu$ CT) section of  $1024 \times 1024$  voxels.

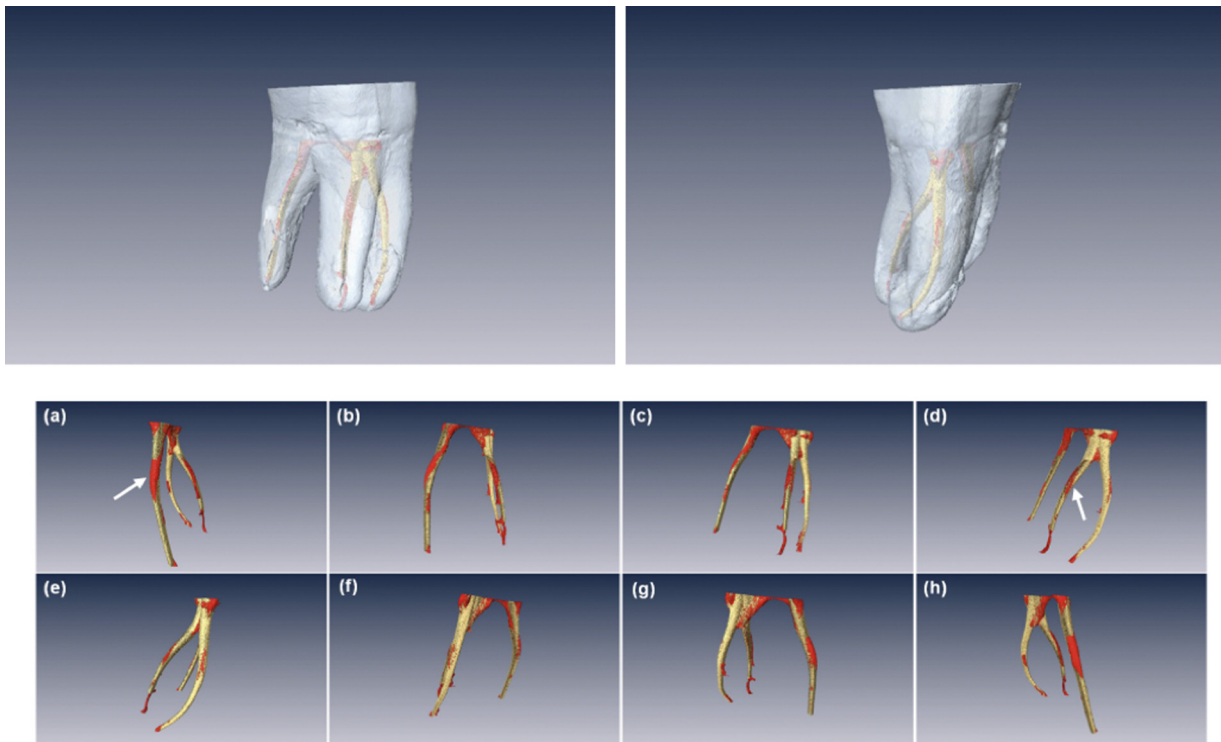
and the untouched root canal surface area was measured for coronal, middle and apical thirds (Figs. 3 and 4). Mean and standard deviations relative to each variable considered were calculated for each group, and one-way analysis of variance was performed to find any significant differences among groups using SPSS 15.0 software for statistical analysis (SPSS Inc., Chicago, IL).

## Results

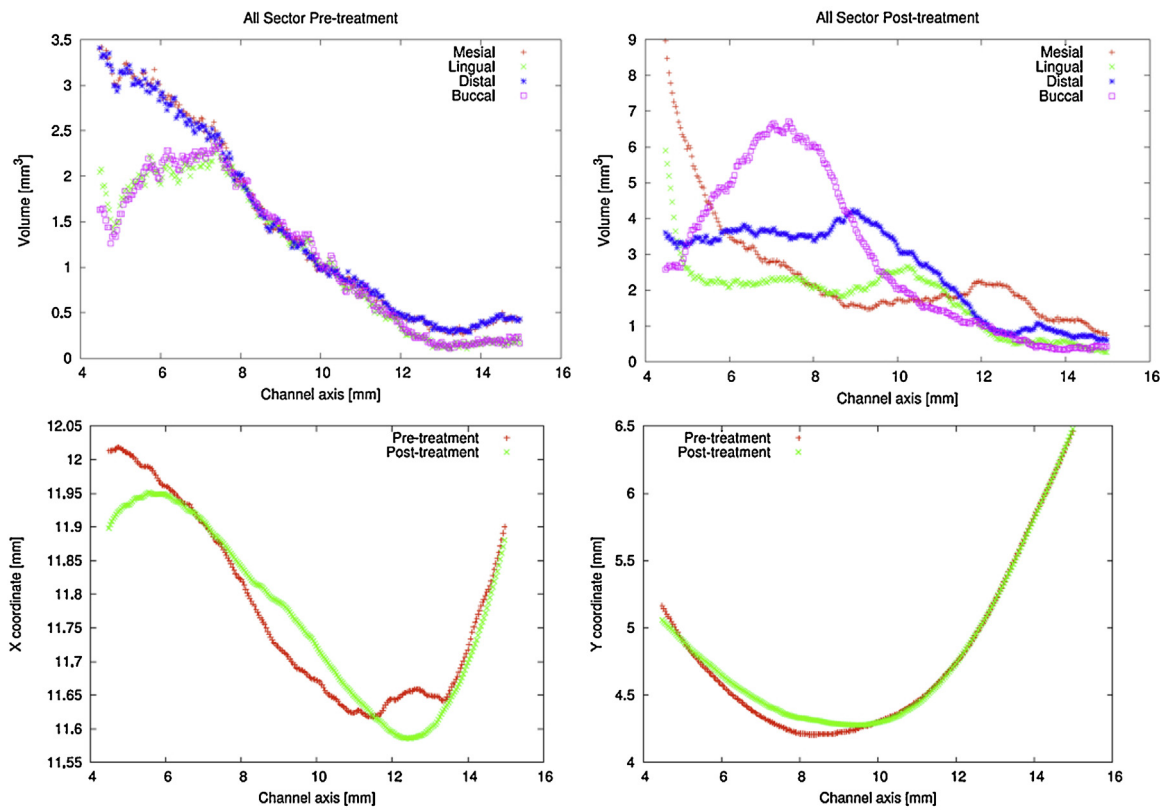
No statistically significant differences were found between the groups in the volume of dentine removed after root canal preparation in all root canals of mandibular and maxillary molars, except for the volume of the coronal third ( $P < 0.05$ ) and the volume of the apical third ( $P < 0.05$ ) of the disto-buccal canal of maxillary molars and in the mesial canals of mandibular molars, where ProFile instruments produced significantly less enlarged canal volume in the apical third and more enlarged canal volume in the coronal third ( $P < 0.05$ ). The results of the total volume of dentine removed are



**Figure 2** Co-registration and three-dimensional repositioning of pre-operative and post-operative  $\mu$ CT scans.



**Figure 3** In yellow the volumes of canals pre-operatively and in red the volumes of dentin removed by the instruments. The untouched root canal surface is evident from the color difference.



**Figure 4** Volumetric and axial changes in root canal axis after root canal instrumentation in one of the specimens analyzed in this research. Transportation was then calculated by comparing the centers of mass before and after treatment.

**Table 1** Volume of dentin removed (VDR), and percentage of uninstrumented canal area (PUCA) (mean  $\pm$  standard deviation).

Group		VDR (mm <sup>3</sup> )	PUCA (%)
Group 1	Reciproc	1.8 $\pm$ 0.9	48 $\pm$ 15.7
Group 2	ProFile	1.2 $\pm$ 1.1	43 $\pm$ 9.4

**Table 2** Canal transportation (expressed in micron) in the different groups for the coronal, middle, and apical thirds after preparation (mean  $\pm$  standard deviation).

Group		Coronal 1/3	Middle 1/3	Apical 1/3
Group 1	Reciproc	43.4 $\pm$ 31.1	38.2 $\pm$ 24.9	23.4 $\pm$ 11.7
Group 2	ProFile	51.4 $\pm$ 33.7	33.2 $\pm$ 19.9	21.4 $\pm$ 9.4

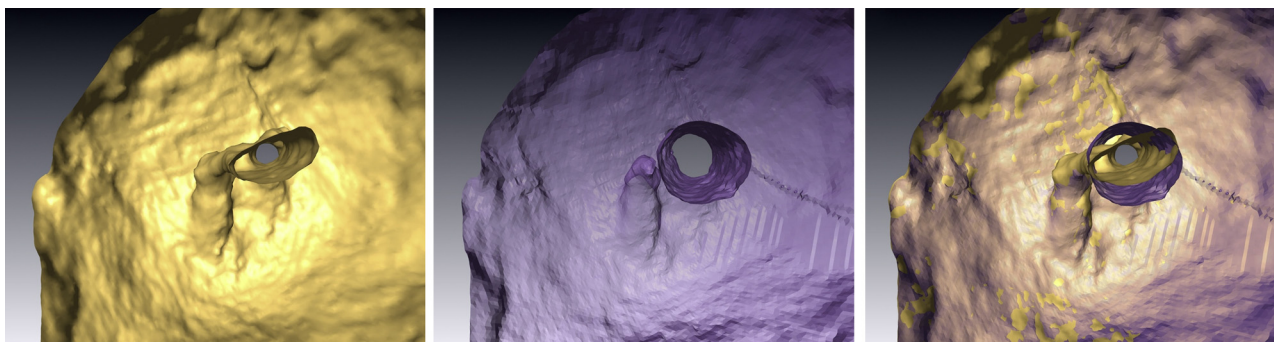
reported in Table 1. No statistically significant differences were found in the root canal axis deviation (Table 2). There were no significant differences between instrument types with regard to uninstrumented area (Table 1). No instruments fractured in Group 1 and only 1 instrument fractured in the Group 2 (size #25 taper.06). Deformations occurred in two ProFile size #25 and #20, taper 0.06 instruments. Qualitative evaluation of the preparations showed that both ProFile and Reciproc were able to prepare root canals in mandibular and maxillary molars with little or no procedural error.

## Discussion

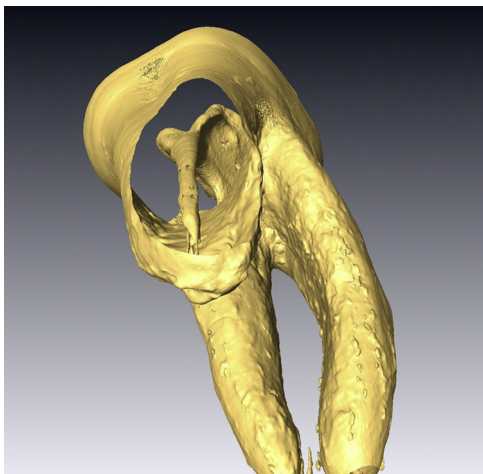
The results obtained in the present study confirm that any technique is able to address mechanically the entire surface of the endodontic space. The extent of the surface contacted by the instruments blades is often a small percentage of the entire root canal surface, confirming the observations already present in the literature.<sup>10</sup> The percentages of prepared root canal surface varied in the present study from a minimum of 56% to a maximum of 87% and although the amount of prepared surface seems to be independent of NiTi rotary instrument type, it seems significantly affected by preoperative canal anatomy, confirming again the data already available in literature.<sup>11–13</sup> The apical preparation was performed following the concept of *Visual Gauging* in

which for each root canal the quality and the amount of dentine removed and embedded on the blades of the instrument was evaluated; the apical size was considered sufficient when a good amount of white sound dentine remained on the blade of the final master apical file. Following this approach the amount of root canal surface contacted by the instruments on the apical area ranged from 69% to 92% and even if there were no statistically significant differences the results seem to be promising, even if other studies are required to understand better the value of the *Visual Gauging* concept. The differences in dentinal volume removed in the coronal third ( $P < 0.05$ ) and in the apical third ( $P < 0.05$ ) of the distobuccal canal of maxillary molars and in the mesial canals of mandibular molars can be explained with the more circular shape of these canals if compared with the other root canals anatomy. In this kind of root canal the differences could be observed between a series of files with continuous taper (ProFile) and a single file technique with variable taper, that is able to perform a wide deep shaped preparation maintaining a certain amount of dentinal tissue in the coronal thirds.

From a more careful analysis of the results there are two main observations that can be made and that can be found formerly in Dr. Riitano's scientific production,<sup>3–6</sup> although it was not carried out with the latest advancements in research techniques that today are available, such as the microtomography, that can be considered today as the gold standard for studying the effect of root canal instrumentation on the original root canal anatomy.<sup>14</sup> The first observation is linked with the diameters of the apical preparation, considering that root canal disinfection appears to be critical for endodontic outcome; the eradication of microorganisms occurs from a combination of mechanical preparation and irrigation. Irrigation alone is not effective, and mechanical disinfection, which is related to removal of a layer of infected dentin, is required especially in the apical areas.<sup>15,16</sup> This is particularly hard to achieve in the apical third when preparing oval and curved root canals. An adequate apical preparation should permit the instrument to contact for 360° the perimeter of the root canals, this aim being easier to achieve in the last millimeters of the apical third, because, although root canals are not perfectly round even in this area, the ratio between mesio-distal and bucco-lingual diameters still permits in the majority of cases, in which apical resorption has not destroyed the anatomical structures, to contact the perimeter of the main root canal<sup>15,17,18</sup> (Figs. 5–7). The goal



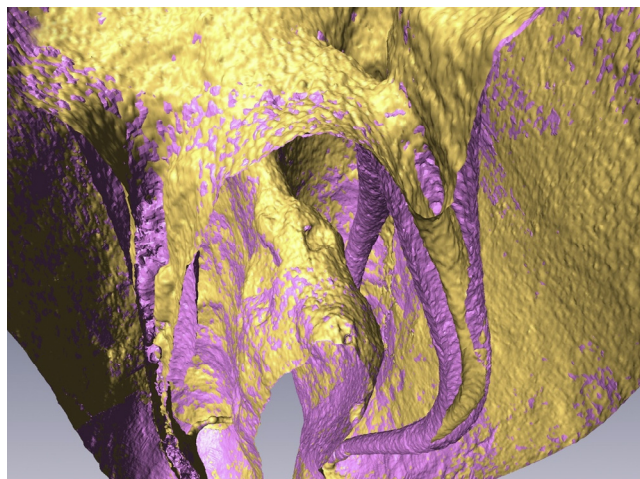
**Figures 5, 6, 7** Three-dimensional reconstruction of the apical area of distal root and root canal of a lower mandibular molar and their superimposition, before the instrumentation in yellow and after the instrumentation in pink.



**Figure 8** Three-dimensional reconstruction of a palatal root canal of first upper molar; the oval extension of the anatomy is evident.

of a round shape of the apical preparation is mandatory even to permit an ideal adaptation of the obturation materials to the root canal walls, and to give an ideal shape of retention during these procedure. The average diameter of preparation appears to be wider than what is commonly suggested in many clinical guide-lines.<sup>19</sup> In molars an apical enlargement up to 0.35 or 0.40 mm as a master apical file is often necessary, that was an indication that Dr. Riitano was suggesting more than two decades ago, and that today is gaining more and more credit among the endodontic scientific community.<sup>15,17,18</sup> Consequently even the manufacturers are proposing wider diameter instruments as optional files to achieve an optimal apical preparation.<sup>20</sup>

The second observation that evidently refers to Riitano's works is the importance of the bucco-lingual diameter during the instrumentation of the root canals (Figs. 8 and 9). This aspect is often disregarded in modern endodontics especially



**Figure 9** Superimposition of three-dimensional reconstructions in first lower molar virtually sectioned in mesio-distal direction, before the instrumentation in yellow and after the instrumentation in pink.

after the appearance on the market of the first NiTi rotary files. The use of files that work in complete rotation and that in the first decade of their use, till the introduction of more active geometries, were suggested to be handled without brushing lateral movements, created many times the belief that a "key-hole" preparation was possible and ideal to achieve. This kind of preparation with high taper in the coronal portion and small diameters of apical preparation can deal with good radiographic results but often without addressing uninstrumented recesses and lateral oval extensions, irrespective of the instrumentation technique, thus leaving debris and unprepared root canal surfaces behind.<sup>21,22</sup> The concept of a perimetral contact maintaining the anatomical geometry, that in coronal third appears to be mainly oval or long oval<sup>17</sup> was a firm conviction of Dr. Francesco Riitano<sup>3-6,23</sup>; this pioneering vision started more than 50 years ago and today has found the scientific justification so that even manufacturers invested many efforts in producing instruments as Self Adjusting File (SAF)<sup>22,24-26</sup> that has in this vision its main strength and it has been widely supported by scientific researches.<sup>22,24-26</sup> In the present study the areas with a greater lack of surface contact were present mainly in the coronal and medium thirds of the root canals, confirming these latter observations.

## Conclusions

Under the conditions of the present study, both the rotary files systems analyzed were able to prepare molar teeth with similar amount of dentine removal and low risk of procedural errors.

## Clinical relevance

The anatomy is the main variable to be considered as factor to obtain successful endodontic therapies, many concepts that can be studied with the latest technologies, were often already addressed with less sophisticated techniques and acute observations by our predecessors as Dr. Francesco Riitano.

## Conflict of interest

The authors have no conflict of interest to declare.

## Acknowledgements

The authors thank Dr. Giuseppina Riitano in invaluable help in literature search and in building up the manuscript, together with Dr. Renato Gullà, Dr. Luciano Giardino and Dr. Giovanni Mura.

## References

1. Hess W. Zur Anatomie der Wurzelkanäle des menschlichen Gebisses mit Berücksichtigung der feineren Verzweigungen am Foramen apicale. *Schweiz Vierteljahrsschr Zahnheilkd* 1917;27: 1-34.
2. Preiswerk: *Lehrbuch und atlas der zahnheilkunde mit einschluß der Mund-Krankheiten*. J.F. Lehmann Verlag; Munchen; 1903.

3. Riitano F. Automatic instrument for alternate irrigation of different liquids with simultaneous aspiration in endodontic treatment of root canals. *Ann Stomatol* 1974;**23**:35–44.
4. Riitano F. Fundamental concepts and instruments in endodontics. *Mondo Odontostomatol* 1976;**18**:28–43.
5. Riitano F. The 3-stages method. *Dent Cadmos* 1976;**44**:10–20.
6. Riitano F. Anatomic endodontic technology (AET) – a crown-down root canal preparation technique: basic concepts, operative procedure and instruments. *Int Endod J* 2005;**38**:575–87.
7. Sinibaldi R, Conti A, Pecci R, Plotino G, Guidotti R, Grande NM, et al. Software tools for the quantitative evaluation of dental treatment effects from  $\mu$ CT scans. *J Biomed Graph Comput* 2013;**3**:85–100.
8. Plotino G, Grande NM, Porciani PF. Deformation and fracture incidence of Reciproc instruments: a clinical evaluation. *Int Endod J* 2015;**48**:199–205.
9. Plotino G, Grande NM, Pecci R, Bedini R, Pameijer CH, Somma F. Three-dimensional imaging using microcomputed tomography for studying tooth macromorphology. *J Am Dent Assoc* 2006;**137**:1555–61.
10. Paque F, Barbakow F, Peters OA. Root canal preparation with Endo-Eze AET: changes in root canal shape assessed by micro-computed tomography. *Int Endod J* 2005;**38**:456–64.
11. Peters OA, Sch€onenberger K, Laib A. Effects of four NiTi preparation techniques on root canal geometry assessed by micro computed tomography. *Int Endod J* 2001;**34**:221–30.
12. Hubscher W, Barbakow F, Peters OA. Root canal preparation with FlexMaster: canal shapes analysed by micro-computed tomography. *Int Endod J* 2003;**36**:740–7.
13. Peters OA, Peters CI, Schonenberger K, Barbakow F. ProTaper rotary root canal preparation: assessment of torque and force in relation to canal anatomy. *Int Endod J* 2003;**36**:93–9.
14. Grande NM, Plotino G, Gambarini G, Testarelli L, D'ambrosio F, Pecci R, et al. Present and future in the use of micro-CT scanner 3D analysis for the study of dental and root canal morphology. *Ann Ist Super Sanità* 2012;**48**:26–34.
15. Baugh D, Wallace J. The role of apical instrumentation in root canal treatment: a review of the literature. *J Endod* 2005;**31**:333–40.
16. Evans GE, Speight PM, Gulabivala K. The influence of preparation technique and sodium hypochlorite on removal of pulp and pre dentine from canals of posterior teeth. *Int Endod J* 2001;**34**:322–30.
17. Wu MK, R'oris A, Barkis D, Wesselink PR. Prevalence and extent of long oval canals in the apical third. *Oral Surg Oral Med Oral Pathol Oral Radiol Endod* 2000;**89**:739–43.
18. Wu MK, Wesselink PR, Walton RE. Apical terminus location of root canal treatment procedures. *Oral Surg Oral Med Oral Pathol Oral Radiol Endod* 2000;**89**:99–103.
19. Buchanan LS. The standardized-taper root canal preparation – Part 1. Concepts for variably tapered shaping instruments. *Int Endod J* 2000;**33**:516–29.
20. Haapasalo M, Shen Y. Evolution of nickel–titanium instruments: from past to future. *Endod Top* 2013;**29**:3–17.
21. Wu M-K, van der Sluis LW, Wesselink PR. The capability of two hand instrumentation techniques to remove the inner layer of dentine in oval canals. *Int Endod J* 2003;**36**:218–24.
22. Peters OA, Paque F. Root canal preparation of maxillary molars with the self-adjusting file: a micro-computed tomography study. *J Endod* 2011;**37**:53–7.
23. Grande NM, Plotino G, Butti A, Messina F, Pameijer CH, Somma F. Cross-sectional analysis of root canals prepared with NiTi rotary instruments and stainless steel reciprocating files. *Oral Surg Oral Med Oral Pathol Oral Radiol Endod* 2007;**103**:120–6.
24. Metzger Z, Teperovich E, Zary R, Cohen R, Hof R. The self-adjusting file (SAF). Part 1: respecting the root canal anatomy, a new concept of endodontic files and its implementation. *J Endod* 2010;**36**:679–90.
25. Kim HC, Sung SY, Ha JH, Solomonov M, Lee JM, Lee CJ, et al. Stress generation during self-adjusting file movement: minimally invasive instrumentation. *J Endod* 2013;**39**:1572–5.
26. Capar ID, Altunsoy M, Arslan H, Ertas H, Aydinbelge HA. Fracture strength of roots instrumented with self-adjusting file and the ProTaper rotary systems. *J Endod* 2014;**40**:551–4.