

ORIGINAL ARTICLE



Safety and Effectiveness of Coronary Intravascular Lithotripsy for Treatment of Severely Calcified Coronary Stenoses

The Disrupt CAD II Study

BACKGROUND: The feasibility of intravascular lithotripsy (IVL) for modification of severe coronary artery calcification (CAC) was demonstrated in the Disrupt CAD I study (Disrupt Coronary Artery Disease). We next sought to confirm the safety and effectiveness of IVL for these lesions.

METHODS: The Disrupt CAD II study was a prospective multicenter, single-arm post-approval study conducted at 15 hospitals in 9 countries. Patients with severe CAC with a clinical indication for revascularization underwent vessel preparation for stent implantation with IVL. The primary end point was in-hospital major adverse cardiac events (cardiac death, myocardial infarction, or target vessel revascularization). An optical coherence tomography substudy was performed to evaluate the mechanism of action of IVL, quantifying CAC characteristics and calcium plaque fracture. Independent core laboratories adjudicated angiography and optical coherence tomography, and an independent clinical events committee adjudicated major adverse cardiac events.

RESULTS: Between May 2018 and March 2019, 120 patients were enrolled. Severe CAC was present in 94.2% of lesions. Successful delivery and use of the IVL catheter was achieved in all patients. The post-IVL angiographic acute luminal gain was 0.83 ± 0.47 mm, and residual stenosis was $32.7 \pm 10.4\%$, which further decreased to $7.8 \pm 7.1\%$ after drug-eluting stent implantation. The primary end point occurred in 5.8% of patients, consisting of 7 non-Q-wave myocardial infarctions. There was no procedural abrupt closure, slow or no reflow, or perforations. In 47 patients with post-percutaneous coronary intervention optical coherence tomography, calcium fracture was identified in 78.7% of lesions with 3.4 ± 2.6 fractures per lesion, measuring 5.5 ± 5.0 mm in length.

CONCLUSIONS: In patients with severe CAC who require coronary revascularization, IVL was safely performed with high procedural success and minimal complications and resulted in substantial calcific plaque fracture in most lesions.

CLINICAL TRIAL REGISTRATION: URL: <https://www.clinicaltrials.gov>. Unique identifier: NCT03328949.

VISUAL OVERVIEW: A [visual overview](#) is available for this article.

Ziad A. Ali, MD, DPhil
Holger Nef, MD, PhD
Javier Escaned, MD, PhD
Nikos Werner, MD, PhD
Adrian P. Banning, MD
Jonathan M. Hill, MD
Bernard De Bruyne, MD, PhD
Matteo Montorfano, MD
Thierry Lefevre, MD
Gregg W. Stone, MD
Aaron Crowley, MA
Mitsuaki Matsumura, BS
Akiko Maehara, MD
Alexandra J. Lansky, MD
Jean Fajadet, MD
Carlo Di Mario, MD, PhD

Key Words: angiography ■ clinical study ■ humans ■ lithotripsy ■ stents

© 2019 The Authors. *Circulation: Cardiovascular Interventions* is published on behalf of the American Heart Association, Inc., by Wolters Kluwer Health, Inc. This is an open access article under the terms of the [Creative Commons Attribution Non-Commercial-NoDerivs License](#), which permits use, distribution, and reproduction in any medium, provided that the original work is properly cited, the use is noncommercial, and no modifications or adaptations are made.

<https://www.ahajournals.org/journal/circinterventions>



WHAT IS KNOWN

- Intravascular lithotripsy is a novel technology, based on an established treatment strategy for renal calculi, delivered via a traditional catheter used to circumferentially modify vascular calcium.
- The Disrupt CAD I study (Disrupt Coronary Artery Disease) demonstrated the feasibility of intravascular lithotripsy in humans for the first time.

WHAT THE STUDY ADDS

- Intravascular lithotripsy was safe, with no reported major dissections (types D–F), perforations, abrupt closure, or slow flow/no reflow.
- In these patients with highly complex coronary lesions, both in-hospital (5.8%) and 30-day (7.6%) major adverse cardiac events were low.
- Optical coherence tomography demonstrated the mechanism of action of intravascular lithotripsy to be intraplaque calcium fracture in ≈80% of patients.

Coronary artery calcification (CAC) hinders percutaneous coronary intervention (PCI) by impairment of device crossing,¹ delamination of drug and polymer from stents,² alteration of elution kinetics and drug delivery,³ and impairment of stent apposition and expansion.⁴ High-pressure noncompliant balloon dilation, specialty balloons (scoring, cutting, ultra-high pressure), and atherectomy are techniques commonly used to facilitate PCI in severe CAC; however, all suffer from significant limitations. Noncompliant balloon dilation, despite high pressures, may be of insufficient force to lead to calcium fracture and thus artery expansion. In the presence of eccentric calcium, balloon dilation may be biased toward noncalcified segments of the artery, leading to dissection at the fibrocalcific interface rather than modification of calcium per se. Specialty balloons, including scoring, cutting, and ultra-high pressure balloons, may be subject to the same limitations as noncompliant balloons with evidence of their safety and effectiveness limited by lack of robust trial data resulting in conservative recommendations for their use in societal guidelines.^{5,6} While laser atherectomy has been used successfully in underexpanded stents,⁷ reports of its use in native severe CAC are limited with guidelines suggesting it as a potential treatment option in moderate but not severe CAC.⁵ Rotational and orbital atherectomy, while highly effective for facilitating lesion crossing, may selectively ablate calcified segments of the artery resulting from guidewire bias,⁸ potentially leaving significant CAC unmodified within the lesion. Periprocedural complications including slow-flow, periprocedural myocardial infarction (MI), complex dissection, and perforation are also known to be significantly

higher with atherectomy compared with balloon-based therapies.^{9–13}

Intravascular lithotripsy (IVL) is a novel technique based on an established treatment strategy for renal calculi, in which multiple lithotripsy emitters mounted on a traditional catheter platform deliver localized pulsatile sonic pressure waves to circumferentially modify vascular calcium. In the Disrupt CAD I study (Disrupt Coronary Artery Disease), we demonstrated the feasibility of IVL to modify vascular compliance in calcific plaque in human coronary arteries for the first time.¹⁴ In the Disrupt CAD II study, we evaluated the safety and effectiveness of IVL for vessel preparation of severe CAC in stenotic de novo coronary lesions before stent implantation and utilized optical coherence tomography (OCT) to examine its mechanism of action and effectiveness.

METHODS

Study Design

Disrupt CAD II was a prospective multicenter, single-arm post-approval study conducted at 15 hospitals in 9 countries designed to assess the safety and performance of the Coronary IVL System to treat calcified, stenotic, de novo coronary lesions before stenting. The study was designed by the principal investigators and sponsor (Shockwave Medical, Inc, Santa Clara, CA). The study was registered at <https://www.clinicaltrials.gov>; unique identifier: NCT03328949. The data, analytic methods, and study materials are proprietary to the sponsor and at this time are not available to nonstudy participants.

Participants

Patients were eligible for enrollment if they had silent ischemia, unstable or stable angina with evidence of myocardial ischemia, or stabilized acute coronary syndrome without elevation in cardiac biomarkers. Participants were required to have a single target lesion requiring PCI with a diameter stenosis ≥50%, lesion length ≤32 mm in native coronary arteries, and severe calcification as determined by the operators, defined as calcification within the lesion on both sides of the vessel assessed by angiography. Participants were excluded if there was planned use of atherectomy, specialty balloons, or investigational coronary devices. Detailed inclusion and exclusion criteria are included in Table I in the [Data Supplement](#). All patients provided written informed consent before enrollment. The study was conducted in accordance with the Declaration of Helsinki, ISO 14155, Good Clinical Practice guidelines, and applicable laws by all related governmental bodies.

Study Device

The coronary IVL catheter is a single-use, sterile, disposable catheter that contains multiple lithotripsy emitters enclosed in an integrated balloon. The emitters generate sonic pressure waves in the shape of a sphere, creating a field effect to treat vascular calcium. The generated sonic pressure waves

selectively disrupt and fracture calcium in situ, altering vessel compliance while minimizing injury and maintaining the integrity of the fibroelastic components of the vessel wall. The IVL catheter is available in 2.5 to 4.0 mm diameters and 12 mm in length. The crossing profiles of the devices were 0.043" for 2.5 to 2.75 mm, 0.044" for 3.0 to 3.5 mm, and 0.046" for 3.75 to 4.0 mm diameter balloons.¹⁵ The IVL catheter is introduced into the target vessel and is positioned across the lesion, using the marker bands as guides, to ensure the circumferential therapeutic field effect created by the emitters is adjacent to the calcium. The IVL catheter is connected via a connector cable to the generator that is preprogrammed to deliver 10 pulses in sequence at a frequency of 1 pulse/s for a maximum of 80 pulses per catheter.

Procedures

A patient was considered enrolled once IVL catheter insertion was attempted. PCI was performed via femoral or radial access with a minimum 6F guiding catheter. The IVL catheter was passed across the lesion over a standard 0.014" guide-wire. If the operator was unable to pass the IVL catheter across the lesion, then an adjunctive tool, that is, buddy wire, small balloon (1.5 mm), or guide catheter extension, was recommended before reinsertion of the IVL catheter, however, ultimately left to the discretion of the operator. Atherectomy was not permitted per protocol. The IVL balloon, sized 1:1 to the reference artery, was inflated to 4 atmospheres, to allow contact with the vessel wall but minimize static barotrauma, and 10 pulses were delivered followed by further dilation to the nominal pressure of 6 atmospheres. The IVL treatment was repeated providing a minimum of 10 pulses in the target lesion with interval deflation to allow for distal perfusion and overlap of calcified segments as needed. If the maximum number of pulses (80 per catheter) were delivered but lesion preparation was incomplete (ie, incomplete expansion of the balloon by angiography), further IVL catheters with the same or different diameter balloon could be used. In addition, different diameter IVL balloons could be used when significant vessel tapering was present throughout the target lesion. The number of catheters was dependent on the lesion length and the diameter of the vessel at each of the treated segments. Subsequent stent implantation and PCI optimization was performed per local standard of care at the discretion of the operator. Dual antiplatelet therapy and other medications were administered per local standard of care. Clinical follow-up was performed by telephone at 30 days.

OCT Substudy Image Acquisition and Analysis

OCT was performed at selected sites using a commercially available frequency domain OCT system (ILUMIEN OPTIS, Abbott Vascular, Santa Clara, CA). Structures were classified according to established OCT reporting standards, and all angles were measured relative to the center of mass of the lumen.¹⁶ Calcific plaque was defined as low-attenuation signal with sharply delineated borders.¹⁶ Details of calcification quantification have been described previously.¹⁷ Briefly, quantitative indices of calcification were evaluated and measured in each OCT frame at 1-mm intervals. Calcium location was defined as superficial if

the luminal leading edge of calcification was located within 0.5 mm from the surface of plaque. Calcification angle was measured using a protractor centered on the lumen. If there were >1 calcium deposits present in a single cross-sectional frame, the angle was defined as the sum of the angles of each individual calcium deposit for that cross section. Maximum calcium angle was recorded for each lesion. Calcium length was determined by identifying the proximal and distal calcium edges and summed if there were multiple separate calcified segments. Calcium thickness was determined as the distance between the luminal edge of the calcium and the outer border of the deposit measured throughout the lesion with the maximum value per lesion recorded. Calcium volume index was then calculated as mean calcium angle (°) × calcium length (mm). Calcium fracture was identified as a new disruption/discontinuity in the calcium sheet identified on OCT post-IVL or stenting. The luminal area was measured by tracing the luminal border on each cross section, which after IVL included marking the lumen contour in continuum with the additional luminal border generated by the fractures, from which the acute luminal gain post-IVL was calculated. To determine the number of fractures per lesion, the fracture lines were traced for continuity frame-by-frame throughout the lesion and cross-checked with the longitudinal OCT image.

End Points and Data Integrity

The primary end point was in-hospital major adverse cardiac events (MACE) defined as cardiac death, MI, or target vessel revascularization. Secondary end points included clinical success, defined as the ability of IVL to produce a residual diameter stenosis <50% after stenting with no evidence of in-hospital MACE, and angiographic success, defined as success in facilitating stent delivery with <50% residual stenosis and without serious angiographic complications (severe dissection impairing flow [type D–F], perforation, abrupt closure, persistent slow flow, or no reflow). MACE was also assessed at 30 days. Periprocedural MI and spontaneous MI used the same definition (peak creatine kinase-MB >3× the upper limit of normal). OCT was used to evaluate the mechanism of action of IVL quantifying CAC characteristics and calcium plaque fracture.

Study monitors assured data accuracy and collected source documents for review. An independent clinical events committee adjudicated all MACEs. An independent angiographic core laboratory analyzed all procedural angiograms (Yale Cardiovascular Research Group, New Haven, CT). Calcification was graded as none or mild, moderate, or severe. Moderate coronary calcium was defined as densities noted only on one side of the arterial wall before contrast injection, whereas severe calcification was defined as radiopacities noted without cardiac motion before contrast injection involving both sides of the arterial wall. Calcium length was measured quantitatively using validated software (QAngio XA [version 7.3]; Medis Medical Imaging System BV, Leiden, the Netherlands). An independent intravascular imaging core laboratory analyzed all OCT images (Cardiovascular Research Foundation, New York, NY), using standard quantitative methods.

Statistical Analysis

Continuous variables are described as mean±SD. Categorical variables are described as proportions. The paired *t* test was

used to compare continuous variables measured pre- and post-treatment on the same patient. Statistical analyses were performed using SAS (SAS Institute, Cary, NC), version 9.4 or higher.

RESULTS

Patients and Procedures

Between May 2018 and March 2019, 120 patients were enrolled at 15 hospitals in 9 countries. Baseline and procedural characteristics are provided in Tables 1 and 2. The left anterior descending artery was the most common target vessel (62.5%). The mean reference vessel diameter (RVD) was 3.04 ± 0.53 mm. The mean minimum lumen diameter was 1.21 ± 0.42 mm with a corresponding percent diameter stenosis on quantitative coronary angiography of $60.0\pm 12.0\%$ and mean lesion length of 19.5 ± 9.8 mm. Severe calcification by angiographic core laboratory analysis was present in 94.2% of the lesions. Calcification was extensive with a mean calcified length by quantitative coronary angiography of 25.7 ± 12.4 mm. Lesions were concentric in 71.7% of cases, and 30.0% had side-branch involvement.

Procedural details are provided in Table 3. Mean overall procedure duration was 68.3 ± 34.2 minutes, with the IVL treatment delivered over 7.9 ± 5.2 minutes. The mean number of IVL catheters used per lesion was 1.2 ± 0.6 . Predilatation to deliver the IVL balloon catheters across the lesion was required in 41.7% of cases. The mean balloon size used for predilatation was 2.2 ± 0.6 mm. Atherectomy was not required in any case. A mean

Table 2. Lesion Characteristics

	n=120
Target vessel	
Protected left main artery	0.8 (1)
Left anterior descending artery	62.5 (75)
Circumflex artery	11.7 (14)
Right coronary artery	25.0 (30)
Reference vessel diameter, mm	3.04 ± 0.53
Minimum lumen diameter, mm	1.21 ± 0.42
Diameter stenosis, %	60.0 ± 12.0
Lesion length, mm	19.5 ± 9.8
Calcified length, mm	25.7 ± 12.4
Severe calcification	94.2 (113)
Lesion assessment	
Concentric	71.7 (86)
Eccentric	28.3 (34)
Side-branch involvement	30.0 (36)

Values are percentage (n) or mean \pm SD.

of 1.3 ± 0.6 drug-eluting stents (DES) were implanted per subject with postdilatation performed in 79.2% of patients at mean 17.4 ± 3.8 atmospheres.

End Points

The in-hospital primary end point occurred in 5.8% of patients, consisting of 7 non-Q-wave MIs. Clinical success was achieved in 94.2% of patients. All patients had a residual stenosis $<50\%$ after stenting. IVL catheter delivery, treatment of the target lesion, and subsequent stent delivery were successful in all patients. Representative examples of the effects of IVL are shown in Figure 1. The post-IVL angiographic acute luminal gain was 0.83 ± 0.47 mm, and residual stenosis was $32.7\pm 10.4\%$, which further decreased to $7.8\pm 7.1\%$ after DES implantation (Table 4). Angiographic success,

Table 1. Baseline and Clinical Demographics

	n=120
Age, y	72.1 ± 9.8
Men	78.3 (94)
Diabetes mellitus	31.7 (38)
Hypertension	80.0 (96)
Hyperlipidemia	71.7 (86)
MI	25.8 (31)
Prior coronary artery bypass grafting	6.7 (8)
Stroke/transient ischemic attack	3.3 (4)
Current smoker	13.3 (16)
Renal insufficiency	8.3 (10)
Angina classification	
Class 0	20.0 (24)
Class I	35.0 (42)
Class II	30.0 (36)
Class III	5.0 (6)
Class IV	1.7 (2)
Not assessed	8.3 (10)

Values are percentage (n) or mean \pm SD. MI indicates myocardial infarction.

Table 3. Procedural Details

	n=120
Total procedure time, min	68.3 ± 34.2
Fluoroscopy time, min	18.0 ± 11.1
Contrast volume, mL	181.9 ± 66.4
Device time, min	7.9 ± 5.2
IVL inflation time, s	84.0 ± 59.7
No. of IVL catheters	1.2 ± 0.6
No. of pulses	70.7 ± 43.4
Maximum IVL inflation pressure, atm	5.8 ± 0.7
No. of stents used	1.3 ± 0.6
Pre-dilatation	41.7 (50)
Post-dilatation	79.2 (95)

Values are percentage (n) or mean \pm SD. atm indicates atmospheres; and IVL, intravascular lithotripsy.

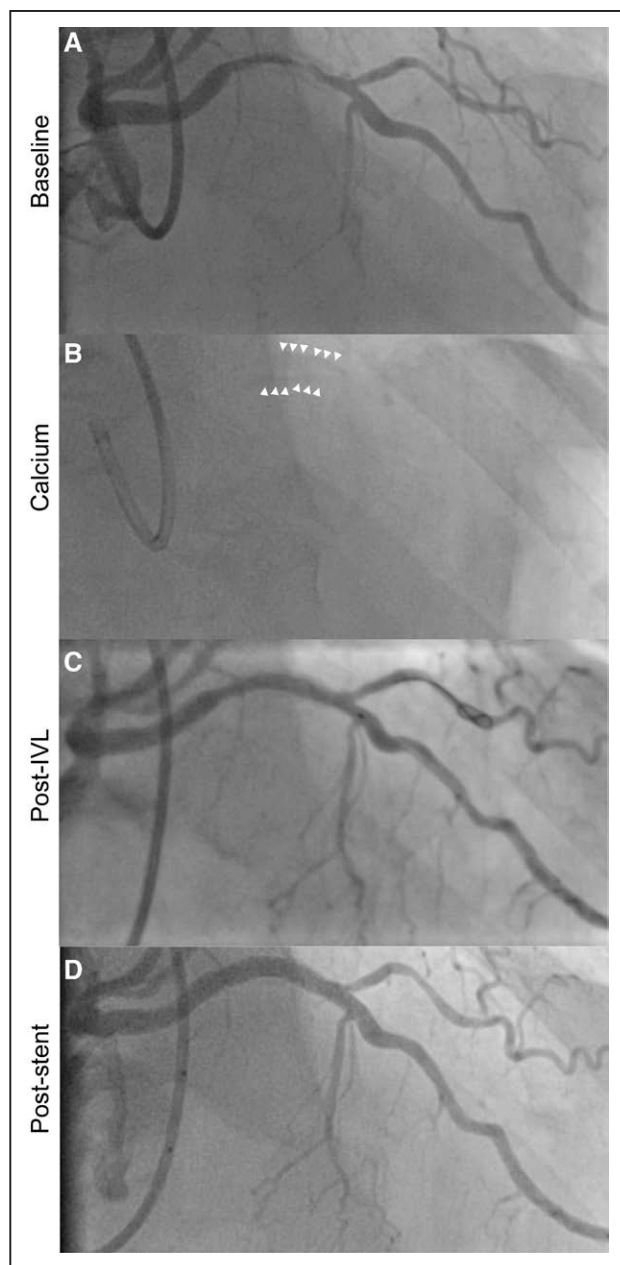


Figure 1. Representative example of Shockwave Intravascular Lithotripsy (IVL) for lesion modification of severe coronary artery calcification.

A, Angiography reveals a left anterior descending lesion with reference vessel diameter of 2.95 mm and 68.1% diameter stenosis by quantitative coronary angiography; **(B)** severe calcification identified by white arrows; **(C)** IVL was completed with a 3.0 mm IVL catheter; and **(D)** final in-stent residual stenosis was 8.8%.

defined as success in facilitating stent delivery with <50% residual stenosis and freedom from perforation, slow flow, no reflow, or type D, E, or F dissection at any point in the procedure, was achieved in all patients. One type B and one type C dissection were identified post-stent IVL and managed conservatively.

The 30-day MACE rate was 7.6% (Table 5). There was 1 cardiac death, 1 Q-wave MI, 7 in-hospital non-Q-wave MIs, and 1 target vessel revascularization during this time

Table 4. Performance Outcomes

	n=120
Clinical success	94.2 (113)
Angiographic success	100.0 (120)
Stent delivery	100.0 (120)
Final in-segment angiographic outcomes (core laboratory)	
Minimum lumen diameter, mm	2.83±0.48
Residual diameter stenosis, %	9.4±7.5
Acute gain, mm	1.63±0.49
Residual diameter stenosis <50%	100.0 (120)
Residual diameter stenosis <30%	99.2 (119)
Final in-stent angiographic outcomes (core laboratory)	
Minimum lumen diameter, mm	2.88±0.47
Residual diameter stenosis, %	7.8±7.1
Acute gain, mm	1.67±0.49
Residual diameter stenosis <50%	100.0 (120)
Residual diameter stenosis <30%	100.0 (120)

Values are percentage (n) or mean±SD.

period. The cardiac death occurred in a 70-year-old male with history of MI, stent implantation in the left anterior descending artery and circumflex artery, atrial fibrillation, ascending aortic aneurysm, systolic dysfunction (ejection fraction, 45%) and multivessel disease who originally presented with presyncope and died suddenly 14 days after treatment of a 95% lesion in the distal right coronary artery. The inclusion of this patient was a protocol deviation, as the patient met defined angiographic exclusion criterion (second lesion with ≥50% stenosis in the same target vessel) due to occluded posterior descending coronary artery and reference vessel diameter >4.0 mm (quantitative coronary angiography, 4.57 mm). Details of the cardiac death, which was adjudicated as a probable stent thrombosis, are included in Table II in the [Data Supplement](#).

OCT Substudy Analysis

OCT was performed at 7 sites, in 48 patients before IVL and 47 after stenting. A comparison of patient characteristics, lesion characteristics, procedural details, and outcomes between patients who underwent OCT and those who did not is included in Tables III through VII in the [Data Supplement](#). Lesion length by OCT was 29.2±9.8 mm. Vessel preparation with IVL led to an increase in minimal luminal area from 2.33±1.35 to 6.10±2.17 mm² ($P<0.001$) after DES implantation. The impact of IVL at the sites of pre-IVL minimal luminal area, maximum calcium site and final minimal stent area is shown in Table 6. IVL significantly increased lumen area and decreased calcium angle. Representative examples of the effects of IVL are shown in Figure 2. Overall calcium fracture was identified in 78.7% of lesions,

Table 5. Clinical and Angiographic Outcomes

	n=120
Final angiographic complications	
Dissections, type	
None	98.3 (118)
A	0.0 (0)
B	0.8 (1)
C	0.8 (1)
D–F	0.0 (0)
Perforations	0.0 (0)
Abrupt closure	0.0 (0)
Slow flow	0.0 (0)
No reflow	0.0 (0)
MACE in hospital	5.8 (7/120)
Cardiac death	0.0 (0/120)
Non-Q-wave MI	5.8 (7/120)
Q-wave MI	0.0 (0/120)
Target vessel revascularization	0.0 (0/120)
MACE through 30 d	7.6 (9/119)
Cardiac death	0.8 (1/119)
Non-Q-wave MI	5.9 (7/119)
Q-wave MI	0.8 (1/119)
Target vessel revascularization	0.8 (1/119)
Stent thrombosis (definite or probable)	1.7 (2/119)

In total, at 30 d, there were 10 MACE in 9 subjects. One subject withdrew before the 30-d end point. Values are percentage (n/N). MACE indicates major adverse cardiac events; and MI, myocardial infarction.

with multiple fractures present in 55.3% (Table 7). Mean fracture length was 5.5 ± 5.0 mm with 3.4 ± 2.6 fractures per lesion and 1.6 ± 0.8 fractures per frame. Maximum calcium thickness and angle at the fracture site were 0.8 ± 0.3 mm and $224.5\pm 70.9^\circ$. At the site of maximum calcification pre-IVL, mean calcium thickness was 0.93 ± 0.20 mm and calcium angle $266.2\pm 77.1^\circ$. After DES implantation and optimization, the acute gain was 4.79 ± 2.45 mm² and final stent expansion $102.8\pm 30.6\%$. Following IVL, the minimal luminal area colocalized with the site of maximal calcification in none of 40 lesions.

DISCUSSION

Disrupt CAD I demonstrated the feasibility of IVL as a new therapeutic modality for management of severe CAC.¹⁴ Herein, we report the results of the Disrupt CAD II study, demonstrating the safety and effectiveness of IVL for modification of these lesions. The major findings are as follows: (1) IVL was a feasible frontline tool for CAC plaque modification, with the IVL catheter crossing the lesion and delivering therapy in all cases; (2) IVL was highly effective, facilitating delivery of stents in all

Table 6. Serial Measurements of Calcified Coronary Lesions on Optical Coherence Tomography

	Pre-IVL	Post-Stent	P Value
At Pre-IVL MLA site, n	48	47	
Lumen area, mm ²	2.33 ± 1.35	6.10 ± 2.17	<0.0001
Calcium angle, °	175.8 ± 96.9	127.1 ± 97.6 [28]	0.055
Maximum calcium thickness, mm	0.9 ± 0.3	0.8 ± 0.3 [28]	0.45
Calcium fracture		17.9% (5/28)	
Stent area, mm ²		6.06 ± 2.20	
Stent expansion, %		79.1 ± 21.0 [44]	
Acute area gain, mm ²		3.99 ± 1.72 [38]	
At pre-IVL maximum calcium site, n	48	38	
Lumen area, mm ²	3.64 ± 1.78	8.47 ± 3.04 [38]	<0.0001
Calcium angle, °	266.3 ± 77.1	215.1 ± 69.4	<0.0001
Maximum calcium thickness, mm	0.93 ± 0.2	0.89 ± 0.2	0.004
Calcium fracture		50% (19/38)	
Stent area, mm ²		7.77 ± 2.65 [38]	
Stent expansion, %		102.8 ± 30.6 [35]	
Acute area gain, mm ²		4.79 ± 2.45	
At final MSA site, n	48	47	
Lumen area, mm ²	4.26 ± 2.86	6.25 ± 2.25	<0.0001
Calcium angle, °	176.6 ± 100.4 [23]	149.4 ± 94.8 [30]	0.0004
Maximum calcium thickness, mm	1.0 ± 0.3 [23]	0.9 ± 0.3 [30]	0.055
Calcium fracture		23.3% (7/30)	
Stent area, mm ²		5.92 ± 2.14	
Stent expansion, %		77.6 ± 20.5 [44]	
Acute area gain, mm ²		2.52 ± 2.03 [35]	

Values are percentage (n/N) or mean \pm SD (n) compared using a paired *t* test. IVL indicates intravascular lithotripsy; MLA, minimal luminal area; and MSA, minimal stent area.

cases and reducing stenosis in severely calcified coronary arteries to a residual of <8% with an acute gain of 1.67 mm; (3) IVL was safe, with no reported type D to F dissections, perforations, abrupt closure, or slow flow/no reflow and 5.8% in-hospital and 7.6% 30-day rates of MACE in this high-risk group; and (4) the IVL mechanism of action was shown to be intraplaque calcium fracture, thereby modifying vascular compliance and facilitating stent expansion.

Severe CAC is a measure of lesion complexity⁵ and is strongly associated with procedural complications and PCI failure.^{18,19} Calcification may impact PCI success in a number of ways. As a result of friction between DES and CAC proximal to the lesion, the polymer may be damaged and hence contribute to target lesion failure.² At the lesion itself, drug delivery from polymer to tissue may be impaired in the setting of severe calcification, with the calcification acting as a barrier to diffusion.^{1,19} Moreover,

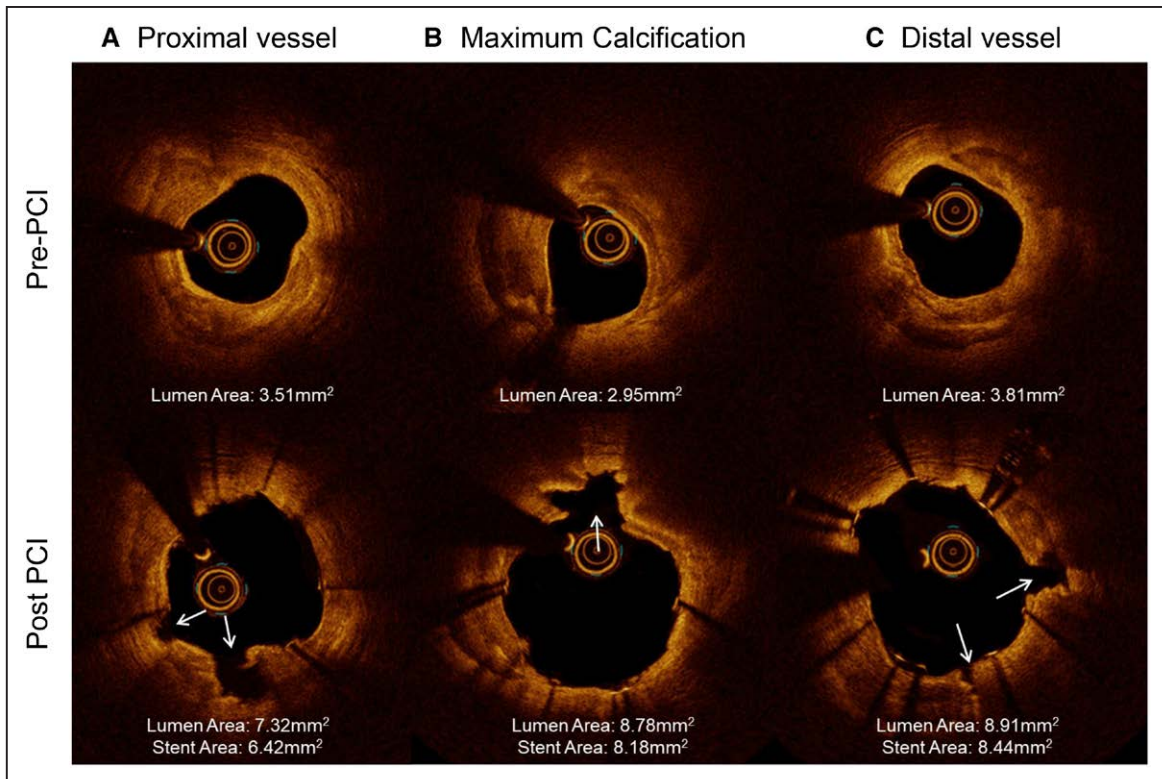


Figure 2. Representative example of optical coherence tomography (OCT) images of Shockwave Intravascular Lithotripsy for lesion modification of severe coronary artery calcification.

Top, Pre-percutaneous coronary intervention (PCI): **(A)** severe calcification is present on OCT in the proximal vessel. **B,** At the site of maximal calcification, there is $>270^\circ$ calcification with minimal thickness >1 mm and minimal luminal area of 2.95 mm^2 . **C,** Severe calcification is present on OCT in the distal vessel. **Bottom,** Post-PCI: **(A)** calcium fracture is identified in 2 locations (white arrows) on OCT coregistered with the pre-PCI image. **B,** At the site of maximal calcification, there is a calcium fracture (white arrow) liberating stent expansion and an acute gain of 5.83 mm^2 . **C,** At the distal vessel, calcium fracture is identified in 2 locations (white arrows) on OCT coregistered with the pre-PCI image.

calcification within the lesion physically impairs stent expansion²⁰—the single most important predictor of early stent thrombosis and restenosis after PCI.^{21–23} Circumferential coronary calcification is also a predictor of strut malapposition,²⁴ which in some studies has been associated with acute stent thrombosis.^{25,26} Taken together, these findings highlight the need for optimal lesion preparation in heavily calcified lesions before PCI.

Rotational or orbital atherectomy may favorably modify CAC to allow delivery of interventional devices, but plaque modification may be limited by guidewire bias.^{4,8,27,28} The only randomized controlled trials to compare rotational atherectomy to standard therapy before DES implantation, ROTAXUS (Rotational Atherectomy Prior to Taxus Stent Treatment for Complex Native Coronary Artery Disease) and PREPARE-CALC (The Comparison of Strategies to PREPARE Severely CALCified Coronary Lesions Trial), failed to demonstrate a long-term clinical benefit.^{9,29} While there was lower procedural success and greater crossover in the standard therapy arms, late loss was greater in the rotational atherectomy arm in ROTAXUS (consistent with the vascular healing response induced by tissue injury during ablation) but not in PREPARE-CALC. In

the periprocedural period, atherectomy, including laser, induces arterial injury by generation of heat³⁰ and myocardial injury by microembolization of atherosclerotic material with or without the clinical manifestation of slow flow/no flow. Specialty balloons using cutting or scoring technologies may avoid these complications.

Table 7. Optical Coherence Tomography Characteristics of Calcium Fracture Induced by Intravascular Lithotripsy

	n=47
Calcium fracture	78.7 (37/47)
1 fracture	23.4 (11/47)
2 fractures	17.0 (8/47)
≥ 3 fractures	38.3 (18/47)
Fracture length, mm	5.5 ± 5.0 [37]
Maximum fracture depth, mm	0.6 ± 0.3 [37]
Maximum calcium thickness at fracture site, mm	0.8 ± 0.3 [37]
Maximum calcium angle at fracture site, $^\circ$	224.5 ± 70.9 [37]
Minimum calcium angle at fracture site, $^\circ$	184.8 ± 64.8 [37]
Calcium fracture per lesion, n	3.4 ± 2.6 [37]
Calcium fracture per frame, n	1.6 ± 0.8 [37]

Values are percentage (n/N) or mean \pm SD [n].

However, a meta-analysis of 4 randomized trials comparing these specialty balloons to standard balloon angioplasty failed to show benefits in restenosis or MACE, and the risks of MI and vessel perforation were increased in the specialty balloon group.³¹

Compared with atherectomy or specialty balloons, IVL offers several potential advantages. First, unlike atherectomy,³² IVL requires no specific training as the IVL device is delivered similar to standard catheter-based PCI. Second, IVL therapy is balloon based, and, therefore, the risk of atheromatous embolization may be lower than free debulking devices. Accordingly, none of the patients in the current study, or Disrupt CAD I, experienced slow-flow or no-reflow events, and the rate of in-hospital MI was relatively low. Third, plaque modification using IVL is not subject to guidewire bias; instead, energy is distributed uniformly across the lithotripsy emitter addressing calcium irrespective of its circumferential location. Fourth, unlike traditional balloon technology, which is dependent on static barometric pressure, IVL delivers circumferential ultrashort pulses of high-intensity acoustic energy, which, by virtue of its compressive and decompressive components, results in effective circumferential modification of calcific atheroma.³³ In addition, whereas standard and specialty balloons are inflated at high atmospheric pressure to modify calcium, IVL is typically performed at low atmospheric pressure balloon inflation, minimizing mechanical vascular trauma. Fifth, side-branch protection using a guidewire may be easily performed using IVL, without risk of wire entrapment or severing as may occur with rotational or orbital atherectomy. Lastly, in the present study, IVL was highly effective, achieving acute gain (1.67 ± 0.49 mm) and residual stenosis ($7.8 \pm 7.1\%$) similar to that seen after DES of largely noncalcified lesions.³⁴

In the ROTAXUS study, strategy success, defined as angiographic success (<20% in-stent residual stenosis of the target lesion in the presence of Thrombolysis in Myocardial Infarction [TIMI] 3 flow), without crossover to balloon therapy alone or stent loss, was achieved in 92.5% of patients treated with rotational atherectomy. In-hospital and 9-month MACE were 4.2% and 24.2%, respectively.⁹ In the ORBIT II study, clinical success, defined by the same measures in the current study, was achieved in 88.9% of patients treated with orbital atherectomy. In-hospital MACE was 9.8%.³⁵ The IVL clinical success rate of 94.2% and in-hospital MACE rate of 5.8%, consistent with those reported in Disrupt CAD I,¹⁴ were similar to that achieved in these predicate studies. Thus, pending long-term results from the present and additional studies, IVL may be a new, simple-to-use therapeutic option for many patients with severe CAC. However, atherectomy will remain the first-line therapy if there is difficulty crossing the lesion with even contemporary low-profile balloon catheters.

The OCT substudy identified calcium fracture as the predominant mechanism of action of IVL, similar to the results from Disrupt CAD I where we showed that the number of fractures was proportional to the magnitude of calcification.¹⁷ Calcium fracture was identified in 78.7% of CAC plaques, with multiple fractures in more than half of the lesions. Of note, following IVL, the minimum lumen area was never at the site of pre-PCI maximal calcification, confirming the utility of IVL in modifying the compliance of severe CAC before stent implantation. Previous studies have identified that compared with lesions without calcium fracture, those with fracture have improved stent expansion, reduced restenosis, and reduced target lesion revascularization.^{36,37} Taken together, the angiographic and OCT findings of the current study support the potential of this new technology to impact clinical outcomes.

Our study has a number of limitations. First, the present study was nonrandomized and lacked a concurrent control group. Second, the secondary end point of clinical success, the ability of IVL to produce a residual diameter stenosis <50% after stenting, may be overly conservative in contemporary practice. While the 50% cutoff was chosen based on the ORBIT II study (which was used as the primary comparator for Disrupt CAD I),³⁵ the post-PCI final residual stenosis of $7.8 \pm 7.1\%$ confirms the effectiveness of IVL in facilitating stent expansion. Third, predilatation with a balloon catheter was required in 41.7% of patients to allow delivery of the IVL catheter. The impact of this on clinical outcomes deserves further study. Fourth, we defined severe calcification by angiography assessment alone. Previous studies have shown that angiography may miss calcium angle >180° in 1 in 5 patients identified by intravascular imaging,³⁸ although the same study found angiographically invisible calcium did not inhibit stent expansion. Finally, the sample size of our study was small, and long-term follow-up has not been completed.

In conclusion, in patients with severe CAC who require revascularization, IVL before stent implantation was performed safely with a low rate of complications and with high procedural success.

ARTICLE INFORMATION

Received August 6, 2019; accepted August 23, 2019.

The Data Supplement is available at <https://www.ahajournals.org/doi/suppl/10.1161/CIRCINTERVENTIONS.119.008434>.

Correspondence

Ziad A. Ali, MD, DPhil, Cardiovascular Research Foundation, 1700 Broadway, 9th Floor, New York, NY 10019. Email zaa2112@columbia.edu

Affiliations

St. Francis Hospital, Roslyn, NY (Z.A.A.). NewYork-Presbyterian Hospital, Columbia University (Z.A.A., A.M.). Clinical Trials Center, Cardiovascular Research Foundation, New York, NY (Z.A.A., G.W.S., A.C., M. Matsumura,

A.M.). The Zena and Michael A. Wiener Cardiovascular Institute, Icahn School of Medicine at Mount Sinai, New York, NY (G.W.S.). Department of Cardiology, University of Giessen, Frankfurt, Germany (H.N.). Hospital Clínico San Carlos IDISSC, Complutense University of Madrid, Spain (J.E.). Krankenhaus der Barmherzigen Brüder Trier, Germany (N.W.). Department of Cardiology, Oxford University Hospitals, United Kingdom (A.P.B.). King's College Hospital, London, United Kingdom (J.M.H.). Department of Cardiology, Cardiovascular Research Centre, OLV Hospital, Aalst, Belgium (B.D.B.). San Raffaele Hospital, Milan, Italy (M. Montorfano). Institut Cardiovasculaire Paris Sud, Hôpital Privé Jacques Cartier, Générale de Santé, Massy, France (T.L.). Yale University Medical Center, New Haven, CT (A.J.L.). Clinique Pasteur, Toulouse, France (J.F.). Structural Interventional Cardiology, Careggi University Hospital, Florence, Italy (C.D.M.).

Sources of Funding

This study was funded by Shockwave Medical, Inc (Santa Clara, CA).

Disclosures

Ziad A. Ali reports personal fees and equity in Shockwave Medical, Inc; grants from Cardiovascular Systems, Inc, and Abbott Vascular; and personal fees from Boston Scientific, AstraZeneca, ACIST Medical, Opens Medical, and Cardinal Health, outside the submitted work. Holger Nef reports consultant fee from Shockwave, Abbott, Boston Scientific and speaker honoraria from Abbott and Boston Scientific. Javier Escaned reports consulting fees from Abbott, Boston Scientific, and Philips and personal fees as speaker from Abiomed, Medtronic, and Opens outside the submitted work. Nikos Werner reports speaker honoraria from Shockwave and Boston Scientific. Adrian P. Banning reports institutional sponsorship for a fellowship from Boston Scientific and lecture fees from Boston Medtronic and Abbott Vascular. He is partially funded by the NHS Oxford NIHR Biomedical Research Centre. Jonathan M. Hill reports personal fees, grants, and equity in Shockwave Medical, personal fees and grants from Abbott Vascular, personal fees and grants from Boston Scientific, and personal fees and grants from Abiomed. Bernard De Bruyne reports institutional grant support from Abbott, Boston Scientific, Biotronik AG and Institutional consultancy fees from Abbott, Opens, and Boston Scientific outside of the submitted work. Thierry Lefevre reports advisory board for Shockwave at euroPCR 2019. Gregg W. Stone: Consultant to Shockwave. Mitsuaki Matsumura reports consultancy for TERUMO Corporation. Akiko Maehara reports grant support from Abbott Vascular and Boston Scientific, and consultant for Conavi Medical Inc. Alexandra J. Lansky reports institutional research support from Shockwave Medical. Carlo Di Mario reports institutional grants from the Disrupt CAD studies from Shockwave Medical. The other authors report no conflicts.

REFERENCES

- Mori S, Yasuda S, Kataoka Y, Morii I, Kawamura A, Miyazaki S. Significant association of coronary artery calcification in stent delivery route with restenosis after sirolimus-eluting stent implantation. *Circ J*. 2009;73:1856–1863. doi: 10.1253/circj.cj-09-0080
- Wiemer M, Butz T, Schmidt W, Schmitz KP, Horstkotte D, Langer C. Scanning electron microscopic analysis of different drug eluting stents after failed implantation: from nearly undamaged to major damaged polymers. *Catheter Cardiovasc Interv*. 2010;75:905–911. doi: 10.1002/ccd.22347
- Tzafiriri AR, Garcia-Polite F, Zani B, Stanley J, Muraj B, Knutson J, Kohler R, Markham P, Nikanorov A, Edelman ER. Calcified plaque modification alters local drug delivery in the treatment of peripheral atherosclerosis. *J Control Release*. 2017;264:203–210. doi: 10.1016/j.jconrel.2017.08.037
- Kini AS, Vengrenyuk Y, Pena J, Motoyama S, Feig JE, Meelu OA, Rajamanickam A, Bhat AM, Panwar S, Baber U, Sharma SK. Optical coherence tomography assessment of the mechanistic effects of rotational and orbital atherectomy in severely calcified coronary lesions. *Catheter Cardiovasc Interv*. 2015;86:1024–1032. doi: 10.1002/ccd.26000
- Levine GN, Bates ER, Blankenship JC, Bailey SR, Bittl JA, Cercek B, Chambers CE, Ellis SG, Guyton RA, Hollenberg SM, Khot UN, Lange RA, Mauri L, Mehran R, Moussa ID, Mukherjee D, Nallamothu BK, Ting HH. 2011 ACCF/AHA/SCAI guideline for percutaneous coronary intervention: a report of the American College of Cardiology Foundation/American Heart Association Task Force on Practice Guidelines and the Society for Cardiovascular Angiography and Interventions. *Circulation*. 2011;124:e574–e651. doi: 10.1161/CIR.0b013e31823ba622
- Windecker S, Kolh P, Alfonso F, Collet JP, Cremer J, Falk V, Filippatos G, Hamm C, Head SJ, Juni P, et al. 2014 ESC/EACTS guidelines on myocardial

- revascularization: The Task Force on Myocardial Revascularization of the European Society of Cardiology (ESC) and the European Association for Cardio-Thoracic Surgery (EACTS) Developed with the special contribution of the European Association of Percutaneous Cardiovascular Interventions (EAPCI). *Eur Heart J*. 2014;35:2541–2619. doi: 10.1093/eurheartj/ehu278
- Lee T, Shlofmitz RA, Song L, Tsiamtsiouris T, Pappas T, Madrid A, Jeremias A, Haag ES, Ali ZA, Moses JW, Matsumura M, Mintz GS, Maehara A. The effectiveness of excimer laser angioplasty to treat coronary in-stent restenosis with peri-stent calcium as assessed by optical coherence tomography. *EuroIntervention*. 2019;15:e279–e288. doi: 10.4244/EIJ-D-18-00139
 - Yamamoto MH, Maehara A, Karimi Galougahi K, Mintz GS, Parviz Y, Kim SS, Koyama K, Amemiya K, Kim SY, Ishida M, Losquadro M, Kirtane AJ, Haag E, Sosa FA, Stone GW, Moses JW, Ochiai M, Shlofmitz RA, Ali ZA. Mechanisms of orbital versus rotational atherectomy plaque modification in severely calcified lesions assessed by optical coherence tomography. *JACC Cardiovasc Interv*. 2017;10:2584–2586. doi: 10.1016/j.jcin.2017.09.031
 - Abdel-Wahab M, Richardt G, Joachim Büttner H, Toelg R, Geist V, Meinertz T, Schofer J, King L, Neumann FJ, Khatib AA. High-speed rotational atherectomy before paclitaxel-eluting stent implantation in complex calcified coronary lesions: the randomized ROTAXUS (Rotational Atherectomy Prior to Taxus Stent Treatment for Complex Native Coronary Artery Disease) trial. *JACC Cardiovasc Interv*. 2013;6:10–19. doi: 10.1016/j.jcin.2012.07.017
 - Iwasaki K, Samukawa M, Furukawa H. Comparison of the effects of nicorandil versus verapamil on the incidence of slow flow/no reflow during rotational atherectomy. *Am J Cardiol*. 2006;98:1354–1356. doi: 10.1016/j.amjcard.2006.06.028
 - Matsuo H, Watanabe S, Warita S, Kojima T, Hirose T, Iwama M, Ono K, Takahashi H, Segawa T, Minatoguchi S, Fujiwara H. Prevention of no-reflow/slow-flow phenomenon during rotational atherectomy—a prospective randomized study comparing intracoronary continuous infusion of verapamil and nicorandil. *Am Heart J*. 2007;154:994.e1–994.e6. doi: 10.1016/j.ahj.2007.07.036
 - Sakakura K, Ako J, Wada H, Naito R, Arao K, Funayama H, Kubo N, Momomura S. Beta-blocker use is not associated with slow flow during rotational atherectomy. *J Invasive Cardiol*. 2012;24:379–384.
 - Sakakura K, Ako J, Wada H, Naito R, Funayama H, Arao K, Kubo N, Momomura S. Comparison of frequency of complications with on-label versus off-label use of rotational atherectomy. *Am J Cardiol*. 2012;110:498–501. doi: 10.1016/j.amjcard.2012.04.021
 - Brinton TJ, Ali ZA, Hill JM, Meredith IT, Maehara A, Iliandala U, Lansky A, Göteborg M, Van Mieghem NM, Whitbourn R, Fajadet J, Di Mario C. Feasibility of shockwave coronary intravascular lithotripsy for the treatment of calcified coronary stenoses. *Circulation*. 2019;139:834–836. doi: 10.1161/CIRCULATIONAHA.118.036531
 - Dini CS, Tomberli B, Mattesini A, Ristalli F, Valente S, Stolicova M, Meucci F, Baldereschi G, Fanelli F, Shlofmitz R, Ali ZA, Di Mario C. Intravascular lithotripsy for calcific coronary and peripheral stenoses [published online May 7, 2019]. *EuroIntervention*. doi: 10.4244/EIJ-D-18-01056
 - Tearney GJ, Regar E, Akasaka T, Adriaenssens T, Barlis P, Bezerra HG, Bouma B, Bruining N, Cho JM, Chowdhary S, Costa MA, de Silva R, Dijkstra J, Di Mario C, Dudek D, Dudeck D, Falk E, Falk E, Feldman MD, Fitzgerald P, Garcia-Garcia HM, Garcia H, Gonzalo N, Granada JF, Guagliumi G, Holm NR, Honda Y, Ikeno F, Kawasaki K, Kochman J, Koltowski L, Kubo T, Kume T, Kyono H, Lam CC, Lamouche G, Lee DP, Leon MB, Maehara A, Manfrini O, Mintz GS, Mizuno K, Morel MA, Nadkarni S, Okura H, Otake H, Pietrasik A, Prati F, Räber L, Radu MD, Rieber J, Riga M, Rollins A, Rosenberg M, Sirbu V, Serruys PW, Shimada K, Shinke T, Shite J, Siegel E, Sonoda S, Sonada S, Suter M, Takarada S, Tanaka A, Terashima M, Thim T, Troels T, Uemura S, Ughi GJ, van Beusekom HM, van der Steen AF, van Es GA, van Es GA, van Soest G, Virmani R, Waxman S, Weissman NJ, Weisz G; International Working Group for Intravascular Optical Coherence Tomography (IWG-IVOCT). Consensus standards for acquisition, measurement, and reporting of intravascular optical coherence tomography studies: a report from the International Working Group for Intravascular Optical Coherence Tomography Standardization and Validation. *J Am Coll Cardiol*. 2012;59:1058–1072. doi: 10.1016/j.jacc.2011.09.079
 - Ali ZA, Brinton TJ, Hill JM, Maehara A, Matsumura M, Karimi Galougahi K, Iliandala U, Göteborg M, Whitbourn R, Van Mieghem N, Meredith IT, Di Mario C, Fajadet J. Optical coherence tomography characterization of coronary lithoplasty for treatment of calcified lesions: first description. *JACC Cardiovasc Imaging*. 2017;10:897–906. doi: 10.1016/j.jcmg.2017.05.012

18. Généreux P, Madhavan MV, Mintz GS, Maehara A, Palmerini T, Lasalle L, Xu K, McAndrew T, Kirtane A, Lansky AJ, Brener SJ, Mehran R, Stone GW. Ischemic outcomes after coronary intervention of calcified vessels in acute coronary syndromes. Pooled analysis from the HORIZONS-AMI (Harmonizing Outcomes With Revascularization and Stents in Acute Myocardial Infarction) and ACUITY (Acute Catheterization and Urgent Intervention Triage Strategy) TRIALS. *J Am Coll Cardiol*. 2014;63:1845–1854. doi: 10.1016/j.jacc.2014.01.034
19. Li J, Tzafiri R, Patel SM, Parikh SA. Mechanisms underlying drug delivery to peripheral arteries. *Interv Cardiol Clin*. 2017;6:197–216. doi: 10.1016/j.iccl.2016.12.004
20. Kobayashi Y, Okura H, Kume T, Yamada R, Kobayashi Y, Fukuhara K, Koyama T, Nezu S, Neishi Y, Hayashida A, Kawamoto T, Yoshida K. Impact of target lesion coronary calcification on stent expansion. *Circ J*. 2014;78:2209–2214. doi: 10.1253/circj.cj-14-0108
21. Fitzgerald PJ, Oshima A, Hayase M, Metz JA, Bailey SR, Baim DS, Cleman MW, Deutsch E, Diver DJ, Leon MB, Moses JW, Oesterle SN, Overlie PA, Pepine CJ, Safian RD, Shani J, Simonton CA, Smalling RW, Teirstein PS, Zidar JP, Yeung AC, Kuntz RE, Yock PG. Final results of the Can Routine Ultrasound Influence Stent Expansion (CRUISE) study. *Circulation*. 2000;102:523–530. doi: 10.1161/01.cir.102.5.523
22. Choi SY, Witzendichler B, Maehara A, Lansky AJ, Guagliumi G, Brodie B, Kellett MA Jr, Dressler O, Parise H, Mehran R, Dangas GD, Mintz GS, Stone GW. Intravascular ultrasound findings of early stent thrombosis after primary percutaneous intervention in acute myocardial infarction: a Harmonizing Outcomes with Revascularization and Stents in Acute Myocardial Infarction (HORIZONS-AMI) substudy. *Circ Cardiovasc Interv*. 2011;4:239–247. doi: 10.1161/CIRCINTERVENTIONS.110.959791
23. Ahn JM, Kang SJ, Yoon SH, Park HW, Kang SM, Lee JY, Lee SW, Kim YH, Lee CW, Park SW, Mintz GS, Park SJ. Meta-analysis of outcomes after intravascular ultrasound-guided versus angiography-guided drug-eluting stent implantation in 26,503 patients enrolled in three randomized trials and 14 observational studies. *Am J Cardiol*. 2014;113:1338–1347. doi: 10.1016/j.amjcard.2013.12.043
24. Lindsay AC, Paulo M, Kadriye K, Tejeiro R, Alegria-Barrero E, Chan PH, Foin N, Syrseloudis D, Di Mario C. Predictors of stent strut malapposition in calcified vessels using frequency-domain optical coherence tomography. *J Invasive Cardiol*. 2013;25:429–434.
25. Souteyrand G, Amabile N, Mangin L, Chabin X, Meneveau N, Cayla G, Vanzetto G, Barnay P, Trouillet C, Rioufol G, Rangé G, Teiger E, Delaunay R, Dubreuil O, Lhermusier T, Mulliez A, Levesque S, Belle L, Caussin C, Motreff P; PESTO Investigators. Mechanisms of stent thrombosis analysed by optical coherence tomography: insights from the national PESTO French registry. *Eur Heart J*. 2016;37:1208–1216. doi: 10.1093/eurheartj/ehv711
26. Taniwaki M, Radu MD, Zaugg S, Amabile N, Garcia-Garcia HM, Yamaji K, Jørgensen E, Kelbæk H, Pilgrim T, Caussin C, Zanchin T, Veugeois A, Abildgaard U, Jüni P, Cook S, Koskinas KC, Windecker S, Räber L. Mechanisms of very late drug-eluting stent thrombosis assessed by optical coherence tomography. *Circulation*. 2016;133:650–660. doi: 10.1161/CIRCULATIONAHA.115.019071
27. Oishi Y, Okamoto M, Sueda T, Hashimoto M, Karakawa S, Kambe M. Guidewire bias in rotational atherectomy in the angled lesion: evaluation based on the thickness of the ablated intima and media. *Circ J*. 2002;66:659–664. doi: 10.1253/circj.66.659
28. Tomey MI, Kini AS, Sharma SK. Current status of rotational atherectomy. *JACC Cardiovasc Interv*. 2014;7:345–353. doi: 10.1016/j.jcin.2013.12.196
29. Abdel-Wahab M, Toelg R, Byrne RA, Geist V, El-Mawardy M, Allali A, Rheude T, Robinson DR, Abdelghani M, Sulimov DS, Kastrati A, Richardt G. High-speed rotational atherectomy versus modified balloons prior to drug-eluting stent implantation in severely calcified coronary lesions. *Circ Cardiovasc Interv*. 2018;11:e007415. doi: 10.1161/CIRCINTERVENTIONS.118.007415
30. Reisman M, Shuman BJ, Harms V. Analysis of heat generation during rotational atherectomy using different operational techniques. *Cathet Cardiovasc Diagn*. 1998;44:453–455.
31. Bittl JA, Chew DP, Topol EJ, Kong DF, Califf RM. Meta-analysis of randomized trials of percutaneous transluminal coronary angioplasty versus atherectomy, cutting balloon atherotomy, or laser angioplasty. *J Am Coll Cardiol*. 2004;43:936–942. doi: 10.1016/j.jacc.2003.10.039
32. Kimball BP, Bui S, Cohen EA, Carere RG, Adelman AG. Early experience with directional coronary atherectomy: documentation of the learning curve. *Can J Cardiol*. 1993;9:177–185.
33. Cleveland RO, McAteer JA. Physics of Shock-Wave Lithotripsy. In: A. D. Smith, G. H. Badlani, G. Preminger, L. R. Kavoussi, eds. *Smith's Textbook of Endourology*. 3rd ed. Volume I. Hoboken, NJ: Wiley-Blackwell; 2012:529–558.
34. Ali ZA, Maehara A, Généreux P, Shlofmitz RA, Fabbiochi F, Nazif TM, Guagliumi G, Meraj PM, Alfonso F, Samady H, Akasaka T, Carlson EB, Leeser MA, Matsumura M, Ozan MO, Mintz GS, Ben-Yehuda O, Stone GW; ILUMIEN III: OPTIMIZE PCI Investigators. Optical coherence tomography compared with intravascular ultrasound and with angiography to guide coronary stent implantation (ILUMIEN III: OPTIMIZE PCI): a randomised controlled trial. *Lancet*. 2016;388:2618–2628. doi: 10.1016/S0140-6736(16)31922-5
35. Chambers JW, Feldman RL, Himmelstein SI, Bhatheja R, Villa AE, Strickman NE, Shlofmitz RA, Dulas DD, Arab D, Khanna PK, Lee AC, Ghali MG, Shah RR, Davis TP, Kim CY, Tai Z, Patel KC, Puma JA, Makam P, Bertolet BD, Nseir GY. Pivotal trial to evaluate the safety and efficacy of the orbital atherectomy system in treating de novo, severely calcified coronary lesions (ORBIT II). *JACC Cardiovasc Interv*. 2014;7:510–518. doi: 10.1016/j.jcin.2014.01.158
36. Fujino A, Mintz GS, Lee T, Hoshino M, Usui E, Kanaji Y, Murai T, Yonetsu T, Matsumura M, Ali ZA, Jeremias A, Moses JW, Shlofmitz RA, Kakuta T, Maehara A. Predictors of calcium fracture derived from balloon angioplasty and its effect on stent expansion assessed by optical coherence tomography. *JACC Cardiovasc Interv*. 2018;11:1015–1017. doi: 10.1016/j.jcin.2018.02.004
37. Kubo T, Shimamura K, Ino Y, Yamaguchi T, Matsuo Y, Shiono Y, Taruya A, Nishiguchi T, Shimokado A, Teraguchi I, Orii M, Yamano T, Tanimoto T, Kitabata H, Hirata K, Tanaka A, Akasaka T. Superficial calcium fracture after PCI as assessed by OCT. *JACC Cardiovasc Imaging*. 2015;8:1228–1229. doi: 10.1016/j.jcmg.2014.11.012
38. Wang X, Matsumura M, Mintz GS, Lee T, Zhang W, Cao Y, Fujino A, Lin Y, Usui E, Kanaji Y, Murai T, Yonetsu T, Kakuta T, Maehara A. In vivo calcium detection by comparing optical coherence tomography, intravascular ultrasound, and angiography. *JACC Cardiovasc Imaging*. 2017;10:869–879. doi: 10.1016/j.jcmg.2017.05.014