



Haemorrhagic enteritis seroconversion in turkey breeders: field observations

Raffaella Ceruti, Marco Della Valentina, Luigi Gavazzi, Annalisa Venni, Viviana Ferrazzi & Guido Grilli

To cite this article: Raffaella Ceruti, Marco Della Valentina, Luigi Gavazzi, Annalisa Venni, Viviana Ferrazzi & Guido Grilli (2007) Haemorrhagic enteritis seroconversion in turkey breeders: field observations, Italian Journal of Animal Science, 6:3, 321-325, DOI: [10.4081/ijas.2007.321](https://doi.org/10.4081/ijas.2007.321)

To link to this article: <https://doi.org/10.4081/ijas.2007.321>



Copyright 2007 Taylor and Francis Group
LLC



Published online: 01 Mar 2016.



Submit your article to this journal [↗](#)



Article views: 107



View related articles [↗](#)



Citing articles: 1 View citing articles [↗](#)



Haemorrhagic enteritis seroconversion in turkey breeders: field observations

Raffaella Ceruti¹, Marco Della Valentina¹, Luigi Gavazzi¹,
Annalisa Venni¹, Viviana Ferrazzi², Guido Grilli²

¹Gruppo Amadori. Cesena, Italy

²Dipartimento di Patologia Animale, Igiene e Sanità Pubblica Veterinaria. Università di Milano, Italy

Corresponding author: Dr. Raffaella Ceruti. Gruppo Amadori. Via Bonfaldina 9, 25046 Cazzago S.Martino (BS), Italy - Tel. +39 030 7757222 - Fax: +39 030 7757224 - Email: raffaella.ceruti@amadori.it

ABSTRACT

Seroconversion to viral haemorrhagic enteritis (HE) was studied in seven flocks of turkey breeders (17.974 birds in total), after 20 weeks of the onset of egg production. They showed no clinical signs, and mortality rate was normal. However, the infection caused a drop in egg production lasting about five weeks (-2.32 eggs laid during this period), but had no effect on hatching parameters.

Key words: Turkey breeders, Haemorrhagic enteritis, Eggs.

RIASSUNTO

SIEROCONVERSIONE DA VIRUS DELL'ENTERITE EMORRAGICA NEL TACCHINO RIPRODUTTORE: OSSERVAZIONI DI CAMPO

Gli Autori segnalano la sieroconversione da HEV in un allevamento di 17.974 tacchini riproduttori, suddivisi in 7 gruppi, avvenuta a 20 settimane di deposizione. I soggetti non hanno manifestato nessuna sintomatologia clinica e la mortalità era nella norma. L'infezione ha però provocato una diminuzione della ovodeposizione per circa 5 settimane (-2,32 uova prodotte nel periodo) senza peraltro alterare i parametri di schiusa.

Parole chiave: Tacchini riproduttori, Enterite emorragica, Uova.

Introduction

Haemorrhagic enteritis (HE) is an economically important disease of turkeys, caused by a type II avian adenovirus (Sharma, 1991). The virus is ubiquitous and may infect mainly commercial turkeys. In Italian farms it has been known for a long time (Mandelli *et al.*, 1977). The disease is most commonly seen in 4-12 week-old turkeys, and the classical form causes rapidly

progressive clinical signs over a 24-hour period. These include depression, bloody droppings and death. Mortality can reach 60%, often over a 5-10 day period during which signs are evident. Gross lesions in broiler turkeys are splenomegaly and either massive haemorrhage into the lumen of the small intestine or congestion of the small intestinal wall. Intranuclear inclusion bodies may be seen in reticular cells of the spleen and in large mononuclear cells of visceral organs.

Lymphocytic hyperplasia may be evident in many tissues, as well as inclusion bodies are often present in these areas (Pierson and Domermuth, 1993). Immunosuppression appears to occur with virulent and avirulent strains of HE virus (HEV). Infection of mature turkeys is often subclinical, but in some cases there is a drop in egg production with loss of shell pigmentation and thinning of the shell (McFerran, 1993). We describe an outbreak of late HE infection in 52-week-old turkey breeders.

Material and methods

Seven flocks of hybrid BUT Big 6 turkey breeders, in total 17,070 parent females and 904 parent males reared in the same farm, were monitored for health and zootechnical aspects during the egg laying period. The turkeys, all of the same age and from the same incubator, were vaccinated according to the schedule set out in Table 1. Health monitoring involved periodical clinical examinations with laboratory tests on any birds that died unexpectedly, and blood sampling (10 turkeys per flock) to establish the immune status of the farm.

Serological tests for *Mycoplasma gallisepticum* (MG), *M. synoviae* (MS), and *M. meleagridis* (MM) (rapid serum plate, RSP) were carried out for three times on the chicks. At 27 weeks the birds were tested for Avian Influenza (AI), *Ornithobacterium rhinotracheale* (ORT), Turkey Rhinotracheitis (TRT), Avian Encephalomyelitis (AE) and HE (using commercial ELISA kits),

PMV1 (hemagglutination-inhibition test, HI), and *Salmonella pullorum-gallinarum* (RSP). The flocks never showed any particular health problem during the brooding period.

In the breeding farm, at the onset of egg laying (at about 30 weeks of age), serological tests were carried out for *Paramyxovirus 1* (PMV1) and *Paramyxovirus 3* (PMV3) (HI), ORT, TRT and HE. Moreover, the birds were tested monthly for MG, MS, and MM (RSP); a monitoring for *Salmonella* spp. in faeces once a month and in pipped eggs twice a month was also performed.

At 20 weeks of egg laying, there was a drop in egg production in some flocks, so we repeated serological tests for PMV1, ORT, TRT, HE and AI, then again two weeks later. In addition, chemical and microbiological tests were carried out on feed and drinking water. At 22 weeks when blood was sampled, some breeders died with no apparent cause were autopsied, and histological and bacteriological examinations were carried out on liver, spleen, lungs and brain samples. Tests for the HE virus were performed at "Istituto Zooprofilattico Sperimentale della Lombardia ed Emilia Romagna", using the PCR technique. In addition, we checked figures for laying (eggs/female housed/week), fertility, embryonic mortality, broken eggs, and hatching percent.

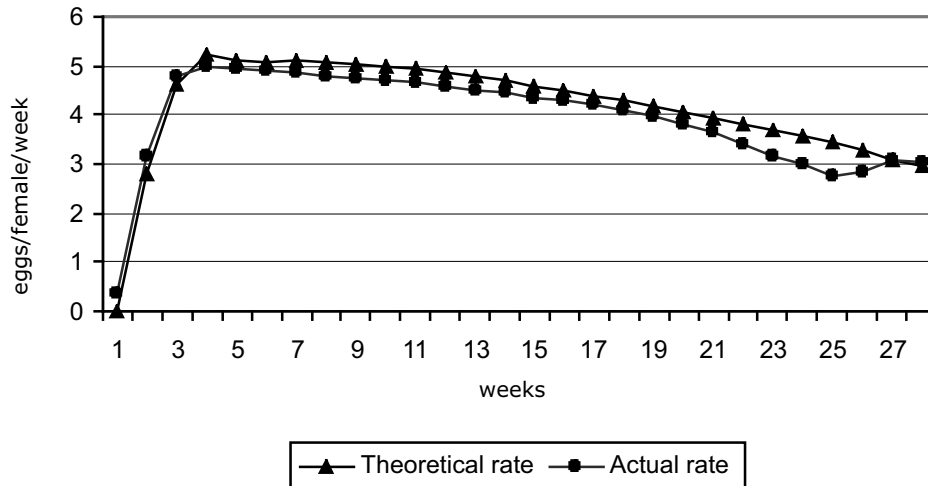
Results and discussion

Hens started laying eggs at the end of November 2005 and the rate remained steady, though slightly below the optimal curve (0.15 eggs/hen/week lower), up to 20 weeks in all flocks, and their health was always excellent. From week 20, all flocks showed a drop in egg production that remained below standard values up to week 25 (-0.53 eggs/hen/week). In the last weeks there was a slight rise (Figure 1). The total eggs/hen amounted to 110 out of 116 expected, most of the drop being concen-

Table 1. Vaccination schedule.

Week	Type of vaccine	Route of administration
1	PMV1	Ocular
5	PMV1 dead	Subcutaneous
12	PMV1 + TRT	Subcutaneous
19	AE+ pox + ORT	Wing; subcutaneous
22	PMV1 + TRT + PMV3	Subcutaneous
26	PMV1 + TRT + PMV3	Subcutaneous

Figure 1. Actual and expected curves for egg laying by the BUT Big 6 hybrid turkey.



trated between weeks 20 and 25 (-3.21 eggs/hen). There were no appreciable changes in the incubated eggs (fertility, embryonic mortality, broken eggs, hatching percent). Microbiological and chemical tests on food and water yielded negative results.

Breeders mortality remained normal and no particular gross or microscopic lesions were found. Bacteriological tests for *Salmonella* spp. and serum tests for *Mycoplasma* spp. were all negative, as were those for AI. Other serological tests (Figure 2) showed that antibody titers for PMV1 and ORT dropped from week 1 to week 22 of laying. The HE titer showed an interesting pattern: tests carried out at the housing and at the onset of egg laying were both negative, since most of the birds had not been vaccinated so we did not detect the seroconversion usually occurring between 8 and 16 weeks of age in response to field viruses (Ianconescu *et al.*, 1985; Neumann *et al.*, 1991) and persisting in breeders until they stop laying (Ianconescu *et al.*, 1984). Only at 20-week monitoring, when we observed the drop in egg production - initially only in some flocks - we realized that some were infected with HE. Two

weeks later, serological testing showed seroconversion in all the flocks, with very high levels of antibody titers. The correlations between antibody titer and egg laying patterns are shown in Figure 3, in particular for flock 4.

Except the drop in egg production, these birds had no clinical symptoms attributable to HE infection, in accordance with McFerran's report (1993), describing however some defects in the eggs (depigmentation, fragile shells), which we did not find. Other reports on seroconversion in meat turkeys also mention no clinical symptoms (Neumann *et al.*, 1991; McCracken and Adair, 1993). This is very likely due to the pathogenicity of the viral strain. The typical lesions of HE - gross or microscopic - were also not seen in hens died without apparent cause, confirming that the presence of lesions depends on the age of the bird at the time of infection (Meteyer *et al.*, 1992). PCR analysis also gave negative findings, probably because the timing of collection of the target organs is very important, since the virus is detectable only for 6-8 days at most after infection (Silim and Thorsen, 1981; McCracken and Adair, 1993); however, we obtained organs at

Figure 2. Antibody titers for the five diseases investigated.

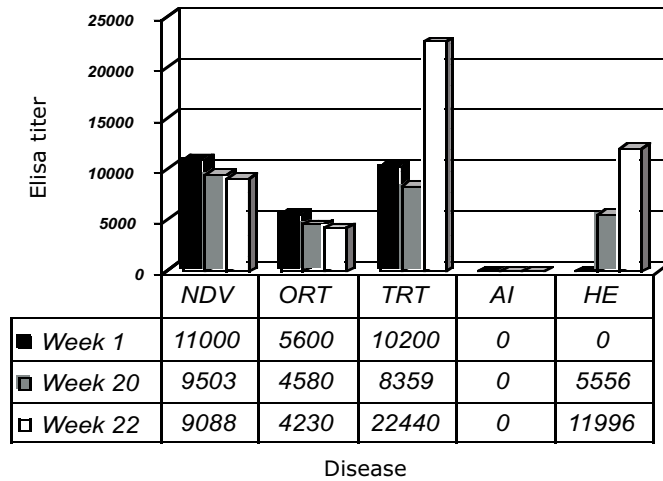
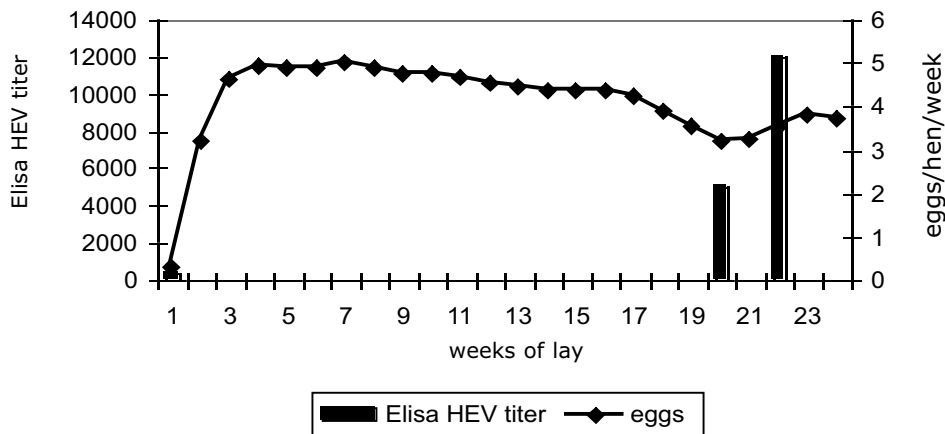


Figure 3. Egg laying pattern and HE antibody titer, flock 4.



22 weeks, when seroconversion became evident, probably two or three weeks after the onset of infection.

Serological tests showed a rise in TRT antibodies after HE infection (Figure 2), at the time when a respiratory disorder was observed in five flocks, and *Escherichia coli* was isolated

from organ samples. Probably the TRT infection in birds, that had been vaccinated but nearly the end of the cycle, was facilitated by the immunosuppressive activity of avirulent strains of the HE virus (Nagaraja *et al.*, 1985; Sharma, 1991; Suresh and Sharma, 1996; Pierson and Domermuth, 1997). HEV infection

has in fact been reported to favour bacterial and viral respiratory infections (Newberry *et al.*, 1993; Hurk *et al.*, 1994; Chary *et al.*, 2002). TRT can also reduce egg production, but in the birds we examined the onset of clinical symptoms and the rise in antibody titer coincided with the return to normal egg laying rates in flocks infected earlier with HEV (Figure 3).

Conclusions

Observations from breeding farms are not always easy to understand. In the present case the drop in egg production does seem linked to a late infection by a weakly pathogenic strain of HEV. This pathogen is frequent in meat turkey breeding farms but has rarely been reported in egg laying breeders.

From the overall health point of view there were no real problems and the financial impact was also light since the infection arose towards the end of the egg laying career. In the light of these findings it appears important to maintain a good antibody level against HEV throughout the reproductive cycle, also considering the secondary infections linked to the immunosuppressive effect of this virus.

REFERENCES

- Chary, P., Rautenschlein, S., Sharma, J.M., 2002. Reduced efficacy of hemorrhagic enteritis virus vaccine in turkeys exposed to avian pneumovirus. *Avian Dis.* 46:353-359.
- Ianconescu, M., McCapes, R.H., Bankowski, R.A., 1984. Serologic survey for hemorrhagic enteritis in California breeder and meat turkeys. pp 29-30 in Proc. 33rd World Poultry Conf., Davis, CA, USA.
- Ianconescu, M., McCapes, R.H., Bankowski, R.A., Kelly, B.J., Ghazikhanian, G.Y., 1985. Hemorrhagic enteritis of turkeys in California: serologic study of hemorrhagic enteritis virus antibody with an enzyme-linked immunosorbent assay. *Avian Dis.* 29:356-363.
- Hurk, J.V., Van Den Allan, B.J., Riddel, C., Watts, T., Potter, A.A., 1994. Effect of infection with hemorrhagic enteritis virus on susceptibility of turkeys to *Escherichia coli*. *Avian Dis.* 38:708-716.
- Mandelli, G., Rampin, T., Guidobono, C.L., Gallazzi, D., 1977. Enterite emorragica da adenovirus nel tacchino. *Clin. Vet.* 100:437-447.
- McCracken, R.M., Adair, B.M., 1993. Avian Adenovirus. In: J.B. McFerrand and M.S. McNulty (eds.) *Virus Infection of Birds*. Elsevier Science Publishers, New York, NYC, USA.
- Meteye, C.U., Mohammed, H.O., Chin, R.P., Bicford, A.A., Trampel, D.W., Klein, P.N., 1992. Relationship between age of flock seroconversion to hemorrhagic enteritis virus and appearance of adenoviral inclusions in the spleen and renal tubule epithelia of turkeys. *Avian Dis.* 36:88-96.
- Nagaraja, K.V., Kang, S.Y., Newman, J.A., 1985. Immunosuppressive effects of a virulent strain of hemorrhagic enteritis virus in turkeys vaccinated against Newcastle disease. *Poultry Sci.* 64:588-590.
- Neumann, U., Behr, K.P., Luders, H., Siegmann, O., 1991. Sequential serological studies in different turkey farms in Northern Germany. 1. Report: Detection of humoral antibodies against hemorrhagic enteritis virus (HEV). *Arch. Geflügelkd.* 55:10-13.
- Newberry, L.A., Skeeles, J.K., Kreider, D.L., Beasley, J.N., Story, J.D., McNew, R.W., Berridge, B.R., 1993. Use of virulent hemorrhagic enteritis virus for the induction of colibacillosis in turkeys. *Avian Dis.* 37:1-5.
- Pierson, F.W., Domermuth, C.H., 1993. Hemorrhagic enteritis, marble spleen disease, and related infection. In: B.W Calnek. (ed.) *Diseases of Poultry Iowa State University Press, USA*, pp 623-632.
- Sharma, J.M., 1991. Hemorrhagic enteritis of turkeys. *Vet. Immunol. Immunopathol.* 30:67-71.
- Silim, A., Thorsen, J., 1981. Hemorrhagic enteritis: virus distribution and sequential development of antibody in turkeys. *Avian Dis.* 25:444-453.
- Suresh, M., Sharma, J.M., 1996. Pathogenesis of type II avian adenovirus infections in turkeys: in vivo immune cell tropism and tissue distribution of the virus. *J. Virol.* 70:30-36.