



Appendicitis in a 14-month-old infant with respiratory symptoms

Giulia Brisighelli, Anna Morandi, Filippo Parolini, Ernesto Leva

ABSTRACT

Although appendicitis is the condition that most commonly requires emergent abdominal surgery in the paediatric population, less than 2% of the disease occurs in infants and it is even more uncommon in neonates. In this report, we describe a rare case of a 14-month-old child presenting with abdominal pain first diagnosed with upper respiratory tract infection and then admitted to our Paediatric Surgery Department with a final diagnosis of acute appendicitis. A particular attention has to be kept on children presenting with an upper respiratory tract infection since symptoms can mask abdominal signs. Due to high morbidity and mortality rate related to a delayed diagnosis, appendicitis always has to be considered as a possible diagnosis, in order to ensure a prompt treatment.

Key words: Acute abdomen, appendicitis, infant, respiratory infections

INTRODUCTION

Although appendicitis is the condition that most commonly requires emergent abdominal surgery in the paediatric population, less than 2% of the disease occurs in infants and it is extremely rare in neonates. Many reports of appendicitis among pre-school aged children have been published and all of them underline the difficulties in diagnosing appendicitis in this group of children.^[1]

The youngest the child, the more atypical the clinical presentation is. Abdominal pain and vomiting, followed by fever, are the most common presenting symptoms while abdominal tenderness and temperature over

38°C are the most common signs.^[2,3] This clinical presentation may simulate other more frequent medical conditions, especially genitourinary infections, gastroenteritis, pneumonia, constipation as well as other surgical conditions. In addition, the difficulties of the clinical examination and the relatively impaired immunity system of the infants contribute to delay diagnosis with a consequent high rate of rupture, prolonged hospitalisation, morbidity and mortality which can be as high as 10% in infants, reaching 80% in neonates.^[4] A case of appendicitis in a 14-month-old male is presented.

CASE REPORT

A 14-month-old male was admitted to our department because of the persistence of fever and anorexia. In the previous week, he had been examined by his paediatrician for fever without any other symptom. He was treated with paracetamol and, as the symptoms did not resolve and cough appeared, he was referred to an Emergency Department and discharged with a diagnosis of upper respiratory tract infection. He was given an antibiotic therapy (amoxicillin and clavulanic acid), paracetamol and oral rehydration.

Because of symptoms' persistence and the subsequent occurrence of a non-biliary vomiting episode, he went back to the same Emergency Department on the following day. His pulse rate was 156/minute, SaO₂ was 96% to 97%, blood pressure was 115/80 mmHg and he was febrile with a temperature of 37.8°C. On clinical examination, he had a meteoric abdomen with initial signs of abdominal tenderness. Peristalsis was valid. A rectal probe was positioned with emission of minimal amount of normal stools. The thoracic examination showed inconstant sounds, especially in left fields. Blood tests revealed total white cell count of 4.81 x 10⁹/l, without a left shift, and C-reactive protein of 20.5 mg/l. A thoracic and abdominal X-ray was performed, the latter showing the presence of multiple air fluid levels. The patient was rehydrated with a

Department of Pediatric Surgery, FONDAZIONE IRCCS CA' GRANDA – Ospedale Maggiore Policlinico, Milano, Italy

Address for correspondence:

Dr. Giulia Brisighelli, Department of Pediatric Surgery, Padiglione Alfieri, Policlinico di Milano, Via F. Sforza 28, 20122, Italy.
E-mail: giulibrisighelli@hotmail.com

normal saline infusion at 40 ml/h, an antibiotic therapy with Ceftriaxone 600 mg e.v. was started and he was then transferred to our department. When he arrived to our ward, he showed clear abdominal tenderness and generalised abdominal pain. Peristalsis was still present. A nasogastric tube was inserted and gastric and salivary content was aspirated. A rectal probe was also positioned and a rectal wash-out with 40 cc of normal saline solution was performed with subsequent emission of large watery non-blood stained stools. His oxygen saturation was 98% and he was still febrile with a temperature of 38.5°C. Six hours after the admission, he repeated a thoracic and an abdominal X-ray that showed diffusely dilated loops of bowel [Figure 1].

Subsequently, the patient underwent abdominal ultrasounds that raised the suspicion of an appendicular phlegmon. A decision was made to proceed for a surgical exploration via a transverse supra-umbilical laparotomy. Entering the peritoneal cavity, free purulent material was encountered and the caecum was found in the right iliac fossa. A gangrenous appendix was removed, multiple intra-abdominal abscesses (sub-hepatic, sub-diaphragmatic and pelvic) were drained and an extensive peritoneal washing was carried out [Figure 2]. Postoperatively, patient was given a seven-day treatment with intravenous Ceftriaxone 750 mg/die and Metronidazole 240 mg/die. On day four, he was started an enteral feeding. The post-operative course has been unremarkable and the child was discharged on day 8 post-operative from our department without any pharmacologic therapy. On the follow-up controls, at 7 and 30 days, the baby was fine.

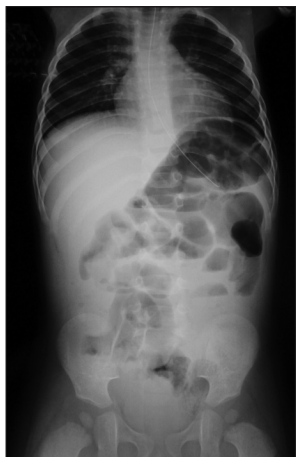

Figure 1: The anteroposterior sitting X-ray showing bowel meteoric distension showing some air fluid levels in central and left quadrants of the abdomen and accentuation of vascular hilar and perihilar pulmonary markings without signs of consolidation

DISCUSSION

Appendicitis is the most common paediatric abdominal acute surgical condition. The disease reaches its maximal incidence in teens and twenties, it becomes decreasingly common throughout childhood and it is even rarer in infants, having an incidence of 1 to 2 cases per 10,000 children per year between birth and the age of 4 years.^[5]

Possible reasons for this low incidence in infancy include a wide-based and a conical shaped appendix, a predominantly liquid and soft solid diet given to infants, the absence of prolonged periods in the upright position and the infrequency of upper respiratory infections that may cause hyperplasia of appendiceal lymphoid tissues.

Moreover, an accurate diagnosis of the disease in infants is very difficult because of the atypical clinical presentation that may simulate other more frequent pathological conditions. Nonetheless, the inability of the small patient to provide a detailed history of the illness further delays the diagnosis.

Unspecific signs and symptoms, together with the rarity of this disorder in infancy, account for overall misdiagnosis rate between 70% and 100% in children 3 years old or younger.^[6]

In addition, literature shows that in a great percent of cases, children with a late diagnosis of appendicitis had already been examined by other physicians without a suspicion of abdominal pathology.^[3]

As a matter of fact, cases of a respiratory, urinary, or gastrointestinal infections subsequently evolved to

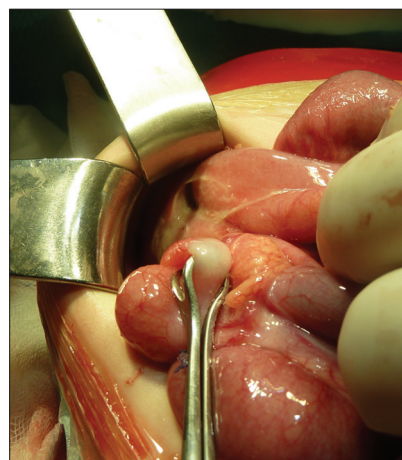


Figure 2: Intraoperative picture showing the sub-hepatic fluid collection and fibrin

acute appendicitis are documented. It is demonstrated that the incidence of appendicitis can increase during viral epidemics and bacterial gastroenteritis.^[7]

Therefore, even though upper respiratory infections are less frequent in children less than 2 years old, an increased index of suspicion of subsequent abdominal involvement should be kept in mind. This could decrease the number of patients discharged with either incorrect or incomplete diagnoses.^[8]

For all these reasons, the great majority of infants almost universally presents when appendiceal perforation has already occurred, being the incidence of perforation close to 100% in infants less than a year of age, between 70% and 80% in children under 2 years and above 50% up to the age of five years.^[3]

In preschool children, the differential diagnoses to consider include acute gastroenteritis, pneumonia, intussusception and Meckel's diverticulitis. Patients with gastroenteritis generally present diarrhoea and vomiting, the latter normally preceding or coinciding with the onset of abdominal pain in the absence of peritoneal signs.^[6] Intussusception is also a common cause of abdominal pain at this age but it is usually characterised by currant jelly stools or blood on rectal examination. Meckel's diverticulitis is the most similar clinical entity to appendicitis but a preoperative differential diagnosis is often difficult to achieve due to unspecificity of the laboratory and clinical findings. Severe constipation or right lower lobe pneumonia should also be considered in the differential diagnosis.^[7]

Abdominal radiographs can be useful to exclude the two latest conditions. In the contrary, they cannot provide a positive diagnosis of appendicitis being the faecalith demonstrated in less than 20% of cases. Ultrasounds, considered the gold standard for the diagnosis of appendicitis with an accuracy close to 100%, become less specific if the appendix ruptures, which is very common in preschool-age children.^[9]

Many authors suggest a more comprehensive utilisation of preoperative imaging, especially in neonates and infants, in order to avoid missed diagnosis, unnecessary surgery and adverse outcomes.^[10]

Contrariwise, other studies show that a higher diagnostic accuracy may prolong pre-operative time, delay surgical treatment with consequent protracted hospitalisation, increased morbidity and mortality

and avoidable costs.^[10] In our experience, clinical examination is still the gold standard to identify which children should undergo surgical exploration. Once the diagnosis of appendicitis is highly suspected, the treatment consists in surgical exploration.

In our case, even in the presence of an ultrasonographic evidence of flemmonous appendix, our decision was to approach the peritoneal cavity through a supraumbilical transverse incision. In fact, the very low incidence of the disease in infants, the difficult diagnosis and the big amount of diseases which could simulate appendicitis led our surgical team to perform such an incision in order to achieve a wider abdominal exposure.^[2,5]

CONCLUSIONS

Appendicitis may represent a cause, although not common, of acute abdomen in infants. We suggest to keep a particular attention to children presenting with a history of upper respiratory tract infection since the presence of symptoms such as cough and grunting can mislead the diagnosis, especially in the absence of clear abdominal signs. A higher diagnostic accuracy rate, although achievable with imaging techniques nowadays available, could cause a delay in the definitive treatment which may be associated with an increased number of perforated appendixes, with a prolonged hospitalisation and a higher morbidity and mortality rate.

Appendicitis in children less than 2 years of age presenting with respiratory signs can pose a diagnostic dilemma even for experienced paediatric surgeons. Diagnosis must not be excessively delayed and the clinician should be primarily guided by a prompt and exhaustive clinical evaluation.

REFERENCES

1. Sakellaris G, Tilemis S, Charissis G. Acute appendicitis in preschool-age children. *Eur J Pediatr* 2005;164:80-3.
2. Nance ML, Adamson WT, Hedrick HL. Appendicitis in the young child: A continuing diagnostic challenge. *Pediatr Emerg Care* 2000;16:160-2.
3. Alloo J, Gerstle T, Shilyansky J, Ein SH. Appendicitis in children less than 3 years of age: A 28-year review. *Pediatr Surg Int* 2004;19:777-9.
4. Lin YL, Lee CH. Appendicitis in infancy. *Pediatr Surg Int* 2003;19:1-3.
5. Ohmann C, Franke C, Kraemer M, Yang Q. [Status report on epidemiology of acute appendicitis]. *Chirurg* 2002;73:769-76.
6. Rothrock SG, Pagane J. Acute appendicitis in children: Emergency department diagnosis and management. *Ann Emerg Med* 2000;36:39-51.
7. Chang YJ, Chao HC, Kong MS, Hsia SH, Yan DC. Misdiagnosed acute appendicitis in children in the emergency department. *Chang Gung Med J* 2010;33:551-7.

8. Singer JI, Losek JD. Grunting respirations: Chest or abdominal pathology? *Pediatr Emerg Care* 1992;8:354-8.
9. Rothrock SG, Skeoch G, Rush JJ, Johnson NE. Clinical features of misdiagnosed appendicitis in children. *Ann Emerg Med* 1991;20: 45-50.
10. Vainrib M, Buklan G, Gutermacher M, Lazar L, Werner M, Rathaus V, *et al.* The impact of early sonographic evaluation on hospital admissions of children with suspected acute appendicitis. *Pediatr Surg Int* 2011;27:981-4.

Cite this article as: Citation will be included before issue gets online***

Source of Support: Nil. **Conflict of Interest:** None declared.

New features on the journal's website

Optimized content for mobile and hand-held devices

HTML pages have been optimized of mobile and other hand-held devices (such as iPad, Kindle, iPod) for faster browsing speed.

Click on [**Mobile Full text**] from Table of Contents page.

This is simple HTML version for faster download on mobiles (if viewed on desktop, it will be automatically redirected to full HTML version)

E-Pub for hand-held devices

EPUB is an open e-book standard recommended by The International Digital Publishing Forum which is designed for reflowable content i.e. the text display can be optimized for a particular display device.

Click on [**EPub**] from Table of Contents page.

There are various e-Pub readers such as for Windows: Digital Editions, OS X: Calibre/Bookworm, iPhone/iPod Touch/iPad: Stanza, and Linux: Calibre/Bookworm.

E-Book for desktop

One can also see the entire issue as printed here in a 'flip book' version on desktops.

Links are available from Current Issue as well as Archives pages.

Click on  View as eBook

Copyright of African Journal of Paediatric Surgery is the property of Medknow Publications & Media Pvt. Ltd. and its content may not be copied or emailed to multiple sites or posted to a listserv without the copyright holder's express written permission. However, users may print, download, or email articles for individual use.