



ELSEVIER



REVIEW

# Updated Scar Management Practical Guidelines: Non-invasive and invasive measures



Stan Monstrey <sup>a,\*</sup>, Esther Middelkoop <sup>b</sup>, Jan Jeroen Vranckx <sup>c</sup>,  
Franco Bassetto <sup>d</sup>, Ulrich E. Ziegler <sup>e</sup>, Sylvie Meaume <sup>f</sup>,  
Luc Téot <sup>g</sup>

<sup>a</sup> Plastic and Reconstructive Surgery Department, Burn Centre, Ghent University Hospital, Ghent, Belgium

<sup>b</sup> Association of Dutch Burn Centres, Beverwijk and Department of Plastic Reconstructive and Hand Surgery, Research Institute MOVE, VU University Medical Centre, Amsterdam, The Netherlands

<sup>c</sup> Department of Plastic and Reconstructive Surgery, KUL Leuven University Hospitals, Leuven, Belgium

<sup>d</sup> Plastic Surgery Institute, University of Padova, Padua, Italy

<sup>e</sup> Plastic and Aesthetic Surgery, Stuttgart Sporerstrasse, Germany

<sup>f</sup> Geriatric Department, Rothschild Hospital, University of Paris 6, Paris, France

<sup>g</sup> Wound Healing Unit and Burns Surgery, Montpellier University Hospital, Montpellier, France

Received 9 August 2013; accepted 16 April 2014

## KEYWORDS

Guideline;  
Plastic surgeon;  
Scar;  
Silicone;  
Surgery

**Summary** Hypertrophic scars and keloids can be aesthetically displeasing and lead to severe psychosocial impairment. Many invasive and non-invasive options are available for the plastic (and any other) surgeon both to prevent and to treat abnormal scar formation. Recently, an updated set of practical evidence-based guidelines for the management of hypertrophic scars and keloids was developed by an international group of 24 experts from a wide range of specialities.

An initial set of strategies to minimize the risk of scar formation is applicable to all types of scars and is indicated before, during and immediately after surgery. In addition to optimal surgical management, this includes measures to reduce skin tension, and to provide taping, hydration and ultraviolet (UV) protection of the early scar tissue. Silicone sheeting or gel is universally considered as the first-line prophylactic and treatment option for hypertrophic scars and keloids. The efficacy and safety of this gold-standard, non-invasive therapy has been demonstrated in many clinical studies. Other (more specialized) scar treatment options are available for high-risk patients and/or scars. Pressure garments may be indicated for more widespread scarring, especially after burns. At a later stage, more invasive or surgical

\* Corresponding author. Department of Plastic Surgery, Ghent University Hospital, De Pintelaan, 185, B-9000 Ghent, Belgium. Tel.: +32 93 32 32 26; fax: +32 93 32 38 99.

E-mail address: [Stan.Monstrey@UGent.be](mailto:Stan.Monstrey@UGent.be) (S. Monstrey).

procedures may be necessary for the correction of permanent unaesthetic scars and can be combined with adjuvant measures to achieve optimal outcomes.

The choice of scar management measures for a particular patient should be based on the newly updated evidence-based recommendations taking individual patient and wound characteristics into consideration.

© 2014 British Association of Plastic, Reconstructive and Aesthetic Surgeons. Published by Elsevier Ltd. All rights reserved.

## Introduction

Plastic surgeons play an important role in both the prevention and the treatment of unaesthetic scar formation following operations, trauma, burns or infections. Estimates indicate that each year around 100 million people in the developed world acquire scars following elective surgery and surgery for trauma.<sup>1</sup> Of these, approximately 15% have excessive or unaesthetic scars.<sup>1</sup> Scarring can also be a major source of dissatisfaction after a purely cosmetic surgical procedure such as aesthetic breast surgery.<sup>2</sup> Furthermore, a recent survey indicated that 91% of patients who underwent a routine surgical procedure would value any improvement in scarring.<sup>3</sup>

Excessive scarring can have unpleasant physical, aesthetic, psychological and social consequences. Physical symptoms may include itching, stiffness, scar contractures, tenderness and pain.<sup>4,5</sup> The psychosocial effects of unaesthetic scarring include diminished self-esteem, stigmatization, disruption of daily activities, anxiety and depression.<sup>5-7</sup>

There is a wide spectrum of cutaneous scarring ranging from mature linear scars to abnormal raised and widespread hypertrophic scars and major keloids. Hypertrophic scars stay within the boundaries of the original lesion and may spontaneously regress with time.<sup>8,9</sup> Hypertrophic scars can be classified as linear or widespread with the former usually resulting from surgery or trauma, and the latter from burn injuries or extensive soft tissue trauma and/or infections. Keloids are excessive scars that grow beyond the boundaries of the original wound. They do not spontaneously regress and frequently recur after being excised.<sup>8,9</sup> Keloids can be differentiated into minor or major with the latter being large, raised (>0.5 cm) scars that may be painful, pruritic and protruding. Histologically, there are additional differences between hypertrophic scars and keloids. For example, hypertrophic scars primarily contain well-organized type III collagen, whereas keloids contain disorganized type I and III collagen bundles.<sup>10</sup> Although existing strategies for the management of hypertrophic scars and keloids are broadly similar, these histological differences suggest that, in the future, therapeutic approaches could be developed which are specifically tailored for these different types of scars.

Currently, a wide variety of different scar management measures has been advocated both to prevent and to treat unaesthetic or excessive scar formation (Table 1). Recently, an international, multidisciplinary group of 24 experts developed a set of practical, evidence-based guidelines for

the management of linear, hypertrophic and keloid scars which could be useful for surgeons, dermatologists, general practitioners and other physicians involved in the prevention and the treatment of scars.<sup>11</sup> The panel developed these guidelines after reviewing new clinical and evidence-based data on scar management that have been reported since the publication of a previous set of guidelines by the International Advisory Panel on Scar Management in 2002.<sup>12</sup> This review article is intended to provide surgeons and other physicians with an overview of the most relevant information from the updated guidelines. Whilst there are many published review articles on treatment approaches for hypertrophic scars and keloids, the current article is different in that it presents these new guidelines and discusses the most relevant aspects for surgeons. In particular, specific surgical techniques that are of benefit in both the prevention and treatment of scars are discussed.

The literature cited in this article includes the most relevant publications that were used to develop the recent evidence-based guidelines.<sup>11</sup> In addition, PubMed was searched using terms including 'scar prevention', 'scar treatment', 'hypertrophic scar', 'keloid', 'silicone', 'intralesional corticosteroid', 'pressure therapy', 'laser therapy', 'radiotherapy' and 'cryotherapy' to identify additional studies and review articles on scar management that are of particular relevance to surgeons. Whilst this article is not a systematic literature review of treatment options for scar management, we do refer interested

**Table 1** Overview of non-invasive and invasive treatments for scars.

Non-invasive treatment	Invasive treatment
<ul style="list-style-type: none"> <li>• <b>Well-accepted, evidence-based, and recommended treatments</b></li> </ul>	
<ul style="list-style-type: none"> <li>• Pressure/compression therapy</li> </ul>	<ul style="list-style-type: none"> <li>• Intralesional corticosteroid injection</li> </ul>
<ul style="list-style-type: none"> <li>• Silicone sheets and gels</li> </ul>	<ul style="list-style-type: none"> <li>• Surgical scar correction</li> </ul>
<ul style="list-style-type: none"> <li>• <b>Investigational treatments and those with less supporting evidence</b></li> </ul>	
<ul style="list-style-type: none"> <li>• Oils, lotions and creams</li> <li>• Massage therapy</li> <li>• Static and dynamic splints</li> <li>• Psychological counselling</li> </ul>	<ul style="list-style-type: none"> <li>• Laser therapy</li> <li>• Radiotherapy</li> <li>• Cryosurgery</li> <li>• Intralesional injection of other products</li> <li>• Antihistamine drugs</li> </ul>

readers to our Scar Management Practical Guidelines book for more extensive lists of supporting references.<sup>11</sup>

### Scar Management Practical Guidelines

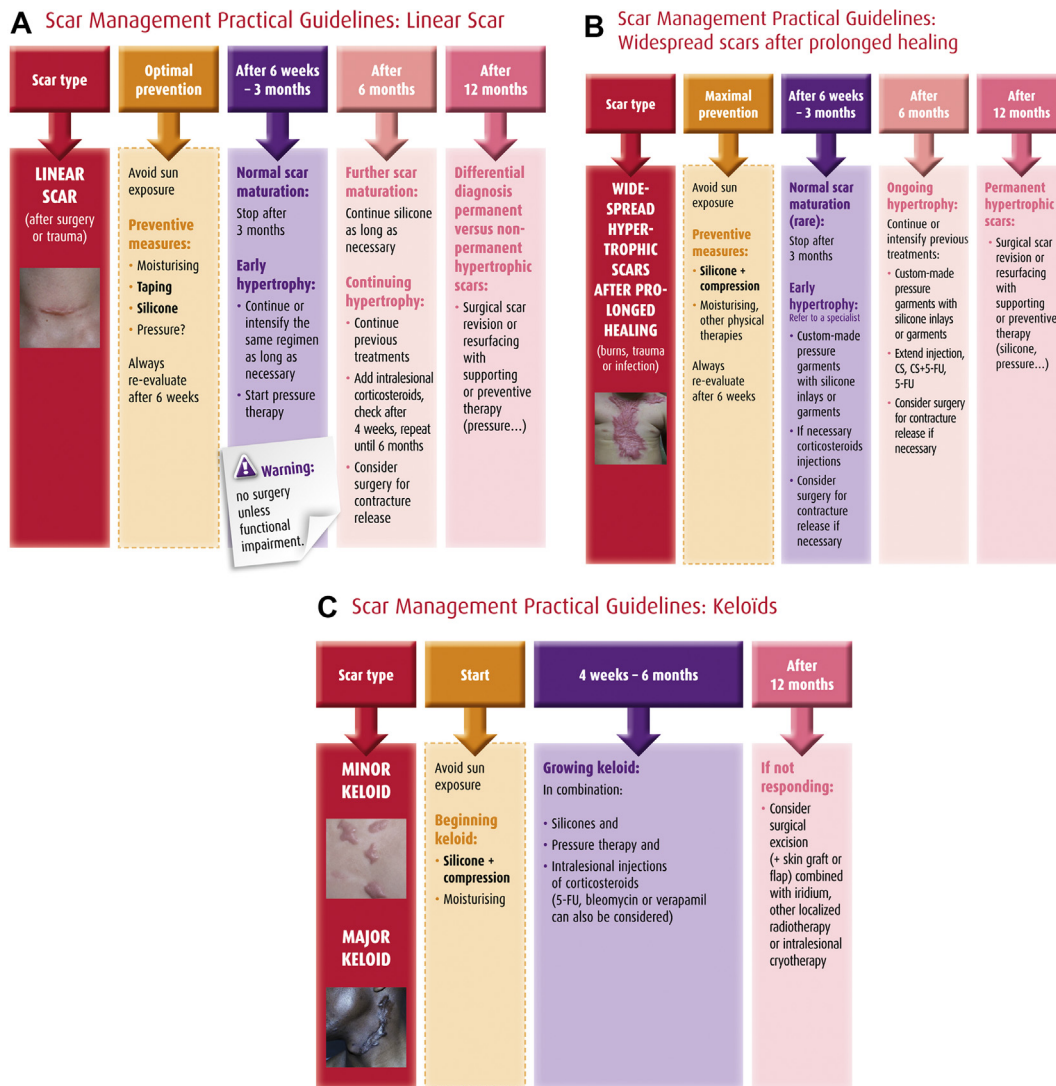
A summary of the updated guidelines on the practical management of linear scars, widespread hypertrophic scars and keloids is shown in Figure 1. The recommendations are discussed more in detail below with an emphasis both on universal preventive strategies applicable to every scar and on more invasive and specialized treatment of excessive scar formation.

#### Scar prevention

Following surgery or trauma, the first priority should always be the *prevention* of abnormal scar formation. In the case of an operative procedure, scar prevention measures should be initiated during or even before surgery. In

elective surgery, the position and the length of the incision line should be carefully considered and if possible should always be parallel to the relaxed skin tension lines. Excessive scar formation can also be prevented by a wide range of measures that reduce inflammation and provide rapid wound closure such as early debridement of dead tissue, reducing the risk of infection through rinsing and disinfection, and optimal dressings providing moist wound healing and/or early surgical wound coverage.<sup>11,13</sup> During the operation, the surgeon should also ensure that excessive tension on the wound edges is avoided.

The three major components of scar prevention immediately after wound closure are as follows: (1) tension relief, (2) hydration/taping/occlusion, and (3) pressure garments. Wounds which have greater tension on their edges, e.g., those perpendicular to Langer’s lines, and those in the deltoid and sternal regions have a higher risk of developing excessive scarring,<sup>14</sup> which can be reduced by the use of post-surgical taping for a 3-month period.<sup>15</sup> More recently, Gurtner et al. investigated the role of mechanical



**Figure 1** Practical guidelines for the management of linear (A), widespread hypertrophic (B) and keloid scars (C). Reproduced with the permission of Maca-Cloetens from ‘Scar Management Practical Guidelines’.

forces on scar formation and the effectiveness of a stress-shielding device in reducing mechanical stress and preventing excessive scar formation.<sup>16</sup> The device was made from silicone polymer sheets and pressure-sensitive adhesive and was applied to wounds immediately after skin closure. Studies in both animals and humans demonstrated that offloading mechanical forces with the stress-shielding device significantly reduced scar formation.<sup>16</sup> In addition, botulinum toxin A decreases tensile forces on post-surgical scars and results in significant improvements in the cosmetic appearances of scars compared with placebo injections.<sup>17</sup>

Moisturizing emollient and humectant creams and moisture-retentive dressings such as silicone sheets and fluid silicone gel have been shown to be beneficial for itching scars, and can also reduce the size and pain or discomfort associated with scars as well as improving their appearance. Studies have shown that, after wound healing, water still evaporates more rapidly through scar tissue and may take over a year to recover to pre-wound levels.<sup>18</sup> Silicone products may help to prevent excessive scar formation by restoring the water barrier through occlusion and hydration of the stratum corneum and need to be used as soon as the wound/suture is healed.<sup>19</sup>

In patients with more widespread scars, such as after burns, pressure garments may also be used prophylactically in wounds that take >2–3 weeks to heal spontaneously with the device being applied as soon as the wound is closed and the patient can tolerate the pressure.<sup>11,20</sup>

Other strategies are currently under investigation for the prevention of scarring such as altering the levels of certain inflammatory cytokines such as transforming growth factor (TGF)- $\beta$ 3. This cytokine reduces connective tissue deposition and is mainly produced towards the end of the wound healing process.<sup>10</sup> Initial clinical studies of avotermin, a human recombinant TGF- $\beta$ 3, have indicated that this treatment may reduce scar formation following full-thickness skin incisions.<sup>21</sup>

Additional general preventive measures for all types of scars recommended in the latest guidelines (Figure 1(A–C)) include avoiding exposure to sunlight and the continued use of sunscreens with a high to maximum sun protection factor (>50) until the scar has matured.<sup>11</sup> Randomized studies in animals and humans have shown that ultraviolet radiation increases scar pigmentation and worsens their clinical appearance.<sup>22,23</sup>

As a general rule, scars should *always be re-evaluated 4–8 weeks after surgery* to determine whether additional scar management interventions are required or whether preventive therapy can be terminated.<sup>11</sup>

### Linear hypertrophic scars

The guidelines recommend that the preventive therapy as described above is continued or intensified in patients who develop early hypertrophy in their linear scar at 6 weeks to 3 months after surgery or trauma.<sup>11</sup> Pressure therapy may be initiated if this has not yet been applied.

If there is further scar maturation 6 months after surgery or trauma, silicone therapy should be continued for as long as necessary. In patients with ongoing hypertrophy, more

invasive measures are indicated such as the use of intralesional corticosteroids. This is the only invasive management option which currently has enough supporting evidence to be recommended in evidence-based guidelines.<sup>11,12</sup> The most commonly used corticosteroid is triamcinolone acetonide 10–40 mg/mL which should be injected into the papillary dermis every 2–4 weeks until the scar is flattened.<sup>8</sup> Between 50% and 100% of patients respond to this treatment with 9–50% experiencing recurrence.<sup>24</sup> Excessive pain during injections can lead to non-compliance with the treatment. Other side effects include skin atrophy, hypopigmentation and telangiectasias.<sup>8,25</sup>

Although the likelihood of developing hypertrophic scars is often thought to be greater in children than in the elderly with much more time required for their scars to mature, there is hardly any evidence to support this in the literature.<sup>26</sup> Despite the fact that there are very few studies on the technique of corticosteroid injections in children, most experts agree that this technique is not contraindicated in these young patients, but that dose adaptation to the child's weight is advised to avoid systemic exposure.<sup>27,28</sup> The corticosteroid injection should always be limited to the scar itself and injection into the periscar tissues must be avoided as this may cause underlying fat atrophy irrespective of a patient's age.<sup>29</sup>

Additional injectable treatment options which may help to treat hypertrophic scars (and keloids) include bleomycin, 5-fluorouracil and verapamil, although the evidence to support these is currently more limited than for intralesional corticosteroids.<sup>11,30–32</sup> Bleomycin is thought to work by decreasing collagen synthesis and, in a study of 50 patients, was shown to adequately flatten hypertrophic scars and keloids in 80% of patients.<sup>30</sup> 5-Fluorouracil inhibits fibroblast proliferation and has been shown to be an effective treatment for inflamed hypertrophic scars.<sup>31</sup> A combination of 5-fluorouracil and triamcinolone acetonide may be more effective at treating scars than the individual treatments.<sup>31,33,34</sup> For example, this combination was associated with significantly greater reductions in scar size and erythema compared with triamcinolone acetonide alone in a 12-week double-blind study of 40 patients.<sup>34</sup> Verapamil is a calcium channel antagonist which both decreases collagen synthesis and increases collagen breakdown. In a randomized, single-blind study of 54 patients with hypertrophic scars or keloids, scar vascularity, pliability, height and width were reduced with intralesional verapamil, although the rate of reduction in these parameters was slower than with intralesional triamcinolone.<sup>32</sup> A scar contracture is an abnormal shrinkage or shortening of a non-matured scar that can result in functional impairment and is often seen in combination with scar hypertrophy. Surgical correction of a scar contracture with a Z-plasty, a skin graft or a flap may be indicated at an early stage to release tension in the scar which eventually restores function and at the same time reduces scar hypertrophy.

If the patient develops a permanent (>1 year) hypertrophic scar, surgical scar revision may be considered.<sup>35,36</sup> Aesthetic correction of linear hypertrophic scars is usually done by simple resection and primary closure together with a type of tension-releasing technique such as undermining and approximation of the wound edges, subcutaneous

sutures, adding a Z-plasty or the use of surgical taping and silicone gels after wound closure.<sup>35</sup>

### Widespread hypertrophic scars

Early application of silicone and compression therapy is essential for patients who are at a risk of widespread hypertrophic scars following burns, mechanical trauma or necrotizing infections. Pressure and silicone therapy should be routinely applied in every wound that takes >2–3 weeks to heal or after skin grafting, and should be given as soon as the wound is closed and the patient can tolerate pressure.<sup>11,20</sup>

Pressure therapy has recently been considered as an 'evidence-based' modality for the treatment of scars.<sup>20</sup> The mechanism of its action remains poorly understood despite its widespread use around the world. Part of the effect of pressure could involve reduction of oxygen tension in the wound through occlusion of small blood vessels resulting in a decrease of (myo)fibroblast proliferation and collagen synthesis.<sup>37</sup>

Recent studies underline the critical role of cellular mechanoreceptors in the high success rate of compression therapy. Mechanoreceptors are involved in cellular apoptosis and are linked to the extracellular matrix. It is conceivable that increased pressure via the matrix regulates apoptosis of dermal fibroblasts and diminishes the hypertrophic process.<sup>38</sup> In addition, through the process of mechanotransduction, sensory nerve cells transduce mechanical pressure into intracellular biochemical and gene expression, thus synthesizing and releasing different cytokines that may play a role in the physiopathogenesis of proliferative scarring.<sup>39</sup>

Finally, besides these causative effects, pressure therapy can also provide symptomatic treatment benefits such as the alleviation of oedema, itchiness and pain which may contribute to the patient's well-being.<sup>40</sup>

The initial treatment of pressure and silicone therapy should be continued or intensified in patients with ongoing hypertrophy. Localized corticosteroid injections can also be indicated to treat the more excessive parts of hypertrophic scars and these can be supplemented with bleomycin, 5-fluorouracil and/or verapamil as appropriate.<sup>11,30,31,33,41</sup> These therapies should preferably be reserved for use in specialized centres in which there is a greater degree of expertise.

Laser therapy is another invasive option which can be used to treat the surface texture of abnormal scars and may also be suitable for the treatment of residual redness, telangiectasias or hyperpigmentation.<sup>11</sup> Vrijman et al., in a recent meta-analysis, demonstrated scientific evidence only for the pulsed dye laser (PDL) 585 and not for the intense pulsed light (IPL), the non-ablative fractional laser (NAFL) 1550 nm, the CO<sub>2</sub> ablative fractional laser (AFL), the 532-nm laser and the 2940-nm erbium laser.<sup>42</sup> Since the publication of this meta-analysis, a case series has been published confirming the efficacy of the PDL, especially in combination with occlusion/compression and intralesional corticosteroids.<sup>43</sup> In addition, there have also been several positive reports on the NAFL 1550 nm and the CO<sub>2</sub> AFL.<sup>44–46</sup> Various other lasers have also been used in the treatment of

scars: Nd:YAG long pulse 1064 nm,<sup>47</sup> Q-switch Nd:YAG,<sup>48</sup> light-emitting diodes (LEDs) and photodynamic therapy (PDT).<sup>49</sup> Finally, laser therapy has also been advocated for the prevention or minimization of both post-surgical and traumatic scars, and even in combination with botulinum toxin.<sup>50</sup> Although more clinical evidence on the use of lasers is needed, both for the choice of the device as well as for the settings/treatment schedules, the increasing number of articles being published on the successful management of hypertrophic scars with lasers is increasing the interest in this therapeutic modality.

As mentioned previously, early surgery is always indicated in the case of contractures with functional impairment. Contracture release after burns in areas such as the neck and axilla are best performed with flaps rather than with skin grafts as flaps usually develop minimal secondary contraction and therefore produce excellent functional and aesthetic results.

Long-standing or permanent widespread hypertrophic scars may be treated surgically, sometimes using the same techniques as for permanent linear hypertrophic scars. For larger scars, serial excision or skin stretching may be indicated which involves the advancement of adjacent skin by sufficient undermining after resection of the central part of the scar.<sup>11,51</sup> Subcutaneous sutures are needed to relieve the tension from the overlying skin given that this procedure involves stretching the skin. Surgical skin replacement (resurfacing) of unaesthetic widespread scars may be performed using autologous skin grafts.<sup>52</sup> Dermal substitutes may also be used for skin resurfacing in patients with extensive skin trauma such as those with severe burns.<sup>53</sup> Tissue expansion is also a very helpful technique for surgical scar correction, especially for reconstruction of the scalp. These surgical reconstruction procedures should ideally be performed in dedicated specialized centres.

### Keloids

Keloids are also best treated in centres with specialized expertise. Patients with growing minor or major keloids should first be treated with silicones in combination with pressure therapy and intralesional injections of corticosteroids.<sup>11</sup> Intralesional 5-fluorouracil, bleomycin and verapamil can also be considered, preferably in accordance with existing treatment protocols.<sup>8,11,30,31,41,54</sup> If the keloid does not respond to 12 months of these treatments, then surgical excision should be considered always in combination with some form of adjuvant therapy as surgical excision alone has been associated with a high recurrence rate of 50–100% and may even result in enlargement of the keloid.<sup>8</sup> Some experts recommend that the lateral parts of keloids should not be excised, but should be joined together and left in situ. However, others have objected to this proposal and consider that the cells from these lateral parts of the keloid are more active in terms of collagen production.<sup>55</sup>

The combination of scar resection and immediate post-operative radiotherapy was proposed many years ago, and both electron beam irradiation and brachytherapy with iridium 192 can be used after surgical removal of the keloid to reduce recurrence rates.<sup>56</sup> Many objections have been

raised concerning the potential side effects of post-operative radiotherapy, especially regarding the potential risk of inducing malignancy. However, on the basis of an extensive review of literature on this subject, Ogawa et al. concluded that the risk of malignancy attributable to keloid radiation therapy is minimal.<sup>57</sup>

An additional promising new invasive treatment modality for keloids is internal cryotherapy in which a metal rod is introduced into the keloid and the subsequent extreme cooling leads to tissue necrosis.<sup>58</sup> In a study of 10 patients, scar volume was significantly reduced by 54% after one intralesional treatment with no recurrence over an 18-month follow-up period.<sup>58</sup>

Finally, imiquimod 5% is a topical immune response modifier which stimulates the production of interferon leading to increased collagen breakdown. Some studies have reported low recurrence rates of 0–29% following surgical excision of keloids and subsequent topical application of imiquimod 5% cream.<sup>59,60</sup> However, other studies have reported that imiquimod 5% cream is not effective at preventing keloid recurrence with recurrence rates of 89%.<sup>61</sup>

### First-line non-invasive scar management: more evidence on the role of silicone therapy

The latest guidelines for scar management advocate silicone therapy as a non-invasive first-line prophylactic and treatment option for both hypertrophic scars and keloids.<sup>11</sup> Indeed, of the non-invasive options, *silicone sheets and silicone gels* are universally considered as the gold standard in scar management and the only non-invasive preventive and therapeutic measure for which there is enough supporting data to make evidence-based recommendations.<sup>12</sup> Silicone therapy is an attractive alternative to more invasive treatment options as it is easy to use and is associated with only minimal side effects such as pruritus, contact dermatitis and dry skin.<sup>62</sup> This therapy is believed to prevent and treat scars through occlusion and subsequent hydration of the scar tissue.<sup>19</sup>

Silicone sheeting consists of a soft, semi-occlusive gel sheet made from medical-grade silicone that is reinforced with a silicone membrane backing to give the sheet increased durability and ease of handling. Some sheets use a combination of silicone and Teflon® (polytetrafluoroethylene) to create ultra-thin, flexible and durable sheeting. Patients may be reluctant to use the sheeting on exposed areas of the body, and compliance with treatment is a frequent concern.<sup>63</sup>

Recently, fluid silicone gel formulations have been developed using the same basic long-chain silicone polymer that is used in silicone sheeting. This more recent formulation of silicone for scar treatment was specifically developed to overcome some of the problems encountered with silicone gel sheets such as the need for fixation and difficulties in using sheets on large areas or near joints as well as on exposed areas such as the face and hands. The fluid silicone gel is applied in a thin layer to the skin where it dries to form a transparent, flexible, gas-permeable, water-impermeable silicone sheet. Similar to silicone sheeting, silicone gels should not be applied to open

wounds and can be used for as long as the patient derives benefit.

The pivotal role of silicone sheeting for the prevention and treatment of hypertrophic scars and keloids resulting from many types of trauma, including burns and surgical excisions, has been established in many clinical studies with all but one showing positive effects.<sup>63–71</sup> A meta-analysis found that silicone sheeting reduces the incidence of hypertrophic scarring in high-risk individuals compared with no treatment (response rate: 0.46; 95% confidence interval 0.21–0.98).<sup>72</sup> Recent data have also shown that silicone sheeting can be used in combination with pressure therapy producing better improvements in post-traumatic hypertrophic scars than either therapy alone. The two treatments have complementary modes of action with the silicone therapy acting on the erythema and pliability of the scar, whereas the pressure therapy prevents scar thickening.<sup>73</sup>

Several clinical studies have indicated the beneficial effects of silicone gels in the prevention and treatment of scars.<sup>74–78</sup> Several comparative studies with silicone sheets have shown that fluid silicone gels have at least equivalent efficacy although patients may find the gel formulations easier to use.<sup>78,79</sup>

### Conclusions

Unaesthetic scarring is associated with physical and psychosocial consequences. Plastic surgeons play an essential role in minimizing scar formation after elective surgery and in correcting unaesthetic scars once matured. Choices regarding appropriate scar management measures should be guided by the clinical recommendations provided in this consensus article, but should also be tailored to individual patient and wound requirements. Preventive measures are a major priority and need to be applied before, during and immediately after wound closure. Treatment of hypertrophic scars, contractures and keloids is generally based on reducing mechanical tension in the scar, removal of the bulky scar tissue by reconstructive surgical techniques and/or injection of substances that promote collagen breakdown in situ. Silicone sheets and gels are recommended as the 'gold standard', non-invasive therapies for both the prevention and the treatment of hypertrophic scars and keloids with gels being preferred by patients. These products can be used in combination with other invasive and non-invasive treatment options to provide patients with optimal outcomes.

### Conflict of interest statement

Stan Monstrey: None.

Esther Middelkoop: The Association of Dutch Burn Centres received financial support from Meda Pharma BV for part of a clinical study comparing Dermatix topical silicone gel to a placebo cream. The Dermatix topical silicone gel was kindly provided by Meda Pharma BV.

Jan Jeroen Vranckx: None.

Franco Bassetto: None.

Ulrich Ziegler: None.

Sylvie Meaume: None.

Luc Téot: None.

## Funding

Editorial assistance in the preparation of this manuscript was provided by David Harrison, Medscript Communications, funded by Meda Pharma SA. The manuscript sponsors were given an opportunity to review an initial version of the manuscript.

## Acknowledgements

The authors take full responsibility for the content of this publication. We thank the following authors of the Scar Management Practical Guidelines book for their invaluable contributions to the development of these guidelines: Nele Brusselaers (Burn Centre and Department of General Internal Medicine, Infectious Diseases and Psychosomatic Medicine, Ghent University Hospital, Ghent, Belgium), Maarten Doornaert and Henk Hoeksema (Department of Plastic and Reconstructive Surgery, Ghent University Hospital, Ghent, Belgium), Anibal Justiniano (Institute of Health Sciences, Catholic University, Porto, Portugal), Benoît Lengelé (Anatomy Department, Catholic University of Louvain, Brussels, Belgium), Anne Le Pillouer-Prost (Clairval Hospital, Marseille, France), Ali Pirayesh (Amsterdam Plastic Surgery, Amsterdam, The Netherlands and Department of Plastic and Reconstructive Surgery, Ghent University Hospital, Ghent, Belgium), Bertrand Richert (Dermatology Department, University Hospital Brugmann – Saint Pierre – Children’s Hospital Reine Fabiola, Université Libre de Bruxelles, Brussels, Belgium), Fabrice Rogge (Plastic and Reconstructive Surgery, Bruges, Belgium), Diane Roseeuw (Dermatology Department, Free University of Brussels, Jette, Belgium), Claude Roques (CSRE Lamalou le Haut, Pediatric Rehabilitation Centre, Lamalou-Les-Bains, France), Xavier Santos Heredero (Plastic and Reconstructive Surgery Department, University Hospitals of Madrid Montepincipe y Torrelodones, Madrid, Spain), Javid Vadoud (Clinique Parc Léopold, Brussels, Belgium), Eric Van den Kerckhove (Physical Medicine and Rehabilitation, University Hospital Gasthuisberg, KUL Leuven University Hospitals, Leuven, Belgium), Helga Van De Velde (Institute Helga Van De Velde, Ghent, Belgium), Nancy Van Loey (Association of Dutch Burns Centres, Beverwijk, The Netherlands) and Antoine J van Trier (Department of Plastic, Reconstructive and Handsurgery, Red Cross Hospital, Beverwijk, The Netherlands).

## References

1. Sund B [Clinical Report]. In: *New developments in wound care*, vol. 86. London: PJB Publications CBS; 2000. pp. 1–255.
2. Abu-Nab Z, Grunfeld EA. Satisfaction with outcome and attitudes towards scarring among women undergoing breast reconstructive surgery. *Patient Educ Couns* 2007;**66**:243–9.
3. Young VL, Hutchison J. Insights into patient and clinician concerns about scar appearance: semiquantitative structured surveys. *Plast Reconstr Surg* 2009;**124**:256–65.
4. Van Loey NE, Bremer M, Faber AW, Middelkoop E, Nieuwenhuis MK. Itching following burns: epidemiology and predictors. *Br J Dermatol* 2008;**158**:95–100.
5. Bell L, McAdams T, Morgan R, et al. Pruritus in burns: a descriptive study. *J Burn Care Rehabil* 1988;**9**:305–8.
6. Robert R, Meyer W, Bishop S, Rosenberg L, Murphy L, Blakeney P. Disfiguring burn scars and adolescent self-esteem. *Burns* 1999;**25**:581–5.
7. Bakker A, Maertens KJ, Van Son MJ, Van Loey NE. Psychological consequences of pediatric burns from a child and family perspective: a review of the empirical literature. *Clin Psychol Rev* 2013;**33**:361–71.
8. Juckett G, Hartman-Adams H. Management of keloids and hypertrophic scars. *Am Fam Physician* 2009;**80**:253–60.
9. Alster TS, Tanzi EL. Hypertrophic scars and keloids: etiology and management. *Am J Clin Dermatol* 2003;**4**:235–43.
10. Gauglitz GG, Korting HC, Pavicic T, Ruzicka T, Jeschke MG. Hypertrophic scarring and keloids: pathomechanisms and current and emerging treatment strategies. *Mol Med* 2011;**17**: 113–25.
11. Published by. In: Middelkoop E, Monstrey S, Teot L, Vranckx JJ, editors. *Scar Management Practical Guidelines*. Maca-Cloetens; 2011. pp. 1–109.
12. Mustoe TA, Cooter RD, Gold MH, et al. International clinical recommendations on scar management. *Plast Reconstr Surg* 2002;**110**:560–71.
13. Bloemen MC, van der Veer WM, Ulrich MM, van Zuijlen PP, Niessen FB, Middelkoop E. Prevention and curative management of hypertrophic scar formation. *Burns* 2009;**35**:463–75.
14. Bayat A, McGrouther DA, Ferguson MW. Skin scarring. *BMJ* 2003;**326**:88–92.
15. Reiffel RS. Prevention of hypertrophic scars by long-term paper tape application. *Plast Reconstr Surg* 1995;**96**:1715–8.
16. Gurtner GC, Dauskardt RH, Wong VW, et al. Improving cutaneous scar formation by controlling the mechanical environment: large animal and phase I studies. *Ann Surg* 2011;**254**: 217–25.
17. Gassner HG, Sherris DA, Otley CC. Treatment of facial wounds with botulinum toxin A improves cosmetic outcome in primates. *Plast Reconstr Surg* 2000;**105**:1948–53.
18. Suetake T, Sasai S, Zhen YX, Ohi T, Tagami H. Functional analyses of the stratum corneum in scars. Sequential studies after injury and comparison among keloids, hypertrophic scars, and atrophic scars. *Arch Dermatol* 1996;**132**: 1453–8.
19. Mustoe TA. Evolution of silicone therapy and mechanism of action in scar management. *Aesthetic Plast Surg* 2008;**32**: 82–92.
20. Engrav LH, Heimbach DM, Rivara FP, et al. 12-Year within-wound study of the effectiveness of custom pressure garment therapy. *Burns* 2010;**36**:975–83.
21. Ferguson MW, Duncan J, Bond J, et al. Prophylactic administration of avotermin for improvement of skin scarring: three double-blind, placebo-controlled, phase I/II studies. *Lancet* 2009;**373**:1264–74.
22. Haedersdal M, Bech-Thomsen N, Poulsen T, Wulf HC. Ultra-violet exposure influences laser-induced wounds, scars, and hyperpigmentation: a murine study. *Plast Reconstr Surg* 1998;**101**:1315–22.
23. Due E, Rossen K, Sorensen LT, Kliem A, Karlsmark T, Haedersdal M. Effect of UV irradiation on cutaneous cicatrices: a randomized, controlled trial with clinical, skin reflectance, histological, immunohistochemical and biochemical evaluations. *Acta Derm Venereol* 2007;**87**: 27–32.
24. Niessen FB, Spauwen PH, Schalkwijk J, Kon M. On the nature of hypertrophic scars and keloids: a review. *Plast Reconstr Surg* 1999;**104**:1435–58.
25. Sproat JE, Dalcin A, Weitauer N, Roberts RS. Hypertrophic sternal scars: silicone gel sheet versus Kenalog injection treatment. *Plast Reconstr Surg* 1992;**90**:988–92.
26. van der Wal MB, Vloemans JF, Tuinebreijer WE, et al. Outcome after burns: an observational study on burn scar

- maturation and predictors for severe scarring. *Wound Repair Regen* 2012;**20**:676–87.
27. Sclafani AP, Gordon L, Chadha M, Romo III T. Prevention of earlobe keloid recurrence with postoperative corticosteroid injections versus radiation therapy: a randomized, prospective study and review of the literature. *Dermatol Surg* 1996;**22**:569–74.
  28. Patel PA, Bailey JK, Yakuboff KP. Treatment outcomes for keloid scar management in the pediatric burn population. *Burns* 2012;**38**:767–71.
  29. Al-Attar A, Mess S, Thomassen JM, Kauffman CL, Davison SP. Keloid pathogenesis and treatment. *Plast Reconstr Surg* 2006;**117**:286–300.
  30. Aggarwal H, Saxena A, Lubana PS, Mathur RK, Jain DK. Treatment of keloids and hypertrophic scars using bleomycin. *J Cosmet Dermatol* 2008;**7**:43–9.
  31. Fitzpatrick RE. Treatment of inflamed hypertrophic scars using intralesional 5-FU. *Dermatol Surg* 1999;**25**:224–32.
  32. Margaret Shanthi FX, Ernest K, Dhanraj P. Comparison of intralesional verapamil with intralesional triamcinolone in the treatment of hypertrophic scars and keloids. *Indian J Dermatol Venereol Leprol* 2008;**74**:343–8.
  33. Davison SP, Dayan JH, Clemens MW, Sonni S, Wang A, Crane A. Efficacy of intralesional 5-fluorouracil and triamcinolone in the treatment of keloids. *Aesthet Surg J* 2009;**29**:40–6.
  34. Darougheh A, Asilian A, Shariati F. Intralesional triamcinolone alone or in combination with 5-fluorouracil for the treatment of keloid and hypertrophic scars. *Clin Exp Dermatol* 2009;**34**:219–23.
  35. Mathes SJ. *Plastic surgery*. 2–4. 2nd ed. Philadelphia: Elsevier Saunders; 2006.
  36. Cooper JS, Lee BT. Treatment of facial scarring: lasers, filler, and nonoperative techniques. *Facial Plast Surg* 2009;**25**:311–5.
  37. Macintyre L, Baird M. Pressure garments for use in the treatment of hypertrophic scars—a review of the problems associated with their use. *Burns* 2006;**32**:10–5.
  38. Reno F, Sabbatini M, Lombardi F, et al. In vitro mechanical compression induces apoptosis and regulates cytokines release in hypertrophic scars. *Wound Repair Regen* 2003;**11**:331–6.
  39. Yagmur C, Akaishi S, Ogawa R, Guneren E. Mechanical receptor-related mechanisms in scar management: a review and hypothesis. *Plast Reconstr Surg* 2010;**126**:426–34.
  40. Ripper S, Renneberg B, Landmann C, Weigel G, Germann G. Adherence to pressure garment therapy in adult burn patients. *Burns* 2009;**35**:657–64.
  41. D'Andrea F, Brongo S, Ferraro G, Baroni A. Prevention and treatment of keloids with intralesional verapamil. *Dermatology* 2002;**204**:60–2.
  42. Vrijman C, van Drooge AM, Limpens J, et al. Laser and intense pulsed light therapy for the treatment of hypertrophic scars: a systematic review. *Br J Dermatol* 2011;**165**:934–42.
  43. Goppold A, Kaune KM, Buhl T, Schon MP, Zutt M. 595 nm pulsed dye laser combined with intralesional corticosteroids in hypertrophic symptomatic scars following breast reduction surgery. *Eur J Dermatol* 2011;**21**:262–3.
  44. Lin JY, Warger WC, Izikson L, Anderson RR, Tannous Z. A prospective, randomized controlled trial on the efficacy of fractional photothermolysis on scar remodeling. *Lasers Surg Med* 2011;**43**:265–72.
  45. Pham AM, Greene RM, Woolery-Lloyd H, Kaufman J, Grunebaum LD. 1550-nm nonablative laser resurfacing for facial surgical scars. *Arch Facial Plast Surg* 2011;**13**:203–10.
  46. Ong MW, Bashir SJ. Fractional laser resurfacing for acne scars: a review. *Br J Dermatol* 2012;**166**:1160–9.
  47. Akaishi S, Koike S, Dohi T, Kobe K, Hyakusoku H, Ogawa R. Nd:YAG laser treatment of keloids and hypertrophic scars. *Eplasty* 2012;**12**:e1.
  48. Cho SB, Lee JH, Lee SH, Lee SJ, Bang D, Oh SH. Efficacy and safety of 1064-nm Q-switched Nd:YAG laser with low fluence for keloids and hypertrophic scars. *J Eur Acad Dermatol Venereol* 2010;**24**:1070–4.
  49. Sakamoto FH, Izikson L, Tannous Z, Zurakowski D, Anderson RR. Surgical scar remodelling after photodynamic therapy using aminolaevulinic acid or its methylester: a retrospective, blinded study of patients with field cancerization. *Br J Dermatol* 2012;**166**:413–6.
  50. Capon A, Iarmarcovai G, Gonnelli D, Degardin N, Magalon G, Mordon S. Scar prevention using laser-assisted skin healing (LASH) in plastic surgery. *Aesthetic Plast Surg* 2010;**34**:438–46.
  51. Verhaegen PD, van der Wal MB, Bloemen MC, et al. Sustainable effect of skin stretching for burn scar excision: long-term results of a multicenter randomized controlled trial. *Burns* 2011;**37**:1222–8.
  52. Hierner R, Degreef H, Vranckx JJ, Garmyn M, Massage P, van Brussel M. Skin grafting and wound healing—the “dermatoplastic team approach”. *Clin Dermatol* 2005;**23**:343–52.
  53. van der Veen VC, van der Wal MB, van Leeuwen MC, Ulrich MM, Middelkoop E. Biological background of dermal substitutes. *Burns* 2010;**36**:305–21.
  54. Naeini FF, Najafian J, Ahmadpour K. Bleomycin tattooing as a promising therapeutic modality in large keloids and hypertrophic scars. *Dermatol Surg* 2006;**32**:1023–9.
  55. Syed F, Ahmadi E, Iqbal SA, Singh S, McGrouther DA, Bayat A. Fibroblasts from the growing margin of keloid scars produce higher levels of collagen I and III compared with intralesional and extralesional sites: clinical implications for lesional site-directed therapy. *Br J Dermatol* 2011;**164**:83–96.
  56. Rio E, Bardet E, Peuvrel P, Pannier M, Dreno B. Perioperative interstitial brachytherapy for recurrent keloid scars. *Plast Reconstr Surg* 2009;**124**:180e–1e.
  57. Ogawa R, Yoshitatsu S, Yoshida K, Miyashita T. Is radiation therapy for keloids acceptable? The risk of radiation-induced carcinogenesis. *Plast Reconstr Surg* 2009;**124**:1196–201.
  58. Har-Shai Y, Amar M, Sabo E. Intralesional cryotherapy for enhancing the involution of hypertrophic scars and keloids. *Plast Reconstr Surg* 2003;**111**:1841–52.
  59. Berman B, Kaufman J. Pilot study of the effect of postoperative imiquimod 5% cream on the recurrence rate of excised keloids. *J Am Acad Dermatol* 2002;**47**:S209–11.
  60. Chuangsuwanich A, Gunjittisomram S. The efficacy of 5% imiquimod cream in the prevention of recurrence of excised keloids. *J Med Assoc Thai* 2007;**90**:1363–7.
  61. Cacao FM, Tanaka V, Messina MC. Failure of imiquimod 5% cream to prevent recurrence of surgically excised trunk keloids. *Dermatol Surg* 2009;**35**:629–33.
  62. Berman B, Perez OA, Konda S, et al. A review of the biologic effects, clinical efficacy, and safety of silicone elastomer sheeting for hypertrophic and keloid scar treatment and management. *Dermatol Surg* 2007;**33**:1291–302.
  63. Carney SA, Cason CG, Gowar JP, et al. Cica-Care gel sheeting in the management of hypertrophic scarring. *Burns* 1994;**20**:163–7.
  64. Gold MH, Foster TD, Adair MA, Burlison K, Lewis T. Prevention of hypertrophic scars and keloids by the prophylactic use of topical silicone gel sheets following a surgical procedure in an office setting. *Dermatol Surg* 2001;**27**:641–4.
  65. Cruz-Korchin NI. Effectiveness of silicone sheets in the prevention of hypertrophic breast scars. *Ann Plast Surg* 1996;**37**:345–8.



66. Fulton Jr JE. Silicone gel sheeting for the prevention and management of evolving hypertrophic and keloid scars. *Dermatol Surg* 1995;21:947–51.
67. Katz BE. Silicone gel sheeting in scar therapy. *Cutis* 1995;56:65–7.
68. Gold MH. A controlled clinical trial of topical silicone gel sheeting in the treatment of hypertrophic scars and keloids. *J Am Acad Dermatol* 1994;30:506–7.
69. Li-Tsang CW, Lau JC, Choi J, Chan CC, Jianan L. A prospective randomized clinical trial to investigate the effect of silicone gel sheeting (Cica-Care) on post-traumatic hypertrophic scar among the Chinese population. *Burns* 2006;32:678–83.
70. Majan JI. Evaluation of a self-adherent soft silicone dressing for the treatment of hypertrophic postoperative scars. *J Wound Care* 2006;15:193–6.
71. Niessen FB, Spauwen PH, Robinson PH, Fidler V, Kon M. The use of silicone occlusive sheeting (Sil-K) and silicone occlusive gel (epiderm) in the prevention of hypertrophic scar formation. *Plast Reconstr Surg* 1998;102:1962–72.
72. O'Brien L, Pandit A. Silicon gel sheeting for preventing and treating hypertrophic and keloid scars. *Cochrane Database Syst Rev*; 2006:CD003826.
73. Li-Tsang CW, Zheng YP, Lau JC. A randomized clinical trial to study the effect of silicone gel dressing and pressure therapy on posttraumatic hypertrophic scars. *J Burn Care Res* 2010;31:448–57.
74. Signorini M, Clementoni MT. Clinical evaluation of a new self-drying silicone gel in the treatment of scars: a preliminary report. *Aesthetic Plast Surg* 2007;31:183–7.
75. van der Wal MB, van Zuijlen PP, van de Ven P, Middelkoop E. Topical silicone gel versus placebo in promoting the maturation of burn scars: a randomized controlled trial. *Plast Reconstr Surg* 2010;126:524–31.
76. Murison M, James W. Preliminary evaluation of the efficacy of dermatix silicone gel in the reduction of scar elevation and pigmentation. *J Plast Reconstr Aesthet Surg* 2006;59:437–9.
77. Chan KY, Lau CL, Adeeb SM, Somasundaram S, Nasir-Zahari M. A randomized, placebo-controlled, double-blind, prospective clinical trial of silicone gel in prevention of hypertrophic scar development in median sternotomy wound. *Plast Reconstr Surg* 2005;116:1013–20.
78. Chernoff WG, Cramer H, Su-Huang S. The efficacy of topical silicone gel elastomers in the treatment of hypertrophic scars, keloid scars, and post-laser exfoliation erythema. *Aesthetic Plast Surg* 2007;31:495–500.
79. Karagoz H, Yuksel F, Ulkur E, Evinc R. Comparison of efficacy of silicone gel, silicone gel sheeting, and topical onion extract including heparin and allantoin for the treatment of postburn hypertrophic scars. *Burns* 2009;35:1097–103.