

## CLINICAL REPORT

# Porokeratosis in the Elderly: A New Subtype of Disseminated Superficial Actinic Porokeratosis

ANNALISA PATRIZI, CARMINE D'ACUNTO, BEATRICE PASSARINI and IRIA NERI

*Department of Clinical and Experimental Medicine, Division of Dermatology, University of Bologna, Bologna, Italy*

**In a review of all cases of porokeratosis histologically diagnosed in our Department during the period 1991–98 we found that 12 patients (22%) were in their seventh to ninth decade. In all 12 (2 males and 10 females) the age of onset of the disease varied between 58 and 89 years (mean age 68.6 years). The clinical picture was similar in all the patients, with the number of lesions varying from a few to 20–50 annular plaques 10–15 mm in diameter, localized mainly on the lower limbs. We suggest that our patients had a very mild form of disseminated superficial actinic porokeratosis confined to the extremities with an unusually late onset. This peculiar variety of late-onset disseminated superficial actinic porokeratosis may represent a type of immunosuppression-induced porokeratosis where the pathologic clone for porokeratosis is present but remains latent until the amount of sun exposure, together with the physiological age-related lowering of immunocompetence, bring about its proliferation. Key words: disseminated superficial actinic porokeratosis; immunosuppression-induced porokeratosis; elderly.**

(Accepted May 5, 2000.)

Acta Derm Venereol 2000; 80: 302–304.

Dr. Annalisa Patrizi, Department of Clinical and Experimental Medicine, Division of Dermatology, University of Bologna, via Massarenti 1, I-40138, Bologna, Italy.

An uncommon genodermatosis characterized by annular, gyrate plaques with central atrophy and sharply elevated hyperkeratotic borders was first described by Majocchi in 1887. Mibelli termed this condition porokeratosis, believing that it involved the pores of the sweat ducts (1). Subsequently some different morphological forms of porokeratosis (PK) were described (2–5). Despite the wide variety of clinical presentations of PK, the histopathological, immunohistochemical and ultrastructural features are exactly the same (6). The pathogenesis of PK is still unknown but nowadays this condition is considered a genodermatosis with an autosomal dominant mode of inheritance. The coexistence of different variants of PK in a single patient or in different members of an affected family (7, 8) is considered to be the different phenotypic expression of a common genetic disorder. In patients with genetic predisposition, external triggering factors such as irradiation, infective agents, trauma and immunosuppression can determine the activation of an abnormal clone of epidermal keratinocytes (9–11) and this could explain the high incidence of cutaneous malignancies reported in patients with PK (12, 13).

In 1998 we reviewed all cases of PK histologically diagnosed in our Department during the period 1991–98 and found 54 cases (28 females and 26 males; age range 4–89

years; mean age 54.5 years). In 14 cases we examined only the histopathological specimens and never actually saw the patients or their medical records or photographs. However, for the other 40 cases sufficient information was available and we were very surprised to find 12 elderly patients among them, whose lesions had not appeared until the sixth decade. Of the remaining 28 cases the final diagnosis was: classic PK of Mibelli (PM) in 7; disseminated superficial actinic PK (DSAP) in 11; linear PK in 4; PK plantaris palmaris et disseminata (PPPD) in 2 (father and son); and immunosuppression-induced PK (ISIP) in 4. We report here the main data from our 12 elderly patients.

## MATERIAL AND METHODS

The patients (2 males and 10 females) were aged between 69 and 89 years (mean age 76.5 years): 1 patient was 69 years old, 7 patients were in their eighth decade and 4 in their ninth decade. The age of onset of the disease varied between 58 years (2 cases) and 81 years. The clinical picture was similar in all patients. The initial lesions were always papules a few mm in diameter which after some months became annular plaques with a diameter of 10–15 mm and an elevated border surmounted by a shallow furrow extending in a centrifugal fashion (Figs 1A and 1B). The number of lesions in each patient varied from a few to 20–50. In 9 patients the lesions were localized only on the lower limbs and in 3 patients the upper limbs were also affected. The trunk, face, neck, palms, soles and mucous membranes were always unaffected. The disease was asymptomatic in 11 patients while 1 patient complained of pruritus, particularly during the papular initial phase.

PK was a casual diagnosis during the physical examination in 4 patients referred to us for other dermatoses. These 4 patients gave a negative family history but this information was unreliable. Except for 1 patient who had a sister affected by cutaneous lesions similar to those of our patients, the family history was negative. In the sister a clinical and histopathological diagnosis of PK had been made at 70 years of age but she was not seen by us and not included in our study. None of our patients had a past history of intensive sun exposure, either as a result of leisure or working outdoors.

Many of these elderly patients suffered from other diseases, such as cardiac, pulmonary or circulatory diseases, type II diabetes mellitus, stabilized rheumatoid arthritis and monoclonal gammopathy, but none had received immunosuppressive therapy before our diagnosis or were suffering from any other conditions associated with immunosuppression, such as transplantation, leukemia or liver disease.

Biopsy specimens were obtained from all patients. Histopathology was always uniform and typical for PK: the pathological hallmark was the cornoid lamella composed of a more or less parakeratotic column contained within an invagination of the epidermis at both edges of the lesion. The cornoid lamella was poorly developed in 7 cases (Fig. 2) and well developed in 5. The granular layer beneath the cornoid lamella was thinned or absent and some of the keratinocytes

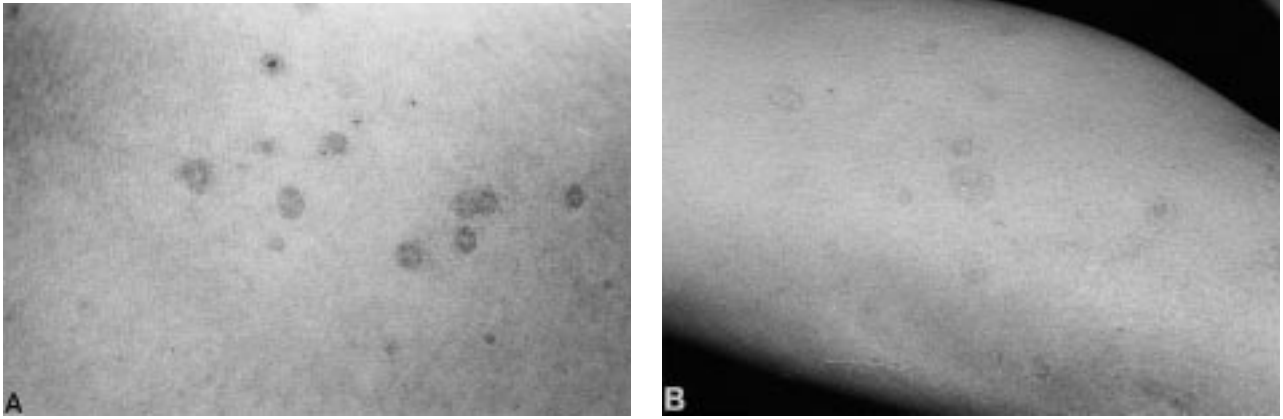


Fig. 1. (A) Initial lesions: papules a few millimeters in diameter. (B) Annular plaques: the diameter varies from 10–15 mm.

of the spinous layer appeared vacuolated and dyskeratotic with pycnotic nuclei.

The epidermis in the central portion of the lesion was thin and atrophic, as was the skin surrounding the lesion. A moderate focal lymphohistiocytic infiltrate, sometimes associated with some melanophages, was often present in the upper dermis beneath the cornoid lamella.

A minimum of 1 year to a maximum of 6 years follow-up was available for 10 patients; during follow-up no evidence of cutaneous malignancy over these lesions was seen and the disease remained stable or showed only a slight worsening.

## DISCUSSION

In addition to the 2 prime forms of PK, localized and disseminated, each of which may appear with 3 different clinical presentations, a new entity named ISIP has recently been suggested (13). While PM and DSAP represent the most frequent types of PK, the other varieties occur less frequently and have been reported only as sporadic case reports. We report here elderly patients affected by a peculiar subtype of PK characterized by a few cutaneous lesions, confined to the extremities, with a morphology very similar to that of DSAP.

DSAP is transmitted with an autosomal dominant mode of inheritance. The largest case studies relate to patients from geographical areas with large amounts of sun exposure, particularly Australia (14–16) where DSAP shows an average

age of onset of 20–40 years. Nevertheless Anderson & Chernosky (14), in a clinicogenetic study of 58 members of 10 families, observed several affected individuals in their 60 s and 70 s who could not recall the duration of their lesions. They concluded that DSAP worsens with age and that the number of affected subjects increases almost linearly with age after the first 16 years of life. In patients with DSAP, principally the elderly, hundreds of lesions are often observed per patient and Shumack & Commens (15) reported a mean count of 268 lesions per subject. All these data contrast with the diagnosis of DSAP in our patients.

In Italy, where the people are mainly indigenous and have a medium-high skin phenotype, DSAP is a rare disease and we consider it also to be rare in other European countries. Cases are sporadic and older patients without a family history of DSAP and with characteristics very similar to those of our patients have sometimes been reported in the literature (17–19).

In conclusion we suggest that our patients had a very mild form of DSAP confined to the extremities, particularly the lower limbs, and with an unusually late onset. In this mild, peculiar, age-related variety of DSAP the pathologic clone for PK is present but remains latent until the amount of sun exposure, together with the physiological lowering of the immunocompetence characteristic of aging (20), brings about its proliferation.

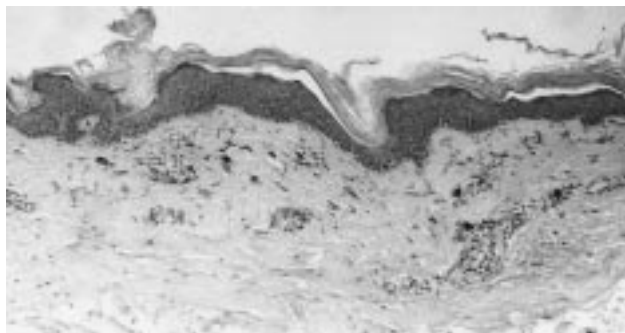


Fig. 2. Cornoid lamella with a poorly developed parakeratotic column contained in an invagination of the epidermis. A moderate focal lymphocytic infiltrate associated with some melanophages is present in the upper dermis beneath the cornoid lamella. Haematoxylin and eosin staining (original magnification  $\times 100$ ).

## REFERENCES

- Mibelli V. Contributo allo studio della ipercheratosi dei canali sudoriferi (porokeratosi). *G Ital Mal Ven Pelle* 1893; 28: 313–355.
- Truffi M. Sur un cas de porokeratose systemisée. *Ann Dermatol Syphiligr* 1905; 6: 521.
- Chernosky ME. Porokeratosis: report of twelve patients with multiple superficial lesions. *South Med J* 1966; 59: 289–294.
- Guss SB, Osbourn RA, Lutzner MA. Porokeratosis plantaris, palmaris, et disseminata: a third type of porokeratosis. *Arch Dermatol* 1971; 104: 366–373.
- Rahbari H, Cordero AA, Mehregan AH. Punctate porokeratosis. A clinical variant of porokeratosis of Mibelli. *J Cutan Pathol* 1977; 4: 338–341.
- Jurecka W, Neumann RA, Knobler RM. Porokeratoses: immunohistochemical, light and electron microscopic evaluation. *Dermatopathology* 1991; 24: 96–101.
- Freyschmidt-Paul P, Hoffmann R, Happle R. Linear poroker-

- atosis superimposed on disseminated superficial actinic porokeratosis: Report of two cases exemplifying the concept of type 2 segmental manifestation of autosomal dominant skin disorders. *J Am Acad Dermatol* 1999; 41: 644–647.
8. Moreland ME, Wyre HW Jr. Porokeratosis: two morphological forms within a family. *Arch Dermatol* 1981; 117: 245–246.
  9. Reed JR, Leone P. Porokeratosis: a mutant clonal keratosis of the epidermis. *Arch Dermatol* 1970; 101: 340–347.
  10. Otsuka F, Huang J, Sawara K, et al. Disseminated porokeratosis accompanying multicentric Bowen's disease. Characterization of porokeratotic lesions progressing to Bowen's disease. *J Am Acad Dermatol* 1990; 23: 355–359.
  11. Magee JW, McCalmont TH, LeBoit PE. Overexpression of p53 tumor suppressor protein in porokeratosis. *Arch Dermatol* 1994; 130: 187–190.
  12. Ninomiya Y, Urano Y, Yoshimoto K, Iwahana H, Asaki S, Itakura M. p53 gene mutation analysis in porokeratosis and porokeratosis-associated squamous cell carcinoma. *J Dermatol Sci* 1997; 14: 173–178.
  13. Schamroth JM, Zlotogorski A, Gilead L. Porokeratosis of Mibelli. *Acta Derm Venereol* 1997; 77: 207–213.
  14. Anderson DE, Chernosky ME. Disseminated superficial actinic porokeratosis (genetic aspects). *Arch Dermatol* 1969; 99: 401–407.
  15. Shumack SP, Commens CA. Disseminated superficial actinic porokeratosis: a clinical study. *J Am Acad Dermatol* 1989; 6: 1015–1022.
  16. Mikhail GR, Wertheimer FW. Clinical variant of porokeratosis (Mibelli). *Arch Dermatol* 1968; 98: 124–131.
  17. Kariniemi AL, Kotovirta ML, Stubb S. Disseminated superficial "actinic" porokeratosis. *Acta Derm Venereol* 1979; 59: 82–84.
  18. Del Castillo LF, Soria C, Diez-Caballero N, et al. Disseminated superficial actinic porokeratosis and squamous cell carcinoma: a report of two cases. *J Eur Acad Dermatol Venereol* 1997; 9: 190–191.
  19. Remond B, Domp Martin A, Mandard JC, Leroy D. Carcinome spinocellulaire et porokératose actinique superficielle disséminée. *Ann Dermatol Venereol* 1994; 121: 50–52.
  20. Sunderhotter C, Kalden H, Luger A. Aging and the skin immune system. *Arch Dermatol* 1997; 133: 1256–1262.

Copyright of Acta Dermato-Venereologica is the property of Taylor & Francis Ltd and its content may not be copied or emailed to multiple sites or posted to a listserv without the copyright holder's express written permission. However, users may print, download, or email articles for individual use.