



# HCV-Negative Mixed Cryoglobulinemic Glomerulonephritis and Solid Malignancy: A Case Report and Review of the Literature

Leonardo Spatola,<sup>1\*</sup> Claudio Angelini,<sup>1</sup> Carlo Selmi,<sup>2,3,4</sup> Silvia Santostasi,<sup>1</sup> Francesco Reggiani,<sup>1</sup>

Raimondo Boeri,<sup>5</sup> Domenico Mavilio,<sup>6</sup> and Salvatore Badalamenti<sup>1</sup>

<sup>1</sup>Humanitas Clinical and Research Center, Unit of Nephrology, via Manzoni 56, 20089, via Manzoni 56 Rozzano (Mi), Italy

<sup>2</sup>Humanitas Clinical and Research Center, Unit of Rheumatology and Clinical Immunology, via Manzoni 56, 20089 Rozzano (Mi), Italy

<sup>3</sup>Biometra Department, University of Milan, Milan, Italy

<sup>4</sup>Division of Rheumatology, Allergy and Clinical Immunology, Genome and Biomedical Sciences Facility, University of California at Davis School of Medicine, 451 Health Sciences Drive, Suite 6510, Davis, CA, 95616 USA

<sup>5</sup>Humanitas Clinical and Research Center, Unit of Pathology, via Manzoni 56, 20089 Rozzano (Mi), Italy

<sup>6</sup>Humanitas Clinical and Research Center, Unit of Clinical and Experimental Immunology, via Manzoni 56, 20089 Rozzano (Mi), Italy

\* Corresponding author: Leonardo Spatola, M.D., Humanitas Clinical and Research Center, Unit of Nephrology, via Manzoni 56, 20089, via Manzoni 56 Rozzano (Mi), Italy. Tel: +39-0282247723, E-mail: leonardo.spatola@humanitas.it

Received 2017 July 15; Accepted 2017 August 19.

## Abstract

**Introduction:** In this report, we present a rare case of HCV-negative cryoglobulinemic glomerulonephritis and recurrent prostate cancer in a 79-year-old Caucasian man. In the literature, only a few cases of solid cancer-associated cryoglobulinemia have been reported, but none have shown both renal involvement and prostate cancer.

**Case Presentation:** A 79-year-old Caucasian man with limb and abdominal purpura, peripheral edema, nausea, and oligoanuric renal failure was admitted to our renal unit in July 2016. In 2007, the patient was successfully treated with radiotherapy for localized prostate cancer and underwent regular follow-up until July 2016 when he developed a recurrence of prostate cancer and was treated with radiotherapy. He was obese and affected by hypertension and stable mild chronic kidney disease (last serum creatinine level, 1.4 mg/dL in July 2016). Serum creatinine level was 5.9 mg/dL upon admission, and blood urea nitrogen was 250 mg/dL with a urinary output of almost 400 ml/day. He tested negative for HCV infection, but positive for type II cryoglobulinemia. Considering the severity of the clinical course of renal biopsy, renal histology was performed, demonstrating cryoglobulinemic membranoproliferative glomerulonephritis. Given the concomitant recurrence of prostate adenocarcinoma, pulse steroid therapy was initiated, followed by prednisone (1 mg/kg/day), without using others immunotherapy agents, such as cyclophosphamide and/or rituximab. Limb and abdominal purpura improved after steroid therapy, whereas renal function failed to recover and hemodialysis treatment was initiated after positioning a central venous catheter. Hemodialysis treatment ameliorated the clinical status of our patient, who is still under chronic treatment.

**Conclusions:** Type II mixed cryoglobulinemia (MC) is a vasculitis of unknown etiology. HCV infection is the major cause of nearly 90% of MC cases. However, contribution of genetic and/or environmental factors remains controversial, as approximately 10% of MC cases present no evidence of HCV infection. These cases are defined as essential MC and are generally associated with a severe course of and suboptimal responses to conventional therapies. This documented report provides the basis for a comprehensive literature review of the rare occurrence of HCV-negative paraneoplastic cryoglobulinemia.

**Keywords:** Mixed Cryoglobulinemia, Essential Mixed Cryoglobulinemia, Cryoglobulinemic Glomerulonephritis, HCV-Negative Cryoglobulinemia

## 1. Introduction

Cryoglobulinemia is described by the presence of serum cryoglobulins, which are atypical proteins (mostly immunoglobulins) soluble at 37°C and precipitating at lower temperatures. Type II mixed cryoglobulinemia (MC) is a rare disease of unknown etiology, characterized by a blend of polyclonal immunoglobulin G (IgG) in associa-

tion with a monoclonal Ig, typically IgM or IgA.

Hepatitis C virus (HCV) infections are involved in approximately 90% of MC cases (1), whereas there is no indication of current or previous exposure to HCV (serum antibodies) in 10% of cases, which are generally associated with a severe course of and suboptimal responses to conventional therapies (2). In some cases, connective

tissue diseases (primarily systemic lupus erythematosus, Sjogren's syndrome, and systemic sclerosis) and lymphoproliferative disorders (B-cell non-Hodgkin lymphoma in most cases) (2) are found in an additional 5% of MC cases. Furthermore, cryoglobulinemia without an associated disease is defined essential (EMC) and accounts for 5% of cases.

We managed a rare case of HCV-negative cryoglobulinemic glomerulonephritis (CG), which developed in correspondence with the recurrence of prostate adenocarcinoma. We also present a comprehensive review of the literature on paraneoplastic MC.

## 2. Case Presentation

A 79-year-old Caucasian man was admitted to the department of nephrology in July 2016 because of the onset of a nonpalpable purpura at the limbs and abdomen 2 days earlier, without pruritus but with diarrhea and peripheral edema. The patient had been successfully treated in 2007 with intensity-modulated radiation therapy for localized prostate adenocarcinoma. He was regularly followed-up until the beginning of July 2016 when cancer recurrence was diagnosed and radiation therapy was reinitiated. The patient was obese and used olmesartan (80 mg) daily for hypertension and stable mild chronic kidney disease (last serum creatinine level, 1.4 mg/dL in July 2016).

Blood tests performed on admission showed acute renal failure (creatinine, 5.9 mg/dL; blood urea nitrogen [BUN], 250 mg/dL; potassium, 6.5 mEq/L), associated with oliguria and acute inflammation. Additional blood and urine tests (Table 1) indicated positive cryoglobulins and cryocrit of 20% with a substantial amount of urinary proteins. The serum examinations were compatible with a nephritic syndrome, secondary to HCV-negative MC. Cryoprecipitate was analyzed via immunodiffusion and immunofixation electrophoresis to identify the cryoglobulin type. The results showed monoclonal IgM and polyclonal IgG, thus confirming the presence of type II cryoglobulinemia.

The abdominal ultrasound demonstrated the regular size of both kidneys and hyperechogenicity of the renal cortex with a 3-cm cyst on the lower pole of the left kidney. The chest X-ray ruled out pleural effusion, and arterial blood gas examination showed no respiratory or metabolic alterations. Intravenous furosemide was initiated to achieve a urinary output of nearly 1500 cc/day, while renal function test results did not improve. The renal biopsy was performed after 4 days.

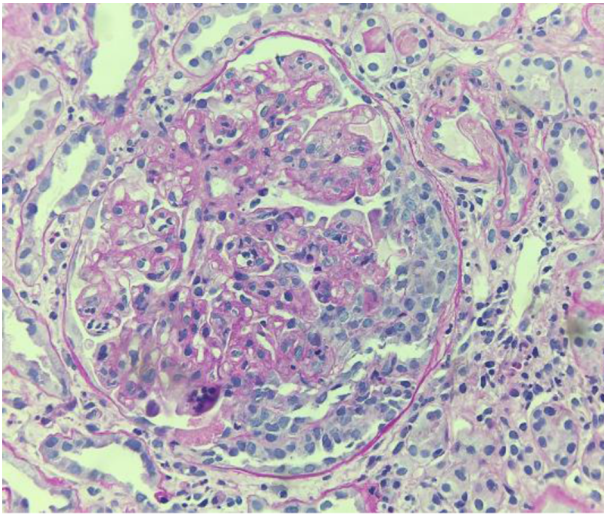
Because of the patient's severe obesity and poor compliance, a tissue sample suitable for light microscopy was collected, although it was insufficient for immunofluorescence and electron microscopy. Nonetheless, light mi-

**Table 1.** The Laboratory Results at Presentation in the Present Case of Essential Mixed Cryoglobulinemia (EMC) and Histologically Confirmed Glomerulonephritis

Blood Tests		Normal Values
Leukocytes, $10^3/\text{mm}^3$	4.48	4.0 - 10.0
Hemoglobin level, g/dL	9.4	13.0 - 18.0
Platelet count, $10^3/\text{mm}^3$	234	130 - 400
Sodium level, mEq/L	148	135 - 145
Potassium level, mEq/L	6.5	3.5 - 5.1
Creatinine level, mEq/L	5.9	0.8 - 1.2
Blood urea nitrogen (BUN), mEq/L	250	20 - 40
Lactate dehydrogenase, IU/L	269	125 - 243
Rheumatoid factor, U/mL	23	0 - 30
Aspartate aminotransferase, U/L	15	10 - 30
Alanine aminotransferase, U/L	20	10 - 30
C3, mg/dL	164	85 - 190
C4, mg/dL	7	10 - 65
IgA, U/L	362	40 - 350
IgG, U/L	784	840 - 1660
IgM, U/L	87	50 - 300
Prostate-specific antigen, ng/mL	4.19	0 - 4.0
HbsAg	Negative	Negative
HCV antibody	Negative	Negative
HCV RNA	Negative	Negative (real-time PCR)
Cryoglobulins	Positive	Negative
Cryocrit, %	20	Negative
Antinuclear antibody	1:320	< 1:4
Anti-dsDNA antibody	Negative	< 1:10
Antineutrophil cytoplasmic antibodies	Negative	Negative
Albumin level, g/dL	2.6	3.5 - 4.5
Proteinuria, g/24h	5.7	0.005 - 0.015
C-reactive protein, mg/L	16.93	0.1 - 1
$\alpha 1$ -globulins, %	8.4	2.9 - 4.9
$\alpha 2$ -globulins, %	16.6	7.8 - 11.8

croscopy revealed a membranoproliferative disease with infiltration of monocytes and capillary duplication with a globular pattern; mesangial proliferation and occasional extracapillary florid proliferation were also observed (Figure 1).

Due to the recent development of prostate cancer in the patient, cyclophosphamide was contraindicated despite its established use for severe CG (3). Therefore, intravenous administration of methylprednisolone (500



**Figure 1.** Light Microscopy revealed a membrano-proliferative disease with infiltration of monocytes and capillary duplication with globular pattern; mesangial proliferation and occasional extracapillary florid proliferation were also observed.

mg/pulse) was applied for 3 days, followed by prednisolone (1 mg/kg) daily. After 3 days, the purpura became less evident and disseminated, while renal function failed to recover (serum creatinine, 5.4 mg/dL; azotemia, 210 mg/dL after 10 days). Inevitably, hemodialysis treatment was initiated, using a temporary central venous catheter in the internal jugular vessel. The patient is currently on hemodialysis with a permanent central venous catheter, and his renal function has not shown any improvements despite high-dose steroids and diuretics.

### 3. Discussion

The majority of CG cases were considered essential until 1993, when Johnson and colleagues reported that cryopositive membranoproliferative glomerulonephritis (MPGN) is associated with chronic HCV infection (4). Today, HCV infection is the cause of nearly 90% of these cases, while the contribution of genetic and environmental factors remains controversial. Approximately 10% of MC cases manifest no evidence of current or previous HCV infection, and 5% have no recognizable associated diseases (1, 2). HCV-negative CG of unknown etiology has been usually reported in areas, such as Northern Europe, where the overall HCV prevalence is almost negligible (5).

In this regard, the French multicenter and transdisciplinary CryoVas survey retrospectively evaluated 242 MC cases without an infectious origin (6) and reported that among secondary MC forms, connective tissue and hematologic diseases were the most frequently identified

causes. On the other hand, 117 patients had EMC and were generally older ( $63 \pm 15$  vs.  $59 \pm 15$  years), with a more frequent renal involvement (38% vs. 25%), compared to the non-essential forms.

Pertinent to our case, the association between HCV-negative cryoglobulinemia and solid tumors has been rarely reported in the literature (7, 8). Rullier and colleagues provided a single-center inventory of cryoglobulinemia-associated solid cancers in an internal medicine setting (7). The study included 9 patients with HCV-related hepatocellular carcinoma and only 2 HCV-negative cases, chronologically compatible with a paraneoplastic phenomenon; these patients included a woman with treated breast cancer and a man with metastatic bladder and lung cancer with unknown etiology. Furthermore, another case of HCV-negative type II cryoglobulinemia in association with solid cancer was reported in a Caucasian patient (8). In the latter patient, solid cancer was diagnosed as gastric adenocarcinoma, but no other putative risk factors were found (8).

To the best of our knowledge, there is no evidence of an association between HCV-negative CG and solid prostate cancer, as highlighted in the present case. Furthermore, our patient had an atypical and extremely rare presentation of HCV-negative CG with oliguria, associated with the recurrence of prostate adenocarcinoma. Despite evidence on the suboptimal response of HCV-negative EMC to conventional therapies (2, 3, 9), an intravenous steroid treatment was initiated, but it failed to recover renal function and the patient continued hemodialysis.

Considering the reported treatments for HCV-negative cryoglobulinemia, the authors in the French CryoVas survey compared patient responses to corticosteroids alone with rituximab (or alkylating agents) plus corticosteroids in noninfectious mixed cryoglobulinemia (6). The Cox regression model showed that the combination of rituximab with corticosteroids was significantly more effective than corticosteroids alone in achieving a complete clinical response.

In this study, complete response was defined as improvement of all baseline clinical manifestations, including renal function (proteinuria  $< 0.5$  g/day, and/or disappearance of hematuria, and/or improvement of glomerular filtration rate [GFR]  $> 20\%$  at baseline GFR  $< 60$  ml/min/1.73 m<sup>2</sup>). On the other hand, combination therapy was significantly associated with severe infections, compared to corticosteroids alone (HR, 9; 95% CI, 3.1-20), especially in patients who received rituximab, along with high doses of corticosteroids ( $> 50$  mg/day). Nevertheless, mortality rate did not differ between the therapeutic regimens (HR, 1.7; 95% CI, 0.5 - 5.8), which may indicate the superiority of combination therapy in HCV-negative CG if compati-

ble with the clinical conditions.

The present case also underlines the importance of detecting CG with a histological pattern of membranoproliferative glomerulopathy, serum cryoglobulin positivity, and features specific to CG on light, immunofluorescence, and electron microscopy (10). In light microscopy, typical glomerular lobulation with infiltration of monocytes into the capillary space and large deposits (thrombi) is detected, while immunofluorescence staining for IgM is generally more intense in comparison with IgG in idiopathic MPGN. On the other hand, electron microscopy reveals electron-dense deposits in subendothelial and mesangial regions, which are characterized by thick-walled microtubular or annular structures, measuring 30 nm in diameter.

In the present case, only light microscopy was performed, as the patient's obesity and limited compliance during the procedure did not allow us to obtain renal tissue samples sufficient for electron microscopy. However, histology was well representative of CG with all its typical features, such as infiltrating leukocytes, membrane basement duplication, and mesangial proliferation. Surprisingly, complement C3 levels may also be normal in MC, as shown in previous reports, possibly due to the acute-phase liver response during infection or inflammation (11-13).

Under the mentioned conditions, the liver is responsible for a large fraction of total complement production, as well as acute-phase proteins. In our case, bioumoral examinations showed an elevated C-reactive protein level of 16.93 mg/dL (normal, 0.1 - 1 mg/dL), serum protein electrophoresis with 8.4%  $\alpha$ 1-globulins (2.9 - 4.9), and 16.6%  $\alpha$ 2-globulins (7.1 - 11.8), confirming the acute inflammatory state. CG presents a worse prognosis compared to idiopathic MPGN, regardless of HCV coexistence or other recognizable pathogenic causes (eg, B-cell lymphoma) (9).

In conclusion, the present case suggests the possibility of CG association with solid malignancies, such as prostate adenocarcinoma without evidence of HCV infection. Cryoglobulinemia has been reported in solid tumours, although the pathogenesis remains unclear (14, 15). The stimulus for monoclonal and/or polyclonal cryoglobulin is uncertain and may involve antibodies produced in response to tumour-associated antigens (crossreacting with autologous antigens), antibodies produced by lymphoid elements in cancer, or systemic immunity alterations induced by the tumour in the presence of different antibodies, as illustrated by Lundberg and colleagues. In the present case, cryoglobulins might be attributed to the latter phenomenon, as we also found positive serum antinuclear antibodies, although immunological alterations (eg, an increase in helper T cells or a decrease in suppressor cells) remain to be determined.

Lack of an identifiable putative risk factor, such as HCV, immunological connective diseases, and recurrent prostate cancer, did not allow us to introduce a more comprehensive treatment. Further evidence in the future may bridge the gap and clarify a possible link between solid organ malignancies and HCV-negative cryoglobulinemia to determine if it is a paraneoplastic syndrome. In this case, a revised classification of cryoglobulinemia should be encouraged to optimize treatment options.

## Acknowledgments

The authors would like to thank the patient for his consent to publish the case report.

## Footnotes

**Authors' Contribution:** All the authors confirmed the rarity of the case and difficulties associated with the diagnosis and management of the patient. Carlo Selmi and Domenico Mavilio analysed and interpreted the immunological data regarding the cryoglobulinemic disease. MS and Raimondo Boeri performed the histological examinations of the kidneys and highlighted the specific features of CG. Claudio Angelini, Francesco Reggiani, and Silvia Santostasi collected all the documents regarding the patient's history, including history of cancer, and contributed to the writing of the case description. SB analyzed the limited available data in the literature regarding the treatment of solid cancer and HCV-negative CG and contributed to the writing of the discussion section. Finally, all authors read and approved the final manuscript.

**Consent to Publication:** The patient consented to the publication of this report.

**Competing Interests:** The authors declare no conflicts of interest.

## References

1. Charles ED, Dustin LB. Hepatitis C virus-induced cryoglobulinemia. *Kidney Int.* 2009;**76**(8):818-24. doi: [10.1038/ki.2009.247](https://doi.org/10.1038/ki.2009.247). [PubMed: [19606079](https://pubmed.ncbi.nlm.nih.gov/19606079/)].
2. Galbiati V, Carne A, Mitjans M, Galli CL, Marinovich M, Corsini E. Isoeugenol destabilizes IL-8 mRNA expression in THP-1 cells through induction of the negative regulator of mRNA stability tristetraprolin. *Arch Toxicol.* 2012;**86**(2):239-48. doi: [10.1007/s00204-011-0758-2](https://doi.org/10.1007/s00204-011-0758-2). [PubMed: [21969073](https://pubmed.ncbi.nlm.nih.gov/21969073/)].
3. Campise M, Tarantino A. Glomerulonephritis in mixed cryoglobulinemia: what treatment? *Nephrol Dial Transplant.* 1999;**14**(2):281-3. [PubMed: [10069172](https://pubmed.ncbi.nlm.nih.gov/10069172/)].
4. Johnson RJ, Gretch DR, Yamabe H, Hart J, Bacchi CE, Hartwell P, et al. Membranoproliferative glomerulonephritis associated with hepatitis C virus infection. *N Engl J Med.* 1993;**328**(7):465-70. doi: [10.1056/NEJM199302183280703](https://doi.org/10.1056/NEJM199302183280703). [PubMed: [7678440](https://pubmed.ncbi.nlm.nih.gov/7678440/)].

5. Tervaert JW, Van Paassen P, Damoiseaux J. Type II cryoglobulinemia is not associated with hepatitis C infection: the Dutch experience. *Ann N Y Acad Sci.* 2007;**1107**:251-8. doi: [10.1196/annals.1381.027](https://doi.org/10.1196/annals.1381.027). [PubMed: [17804553](https://pubmed.ncbi.nlm.nih.gov/17804553/)].
6. Terrier B, Krastinova E, Marie I, Launay D, Lacraz A, Belenotti P, et al. Management of noninfectious mixed cryoglobulinemia vasculitis: data from 242 cases included in the CryoVas survey. *Blood.* 2012;**119**(25):5996-6004. doi: [10.1182/blood-2011-12-396028](https://doi.org/10.1182/blood-2011-12-396028). [PubMed: [22474249](https://pubmed.ncbi.nlm.nih.gov/22474249/)].
7. Rullier P, Le Quellec A, Cognot C. Cryoglobulins not HCV-related and solid tumors: retrospective analysis from a series of 493 patients. *Eur J Intern Med.* 2009;**20**(8):e158. doi: [10.1016/j.ejim.2009.09.014](https://doi.org/10.1016/j.ejim.2009.09.014). [PubMed: [19892296](https://pubmed.ncbi.nlm.nih.gov/19892296/)].
8. Milas-Ahic J, Prus V, Sustic N, Visevic R, Ivana K, Kardum Z. [Cryoglobulinemic vasculitis as a Manifestation of Paraneoplastic Syndrome—a Case Report]. *Reumatizam.* 2015;**62**(1):27-30. [PubMed: [26891578](https://pubmed.ncbi.nlm.nih.gov/26891578/)].
9. Hiramatsu R, Hoshino J, Suwabe T, Sumida K, Hasegawa E, Yamanouchi M, et al. Membranoproliferative glomerulonephritis and circulating cryoglobulins. *Clin Exp Nephrol.* 2014;**18**(1):88-94.
10. D'Amico G, Colasanti G, Ferrario F, Sinico RA. Renal involvement in essential mixed cryoglobulinemia. *Kidney Int.* 1989;**35**(4):1004-14. [PubMed: [2651764](https://pubmed.ncbi.nlm.nih.gov/2651764/)].
11. Tarantino A, Anelli A, Costantino A, De Vecchi A, Monti G, Massaro L. Serum complement pattern in essential mixed cryoglobulinaemia. *Clin Exp Immunol.* 1978;**32**(1):77-85. [PubMed: [668194](https://pubmed.ncbi.nlm.nih.gov/668194/)].
12. Veetil BM, Osborn TG, Mayer DF. Extreme hypercomplementemia in the setting of mixed cryoglobulinemia. *Clin Rheumatol.* 2011;**30**(3):415-8. doi: [10.1007/s10067-010-1652-7](https://doi.org/10.1007/s10067-010-1652-7). [PubMed: [21213005](https://pubmed.ncbi.nlm.nih.gov/21213005/)].
13. Gorevic PD. Rheumatoid factor, complement, and mixed cryoglobulinemia. *Clin Dev Immunol.* 2012;**2012**:439018. doi: [10.1155/2012/439018](https://doi.org/10.1155/2012/439018). [PubMed: [22956968](https://pubmed.ncbi.nlm.nih.gov/22956968/)].
14. Galli M, Oreni L, Saccardo F, Castelnovo L, Filippini D, Marson P, et al. HCV-unrelated cryoglobulinaemic vasculitis: the results of a prospective observational study by the Italian Group for the Study of Cryoglobulinaemias (GISC). *Clin Exp Rheumatol.* 2017;**35 Suppl 103**(1):67-76. [PubMed: [28466806](https://pubmed.ncbi.nlm.nih.gov/28466806/)].
15. Lundberg WB, Mitchell MS. Transient warm autoimmune hemolytic anemia and cryoglobulinemia associated with seminoma. *Yale J Biol Med.* 1977;**50**(4):419-27. [PubMed: [906560](https://pubmed.ncbi.nlm.nih.gov/906560/)].