

Pheochromocytomas Most Commonly Present As Adrenal Incidentalomas

Aggarwal, Sunil; Prete, Alessandro; Chortis, Vasileios; Asia, Miriam; Sutcliffe, R; Arlt, Wiebke; Ronchi, Cristina; Karavitaki, Niki; Ayuk, John ; Elhassan, Yasir

DOI:
[10.1210/clinem/dgad401](https://doi.org/10.1210/clinem/dgad401)

License:
Creative Commons: Attribution-NonCommercial-NoDerivs (CC BY-NC-ND)

Document Version

Version created as part of publication process; publisher's layout; not normally made publicly available

Citation for published version (Harvard):

Aggarwal, S, Prete, A, Chortis, V, Asia, M, Sutcliffe, R, Arlt, W, Ronchi, C, Karavitaki, N, Ayuk, J & Elhassan, Y 2023, 'Pheochromocytomas Most Commonly Present As Adrenal Incidentalomas: A Large Tertiary Center Experience', *European Journal of Endocrinology*. <https://doi.org/10.1210/clinem/dgad401>

[Link to publication on Research at Birmingham portal](#)

General rights

Unless a licence is specified above, all rights (including copyright and moral rights) in this document are retained by the authors and/or the copyright holders. The express permission of the copyright holder must be obtained for any use of this material other than for purposes permitted by law.

- Users may freely distribute the URL that is used to identify this publication.
- Users may download and/or print one copy of the publication from the University of Birmingham research portal for the purpose of private study or non-commercial research.
- User may use extracts from the document in line with the concept of 'fair dealing' under the Copyright, Designs and Patents Act 1988 (?)
- Users may not further distribute the material nor use it for the purposes of commercial gain.

Where a licence is displayed above, please note the terms and conditions of the licence govern your use of this document.

When citing, please reference the published version.

Take down policy

While the University of Birmingham exercises care and attention in making items available there are rare occasions when an item has been uploaded in error or has been deemed to be commercially or otherwise sensitive.

If you believe that this is the case for this document, please contact UBIRA@lists.bham.ac.uk providing details and we will remove access to the work immediately and investigate.

Pheochromocytomas Most Commonly Present As Adrenal Incidentalomas: A Large Tertiary Center Experience

Sunil Aggarwal,^{1,2,3} Alessandro Prete,^{1,2,3,4} Vasileios Chortis,^{1,2,3} Miriam Asia,³ Robert P. Sutcliffe,⁵ Wiebke Arlt,^{1,2,3} Cristina L. Ronchi,^{1,2,3} Niki Karavitaki,^{1,2,3} John Ayuk,^{2,3} and Yasir S. Elhassan^{1,2,3}

¹Institute of Metabolism and Systems Research, University of Birmingham, Birmingham B15 2TT, UK

²Centre for Endocrinology, Diabetes and Metabolism, Birmingham Health Partners, Birmingham B15 2TT, UK

³Department of Endocrinology, Queen Elizabeth Hospital Birmingham, Birmingham B15 2GW, UK

⁴NiHR Birmingham Biomedical Research Centre, University of Birmingham and University Hospitals Birmingham NHS Foundation Trust, Birmingham B15 2TT, UK

⁵Department of Hepatobiliary Surgery, Queen Elizabeth Hospital Birmingham, Birmingham B15 2GW, UK

Correspondence: Yasir S. Elhassan, MD, Institute of Metabolism and Systems Research, College of Medical and Dental Sciences, University of Birmingham, Edgbaston, Birmingham, West Midlands B15 2TT, UK. Email: Y.S.Elhassan@bham.ac.uk.

Abstract

Context: Pheochromocytomas are increasingly diagnosed in incidentally detected adrenal masses. However, the characteristics of incidental pheochromocytomas are unclear.

Objective: We aimed to assess the proportion and clinical, biochemical, radiological, genetic, histopathological, and follow-up characteristics of incidental pheochromocytomas.

Methods: A retrospective review was conducted of patients with pheochromocytoma seen between January 2010 and October 2022 at a large UK tertiary care center. The diagnosis was confirmed histologically or by the combined presence of increased plasma and/or urinary metanephrines (MN), indeterminate adrenal mass on cross-sectional imaging, and metaiodobenzylguanidine avidity.

Results: We identified 167 patients with pheochromocytoma; 144 (86.2%) underwent adrenalectomy, for 23 (13.8%) surgery was either awaited, deemed unsuitable due to frailty or other metastatic malignancy, or declined by the patients. Excluding pheochromocytomas diagnosed via screening genetically predisposed individuals (N = 20), 37 of 132 (28.0%) presented with adrenergic symptoms and/or uncontrolled hypertension, while 91 of 132 (69.0%) patients presented with an incidentally detected adrenal mass. Incidentally detected patients were older (median age 62 years) than those detected due to clinical suspicion (aged 42 years) or after genetic screening (aged 33 years) (all $P < .05$). Incidentally detected pheochromocytomas were smaller (median 42 mm) than tumors detected due to adrenergic symptoms/uncontrolled hypertension (60 mm), but larger than tumors identified by genetic screening (30 mm) (all $P < .05$). Increased MN excretion showed a similar pattern (symptomatic/uncontrolled hypertension > incidental > genetic screening) (all $P < .05$). Hereditary predisposition was detected in 20.4% of patients (incidental, 15.3%; symptomatic/uncontrolled hypertension, 42.9%).

Conclusion: The majority of pheochromocytomas are diagnosed incidentally and have distinct clinical, radiological, biochemical, and genetic features. Their detection at older age but smaller size may point to a different underlying tumor biology.

Key Words: pheochromocytoma, adrenal incidentaloma, catecholamines, metanephrines, normetanephrines

Abbreviations: CT, computed tomography; GAPP, grading system for adrenal pheochromocytoma and paraganglioma; MRI, magnetic resonance imaging; MIBG, metaiodobenzylguanidine; MN, metanephrines; NMN, normetanephrines; PASS, pheochromocytoma of the adrenal gland scaled score; PPGL, pheochromocytomas/paragangliomas; ULN, upper limit of normal.

Pheochromocytomas are rare neuroendocrine tumors originating from the chromaffin cells of the adrenal medulla that produce excess catecholamines. Unrecognized pheochromocytomas are associated with high mortality, most commonly from cardiovascular disorders (1, 2). Historically, up to 50% of cases of pheochromocytoma were detected post mortem (2, 3). With an improved understanding of the pathogenesis of these tumors, the diagnosis has been suspected in patients with clinical features related to catecholamine excess, typically paroxysmal and/or uncontrolled hypertension and adrenergic symptoms including anxiety, dizziness, as well as

the classic triad of headaches, profuse sweating, and palpitations (4). However, these manifestations are highly nonspecific and can mimic a plethora of other disorders (5). Therefore, it is recognized that the most challenging facet of pheochromocytoma detection is to seriously consider it in the differential diagnosis.

In the last two decades, the list of germline mutation syndromes associated with an increased risk of hereditary pheochromocytoma has expanded (6). Familial genetic testing is strongly recommended in patients with pheochromocytoma, and surveillance for the development of pheochromocytomas/

paragangliomas (PPGL) is undertaken in affected family members (7). This has led to the preemptive diagnosis of pheochromocytoma in asymptomatic cases discovered on testing of genetically predisposed individuals.

More recently, with the advent of modern imaging modalities and increased access to cross-sectional imaging, incidental adrenal masses are increasingly detected (8). The proportion of pheochromocytomas in adrenal incidentalomas is relatively small, around 7% (9, 10). Nevertheless, to avoid the adverse clinical consequences of a missed diagnosis of pheochromocytoma, it is recommended that all patients with adrenal incidentalomas be tested for catecholamine excess by measuring plasma or urinary metanephrines (MNs) (11).

Considering the evolution in the presentation of pheochromocytoma, we aimed to assess the proportion and clinical, biochemical, radiological, genetic, histopathological, and follow-up characteristics of incidental pheochromocytomas in a large UK tertiary care center.

Materials and Methods

Patient Selection

We performed a retrospective electronic clinical records review of patients with pheochromocytomas managed at the Queen Elizabeth Hospital Birmingham (Birmingham, UK) between January 2010 and October 2022. The diagnosis was confirmed histologically or by the combined presence of increased plasma or urinary MNs, an indeterminate adrenal mass on computed tomography (CT) or magnetic resonance imaging (MRI), and positive metaiodobenzylguanidine (MIBG) scintigraphy findings (7, 12).

All patients were discussed in our tertiary adrenal tumor multidisciplinary team meeting and if a presumed diagnosis of pheochromocytoma was made, adrenalectomy was recommended. Institutional review board approval for retrospective data review from patients undergoing routine clinical care was obtained from the University Hospital Birmingham NHS Foundation Trust (reference CARMS-18152).

Clinical Assessment

Adrenal tumors detected serendipitously without suspicion of adrenal disease that subsequently transpire to be pheochromocytomas were considered “incidental.” The clinical features considered to be potentially adrenergic in nature included episodic headaches, sweating, palpitations and dizziness, anxiety and panic attacks, and paroxysmal hypertension. Uncontrolled hypertension was determined by the referring clinician and defined as blood pressure greater than or equal to 140 mm Hg systolic and/or greater than or equal to 90 mm Hg diastolic despite 3 or more anti-hypertensive medications. In our outpatient clinic, blood pressure was assessed immediately before the clinical consultation by the clinical support staff and after the patient had been seated for at least 10 minutes. An existing diagnosis of hypertension was captured from the patients’ primary or secondary health care records and was also confirmed with the patient in our clinic.

Metanephrines and Normetanephrine Measurements

In our institution, plasma-free MNs are routinely measured in the seated position and using seated reference ranges (13).

Supine plasma-free MN measurements are carried out only in selected cases of suspected false-positive seated plasma MN results. For the purpose of this study, only plasma MNs in the seated position were used for the analysis. Blood samples were collected on ice and transferred to the laboratory within 1 hour of venipuncture. For the 24-hour urinary fractionated MNs, patients were provided with urine bottles containing hydrochloric acid. From the day before the test, patients were instructed to abstain from caffeine intake, exercise, and smoking or consuming nicotine.

Drug causes of a false increase in catecholamine levels were excluded in all cases (14). Whenever relevant, the offending drug was discontinued for a minimum of 2 weeks before MN measurement was repeated, which was required in only 3 cases.

Plasma MN were measured by liquid chromatography–tandem mass spectrometry using the Chromsystems MassChrom Free Metanephrines in Plasma commercial kit. The kit employs solid-phase extraction to extract the MNs from plasma and the extracts are analyzed on a Shimadzu UPLC system coupled with a Sciex 6500 QTrap mass spectrometer.

Total fractionated urinary MNs were measured using a validated liquid chromatography–tandem mass spectrometry assay employing a Sciex 5000 mass spectrometer.

Genetic Testing

After obtaining patients’ consent, genetic testing was undertaken in accordance with the national eligibility criteria for genetic testing that restricted testing in patients older than 60 years without prior medical history or family history suggestive of hereditary pheochromocytoma (15). Genetic testing was undertaken using next-generation sequencing of coding regions in *FH* (NM_000143.4), *MAX* (NM_002382.5), *MEN1* (NM_130799.2), *RET* (exons 10, 11, 13–16)(NM_020975.6), *SDHAF2* (NM_017841.4), *SDHB* (NM_003000.3), *SDHC* (NM_003001.5), *SDHD* (NM_003002.4), *TMEM127* (NM_017849.4), and *VHL* (NM_000551.4). *NF1* testing was included if clinical features of neurofibromatosis type 1 were detected.

Statistical Analyses

The MN measurements are presented as fold-increase above the upper limit of normal (ULN). A value of zero was assigned when there was no increase. The largest tumor diameter and the highest level of either MNs or normetanephrines (NMN), whether plasma or urinary measurements, were used in the analyses. If both MNs and NMNs were increased, a sum of the two was used in the correlation with tumor size analysis. In bilateral pheochromocytoma, the larger tumor was considered in the analyses. For the comparison of the α -blocker dose required in the different modes of presentation, the dose immediately preoperatively (or at the last follow-up if a patient did not undergo surgery) was considered in the analysis.

Descriptive statistics were used to compare cohorts. Wherever relevant, data are presented as median and range. Continuous variables were compared with the nonparametric Mann-Whitney *U* or one-way analysis of variance tests. Correlations between variables (tumor size and plasma and urinary metanephrines concentrations) were assessed using linear regression analysis. Disease recurrence was assessed using the Kaplan-Meier method and log-rank (Mantel-Cox).

Statistical significance was set at P less than .05. The statistical analyses and all the graphs were performed using the software GraphPad Prism version 9.0.

Results

Patients

A total of 167 patients with pheochromocytoma were included in the study (Table 1). Women represented 58.2% of cases ($N = 97$) and the median age at the time of diagnosis was 53 years (range, 12-86 years). Adrenalectomy was undertaken in 144 (86.2%) patients and pheochromocytoma was histologically confirmed in all. In the remaining 23 (13.8%) patients, surgery was either awaited ($N = 5$), deemed unsuitable because of frailty or other metastatic malignancy ($N = 16$), or declined by patients ($N = 2$). Pheochromocytoma was right-sided in 80 (48.0%) patients, left-sided in 75 (45.0%) patients, and bilateral at presentation in 12 (7.0%) patients. Metastatic disease at presentation was evident in only 4 (2.4%) patients.

Clinical Presentation According to Mode of Diagnosis

Details on the mode of presentation leading to the discovery of pheochromocytoma were available for 152 patients. After excluding pheochromocytomas diagnosed via screening genetically predisposed individuals ($N = 20$; 13.2%), the most common mode of presentation was detection during routine workup for adrenal incidentaloma (91 patients; 69.0%), followed by presentation with adrenergic symptoms/uncontrolled hypertension (37 patients; 28.0%), and acute cardiomyopathy (4 patients; 3.0%) (Fig. 1A). The reasons for imaging in patients whose pheochromocytoma was diagnosed incidentally were abdominal (pain, diarrhea, weight loss; $N = 43$, 47.2%), thoracic (suspected pulmonary embolism, infection, or suspected malignancy on chest x-ray; $N = 22$, 24.3%), urological (hematuria, stones; $N = 18$, 19.7%), oncological (staging for other malignancy; $N = 4$, 4.4%), or unknown ($N = 4$, 4.4%). Only 1 of the 4 patients with metastatic disease at presentation was diagnosed incidentally, while the other 3 presented with adrenergic symptoms.

The median age at diagnosis in patients with incidentally discovered pheochromocytomas was 62 years (range, 23-86 years); this was higher than that of the patients who presented with adrenergic symptoms/uncontrolled hypertension who had median age at diagnosis of 42 years (range, 16-79 years) ($P < .001$) (Fig. 1B). The youngest group at pheochromocytoma diagnosis were those discovered during screening for known genetic susceptibility with a median age of 33 years (range, 12-68 years) ($P < .001$).

Interestingly, 40.7% of patients who were diagnosed after an adrenal incidentaloma was detected retrospectively reported adrenergic symptoms typical of pheochromocytoma (Fig. 1C). If those were excluded, then 54 (32.3%) patients would have been diagnosed purely as adrenal incidentaloma. Similarly, 35.6% of patients with incidental pheochromocytoma had an underlying diagnosis of hypertension with a median age of diagnosis of 53 years (range, 27-72 years), which was higher than the median age of diagnosis of hypertension in the adrenergic symptoms/uncontrolled hypertension group (38 years; range, 16-77 years) ($P = .001$) (Fig. 1D). There was no difference in the systolic, diastolic, or mean arterial pressure (calculated as diastolic blood pressure +1/3 (systolic

blood pressure – diastolic pressure)) based on the mode of presentation (Supplementary Fig. 1) (16).

Radiological Characteristics

The median size of pheochromocytoma was 45 mm (range, 10-215 mm) (Fig. 2). Incidental pheochromocytomas were smaller than those detected in patients with adrenergic symptoms/uncontrolled hypertension (median size 42 mm [range, 14-180 mm] vs 60 mm [range, 15-215 mm]; $P = .01$), but larger than pheochromocytomas detected via screening for known genetic susceptibility (median 30 mm [range, 10-75 mm]; $P = .003$) (Fig. 2).

In 131 patients the detection was based on CT and all tumors were either heterogeneous, thereby preventing measurement of the attenuation value in Hounsfield units (HU), or were homogeneous with an unenhanced density of 10 or more HU (median 33 HU; range, 10-77 HU). MRI was undertaken in 43 patients; 22 (52.4%) had hyperintensity in T2-weighted images (data not shown).

Preoperative MIBG scanning was undertaken in 98 (65.7%) patients; 92 (94.0%) showed avid uptake while 6 (6.0%) patients with high MNs and subsequent histologically proven pheochromocytoma had non-MIBG-avid tumors (see Table 1). All patients with metastatic pheochromocytoma ($N = 4$) had evident disease spread on cross-sectional imaging at the time of tumor diagnosis. MIBG did not identify more cases of metastatic pheochromocytoma than cross-sectional imaging but, in the 4 patients with metastasis at presentation, identified more metastatic lesions than those evident on CT or MRI (data not shown).

Biochemical Characteristics

Most patients were diagnosed based on plasma MN measurements ($N = 134$, 80.2%) and in 33 (19.8%) patients the diagnosis was based on only urinary MN results (see Table 1).

Only 21 patients had both plasma and urine MNs measured at presentation and, as expected, we confirmed that the levels correlated positively and strongly (data not shown).

The predominant increase was in normetanephrines (NMN) in 75 of 139 (54.0%) patients and MNs in 60 (43.2%). The proportions of the different patterns of MN levels were an increase in NMN only, 46 (33.0%) patients; MNs only, 11 (8.0%) patients; both increased, 78 (56.0%) patients; both normal, 4 (3.0%) patients (see Table 1). None of the patients had a predominant increase in the plasma concentrations of the dopamine metabolite 3-methoxytyramine.

The median increase of MNs was 5-fold ULN (range, 1-fold to 96-fold ULN) (Fig. 3A). Incidental pheochromocytomas secreted lower MN levels than in patients presenting with adrenergic symptoms/uncontrolled hypertension (median 5-fold ULN vs 15-fold ULN; $P < .0001$), but higher than those diagnosed during screening for known genetic susceptibility (median 3-fold ULN; $P < .0001$) (see Fig. 3A).

Overall, tumor size correlated positively with MN concentration ($R = 0.52$; $P < .0001$) (Supplementary Fig. 2 (16)). The correlation between tumor size and metanephrines did not change after the exclusion of the 12 patients with bilateral pheochromocytoma at presentation (data not shown). Furthermore, this trend persisted in incidental pheochromocytomas when we compared the median tumor size to the median degree of increase in MNs: size 20 mm or less, median MNs less than 2-fold ULN; size greater than 20 to 30 mm,

Table 1. Patient characteristics

	Overall	Incidental	Adrenergic symptoms/ uncontrolled hypertension	Screening for genetic susceptibility	Acute cardiomyopathy	Unknown mode of presentation
Total No. of patients, N (%)	167	91	37	20	4	15
• Adrenalectomy	144 (86.2)	72 (79.1)	33 (89.2)	20 (100)	4 (100)	15 (100)
• No adrenalectomy	23 (13.8)	19 (20.9)	4 (10.8)	—	—	—
– Unsuitable (eg, frailty, other metastatic malignancy)	16	14	2	—	—	—
– Surgery awaited	5	3	2	—	—	—
– Surgery declined by patient	2	2	—	—	—	—
Sex, N (%)	167	91	37	20	4	15
• Male	70 (41.8)	37 (40.0)	12 (32.4)	11 (55.0)	2 (50.0)	8 (53.3)
• Female	97 (58.2)	54 (60.0)	25 (67.6)	9 (45.0)	2 (50.0)	7 (46.7)
Median age at diagnosis, y (range)	53 (12-86)	62 (23-86)	42 (16-79)	33 (12-68)	43 (16-73)	
Laterality, N (%)	167	91	37	20	4	15
• Right	80 (48.0)	49 (53.8)	15 (40.6)	5 (25.0)	1 (25.0)	10
• Left	75 (45.0)	39 (42.9)	18 (48.6)	10 (50.0)	3 (75.0)	5
• Bilateral	12 (7.0)	3 (3.3)	4 (10.8)	5 (25.0)	—	—
Radiological diagnosis, N (%)	155	89	34	20	4	8
• CT	132 (85.2)	87 (97.8)	26 (76.5)	9 (45.0)	4 (100)	6 (75.0)
• MRI	49 (31.6)	21 (23.6)	12 (35.3)	11 (55.0)	1 (25.0)	4 (50.0)
• MIBG	98 (63.2)	58 (65.2)	26 (76.5)	9 (45.0)	2 (50.0)	3 (37.5)
– Positive	92 (94.0)	55 (94.8)	23 (88.5)	9 (100)	2 (100)	3 (100)
– Negative	6 (6.0)	3 (5.2)	3 (11.5)	0	0	0
– Median tumor diameter: mm (range)	45 (10-215)	42 (14-180)	60 (15-215)	30 (10-75)	52 (44-65)	46 (18-150)
Metastatic disease at presentation, N (%)	4 (2.4)	1 (2.5.0)	3 (75.0)	0	0	0
Biochemical diagnosis, N (%)	139	84	32	11	4	8
• NMN increased only	46 (33.0)	27 (32.1)	12 (37.5)	4 (36.4)	1 (25.0)	2 (25.0)
• MN increased only	11 (8.0)	7 (8.3)	0	3 (27.2)	0	1 (12.5)
• Both MN and NMN increased	78 (56.0)	46 (54.8)	20 (62.5)	4 (36.4)	3 (75.0)	5 (62.5)
• MN and NMN normal	4 (3.0)	4 (4.8)	0	0	0	
Preoperative α -blockade, N (%)	163 (97.6)					
• Doxazosin	135 (82.8)	—	—	—	—	—
• Phenoxybenzamine	28 (17.2)					
Histopathology, median (range)						
• Ki67 index, %	1 (<1-70)	1 (<1-70)	2 (1-35)	1.8 (<1-8)	—	—
• PASS	4 (0-17)	4 (0-17)	5 (0-15)	4 (0-8)	—	—

Abbreviations: CT, computed tomography; MIBG, metaiodobenzylguanidine; MN, metanephrines; MRI, magnetic resonance imaging; NMN, normetanephrines, PASS, Pheochromocytoma of the Adrenal Gland Scaled Score.

median MNs 2- to 3-fold ULN; size greater than 30 to 40 mm, median MNs 3- to 4-fold ULN; greater than 40 mm, median MNs 8- to 9-fold ULN ($P < .0001$) (Fig. 3B). The exclusion of patients for whom the diagnosis was based on only urinary MNs did not change the results (data not shown).

Preoperative Management

Most patients were treated with α -blockers as soon as pheochromocytoma was diagnosed (N = 163; 97.6%), with doxazosin and phenoxybenzamine being used in 82.8% and 17.2% of cases, respectively (see Table 1). Of those undergoing surgery, 4 (2.4%) patients were not treated with

preoperative α -blockade: Two had normal MN and, therefore, pheochromocytoma was not suspected; 1 was hypotensive, and α -blockers were considered inappropriate; and 1 underwent surgery for a presumed renal tumor, but histology was consistent with pheochromocytoma.

The α -blocker dose was titrated according to clinical response, aiming for a blood pressure of less than 120/80 mm Hg. The median total daily dose of doxazosin at the time of adrenalectomy (or at the last follow-up if a patient did not undergo surgery) was 6 mg (range, 1-32 mg) and 40 mg for phenoxybenzamine (range, 10-90 mg). The median total daily dose of doxazosin varied by the mode of presentation; patients with incidental pheochromocytomas and those detected

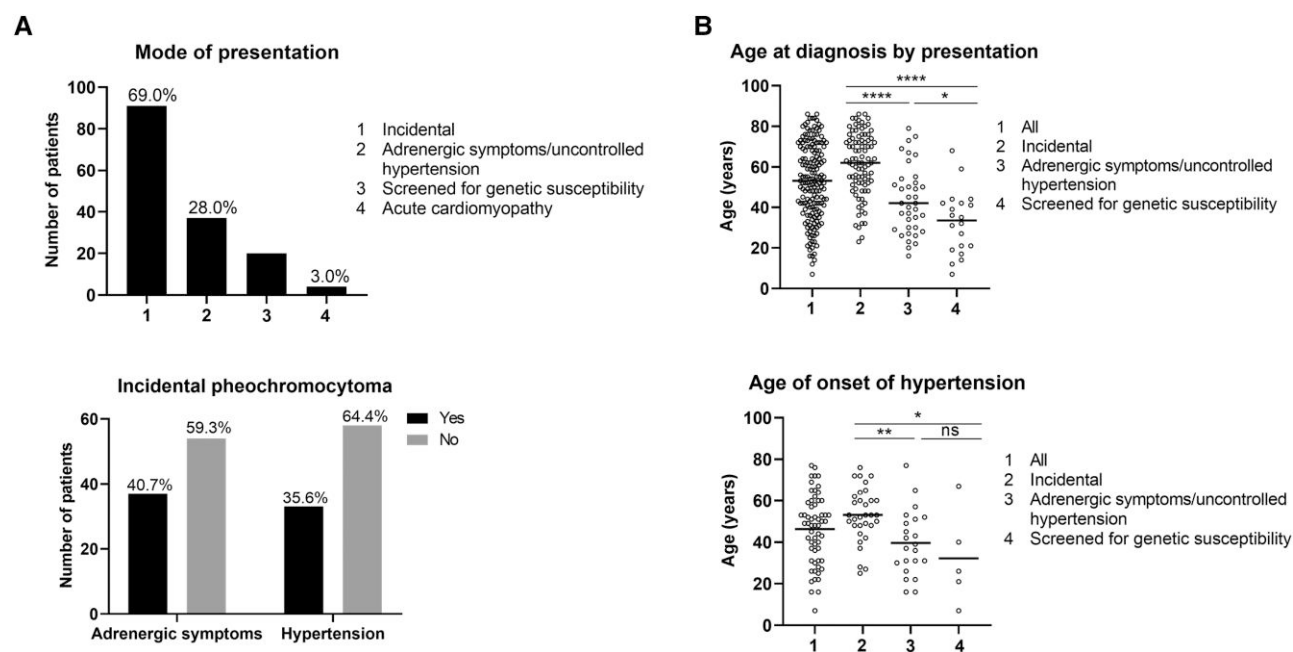


Figure 1. Clinical characteristics of patients with pheochromocytoma. A, Patients divided by pheochromocytoma mode of discovery after excluding those diagnosed on screening for genetic susceptibility (N = 20) and those with unknown mode of discovery (N = 15). B, Spread of patients' age, divided by mode of discovery of pheochromocytoma. C, Prevalence of adrenergic symptoms and an underlying diagnosis of hypertension in patients with pheochromocytoma who presented as adrenal incidentaloma. D, Spread of age of onset of hypertension, divided by mode of discovery of pheochromocytoma. The horizontal lines represent the median of each group. Statistical significance was set at P less than .05.

during screening for underlying genetic susceptibility required lower doses (median 4 mg; range, 1-20 mg) than those with adrenergic symptoms/uncontrolled hypertension (median 8 mg; range, 1-32 mg) ($P = .001$) (Fig. 4). There was no relationship between doxazosin dose and tumor size (data not shown). The number of patients treated with phenoxybenzamine was too small to assess for such differences.

Genetic Characteristics

Of the 147 patients not known to have underlying genetic susceptibility to pheochromocytoma, 103 (70.0%) patients underwent genetic testing postoperatively and germline mutations that predispose to pheochromocytoma were detected in 21 (20.4%). The detected germline mutations were in *NF1* (6 patients, 28.6%), *RET* (4 patients, 19.0%), *SDHB* (4 patients, 19.0%), *VHL* (3 patients, 14.3%), *TMEM127* (2 patients, 9.5%), *MEN1* (1 patient, 4.8%), and *MAX* (1 patient, 4.8%) (Supplementary Table 1 (16)).

Of the 91 patients who presented with adrenal incidentalomas, genetic testing was undertaken in 59 (64.8%) patients out of whom 9 (15.3%) had a confirmed underlying germline mutation. On the other hand, 28 (75.7%) of 37 patients with adrenergic symptoms/uncontrolled hypertension underwent genetic testing and 12 (42.9%) had a confirmed underlying mutation. Of the 4 patients who presented with acute cardiomyopathy, 2 underwent genetic testing and it was negative while 2 did not meet the national genetic testing criteria (see Supplementary Table 1 (16)).

Of the 12 patients who presented with bilateral pheochromocytomas, 10 (83.3%) had a known underlying genetic defect that predisposes to pheochromocytoma or were confirmed to have one on postoperative genetic testing (*VHL*, 5 patients; *RET*, 2 patients; *NF1*, 1 patient;

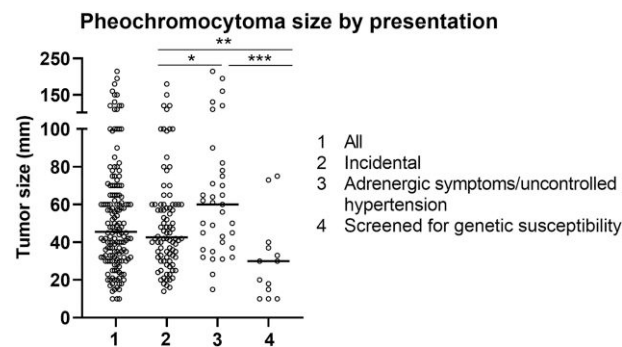


Figure 2. Radiological characteristics. Spread of pheochromocytoma tumor size, divided by mode of discovery. The horizontal lines represent the median of each group. Statistical significance was set at P less than .05.

TMEM127, 1 patient; *MAX*, 1 patient) (Supplementary Table 1 (16)).

The 20 patients with a known underlying genetic susceptibility who developed pheochromocytoma during screening had pathogenic mutations in *VHL* (9 patients, 45.0%), *RET* (8 patients, 40.0%), and *NF1* (3 patients, 15.0%) (see Supplementary Table 1 (16)).

Histopathological Characteristics

Pathology data were available for 127 (76.0%) patients. The median Ki67 proliferation index in all patients was 1% (range, <1%-70%), which tended to be higher in pheochromocytomas that presented with adrenergic symptoms/uncontrolled hypertension compared to those detected incidentally; median Ki67 index 2% (range, 1%-35%) vs 1% (range, <1%-70%) ($P = .06$) (see Table 1). Otherwise, no difference

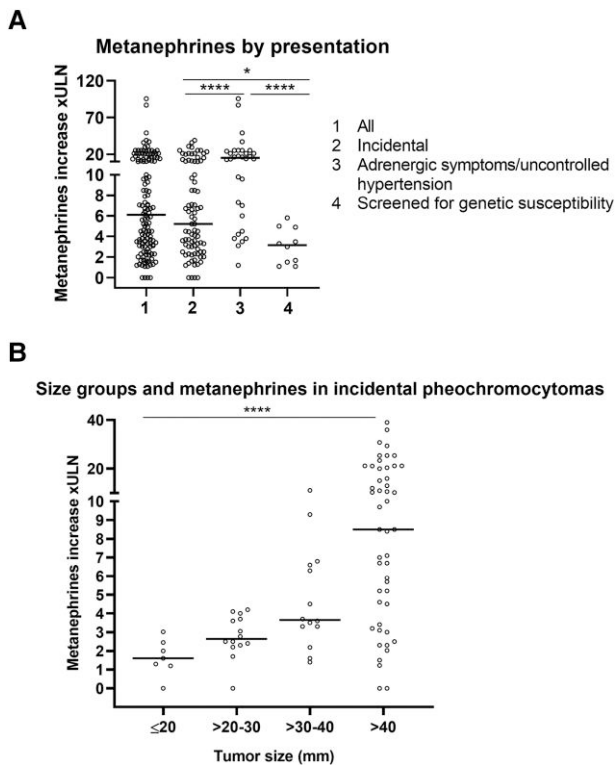


Figure 3. Biochemical characteristics. A, Spread of metanephrines increase, divided by mode of discovery of pheochromocytoma. B, Increase in metanephrines levels in patients with pheochromocytoma who presented as adrenal incidentaloma, divided into 4 tumor size groups. The horizontal lines represent the median of each group. Statistical significance was set at P less than .05.

was detected in the Ki67 index between the groups. The median Pheochromocytoma of the Adrenal Gland Scaled Score (PASS) (17) was 4 (range, 0-17), which was not different between the groups; incidental 4 (range, 0-17); adrenergic symptoms/uncontrolled hypertension 5 (range, 0-15); screening for known genetic susceptibility 4 (range 0-8), $P > .05$ for all (see Table 1). The available data on Grading system for Adrenal Pheochromocytoma and Paraganglioma (GAPP) (18) were scanty and therefore meaningful comparisons could not be undertaken.

Follow-up Characteristics

The median duration of follow-up of all patients from adrenalectomy to last follow-up (or from diagnosis to last follow-up if a patient did not undergo surgery) was 36 months (range, 1-179 months). Overall, 17 (10.2%) patients developed metachronous or metastatic disease during follow-up; incidental 4.4% (N=4, median follow-up 23 months [range, 1-146 months]), symptomatic/uncontrolled hypertension 8.1% (N=3, median follow-up 36 months [range, 1-179 months]); and screened for genetic susceptibility 40.0% (N=8, 113 months [range, 2-169 months]). Using the Kaplan-Meier method, no significant difference in disease recurrence was observed between the groups ($P = .921$; Supplementary Fig. 3 (16)). The mode of presentation of the first tumor was unknown in 2 patients who developed disease recurrence. Overall, the median time to disease recurrence was 80 months (range, 6-153 months).

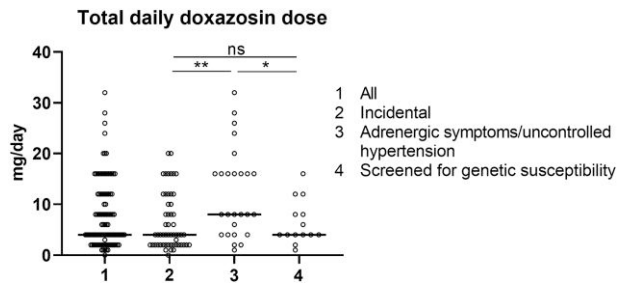


Figure 4. Preoperative α -blockade. Total daily dose of doxazosin immediately preoperatively (or at last follow-up if a patient did not undergo surgery), divided by mode of discovery of pheochromocytoma. The horizontal lines represent the median of each group. Statistical significance was set at P less than .05.

Among the 4 patients with incidentally detected pheochromocytoma who developed disease recurrence, 1 underwent genetic testing confirming an *NFI* mutation, 1 declined genetic testing, and 2 did not meet the national genetic testing criteria at the diagnosis of first tumor and died after disease recurrence and before genetic testing was undertaken. Regarding the 3 patients in the symptomatic/uncontrolled hypertension group who developed disease recurrence, 1 underwent genetic testing confirming an *SDHB* mutation, and 2 did not meet the national genetic testing criteria at the diagnosis of the first tumor.

Discussion

We present one of the largest pheochromocytoma cohorts published to date and demonstrate that the most common mode of detection is during routine workup for adrenal incidentaloma leading to distinct clinical, radiological, biochemical, and genetic characteristics. This shift in the mode of presentation of pheochromocytoma mirrors the ever-increasing detection of adrenal incidentalomas as a result of widespread use of and increased access to cross-sectional imaging (8).

The diagnosis of pheochromocytoma is usually straightforward in patients who present with typical symptoms and/or uncontrolled hypertension, as they have larger tumors and unequivocal increases in MNs. Although pheochromocytomas diagnosed during screening patients with known underlying genetic susceptibility were the smallest in this study and associated with the lowest degree of abnormal MNs, the diagnosis is usually also straightforward as the underlying genetic susceptibility makes the pretest probability for pheochromocytoma relatively high. On the other hand, the most challenging category was that of patients who presented with adrenal incidentalomas, since smaller pheochromocytomas (<2 cm) were associated with a median increase in MNs less than twice the ULN. This should still raise suspicion of the diagnosis because despite the low pretest probability for the detection of pheochromocytoma in adrenal incidentalomas (9, 10), a mildly raised MN level (< twice the ULN) in the presence of an adrenal tumor increases the posttest probability to up to 80% (19). This emphasizes the importance of appropriate radiological workup and that small, indeterminate adrenal incidentalomas should not be disregarded as pheochromocytoma remains a possibility. These data are useful considerations for clinical practice as they highlight that the clinical and biochemical thresholds for the diagnosis of pheochromocytoma

need to be determined on an individual case basis, considering the mode of patient presentation. It is likely that the detection of incidental pheochromocytomas will continue to increase, and clinicians should be aware that pheochromocytoma is possible even in small adrenal masses with normal to borderline increases in MNs.

The finding that incidental pheochromocytomas are smaller in size and detected in older patients may suggest a different underlying tumor biology. This concept was briefly explored a decade ago when it was reported that incidental pheochromocytomas exhibited increased cellularity and number of mitoses and displayed different transcriptional features in relevant genes (*PNMT*, *SGII*, *VMAT1*, *NET* and *NPY*; quantitative polymerase chain reaction) and *PNMT* protein expression on Western blotting (20).

All pheochromocytomas carry metastatic potential (21); however, the very low prevalence of metastatic disease at presentation in this study may be due to earlier detection of pheochromocytomas as adrenal incidentalomas. Indeed, of 4 patients with metastatic disease at presentation, only 1 was diagnosed incidentally.

We found that symptoms attributable to pheochromocytoma were very common in patients presenting incidentally, and therefore an opportunity for earlier diagnosis in these cases was missed. This reminds us of the highly nonspecific nature of pheochromocytoma symptoms and reinforces the need for a high index of suspicion to proactively make the diagnosis. Similarly, hypertension was highly prevalent in incidental pheochromocytomas, although hypertension is also prevalent in patients with adrenal incidentaloma overall, even the non-functioning ones (22, 23).

The requirement of higher α -blocker doses in patients who present with adrenergic symptoms/uncontrolled hypertension may reflect the larger tumor size and higher MN levels and is a useful consideration that can guide the preoperative management strategy in terms of the frequency of clinic appointments, α -blocker dose titration, and presurgical admission. There is existing controversy about whether patients with PPGL should systematically receive preoperative alpha-blockers (24). It is at least reasonable to question whether patients with small incidental pheochromocytoma should receive preoperative α -blockers, which can be associated with lower intraoperative blood pressure and increased perioperative morbidity (25, 26).

The proportion of detection of germline mutations after the diagnosis of pheochromocytoma in this study was overall lower than the classic figure of 30% to 40% reported in multiple studies (6, 27). Interestingly, however, this varied with the mode of presentation as incidental pheochromocytomas were much less likely to be hereditary. The increased detection of incidental pheochromocytomas will ultimately lead to increased detection of probands. This will feed into increased presymptomatic pheochromocytoma screening in susceptible family members, which is likely to become an even more common mode of tumor discovery.

Gruber et al (28) showed that the proportion of incidentally detected PPGL has steadily increased from 31% in the period 1995 to 2004 to 61% in 2005 to 2016, and vice versa for patients who present with suggestive clinical features. Conversely, a Danish population study reported a lower proportion (37%) (29) compared to those observed in our study and at the Mayo Clinic (28), which may suggest selection bias in tertiary referral centers. However, the steadily increasing

proportion of incidental pheochromocytomas within the same institution observed at the Mayo Clinic is a counterargument (28). Additionally, if we exclude patients who retrospectively reported adrenergic symptoms, then our figure becomes closer to that of the Danish study (29).

In terms of imaging, our data also confirm previous findings that all pheochromocytomas are radiologically indeterminate, that is, they either appear heterogeneous (thereby preventing measurement of the attenuation value) or have unenhanced CT density value of 10 HU or greater (30). Therefore, measuring plasma or urinary MNs in patients with incidentally discovered adrenal masses that are homogenous and have an unenhanced CT density of less than 10 HU is of little clinical value.

The strengths of our study include the large number of patients from a single center, with homogenous clinical, biochemical, and radiological assessments, and managed by the same multidisciplinary team. A limitation is the retrospective nature of the data collection and the potential selection bias as our center represents the regional referral center for complex adrenal tumors, most of which are detected as incidentalomas.

In conclusion, in this large cohort, most pheochromocytomas were diagnosed incidentally. The mode of tumor presentation influences the clinical, radiological, biochemical, and genetic characteristics and should be considered during the interpretation of the patient's results. Small, indeterminate adrenal incidentalomas should not be disregarded, even with normal or borderline MNs, as pheochromocytoma remains a possibility. Incidental pheochromocytomas are associated with older patient age, smaller tumors, lower MN levels, and lower likelihood of being hereditary, which may reflect a different tumor biology. Thus, incidental pheochromocytomas can represent a diagnostic challenge for being "atypical."

Funding

A.P. receives support from the NIHR Birmingham Biomedical Research Centre at the University Hospitals Birmingham NHS Foundation Trust and the University of Birmingham (grant reference No. NIHR203326). The views expressed are those of the authors and not necessarily those of the NIHR or the Department of Health and Social Care UK. V.C. received support from the Academy of Medical Sciences UK (Starter Grant for Clinical Lecturers SGL020/1018).

Disclosures

C.L.R. is an editorial board member for *The Journal of Clinical Endocrinology & Metabolism*. The other authors have nothing to disclose.

Data Availability

Some or all data sets generated during and/or analyzed during the current study are not publicly available but are available from the corresponding author on reasonable request.

References

1. Stolk RF, Bakx C, Mulder J, Timmers HJLM, Lenders JWM. Is the excess cardiovascular morbidity in pheochromocytoma related to blood pressure or to catecholamines? *J Clin Endocrinol Metab*. 2013;98(3):1100-1106.

2. Khorram-Manesh A, Ahlman H, Nilsson O, Odén A, Jansson S. Mortality associated with pheochromocytoma in a large Swedish cohort. *Eur J Surg Oncol*. 2004;30(5):556-559.
3. St. Sutton JM, Sheps SG, Lie JT. Prevalence of clinically unsuspected pheochromocytoma. Review of a 50-year autopsy series. *J Urol*. 1982;56(6):354-360.
4. Lenders JWM, Eisenhofer G, Mannelli M, Pacak K. Pheochromocytoma. *Lancet*. 2005;366(9486):665-675.
5. Neumann HPH, Young WF, Eng C. Pheochromocytoma and paraganglioma. *N Engl J Med*. 2019;381(6):552-565.
6. Neumann HP, Young WF, Krauss T, et al. 65 Years of the double helix: genetics informs precision practice in the diagnosis and management of pheochromocytoma. *Endocr Relat Cancer*. 2018;25(8):T201-T219.
7. Lenders JWM, Duh QY, Eisenhofer G, et al. Pheochromocytoma and paraganglioma: an endocrine society clinical practice guideline. *J Clin Endocrinol Metab*. 2014;99(6):1915-1942.
8. Ebbehøj A, Li D, Kaur RJ, et al. Epidemiology of adrenal tumours in Olmsted County, Minnesota, USA: a population-based cohort study. *Lancet Diabetes Endocrinol*. 2020;8(11):894-902.
9. Mantero F, Terzolo M, Arnaldi G, et al. A survey on adrenal incidentaloma in Italy. Study group on adrenal tumors of the Italian society of endocrinology. *J Clin Endocrinol Metab*. 2000;85(2):637-644.
10. Ichijo T, Ueshiba H, Nawata H, Yanase T. A nationwide survey of adrenal incidentalomas in Japan: the first report of clinical and epidemiological features. *Endocr J*. 2020;67(2):141-152.
11. Fassnacht M, Arlt W, Bancos I, et al. Management of adrenal incidentalomas: European society of endocrinology clinical practice guideline in collaboration with the European Network for the Study of Adrenal Tumors. *Eur J Endocrinol*. 2016;175(2):G1-G34.
12. Blanchet EM, Martucci V, Pacak K. Pheochromocytoma and paraganglioma: current functional and future molecular imaging. *Front Oncol*. 2012;1:58.
13. Chortis V, Bancos I, Crowley RK, Arlt W. Supine or sitting? Economic considerations regarding patient position during plasma metanephrine analysis for the exclusion of chromaffin tumours. *Clin Endocrinol (Oxf)*. 2015;82(3):462-463.
14. Van Berkel A, Lenders JWM, Timmers HJLM. Diagnosis of endocrine disease: biochemical diagnosis of pheochromocytoma and paraganglioma. *Eur J Endocrinol*. 2014;170(3):R109-R119.
15. NHS England. National Genomic Test Directory. Accessed November 11, 2022. <https://www.england.nhs.uk/publication/national-genomic-test-directories/>
16. Aggarwal S, Prete A, Chortis V, et al. Supplementary material for "Pheochromocytomas most commonly present as adrenal incidentalomas: a large tertiary center experience." Date of deposit June 12, 2023. https://figshare.com/articles/journal_contribution/_strong_Pheochromocytomas_Most_Commonly_Present_As_Adrenal_Incidentalomas_A_Large_Tertiary_Center_Experience_strong_/23501985
17. Thompson LDR. Pheochromocytoma of the Adrenal Gland Scaled Score (PASS) to separate benign from malignant neoplasms: a clinicopathologic and immunophenotypic study of 100 cases. *Am J Surg Pathol*. 2002;26(5):551-566.
18. Kimura N, Takayanagi R, Takizawa N, et al. Pathological grading for predicting metastasis in pheochromocytoma and paraganglioma. *Endocr Relat Cancer*. 2014;21(3):405-414.
19. Eisenhofer G, Prejbisz A, Peitzsch M, et al. Biochemical diagnosis of chromaffin cell tumors in patients at high and low risk of disease: plasma versus urinary free or deconjugated O-methylated catecholamine metabolites. *Clin Chem*. 2018;64(11):1646-1656.
20. Haissaguerre M, Courel M, Caron P, et al. Normotensive incidentally discovered pheochromocytomas display specific biochemical, cellular, and molecular characteristics. *J Clin Endocrinol Metab*. 2013;98(11):4346-4354.
21. Lloyd RV, Osamura RY, Klöppel G, Rosai J. *WHO Classification of Tumours of Endocrine Organs*. 4th ed. IARC Publications; 2017.
22. Elhassan YS, Alahdab F, Prete A, et al. Natural history of adrenal incidentalomas with and without mild autonomous cortisol excess. *Ann Intern Med*. 2019;171(2):107-116.
23. Prete A, Subramanian A, Bancos I, et al. Cardiometabolic disease burden and steroid excretion in benign adrenal tumors. *Ann Intern Med*. 2022;175(3):325-334.
24. Castinetti F, De Fremerville J-B, Guerin C, Cornu E, Sarlon G, Amar L. Controversies about the systematic preoperative pharmacological treatment before pheochromocytoma or paraganglioma surgery. *Eur J Endocrinol*. 2022;186(5):D17-D24.
25. Groeben H, Walz MK, Nottebaum BJ, et al. International multicentre review of perioperative management and outcome for catecholamine-producing tumours. *Br J Surg*. 2020;107(2):e170-e178.
26. Groeben H, Nottebaum BJ, Alesina PF, Traut A, Neumann HP, Walz MK. Perioperative α -receptor blockade in pheochromocytoma surgery: an observational case series. *Br J Anaesth*. 2017;118(2):182-189.
27. Amar L, Bertherat J, Baudin E, et al. Genetic testing in pheochromocytoma or functional paraganglioma. *J Clin Oncol*. 2005;23(34):8812-8818.
28. Gruber LM, Hartman RP, Thompson GB, et al. Pheochromocytoma characteristics and behavior differ depending on method of discovery. *J Clin Endocrinol Metab*. 2019;104(5):1386-1393.
29. Ebbehøj A, Stochholm K, Jacobsen SF, et al. Incidence and clinical presentation of pheochromocytoma and sympathetic paraganglioma: a population-based study. *J Clin Endocrinol Metab*. 2021;106(5):e2251-e2261.
30. Canu L, Van Hemert JAW, Kerstens MN, et al. CT characteristics of pheochromocytoma: relevance for the evaluation of adrenal incidentaloma. *J Clin Endocrinol Metab*. 2018;104(2):312-318.