

Washington University School of Medicine

Digital Commons@Becker

2020-Current year OA Pubs

Open Access Publications

1-1-2023

Plug inguinal hernia repair mimicking nodal spread of prostate cancer on PSMA-PET/CT

Genevieve C. Muñoz

Tyler J. Fraum

Follow this and additional works at: https://digitalcommons.wustl.edu/oa_4



Part of the [Medicine and Health Sciences Commons](#)

Please let us know how this document benefits you.

Available online at www.sciencedirect.com

ScienceDirect

journal homepage: www.elsevier.com/locate/radcr

Case Report

Plug inguinal hernia repair mimicking nodal spread of prostate cancer on PSMA-PET/CT ☆

Genevieve C. Muñoz, MA^{a,*}, Tyler J. Fraum, MD^b^a Washington University School of Medicine, St. Louis, MO, USA^b Mallinckrodt Institute of Radiology, Washington University School of Medicine, St. Louis, MO, USA

ARTICLE INFO

Article history:

Received 22 September 2022

Accepted 29 September 2022

Available online 27 October 2022

Keywords:

PET/CT

Prostate cancer

PSMA

ABSTRACT

A variety of non-prostatic or non-malignant findings exhibiting prostate specific membrane antigen (PSMA) tracer uptake and resemble metastatic disease on positron emission tomography (PET) imaging. In this case, a 72-year-old man presenting for initial staging of prostate cancer was found to have PSMA tracer uptake along the left external iliac vessels corresponding to a structure resembling a lymph node on computed tomography (CT). This finding was initially concerning for nodal spread of the patient's primary neoplasm. However, chart review revealed a remote history of left inguinal hernia plug repair with location corresponding to the area of PSMA activity. This case highlights PSMA uptake related to surgical mesh from inguinal hernia plug repair as a mimic of nodal metastatic disease on PSMA PET.

© 2022 The Authors. Published by Elsevier Inc. on behalf of University of Washington.

This is an open access article under the CC BY-NC-ND license

(<http://creativecommons.org/licenses/by-nc-nd/4.0/>)

Introduction

Positron emission tomography (PET) utilizing tracers targeting prostate specific membrane antigen (PSMA) are a powerful new imaging tool that have the potential to improve staging and management of prostate cancer. PSMA-PET has been shown to have 27% greater diagnostic accuracy in detecting metastatic prostatic disease than conventional imaging with computed tomography (CT) and bone scintigraphy [1]. However, experience with PSMA-PET has shown that benign non-prostatic structures and disease processes can display PSMA-avidity on imaging. Awareness of these potential prostate can-

cer mimics is essential to maximize the accuracy of PSMA-PET interpretations.

Case report

A 72-year-old man with a history of transurethral resection of the prostate (TURP) in 2006 secondary to benign prostatic hyperplasia and chronically elevated serum prostate-specific antigen (PSA) level presented with rising PSA values while on finasteride treatment. His PSA values increased from 3.1 ng/mL in January 2020 to 4.9 mg/mL in May 2021.

☆ Competing Interests: None.

* Corresponding author at: 510 S Kingshighway Blvd, Campus Box 8131, St. Louis, MO 63108

E-mail address: gcmunoz@wustl.edu (G.C. Muñoz).<https://doi.org/10.1016/j.radcr.2022.09.107>1930-0433/© 2022 The Authors. Published by Elsevier Inc. on behalf of University of Washington. This is an open access article under the CC BY-NC-ND license (<http://creativecommons.org/licenses/by-nc-nd/4.0/>)

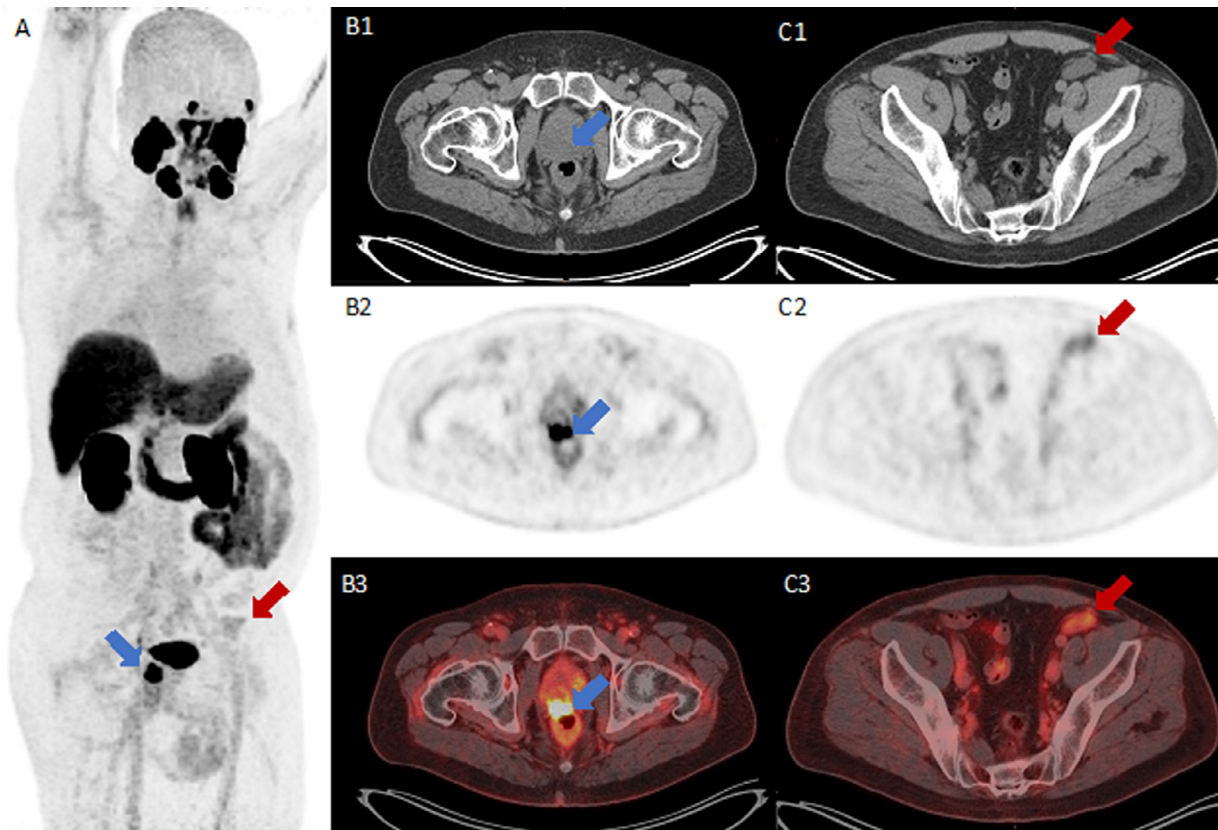


Fig. 1 – PSMA-PET/CT with findings significant for moderate tracer activity within the prostate gland (blue arrow, images A and B1-3) and mild tracer activity within a lobulated, hypoattenuating 3.5 x 1.5 cm structure along the distal left external iliac vasculature (red arrow, images A and C1-3).

This elevation in serum PSA levels despite finasteride therapy was concerning for prostate adenocarcinoma. Digital rectal exam revealed a prostate nodule at midline, and post-void scanning revealed 120 mL residual urine. A 3T prostate-protocol pelvic MRI without and with contrast revealed a large, PI-RADS 5 lesion in the right peripheral zone of the prostate gland with extra-prostatic extension and possible infiltration of the rectal wall. Biopsies indicated a Grade Group 5 adenocarcinoma of the prostate, with pathology significant for Gleason scores of $5 + 4 = 9$, $4 + 4 = 8$, and $4 + 3 = 7$ with a total of 10 of 16 cores involved. A PSMA-PET/CT performed for initial staging showed moderate focal uptake in the prostate, corresponding to the lesion seen on prior MRI (images A and B1-3, blue arrows).

The PSMA-PET/CT also showed a lobulated, hypoattenuating 3.5×1.5 cm structure along the distal left external iliac vessels with mild PSMA avidity (images A and C1-3, red arrows). This finding was initially concerning for nodal metastatic spread, although the location along the distal external iliac vasculature was felt to be unusual for prostate cancer spread. Furthermore, given the moderate PSMA-avidity of the primary tumor, the PSMA uptake in this lesion was lower than expect for a nodal metastasis of this size. These atypical imaging features prompted a chart review, which revealed that the patient had under-

gone a left inguinal hernia repair 15 years prior. Based on its shape and location, the structure in question represented a “plug” repair, in which surgical mesh is folded into a cone shape to fill the inguinal hernia defect [2]. The area of concern therefore represented benign non-prostatic PSMA uptake around a surgical mesh rather than a nodal metastasis. The patients subsequently underwent treatment with external beam radiation therapy and systemic androgen deprivation therapy, with currently undetectable serum PSA level (Fig. 1).

Discussion

To our knowledge, this is the first report of an inguinal hernia plug repair exhibiting tracer uptake on a PSMA-PET/CT, although similar findings have previously been reported for FDG-PET/CT [3,4]. PSMA uptake by non-prostatic disease processes has been reported by multiple authors [5,6]. For example, sites of neovascularization have been shown to express PSMA [7], and some have postulated that immune cells express PSMA [8]. However, the causes of non-prostatic PSMA avidity require further study.

Our case of an inguinal hernia plug repair mimicking nodal spread of prostate cancer represents an important pitfall in PSMA-PET imaging, as inguinal hernia repairs are common among men. Nodal metastasis of prostate cancer to the external iliac lymph nodes is relatively common but predominantly involves the proximal portions of this nodal chain. One large study showed that 18% of patients with treatment-naïve prostate cancer and nodal spread exhibited PSMA PET/CT avidity in the external iliac chains [9]. However, the distal location and relatively low PSMA uptake of the structure in question appropriately raised suspicion for a non-prostatic entity, allowing this finding to be correctly recognized as a surgical mesh rather than a nodal metastasis. The detection of nodal spread on PSMA-PET can have important implications for staging and treatment, and misinterpretation of this non-prostatic focus of tracer uptake could have easily impacted our patient's clinical course.

This case of benign non-prostatic PSMA avidity in the region of the external iliac vessels represents an important consideration when staging prostatic adenocarcinoma. Although nodal spread of prostate cancer is commonly found in pelvic lymph nodes, not all sites of PSMA avidity will represent metastatic disease. In addition, this case illustrates that foreign material such as surgical mesh may demonstrate PSMA avidity, even many years after placement. Inguinal hernia plug repair should be considered when a node-like PSMA-avid structure is encountered along the distal external iliac vessels.

Conclusion

PSMA-PET is an important tool for a diagnosis, staging, and surveillance of prostate cancer. Benign non-prostatic lesions exhibiting PSMA avidity are an important pitfall that can reduce staging accuracy. This case report demonstrates that surgical mesh associated with previous inguinal hernia plug repair may mimic nodal spread of prostate cancer on PSMA PET/CT.

Patient consent

All images and information were published with patient consent.

REFERENCES

- [1] Hofman MS, Lawrentschuk N, Francis RJ, Tang C, Vela I, Thomas P, et al. Prostate-specific membrane antigen PET-CT in patients with high-risk prostate cancer before curative-intent surgery or radiotherapy (proPSMA): a prospective, randomised, multicentre study. *Lancet* 2020;395(10231):1208–16.
- [2] Kulacoglu H. Current options in inguinal hernia repair in adult patients. *Hippokratia* 2011;15(3):223–31.
- [3] Bahçeci T, Nursal GN, Aydın M. Intense FDG uptake around the inguinal surgical mesh 5 years after operation: case report and review of the literature. *Mol Imaging Radionucl Ther* 2012;21(1):35–7.
- [4] Koljevic-Markovic A, Orcurto MV, Doenz F, Delaloye AB, Prior JO. Persistent FDG uptake around an inguinal mesh prosthesis 25 years after implantation. *Clin Nucl Med* 2007;32(3):242–3.
- [5] de Galiza Barbosa F, Queiroz MA, Nunes RF, Costa LB, Zaniboni EC, Marin JFG, et al. Nonprostatic diseases on PSMA PET imaging: a spectrum of benign and malignant findings. *Cancer Imaging* 2020;20(1):23.
- [6] Sheikhbahaei S, Werner RA, Solnes LB, Pienta KJ, Pomper MG, Gorin MA, et al. Prostate-specific membrane antigen (PSMA)-targeted PET imaging of prostate cancer: an update on important pitfalls. *Semin Nucl Med* 2019;49(4):255–70.
- [7] Gordon IO, Tretiakova MS, Noffsinger AE, Hart J, Reuter VE, Al-Ahmadie HA, et al. Prostate-specific membrane antigen expression in regeneration and repair. *Mod Pathol* 2008;21:1421–7.
- [8] Hermann RM, Djannatian M, Czech N, Nitsche M. Prostate-specific membrane antigen PET/CT: false-positive results due to sarcoidosis. *Case Rep Oncol* 2016;9:457–63.
- [9] Koerber SA, Stach G, Kratochwil C, Hefner MF, Rathke H, Herfarth K, et al. Lymph node involvement in treatment-naïve prostate cancer patients: correlation of PSMA PET/CT imaging and roach formula in 280 men in radiotherapeutic management. *J Nucl Med* 2020;61(1):46–50.