

Washington University School of Medicine

Digital Commons@Becker

2020-Current year OA Pubs

Open Access Publications

12-1-2022

The clinical spectrum of SMA-PME and in vitro normalization of its cellular ceramide profile

Michelle M Lee

Toni S Pearson

et al.




Follow this and additional works at: https://digitalcommons.wustl.edu/oa_4

 Part of the [Medicine and Health Sciences Commons](#)

Please let us know how this document benefits you.

RESEARCH ARTICLE

The clinical spectrum of SMA-PME and in vitro normalization of its cellular ceramide profile

Michelle M. Lee^{1,*}, Graeme S. V. McDowell^{2,*}, Darryl C. De Vivo³, Daniel Friedman⁴, Samuel F. Berkovic⁵ , Maria Spanou⁶, Argirios Dinopoulos⁶, Katheryn Grand⁷, Pedro A. Sanchez-Lara⁷, Michelle Allen-Sharples⁷, Jodi Warman-Chardon^{8,9}, Alexander Solyom¹⁰, Thierry Levade¹¹, Edward H. Schuchman¹², Steffany A. L. Bennett², David A. Dymont⁹  & Toni S. Pearson^{1,3} 

¹Department of Neurology, Washington University School of Medicine, St. Louis, Missouri, USA

²Neural Regeneration Laboratory, Ottawa Institute of Systems Biology, Department of Biochemistry, Microbiology and Immunology, University of Ottawa, Ottawa, Ontario, Canada

³Departments of Neurology and Pediatrics, Columbia University Irving Medical Center, New York, New York, USA

⁴Department of Neurology, NYU Grossman School of Medicine, New York, New York, USA

⁵Epilepsy Research Centre, Department of Medicine, University of Melbourne, Heidelberg, Victoria, Australia

⁶Pediatric Neurology Division, 3rd Department of Pediatrics, Attikon University Hospital, Athens, Greece

⁷Department of Pediatrics, Cedars-Sinai Medical Center, Los Angeles, California, USA

⁸Department of Medicine (Neurology), Ottawa Hospital Research Institute, Ottawa, Ontario, Canada

⁹Children's Hospital of Eastern Ontario Research Institute, Ottawa, Ontario, Canada

¹⁰Aceragen, Basel, Switzerland

¹¹Laboratoire de Biochimie Métabolique, CHU Toulouse, INSERM U1037, Centre de Recherches en Cancérologie de Toulouse, Université Paul Sabatier Toulouse, Toulouse, France

¹²Department of Genetics and Genomic Sciences, Icahn School of Medicine at Mount Sinai, New York, NY, USA

Correspondence

Toni S. Pearson, Division of Neurology, Nationwide Children's Hospital, Columbus, OH, USA. Tel: +614-722-4625; Fax: +614-722-4633; E-mail:

toni.pearson@nationwidechildrens.org

David A. Dymont, Children's Hospital of Eastern Ontario Research Institute, Ottawa, ON, Canada. Tel: +613-857-3668; Fax: +613-738-4220; E-mail:

ddymont@cheo.on.ca

Received: 5 September 2022; Revised: 12 October 2022; Accepted: 14 October 2022

Annals of Clinical and Translational Neurology 2022; 9(12): 1941–1952

doi: 10.1002/acn3.51687

*These authors contributed equally.

Abstract

Objective: The objectives of this study were to define the clinical and biochemical spectrum of spinal muscular atrophy with progressive myoclonic epilepsy (SMA-PME) and to determine if aberrant cellular ceramide accumulation could be normalized by enzyme replacement. **Methods:** Clinical features of 6 patients with SMA-PME were assessed by retrospective chart review, and a literature review of 24 previously published cases was performed. Leukocyte enzyme activity of acid ceramidase was assessed with a fluorescence-based assay. Skin fibroblast ceramide content and was assessed by high performance liquid chromatography, electrospray ionization tandem mass spectroscopy. Enzyme replacement was assessed using recombinant human acid ceramidase (rhAC) in vitro. **Results:** The six new patients showed the hallmark features of SMA-PME, with variable initial symptom and age of onset. Five of six patients carried at least one of the recurrent SMA-PME variants observed in two specific codons of *ASAH1*. A review of 30 total cases revealed that patients who were homozygous for the most common c.125C > T variant presented in the first decade of life with limb-girdle weakness as the initial symptom. Sensorineural hearing loss was associated with the c.456A > C variant. Leukocyte acid ceramidase activity varied from 4.1%–13.1% of controls. Ceramide species in fibroblasts were detected and total cellular ceramide content was elevated by 2 to 9-fold compared to controls. Treatment with rhAC normalized ceramide profiles in cultured fibroblasts to control levels within 48 h. **Interpretation:** This study details the genotype–phenotype correlations observed in SMA-PME and shows the impact of rhAC to correct the abnormal cellular ceramide profile in cells.

Introduction

Spinal muscular atrophy with progressive myoclonic epilepsy (SMA-PME; OMIM 159950) is an autosomal recessive lysosomal storage disorder caused by pathogenic variations in *ASAH1*.^{1–3} This gene encodes the enzyme acid ceramidase (AC), which catalyzes the breakdown of ceramides into sphingosine and free fatty acids in the lysosome.⁴ SMA-PME is a rare condition and, to date, a total of 24 patients from 19 families have been reported in detail in the literature with confirmed pathogenic variation in *ASAH1*.^{3,5–19} Reported patients commonly present with proximal weakness in mid-childhood, followed by progressive seizures and myoclonus.²⁰ Mortality may result from respiratory insufficiency in early adulthood or from complications of refractory seizures. The isolated neurological phenotype observed in SMA-PME contrasts with the predominant peripheral symptoms associated with Farber Lipogranulomatosis or Farber disease (FD; OMIM:22800). FD is also a result of pathogenic variation at *ASAH1* and is characterized by a clinical triad of joint disease presenting as arthritis and/or contractures, subcutaneous nodules, and a hoarse voice secondary to laryngeal involvement.²¹ Farber disease has a broad phenotypic spectrum ranging from rapidly progressive disease leading to death in the first years of life, to rarer forms characterized by slowly progressive adult-onset disease.²² While peripheral symptoms predominate in Farber disease, there have also been neurological symptoms reported to occur in a subset of patients that includes seizures, hypotonia, and lower motor neuron disease that can show in the late stages of the disease.^{18,23}

Here, we describe the clinical features of six patients with SMA-PME (four previously unpublished and two published with brief clinical data^{24,25}). We analyze the clinical features and relationship of genotype to phenotype in these 6 patients and the 24 previously reported.^{3,5–17} We describe pathogenic nonsense, missense, or splice site variants in *ASAH1* in each patient combined with biochemical verification of AC loss of function either by the detection of elevated ceramide using high performance liquid chromatography, electrospray ionization, tandem mass spectrometry (LC–ESI–MS/MS) or by AC deficiency assessed through enzyme analysis. We further show that the cellular phenotype of increased ceramide profile can be normalized by treatment with recombinant human acid ceramidase (rhAC). These observations provide insights into the broad phenotypic spectrum observed in SMA-PME and provide *in vitro* evidence for the impact of rhAC as a potential treatment requiring further pre-clinical investigation.

Methods

Standard protocol approvals, registrations, and patient consents

Six patients were enrolled by informed consent from their families and according to the following research ethics board approvals: CHEO REB #11/04 E.

Participants

We report here six patients with SMA-PME and their genotypes. Clinical information was collected retrospectively. Additional literature reviews were performed for 24 previously reported cases with molecularly confirmed SMA-PME.^{3,5–17} Criteria for inclusion were: an isolated neurological presentation, an adequate description of the clinical phenotype, and confirmed pathogenic variants in *ASAH1*. We excluded reports of cases that lacked clinical data²⁶ and historical reports of SMA-PME that lacked molecular confirmation. Because several transcripts have been used in the literature when describing variants in *ASAH1*, we have converted variants to nomenclature corresponding to the NM_177924.5 transcript.¹⁹

Acid ceramidase activity and immunoblotting

Fibroblast cell lines were generated from a punch biopsy by standard methods. Leukocyte AC activity was assayed in patients and their parents. Lymphocytes were isolated from whole blood and AC activity was determined in the cell lysates using a fluorescence-based assay with minor modifications.^{27,28} Fibroblast AC activity before (0 h) and after rhAC treatment (24 and 48 h) was assayed in three patients compared to seven controls (age- and sex-matched) by LC–ESI–MS/MS as described below. Immunoblotting was performed as previously described.²⁹ Primary antibodies were rabbit anti-ASAHI α , 1/500 (gifted by Professor Konrad Sandhoff, Universität Bonn) and rabbit anti-ASAHI β , 1/400, (Sigma, cat# HP005468). Secondary antibodies were HRP-Donkey anti-Rabbit IgG, 1:5000, (Jackson ImmunoResearch, cat# 711-035-152).

In vitro treatment with rhAC and LC–ESI–MS/MS analysis of cellular ceramide content

Primary fibroblasts were cultured in Dulbecco's Modified Eagle Medium: Ham's Nutrient mixture 12 (D-MEM/F-12) (Gibco, cat# 12400-016) supplemented with 10% fetal bovine serum (Sigma Aldrich, F0926), and 2 mmol/L L-glutamine (Gibco, cat# 25030–081). Recombinant human acid ceramidase (rhAC) is derived from CHO-M cells

transfected with a DNA plasmid vector expressing wild-type human AC. It was produced at a contract manufacturing facility and was provided under material transfer agreement (MTA) originated under Enzyvant and currently with Aceragen. Development for potential clinical use is continuing under Aceragen as ACG-801. Where treatment with rhAC is indicated, cultures were treated with 10 $\mu\text{g}/\text{mL}$ of rhAC in complete media similarly to the work in Farber patient cells.³⁰ Media + rhAC was refreshed every 24 h. Lipids were extracted according to a modified acidified Bligh and Dyer lipid extraction previously described in detail.^{31,32} Briefly, cells were trypsinized, counted via hemocytometer, washed with phosphate buffered saline (BioShop, cat# PBS404), and pelleted. Pellets were resuspended in 0.1 mol/L sodium acetate (Sigma, cat# S-2889, in LC/MS grade water; J.T. Baker, cat# 9831-03), acidified methanol (2% acetic acid, Fisher, A38-212 in methanol; Fisher, cat#BP1105, (v/v)) was added, along with 235 pmol of Cer(d18:1/16:0-d31) (Avanti Polar Lipids, cat# 868516). Lipids were extracted by addition of chloroform (Fisher, cat# C298) to a ratio of 1.6:2:1.4 sodium acetate:acidified methanol:chloroform (v/v/v). The organic phase was collected, and the samples were back-extracted three times, with the organic phases being collected and pooled. Samples were dried under a constant stream of nitrogen gas. Dried lipid extracts were re-dissolved in ethanol, stored under nitrogen gas in amber glass vials (Chromatographic Specialties, cat# C779100AW) and kept at -80°C until use.

Ceramide content was quantified by LC-ESI-MS/MS using an Agilent 1290 LC and a triple quadrupole-linear ion trap mass spectrometer QTRAP 5500 (AB SCIEX). LC separation was achieved on a 100 mm \times 250 μm (i.d.) capillary column packed with ReproSil-Pur 120 C8 beads (particle size of 3 μm and pore size of 120 \AA , Dr. A. Maisch, Ammerbruch, Germany) with 5 μL sample injections by an autosampler maintained at 4°C with a flow rate of 10 $\mu\text{L}/\text{min}$. The binary solvent gradient consisted of LC/MS grade water with 0.1% formic acid (Fisher, 56302) and 10 mmol/L ammonium acetate (OmniPur, 2145) (solvent A), and acetonitrile (J.T. Baker cat#9829-03)/isopropanol (Fisher, cat# A416-4) (5:2; v/v) with 0.1% formic acid and 10 mmol/L ammonium acetate (solvent B). Gradient elution started with 30% B, ramping to 100% B over 5 min. After 30 min at 100% B, the gradient dropped to 30% B over the course of a minute, where it remained for the time remaining in the run to re-equilibrate the column. Data acquisition was performed in positive ion mode using multiple reaction monitoring (MRM) monitoring the product ion of 264.3, corresponding to di-dehydrated d18:1 sphingosine backbone. Instrument control and data acquisition were performed with Analyst software (v. 1.6.2, AB SCIEX).

Processing of quantitative MRM data was performed using MultiQuant software (v. 3.0.2, AB SCIEX). Ceramide abundances were expressed as pmol equivalents of Cer(d18:1/16:0-d31) per million cells. Percent activity, defined as the change in ceramide content at 0, 24, and 48 h following rhAC treatment, was expressed relative to untreated age- and sex-matched controls. Total ceramide content was analyzed statistically using a one-way ANOVA with Holm-Šidák post-hoc tests. Changes in the abundances of individual ceramide species were determined statistically by multiple *t*-tests with false discovery rate (FDR) set at 1% using two-stage linear step-up FDR procedure of Benjamini, Krieger and Yekutieli³³ without assuming consistent standard deviation. The change in percent activity was assessed 0–48 h after treatment with rhAC and time needed to correct ceramide levels determined by linear regression. Statistical analyses were performed using GraphPad Prism version 9.41 (GraphPad Software).

Data availability

Anonymized data not published within the article will be made available upon request from a qualified investigator(s).

Results

Case reports

Patient 1 is a 21-year-old female, briefly reported previously at age 15 years,²⁵ who presented with seizures, weakness, and involuntary movements at age 9 years. Her non-consanguineous parents were of South Asian ancestry. Following normal early childhood development, her reported first symptom was mild learning difficulties at age 7 years (Table 1). At age 9 years, she developed brief and sudden drop attacks, and separate episodes of eye rolling and staring. An EEG showed generalized epileptiform discharges and a diagnosis of myoclonic seizures was made. Treatment with sodium valproate was initiated. At age 10 years, she developed difficulty rising from the floor due to muscle weakness, “limb shaking,” and torticollis (head turn to the left). At age 12 years, she developed generalized tonic-clonic seizures. Neurological examination at age 13 years revealed hypotonia and symmetrical, proximal upper and lower limb muscle atrophy and weakness with relatively preserved distal limb strength. Tendon reflexes were brisk with spread. Hoffman’s sign was present bilaterally. She had cervical and foot dystonia. There were frequent brief, small amplitude multifocal jerks in the hands and arms at rest that increased with action, and in the legs upon standing, consistent with cortical myoclonus. Gait was independent,

Table 1. Clinical characteristics of 6 patients with molecularly confirmed SMA-PME

ID	Sex	Onset age (years)	Initial symptom	Weakness onset age (years)	Seizure onset age (years)	Seizure types	EEG findings	Other features	Age at Last follow-up	ASAH1 genotype [NM_177924.5]
1	F	7	Learning difficulties	10	9	GTC, myoclonic	Diffuse background slowing; 2.5–3 Hz focal spikes with maximum amplitude posteriorly, bursts of generalized spike-slow wave (age 16)	Myoclonus, dystonia	21 years	c.124A>G p.(Thr42Ala), c.536C>T p.(Thr179Ile)
2	M	5	SNHL	12	15	GTC, absence, myoclonic	Frontal predominant, generalized spike and polyspike-wave discharges in runs of up to 15 seconds (age 21)	Myoclonus, cognitive decline, anxiety	Died at age 26 years	c.125+1G>A, c.456A>C
3	F	2	Weakness	2	6	Atonic, myoclonic, absence	Abundant generalized 3–4 Hz spike and wave discharges in runs of up to 8 seconds during wakefulness, improving in sleep (age 10)	Myoclonus	11 years	c.125C>T p.(Thr42Met)
4	M	3	Speech delay, SNHL	15	10	GTC, myoclonic	Generalized epileptiform activity with occipital predominance	Cognitive decline, hallucinations	Died at age 19 years	c.456A>C, c.918-2A>G
5	F	3	Seizures	4	3	Atonic, myoclonic	Generalized complexes of spike and wave with frontal-central predominance. Rhythmic spike activity located in central region related with episodes of behavioral arrest with fear and scream	Tongue fasciculation, moderate SNHL	10 years	c.109C>A p.(Pro37Thr), c.410_411del p.(Tyr137*)
6	F	13	Seizures	None reported	13	Myoclonic	Multiple episodes of epileptic myoclonus	Myoclonus, SNHL detected on audiology (asymptomatic)	14 years	c.186G>A p.(Trp62*), c.456A>C

GTC, generalized tonic-clonic; SNHL, sensorineural hearing loss.

normal-based and steady. Her weakness progressed and she lost the ability to walk independently at age 14 years. At age 16–17 years, her seizure burden worsened and there was accompanying cognitive decline, leading to a homebound state. At age 21 years, she has severe generalized weakness and is tracheostomy- and ventilator-dependent due to chronic respiratory failure. Trio-exome sequencing showed biallelic variants in *ASAHI*; c.536C > T, p.(Thr179Ile) and c.124A > G, p.(Thr42Ala) (Table 1).

Patient 2 was a 26-year-old male who presented at age 22 years with seizures, myoclonus, and weakness. His early childhood medical and developmental history were normal. At age 5 years he was diagnosed with sensorineural hearing loss (Table 1). At age 12 years, he began to have difficulty keeping up with peers in sports. He nonetheless continued to play sports until age 16 years. At age 15 years, he had his first generalized tonic-clonic seizure. After a second seizure, he was treated with phenytoin and then valproate. He was seizure-free until age 18 years, when he experienced a prolonged generalized tonic-clonic seizure after starting college. These continued every few weeks with subsequent daily staring spells. Mild cognitive difficulties (short term memory and processing speed impairments), limb myoclonus, and anxiety were apparent by age 18 years and progressed. He continued to experience dozens of myoclonic seizures per day that were refractory to medications. Placement of a vagal nerve stimulator at age 21 years did not improve seizure frequency. On examination at 22 years of age, Montreal Cognitive Assessment (score 18/30) revealed impaired executive function, spatial construction, memory, and attention. He had mild proximal upper and lower limb weakness, prominent facial myoclonus, and myoclonus in both arms that worsened with action. Tendon reflexes were reduced in the arms, normal in the legs, and plantar reflexes were flexor. Gait was wide-based and unsteady. Between age 22 and 24 years, he had daily myoclonic and absence seizures and tonic-clonic seizures every 6 months. Despite mild cognitive impairment, he was able to complete college level courses online. At age 24 years, he required a wheelchair and 24-h support for activities of daily living. From age 25 to 26 years, he had multiple hospitalizations for aspiration pneumonia. He died at age 26 years due to respiratory failure. Sanger sequencing of *ASAHI* identified the splicing variants c.125 + 1G > A and c.456A > C (Table 1).

Patient 3 is an 11-year-old female with a background history of sickle cell disease who presented at age 5 years with early-onset, progressive weakness. A maternal half-brother had died at age 9 years, with a diagnosis of a “spinal muscular atrophy-like illness” associated with seizures that had manifested initially with weakness at

2.5 years of age. Her first reported symptom, at age 2 years, was muscle weakness that caused falls and difficulty climbing stairs (Table 1). Neurological examination at age 5 years revealed age-appropriate speech and cognitive function. She had tongue fasciculations and limb-girdle weakness with milder distal limb weakness. Tendon reflexes were normal in the arms and brisk in the legs with bilateral ankle clonus. She had a waddling gait, and Gowers’ sign was present. At age 6 years she developed myoclonic seizures characterized by brief head drops. By age 10 years progressive weakness led to impaired head control, inability to lift her arms above shoulder-height, and loss of independent ambulation. At age 10–11 years her seizures worsened; she developed frequent seizures with altered responsiveness, refractory to multiple medications (levetiracetam, valproic acid, lacosamide, perampamil) and regression of cognitive function. A gastrostomy tube was inserted at age 11 years and initiation of the ketogenic diet led to subsequent improvement in seizure frequency and duration, although multiple daily myoclonic seizures persisted. Exome sequencing at age 5 years identified a homozygous pathogenic variant in *ASAHI*, c.125C > T, p.(Thr42Met) (Table 1).

Patient 4 was a 19-year-old male, briefly reported by Courage *et al.*,²⁴ who first presented at age 3–4 years with speech delay (Table 1). He was found to have mild to moderate high frequency bilateral sensorineural hearing loss. Otherwise, his perinatal and early childhood medical and developmental history were normal. There were no significant concerns about his cognition though parents reflected post-diagnosis that he had lost some specific skills during childhood (for example, the ability to read the hands of a clock). At age 10 years, he presented with “muscle twitching” and was initially diagnosed with a tic disorder. The abnormal movements progressed in frequency (up to once every 30 s) and included head drops. An EEG at age 12 years demonstrated frequent generalized epileptiform activity with an occipital emphasis, marked photosensitivity, and revealed the ‘twitches’ to be myoclonic jerks, leading to a diagnosis of progressive myoclonic epilepsy. He remained active in sports until age 15 years when leg weakness prevented athletic activities. Subsequent motor deterioration was rapid. He became fully wheelchair-dependent by age 16 years due to progressive proximal weakness and frequent falls, and developed recurrent tonic-clonic seizures at that age. Speech became slurred and, at age 18 years, he lost the ability to speak, coincident with onset of hallucinations and clear cognitive decline. Due to progressive weight loss and concerns for choking, and recurrent respiratory infections, a gastrostomy tube was inserted at age 18 years and he required night-time non-invasive ventilation. His seizure burden became increasingly severe and he died at

age 19 years due to status epilepticus. Exome sequencing identified the *ASAH1* variant, c.918-2A > G that is suspected to impact splicing, and the known splicing variant, c.456A > C (Table 1).

Patient 5 is a 10-year-old female who first presented at age 3 years with frequent falls (Table 1). At age 4 years, episodes progressed to include head drops. EEG showed generalized spike-wave epileptic discharges with central-parietal predominance. Brain MRI was normal and a metabolic work up was non-diagnostic. At age 5.5 years, seizures occurred several times per day with tonic extension of upper limbs followed by a cry and expression of fear. On examination, she had tongue fasciculations, vertical downgaze palsy, distal myoclonus of the limbs, lower limb hyperreflexia, and muscle weakness. A second brain MRI at age 6 years revealed generalized cerebral atrophy. At age 6.5 years she presented with myoclonic seizures and suspected lower motor neuron disease. Exome analysis revealed a paternally inherited heterozygous variant c.109C > A, p.(Pro37Thr) in *ASAH1*. A second variant was not identified at that time. An EMG confirmed neuropathy and enzyme activity of AC was significantly reduced in leukocytes (Table 3), confirming the diagnosis of SMA-PME. At last follow-up at age 10 years, she had significant muscle weakness, ptosis, and moderate sensorineuronal hearing loss. Her memory and cognition were preserved. She continued to experience 20–50 seizures per day with short myoclonic jerks, head drop, and episodes of behavioral arrest, refractory to multiple medications. Sequencing of *ASAH1* performed by the Care4Rare Canada Consortium subsequently identified a second, maternally inherited variant in *ASAH1*, c.410_411del, p.(Tyr137*) (Table 1).

Patient 6 is a 14-year-old typically developing female who first presented at age 13 years with abnormal jerking movements of her legs and arms. (Table 1; Table S1). Her prior medical history was unremarkable and she was initially diagnosed with tics by her primary physician. Neurologic examination demonstrated decreased muscle bulk and hyporeflexia in the upper extremities, and bursts of upper limb myoclonus. A brain MRI and nerve conduction study were both normal. An EEG demonstrated poly-spike and wave discharges and multiple episodes of epileptic myoclonus, and she was diagnosed with juvenile myoclonic epilepsy. Treatment with levetiracetam was initiated, with a good response. An epilepsy next-generation sequencing panel revealed two pathogenic variants in *ASAH1*, c.186G > A, p.(Trp62*) and the splicing variant c.456A > C, each inherited from an unaffected carrier parent (Table 1). EMG subsequently demonstrated chronic neurogenic changes of proximal and bulbar muscles. Audiology evaluation revealed sensorineural hearing loss, which was asymptomatic. Two of her three siblings

have also inherited both pathogenic variants. At ages 13 and 11 years, both siblings are typically developing and asymptomatic, but did have evidence of high frequency hearing loss on audiology screening.

Clinical features of the 6 patients indicate a well-defined spectrum but broad phenotypic variability in terms of age at onset, individual symptom severity and outcome (Table 1; Table S1). Consistently observed features were: gradually progressive proximal limb weakness due to lower motor neuron involvement, myoclonic seizures, and persistent myoclonus that worsened with action and was typically most evident in the arms and hands. In all patients, symptom onset was in childhood–adolescence (age 2–13 years) but initial symptoms were variable with weakness ($n = 1$), subtle cognitive dysfunction ($n = 1$), seizures ($n = 2$), or sensorineural hearing loss ($n = 2$). Loss of ambulation due to progressive weakness occurred during the second decade of life in 3 cases; two patients became unable to walk before age 10 years, and another had seizures only. Cognitive decline became apparent during the course of the disease for patients 1–4. Cervical and foot dystonia, not previously reported as manifestations of SMA-PME,¹⁹ were uniquely observed in patient 1.

Five of the six patients had previously reported pathogenic variants (Table 2).^{3,5–19} Patient 3 was homozygous for the most frequent SMA-PME variant, c.125C > T p.(Thr42Met). Alterations at the same codon at c.124A > G p.(Thr42Ala) and the adjacent nucleotide (c.125 + 1) in Patients 1 and 2, respectively, suggest that this is an important locus for SMA-PME. Another recurrent variant, c.456A > C, was observed in patients 2, 4, and 6. The splice variant within intron 11 (c.918-2A > G) was previously reported in Patient 4, and in a patient with a mixed presentation of SMA and Farber disease.^{24,34} The c.410_11del p.(Tyr137*) variant in Patient 5 was previously reported in a patient with SMA without epilepsy who later developed systemic features of FD¹⁷. Two entirely novel variants were identified: *ASAH1*, c.109C > A, p.(Pro37Thr) (in Patient 5), and *ASAH1*, c.186G > A, p.(Trp62*) (in Patient 6) (Table 1).

Literature review and phenotype:genotype correlations

We analyzed these genotypes and natural histories together with the 24 cases of SMA-PME previously reported in the literature from 19 families^{3,5–17} (Table 2; Table S1). While the overall number of reported patients are few, there is some evidence of a genotype:phenotype correlation for specific recurrent variants that have been observed in at least 3 families (Table 2). Patients who were homozygous for the most common variant,

Table 2. Clinical characteristics by *ASAH1* genotype

	Homozygous or compound heterozygous for most frequent variant, c.125C>T p.(Thr42Met)	Carriers of c.456A>C	Carriers of c.124A>G p.(Thr42Ala)	Remaining genotypes
Number of patients	13 (11 homozygous)	7	4 (2 homozygous)	6
Age of onset – mean (range)	4.8 y (2–10 y)	6.7 y (3–13 y)	5.7 y (3–7 y)	3.2 y (0.8–8 y)
Initial symptom				
Weakness	Y (12/13)	Y (2/7)	Y (3/4)	Y (4/6)
Seizures	N	Y (2/7)	N	Y (2/6)
Myoclonus	Y (1/13)	Y (3/7)	N	Y (1/6)
Sensorineural hearing loss	N	Y (2/7)	N	N
Learning/developmental difficulties	N	Y (1/7)	Y (1/4)	N
Clinical features during disease course				
Weakness	Y (13/13)	Y (6/7)	Y (4/4)	Y (6/6)
Time from weakness onset to loss of ambulation	9.8 y (6–13 y; N = 6)	9.8 y (1–15 y, N = 4)	4.0 years (N = 1) 3 patients remained ambulatory into adulthood	9.0 y (N=1)
Seizures	Y (13/13)	Y (7/7)	Y (1/4)	Y (5/6)
Onset age of seizures	8.0 y (3–12 y; N = 13)	11.5 y (8–15 y, N=6)	9 y (N = 1)	4 y (3 and 5 y; N = 2)
Myoclonus	Y (13/13)	Y (7/7)	Y (2/4)	Y (3/6)
Hearing loss	NR (0/13)	Y (6/7)	NR (0/4)	Y (1/6)
Age at death	16.5 y (13–19 y; N = 4)	20.7 y (17–26 y; N = 3)	None have died	None have died
Mixed (FD) clinical course	N	N	Y (N = 1)	Y (N=1)

Y, yes; N, No; NR, not reported.

c.125C > T p.(Thr42Met) ($n = 11$, including Patient 3 in the current report), typically developed weakness in the first decade of life as the initial symptom, with one exception of a patient whose initial symptom was tremor (Table 2; Table S1). The splicing variant c.456A > C was associated with sensorineural hearing loss in 6 of 7 patients with this variant, including 3 of the patients in this series. It was the initial symptom in Patients 2 and 4, and was detected after diagnosis on audiology assessment in patient 6. Initial symptoms were variable in this group (Table 2). A recurrent c.124A > G p.(Thr42Ala) variant was detected in four patients, three of whom did not develop seizures at all by ages 17, 30, and 45 years, respectively (Table 2; Table S1). Reported clinical features in the fourth group without any recurrent variant (Table 2) were variable, with myoclonus or tremor in only 50%, although the small numbers preclude statistical comparison.

hAC processing, activity, and function

Human AC enzyme levels were assessed by immunoblotting of lysates extracted from fibroblasts derived from patients 1, 2, and 4. In all three patients, levels of the beta subunit (40 kDa) were reduced and levels of the alpha subunit were barely detectable compared to unrelated age

and sex-matched controls (Fig. 1). Cellular AC activity was assessed in leukocytes from patients 1, 2, 3, and 5. Activity ranged from 4.1% to 13.1% compared to either unaffected carrier parents or unrelated controls (Table 3). AC function was further assessed in fibroblasts from patients 1, 2, 4, and 5 by directly quantifying cellular ceramide content by LC-ESI-MS/MS. Total cellular ceramide content was significantly elevated in each patient confirming loss of AC function and thus pathogenicity of the *ASAH1* variants (Fig. 2A–D, left panel). In total, 18 different ceramide species with a d18:1 sphingosine backbone were detected. Abundances of 11 species were significantly elevated in patient 1 (Fig. 2A, right panel). All species were significantly elevated in patients 2, 4, and 5 regardless of N-acyl chain length or degree of unsaturation (Fig. 2B–D, right panel).

Rescue of the cellular phenotype by rhAC

To assess whether enzyme replacement could normalize cellular ceramide levels in SMA-PME cells, dermal fibroblasts cultures from patients 1, 2, and 4 were treated for 0, 24, and 48 h with wild-type rhAC (10 µg/mL) (Fig. 3). Administration of rhAC significantly reduced total ceramide abundance (Fig. 3A). Assessment of the rate of change in activity indicated that 58 h of treatment would

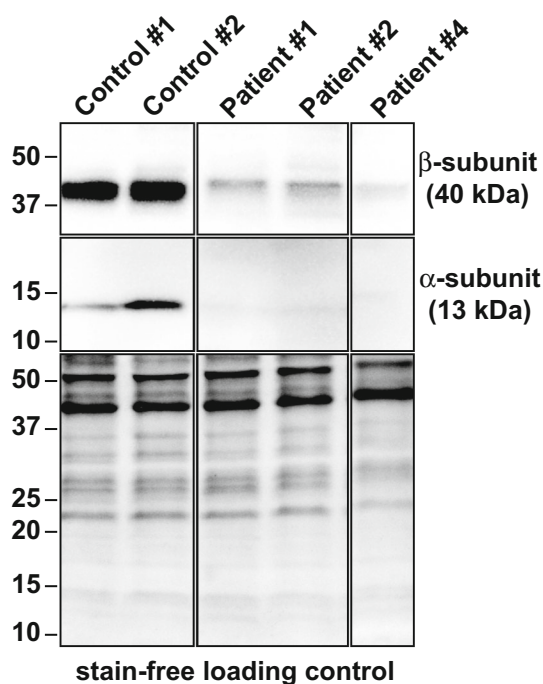


Figure 1. Assessment of AC enzyme processing by immunoblotting. Levels of the acid ceramidase β - and α -subunit are reduced compared to controls in Patient #1, #2, and #4. Loading controls are stain-free signal of total protein assessed using the PROTEAN TGX Stain-Free system.

Table 3. Acid ceramidase activity in leukocytes (nmol/mg/hour)

	Unrelated control	Patient	Mother	Father	Patient % of parent(s)	Patient % of control
Family 1		0.117	1.846	1.466	7.1	–
Family 2	–	0.110	1.551	1.331	7.6	–
Family 3	3.380	0.162	1.238	–	13.1	4.8
Family 5		0.225	4.919	6.039	4.1	

be required to completely correct ceramide levels in vitro (Fig. 3B).

Discussion

SMA-PME remains an ultra-rare condition that now encompasses 30 reported patients with molecularly confirmed variation in *ASAHI*. Our series of 6 patients from different families, examined in the context of the 24 previously reported patients, illustrate the significant variability of symptom onset and progression of SMA-PME. Initial symptoms include weakness due to motor neuron disease, seizures, or myoclonus. These features, which may vary in the order of onset, constitute the core clinical

features of this condition. The small-amplitude, twitchy movements of cortical myoclonus may mimic tremor, especially in the hands. This may explain the description of tremor in several previously reported cases (Table S1). In addition, sensorineural hearing loss was the presenting symptom in two of our patients, who both carried the c.456A > C variant.

The disease course of our 6 patients illustrate the clinical spectrum of this disorder, from which certain patterns of genotype:phenotype correlation emerge. (Table 2; Table S1). First, individuals who are homozygous for the common recurrent c.125C > T variant characteristically present with proximal limb weakness during early childhood (between ages 2 and 6 years in all but one patient), followed within a few years by the development of seizures, and progressive motor and cognitive functional decline thereafter. The time from symptom onset to loss of the ability to walk ranged from 6 to 13 years in those reported, and the age of death was typically in the teen years. However, it should be emphasized that some individuals continued to walk independently and survived into their late teens and early 20s. Second, the recurrent heterozygous c.456A > C variant was associated with sensorineural hearing loss in 6 of 7 reported patients (3 in this series and 3 in the literature).^{5,8,11,24} Hearing loss was the first symptom in 2 of our patients, presenting years before the onset of either seizures or weakness. The hearing of the last patient with this variant was not described in the report describing their symptoms.⁷ Five of these seven patients experienced a later onset of seizures and weakness than patients homozygous for *ASAHI*, c.125C > T, p.(Thr42Met), manifesting during the second decade of life. Further study will be required for definitive conclusions regarding any genotype:phenotype correlation.

There are only 6 patients who do not carry at least one copy of the recurrent variants, and they show a higher degree of symptom variability than those with the recurrent variants (Table S1). For example, 2 siblings homozygous for c.1078A > G experienced onset of weakness at age 10 months,¹⁵ which is the youngest age of onset reported. Another patient without a recurrent variant carries a homozygous change at c.1157G > A.¹⁵ This patient had optic atrophy, not previously associated with SMA-PME, in addition to weakness and seizures. Lastly, Patient 5 in the current series with a substitution at c.109C > A, p.(Pro37Thr) and a small deletion at c.410_411del, p.(Tyr137*) had an extremely early onset of intractable seizures at age 3 years that occurred prior to onset of weakness.

When we review the *genotypes* of the 24 reported cases and the current 6 cases, it becomes apparent that 20/30 (66%) carry at least one copy of the recurrent variants

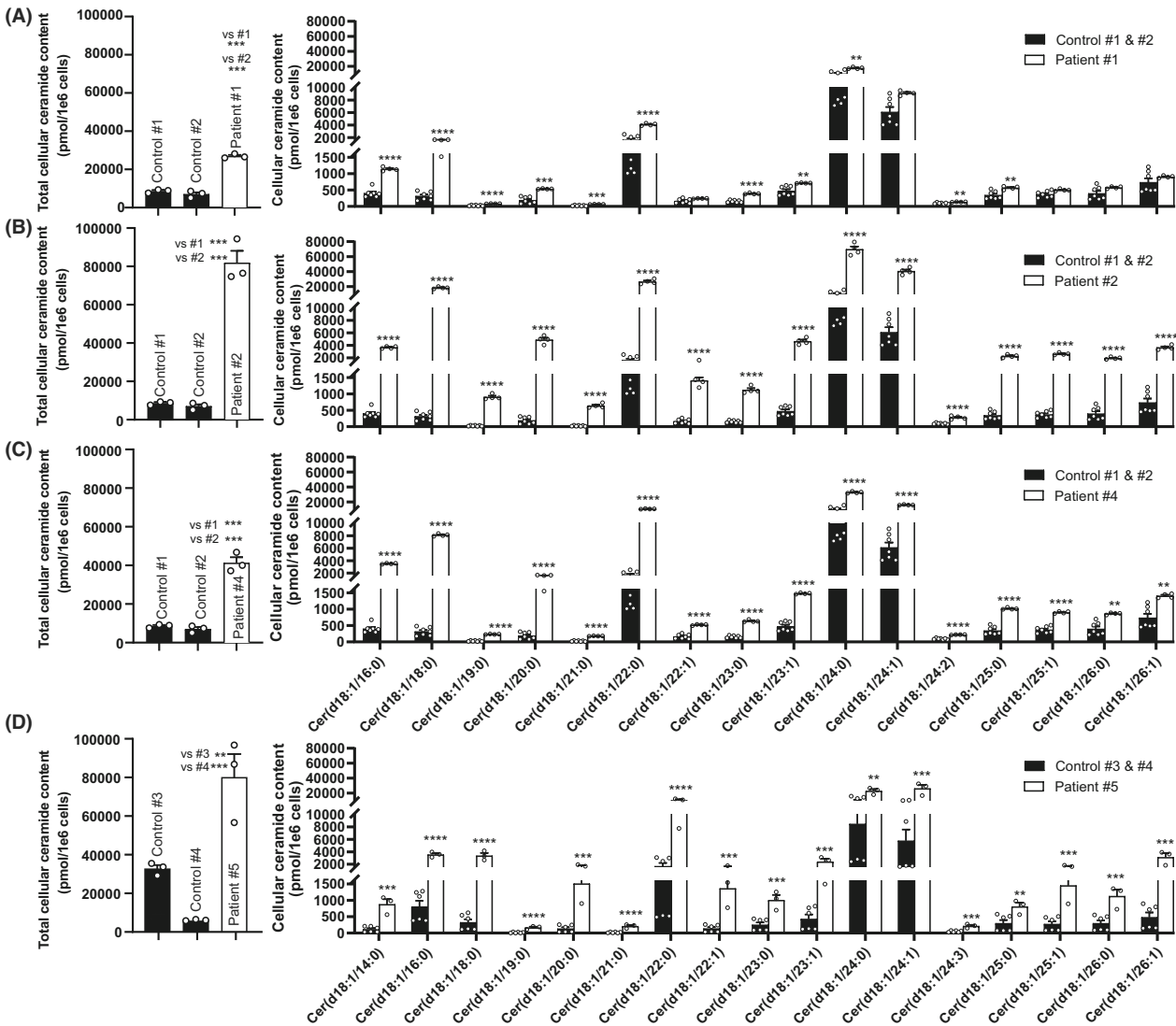


Figure 2. Molecular profiling by LC-ESI-MS/MS of fibroblast ceramides. Levels of the individual profiled ceramide species in controls and in (A) Patient #1, (B) Patient #2, (C) Patient #4, and (D) Patient #5. Data represents mean abundance (pmol/1E6 cells) \pm SEM. In control cultures, data represent $n = 3$ –4 cultures from two different control (wild-type) biopsies. In patient cultures, data are $n = 4$ cultures from the same patient. Statistics are multiple unpaired t -tests with Welch t -test correction and false detection rate of 1% according to Benjamini, Krieger, and Yeukuteli. $^{**}q < 0.01$.

c.125C > T, p.(Thr42Met), and c.124A > G, p.(Thr42Ala) or the immediately adjacent c.125 + 1 (thought to impact the splice at the exon 2 boundary²⁶). When the other recurrent variant is considered (c.456A > C), 25/30 (83%) carry at least one of the variants at these two loci. The c.456A > C variant does not induce a p.(Lys152Asn) substitution, but rather alters exon splicing.⁵ The other 3 variants located near exon/intron boundaries (c.125C > T, p.(Thr42Ala), c.124A > G, p.(Thr42Met) and c.125 + 1) have not been assessed for their impact on splicing in lymphocytes, and detection programs provide mixed results. Ceramidase activity has been reported for

some, but not all, of the 24 cases in the literature^{3,5,8,10,13,14} and the activity was highly variable from 4.7% to 32% of controls. The enzyme activity of the four cases reported here (4.1–13.1%) was consistent with previous reports.

Acid ceramidase deficiency may present with isolated neurologic features (SMA-PME, predominant PME alone,⁵ SMA alone^{10,14}), isolated systemic features (forms of FD,¹⁸ progressive osteolysis,²² familial keloid scars³⁵), or a combination.¹⁸ The development of systemic symptoms in adulthood following childhood-onset SMA has been reported.¹⁶ The pathophysiological mechanisms that

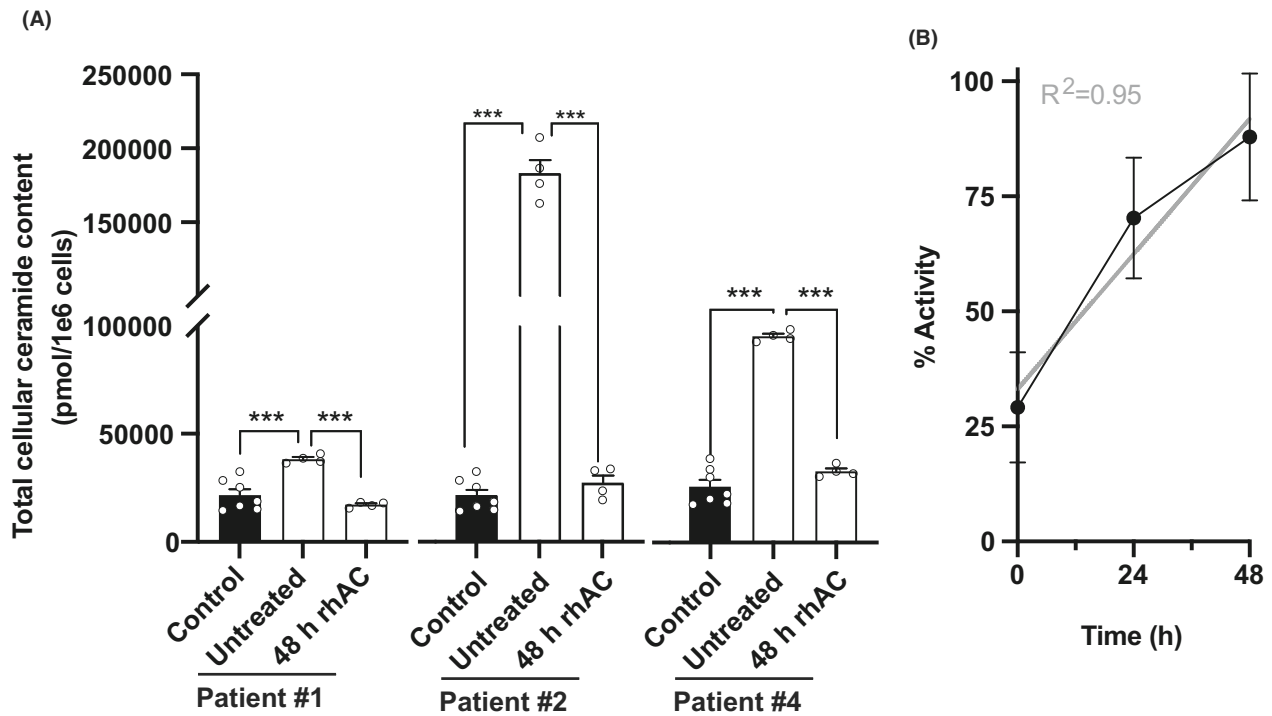


Figure 3. Loss of *ASAH1* function in fibroblasts of patient#1, #2, and #4 can be rescued by treatment with rhAC. (A) Total ceramide levels, quantified by LC-ESI-MS/MS, are significantly increased in fibroblasts cultures of SMA-PME patients relative to control (wild-type *ASAH1*). Treatment for 48 h with wild-type rhAC (10 μ g/mL) normalizes ceramide levels. Levels in all rhAC-treated cultures were comparable to control levels and significantly lower than in untreated cultures. Data represents mean \pm SEM. In control cultures, data represent $n = 3-4$ replicate cultures from four different control (wild-type) biopsies. Note the controls compared to patient#1 and patient#2 are fibroblast cultures from a 26-year-old male and a 9-year-old female; controls compared to patient#4 were fibroblasts from a 6 year old male and a 7 year old male. In patient cultures, $n = 4$ replicate cultures from the same patient. Statistics are one-way ANOVA. *** $p < 0.001$, *post-hoc* Holm-Šidák correction for multiple comparisons. (B) The time required to correct ceramide levels in patient fibroblasts was determined by establishing the rate of change in percent activity at 0, 24, and 48 h following treatment with rhAC relative to all controls and performing linear regression. 58 h of treatment with 10 μ g/ml rhAC would be required to normalize fully ceramide content in vitro.

underlie this phenotypic variability are not yet understood. Residual AC activity, while overall reduced in the *ASAH1* disease spectrum, does not correlate, entirely, with either SMA-PME or FD. Pathogenic variants in the alpha and beta subunit of the enzyme also appear to occur in both disorders so an obvious effect of the protein subunit is not apparent. There are recurrent variants observed in Farber disease alone (c.998G > A, c.505T > C) as well as the previously mentioned recurrent variants in SMA-PME (c.125C > T, c.124A > G, c.456A > C). Importantly, the only published variants shared in both disorders are c.918-2A > G and c.410_411del, each observed in one patient in this series (Patients 4 and 5, respectively) and in one other individual with a mixed presentation of SMA and FD.^{17,34} This highlights the potential importance of the patients' genotype in predicting the clinical manifestations and disease course. Increasing knowledge of the biology of AC, particularly its catalytic mechanism and the importance of specific amino acid residues for its

activation and function, should lead to improved understanding of how the dysfunction can result in such disparate presentations. The use of mass spectrometry to characterize the metabolomic signature in patients is a key means of understanding how phenotypes may be similar or differ from one another in a predictive fashion.

Management of SMA-PME is supportive and multidisciplinary with no curative treatments available. Alayoubi et al. generated a mouse model of systemic AC deficiency, and it has been shown that AC enzyme replacement (either by direct injection or gene therapy with a lentivirus vector) leads to reduced cellular infiltrations, reduced ceramide in target tissues, and increased lifespans in Farber mice.^{30,36} Hematopoietic stem cell transplant has resulted in a resolution of the peripheral symptoms in some Farber patients, which is also a promising indication of the potential of enzyme replacement in human patients, but there does not appear to be an effect on CNS symptoms.³⁷

Our study is the first preclinical study to demonstrate the effects of recombinant enzyme replacement (currently in development as ACG-801) in cells from patients with an SMA-PME phenotype resulting from acid ceramidase deficiency, including demonstration that the ceramide accumulation in cultured fibroblasts can be rescued by treatment with rhAC. This has been performed with success in a mouse model of Farber disease.³⁰ Our work represents a preliminary study that requires replication and further preclinical study but does point to restoration of homeostasis by administration of wild-type enzyme over time. It is reasonable to expect that delivery of rhAC into the central nervous system will be required to be effective as a treatment for neurologic manifestations of AC deficiency although this will represent a significant obstacle to overcome given the enzyme's inability to cross the blood–brain barrier. The therapeutic window of opportunity to halt or even potentially reverse clinical progression in SMA-PME also remains to be determined.

Acknowledgements

The authors would like to acknowledge the patients and their families for their participation in this research. Sequencing of *ASAH1* for Patient 5 was performed by Ruobing Zou and the Care4Rare Canada Consortium. The authors would like to thank Dr. Wendy Mears for sample preparation. Recombinant human acid ceramidase enzyme (rhAC) was provided by Enzyvant under a material transfer agreement, the compound is being further developed for potential clinical use by Aceragen as ACG-801. This work was supported in part by a Can-Gard Spring Accelerator grant to DAD and SALB.

Conflict of Interest

Dr Schuchman is a consultant and member of the Scientific Advisory Board for Aceragen, the company that manufactures the recombinant enzyme that was used for the *in vitro* studies described in this manuscript. Dr Schuchman co-founded a start-up company that was formed to study and treat acid ceramidase deficiency which was later sold to Aceragen, and holds stock options in Aceragen which have not been exercised.

Author Contributions

AS, EHS, SALB, DAD, and TSP participated in study design. MML, GSVM, DCD, DF, SFB, MS, AD, KG, PAS-L, MA-S, JW-S, TL, EHS, SALB, DAD, and TSP collected and analyzed data. GSVM performed experiments. MML, GSVM, DF, SFB, MS, AD, KG, PAS-L, MA-S, SALB, DAD, and TSP drafted the manuscript. All authors revised manuscript for intellectual content.

REFERENCES

1. Lance JW, Evans WA. Progressive myoclonic epilepsy, nerve deafness and spinal muscular atrophy. *Clin Exp Neurol*. 1984;20:141-151.
2. Haliloglu G, Chattopadhyay A, Skorodis L, et al. Spinal muscular atrophy with progressive myoclonic epilepsy: report of new cases and review of the literature. *Neuropediatrics*. 2002;33(6):314-319.
3. Zhou J, Tawk M, Tiziano FD, et al. Spinal muscular atrophy associated with progressive myoclonic epilepsy is caused by mutations in *ASAH1*. *Am J Hum Genet*. 2012;91(1):5-14.
4. Li C-M, Park J-H, He X, et al. The human acid ceramidase gene (*ASAH*): structure, chromosomal location, mutation analysis, and expression. *Genomics*. 1999;62(2):223-231.
5. Dyment DA, Sell E, Vanstone MR, et al. Evidence for clinical, genetic and biochemical variability in spinal muscular atrophy with progressive myoclonic epilepsy: evidence for variability of SMA-PME. *Clin Genet*. 2014;86(6):558-563.
6. Giraldez BG, Guerrero-Lopez R, Ortega-Moreno L, et al. Uniparental disomy as a cause of spinal muscular atrophy and progressive myoclonic epilepsy: phenotypic homogeneity due to the homozygous c.125C>T mutation in *ASAH1*. *Neuromuscul Disord*. 2015;25(3):222-224.
7. Rubboli G, Veggiotti P, Pini A, et al. Spinal muscular atrophy associated with progressive myoclonic epilepsy: a rare condition caused by mutations in *ASAH1*. *Epilepsia*. 2015;56:692-698. <http://www.ncbi.nlm.nih.gov/pubmed/25847462>
8. Gan JJ, Garcia V, Tian J, et al. Acid ceramidase deficiency associated with spinal muscular atrophy with progressive myoclonic epilepsy. *Neuromuscul Disord*. 2015;25(12):959-963.
9. Oguz Akarsu E, Tekturk P, Yapici Z, Tepgec F, Uyguner ZO, Baykan B. Eyelid myoclonic status epilepticus: a rare phenotype in spinal muscular atrophy with progressive myoclonic epilepsy associated with *ASAH1* gene mutation. *Seizure*. 2016;42:49-51.
10. Filosto M, Aureli M, Castellotti B, et al. *ASAH1* variant causing a mild SMA phenotype with no myoclonic epilepsy: a clinical, biochemical and molecular study. *Eur J Hum Genet*. 2016;24(11):1578-1583.
11. Kernohan KD, Frésard L, Zappala Z, et al. Whole-transcriptome sequencing in blood provides a diagnosis of spinal muscular atrophy with progressive myoclonic epilepsy. *Hum Mutat*. 2017;38(6):611-614.
12. Yildiz EP, Yesil G, Bektas G, et al. Spinal muscular atrophy with progressive myoclonic epilepsy linked to mutations in *ASAH1*. *Clin Neurol Neurosurg*. 2018;164:47-49.
13. Shervin Badv R, Nilipour Y, Rahimi-Dehgolan S, Rashidi-Nezhad A, Ghahvechi Akbari M. A novel case report of

- spinal muscular atrophy with progressive myoclonic epilepsy from Iran. *Int Med Case Rep J*. 2019;12:155-159.
14. Ame van der Beek N, Nelson I, Froissart R, et al. A new case of SMA phenotype without epilepsy due to biallelic variants in *ASAHI*. *Eur J Hum Genet*. 2019;27(3):337-339.
 15. Mahmoud IG, Elmonem MA, Zaki MS, et al. *ASAHI*-related disorders: description of 15 novel pediatric patients and expansion of the clinical phenotype. *Clin Genet*. 2020;98(6):598-605.
 16. Puma A, Ezaru A, Cavalli M, et al. A case of *ASAHI*-related pure SMA evolving into adult-onset Farber disease. *Clin Genet*. 2021;100(2):234-235.
 17. Axente M, Shelby E-S, Mirea A, et al. Clinical features and genetics in non-5q spinal muscular atrophy caused by acid ceramidase deficiency. *J Med Life*. 2021;14(3):424-428.
 18. Yu FPS, Amintas S, Levade T, Medin JA. Acid ceramidase deficiency: Farber disease and SMA-PME. *Orphanet J Rare Dis*. 2018;13(1):121.
 19. Elsea SH, Solyom A, Martin K, et al. *ASAHI* pathogenic variants associated with acid ceramidase deficiency: Farber disease and spinal muscular atrophy with progressive myoclonic epilepsy. *Hum Mutat*. 2020;41(9):1469-1487.
 20. Dymant DA, Bennett SA, Medin JA, Levade T. *ASAHI*-Related Disorders. In: Adam MP, Ardinger HH, Pagon RA, et al., eds. *GeneReviews*®. University of Washington, Seattle; 1993 [cited 2021 Sep 19]. Available from: <http://www.ncbi.nlm.nih.gov/books/NBK488189/>
 21. Levade T, Sandhoff K, Schulze H, Medin JA. Acid ceramidase deficiency: Farber Lipogranulomatosis. In: Valle DL, Antonarakis S, Ballabio A, et al., eds. *Scriver's Online Metabolic and Molecular Basis of Inherited Disease*. McGraw-Hill; 2019 [cited 2021 Sep 19] Available from: <https://ommbid.mhmedical.com/content.aspx?bookid=2709§ionid=225069235>
 22. Bonafé L, Kariminejad A, Li J, et al. Brief report: peripheral osteolysis in adults linked to *ASAHI* (acid ceramidase) mutations: a new presentation of Farber's disease. *Arthritis Rheumatol*. 2016;68(9):2323-2327.
 23. Levade T, Moser HW, Fensom AH, Harzer K, Moser AB, Salvayre R. Neurodegenerative course in ceramidase deficiency (Farber disease) correlates with the residual lysosomal ceramide turnover in cultured living patient cells. *J Neurol Sci*. 1995;134(1-2):108-114.
 24. Courage C, Oliver KL, Park EJ, et al. Progressive myoclonus epilepsies—residual unsolved cases have marked genetic heterogeneity including dolichol-dependent protein glycosylation pathway genes. *Am J Hum Genet*. 2021;108(4):722-738.
 25. Sathé S, Pearson T. Phenotypic characterization of the spinal muscular atrophy with progressive myoclonus epilepsy syndrome caused by *ASAHI* mutations. *Mol Genet Metab*. 2014;111(2):S93.
 26. Cozma C, Iuraşcu M-I, Eichler S, et al. C26-Ceramide as highly sensitive biomarker for the diagnosis of Farber disease. *Sci Rep*. 2017;7(1):6149.
 27. He X, Li CM, Park JH, Dagan A, Gatt S, Schuchman EH. A fluorescence-based high-performance liquid chromatographic assay to determine acid ceramidase activity. *Anal Biochem*. 1999;274(2):264-269.
 28. Bedia C, Camacho L, Abad JL, Fabriàs G, Levade T. A simple fluorogenic method for determination of acid ceramidase activity and diagnosis of Farber disease. *J Lipid Res*. 2010;51(12):3542-3547.
 29. Fowler SL, Maclean AC, Bennett SA. Tissue-specific cross-reactivity of connexin32 antibodies: problems and solutions unique to the central nervous system. *Cell Commun Adhes*. 2009;16(4):117-130.
 30. He X, Dworski S, Zhu C, et al. Enzyme replacement therapy for Farber disease: proof-of-concept studies in cells and mice. *BBA Clin*. 2017;7:85-96.
 31. Granger MW, Liu H, Fowler CF, et al. Distinct disruptions in Land's cycle remodeling of glycerophosphocholines in murine cortex mark symptomatic onset and progression in two Alzheimer's disease mouse models. *J Neurochem*. 2019;149(4):499-517.
 32. Xu H, Valenzuela N, Fai S, Figeys D, Bennett SAL. Targeted lipidomics – advances in profiling lysophosphocholine and platelet-activating factor second messengers. *FEBS J*. 2013;280(22):5652-5667.
 33. Benjamini Y, Krieger AM, Yekutieli D. Adaptive linear step-up procedures that control the false discovery rate. *Biometrika*. 2006;93(3):491-507.
 34. Lee BH, Mongiovi P, Levade T, Marston B, Mountain J, Ciafaloni E. Spinal muscular atrophy and Farber disease due to *ASAHI* variants: a case report. *Am J Med Genet A*. 2020;182(10):2369-2371.
 35. Santos-Cortez RLP, Hu Y, Sun F, et al. Identification of *ASAHI* as a susceptibility gene for familial keloids. *Eur J Hum Genet*. 2017;25(10):1155-1161.
 36. Alayoubi AM, Wang JCM, Au BCY, et al. Systemic ceramide accumulation leads to severe and varied pathological consequences. *EMBO Mol Med*. 2013;5(6):827-842.
 37. Ehler K, Frosch M, Fehse N, Zander A, Roth J, Vormoor J. Farber disease: clinical presentation, pathogenesis and a new approach to treatment. *Pediatr Rheumatol*. 2007;5(1):15.

Supporting Information

Additional supporting information may be found online in the Supporting Information section at the end of the article.

Table S1. Characteristics of patients with SMA-PME from the literature.