

Jurnal Info Kesehatan

Vol. 21, No. 2, June 2023, pp. 239-247

P-ISSN 0216-504X, E-ISSN 2620-536X

DOI: [10.31965/infokes.Vol21Iss2.1064](https://doi.org/10.31965/infokes.Vol21Iss2.1064)

Journal homepage: <http://jurnal.poltekkeskupang.ac.id/index.php/infokes>



RESEARCH

Open Access

MRI Case Report of Perianal Fistula with T2 TSE SPIR Sequence

Nursama Heru Apriantoro^{1a*}, Arif Rohman Saleh^{1b}, Gando Sari^{1c}, Puji Supriyono^{1d}, Mahfud Edy Widiatmoko^{1e}

¹ Department of Radiodiagnostics and Radiotherapy, Politeknik Kesehatan Kementerian Kesehatan Jakarta II, Jakarta, Indonesia

^a Email address: nursamaheru@poltekkesjkt2.ac.id

^b Email address: arif.r.saleh@gmail.com

^c Email address: bundagandosari@gmail.com

^d Email address: puji.supriyono1964@gmail.com

^e Email address: mhfdmoko@gmail.com

Received: 22 January 2023

Revised: 28 May 2023

Accepted: 15 June 2023

Abstract

MRI is a diagnostic imaging tool crucial for pelvic examination in perianal fistula cases. MRI imaging offers some advantages, especially in showing the area of spesi and secondary dilatation. Both have a high recurrence rate after surgery and an important role in determining surgical outcomes and minimizing complications. This study aims to evaluate pelvic MRI examination of perianal fistulas using the T2 TSE SPIR (Turbo Spin Echo Spectral Presaturation with Inversion Recovery) sequence. Research design used a qualitative descriptive method with participatory observation through a case study approach to Perianal Fistula using T2 TSE_SPIR. It was carried out at the Radiology Department of Mayapada Hospital in South Jakarta from August to December 2022. The MRI equipment Philips Achieva 1.5 Tesla with Sense Body Coil. MRI contrast agent of gadoteric acid, Vitamin E capsule, was attached to the perianal fistula location to make it easier for the radiologist to see the path of the perianal fistula. The results of Pelvis MRI images in perianal fistulas using the T2 TSE SPIR sequence shown with clear boundaries of perianal fistulas with anal organs, sigmoid colon, bladder, and prostate between one organ and another. Implementing the selection of the T2 TSE SPIR sequence to visualize fluid images becomes hyper-intensive by suppressing fat signals so that only fluid is visible in the perianal abscess and fistula images.

Keywords: MRI Perianal Fistula, T2 TSE SPIR, Gadoteric Acid, Sense Body Coil.

*Corresponding Author:

Nursama Heru Apriantoro

Department of Radiodiagnostics and Radiotherapy, Politeknik Kesehatan Kementerian Kesehatan Jakarta II, Jakarta, Indonesia

Email: nursamaheru@poltekkesjkt2.ac.id



©The Author(s) 2023. This article is distributed under the terms of the Creative Commons Attribution 4.0 International License (<http://creativecommons.org/licenses/by/4.0/>), which permits unrestricted use, distribution, and reproduction in any medium, provided you give appropriate credit to the original author(s) and the source, provide a link to the Creative Commons license, and indicate if changes were made. The Creative Commons Public Domain Dedication waiver (<http://creativecommons.org/publicdomain/zero/1.0/>) applies to the data made available in this article, unless otherwise stated.

1. INTRODUCTION

Perianal fistula is an inflammatory disorder in the anorectal area characterized by the presence of a channel between the anal canal and the (Das & Chakrabartty, 2021; Sarda et al., 2022; Włodarczyk et al., 2021). An anal fistula is usually the result of an untreated perianal abscess. This condition may also be associated with tuberculosis, cancer, radiation therapy, etc. (Amarprakash et al., 2022; Hokkanen et al., 2019). Perianal fistulae are the second most common anorectal disease after hemorrhoids. Surgery is considered the treatment of choice, aiming to avoid recurrence and maintain anal sphincter function. The risk of recurrence increases to 25% if the surgeon fails to recognize and thoroughly remove the fistula and associated elements during corrective surgery, especially internal openings and secondary tracts (Singh et al. 2022). Accurate and comprehensive evaluation of the fistula tract before surgery is, therefore a very important diagnostic strategy and greatly contributes to the success of the surgery. Magnetic resonance imaging (MRI) examination to determine fistula tract anatomy, presence of an abscess, and parameters of inflammation (Halligan, 2020; Shahzad et al., 2021; Włodarczyk et al. 2021)

MRI imaging has emerged as the preferred technique for preoperative evaluation of perianal fistulas to better treatment outcomes. The importance of MR imaging in this context lies in its ability to reveal hidden areas of sepsis and secondary enlargement, both of which contribute to high postoperative recurrence rates, determine surgical outcomes, and minimize complications. It plays an important role in limiting. Additionally, MRI images can be used to define the anatomic relationship of the perianal fistula and forecast the likelihood of post-operative faecal incontinence (Amato et al., 2020; Criado et al., 2018; Molteni et al., 2018; Shahzad et al., 2021; Sharma et al., 2020; Westbrook & Talbot, 2019).

MRI tools are more accurate than endosonography in determining the type of fistula and allow more branches to be detected (Cerit et al., 2020; Wahyuningtiyas & Apriantoro, 2020; Sharma et al., 2020). In another study, CT scan fistulography was able to locate the internal orifice in 28 patients (68.2%), whereas MRI was able to detect this aspect in 35 patients (85.3%).was more successful (Shahzad et al., 2021). Granulation tissue, inflammation, and edema around the fistula, abscess, and fistula wall fibrosis were also evaluated, from the study benefit from resonance imaging Magnetic (MR) includes Multiplanar imaging and advanced soft tissue differentiation (Madany et al., 2023; Sharma et al., 2022)

MRI is a diagnostic imaging tool that is very crucial in Pelvis MRI in cases of perianal fistula (Chen et al., 2021; Hyde et al., 2018; Lee et al., 2018). Examination technique and Pelvis MRI sequence for perianal fistulas used in routine examinations at MRI Radiology Installation Mayapada Hospital South Jakarta using a marker procedure at a location suspected of having a perianal fistula using vitamin E with the clockwise method and the sequence used T1W_TSE, T2W_TSE, and T2W_TSE_SPIR followed by gadolinium-based contrast material sequence T1W_TSE (Konan et al., 2018; Kakani, 2021; Sarma, 2019; Westbrook & Talbot, 2019). Using fat suppression techniques used in MRI examination is Spectral Presaturation with Inversion Recovery (SPIR), a fat suppression method that applies a frequency selective Inversion pulse. Frequency selective Inversion pulse is a combination of Fat Saturation and Short TAU Inversion Recovery (STIR) techniques which are based on not only fat tissue resonance frequency but also a short Time Inversion (TI) time (McRobbie et al., 2017; Westbrook & Talbot, 2019). This technique for this study to get a result that can suppress the fat signal so that only fluid signals are visualized on imaging, showing the perianal fistula tract, and inflammation in the area around the fistula.

2. RESEARCH METHOD

The research method used qualitative descriptive with participatory observation through a case study approach to Perianal Fistula using T2 TSE SPIR. The Case study was conducted

at the Radiology installation of Mayapada Hospital in south Jakarta. These observation samples include only patients with perianal fistula cases from August to December 2022. Data were taken based on the results of observations, bibliographies, documentation, and interview results. Instruments and materials used during the research include; MRI equipment with PHILIPS 1.5 Tesla Achieva, Sense Body Coil, MRI headphones, and other supporting devices in the form of an MRI operator table, handscoon, tissue, earplugs, and patient monitoring devices in the MRI room. The examination parameters was used as shown in Table 1. This research has received ethical approval from the Health Polytechnic of the Ministry of Health Jakarta II No.LB.02.01/I/30/1091/2022.

Table 1. Parameters for Pelvis MRI using T2_TSE_SPIR sequences.

Sequences	TR ^a (ms)	TE ^b (ms)	FOV ^c (cm)	Matrix	Thick (mm)	Gaps (mm)	NSA ^d
Sagittal T2W_TSE	3660	80	38	512 x 256	3	0.3	2
Sagittal T2W_TSE_SPIR	3658	120	38	512 x 320	3	0.3	2
sagittal T1W_TSE	645	10	38	512 x 256	3	0.3	2
T2W_TSE axial oblique	466	80	25	320 x 256	3	0.3	3
T2W_TSE_SPIR axial oblique	3658	120	25	320 x 256	3	0.3	3
T2W_TSE coronal oblique	466	80	28	320 x 256	3	0.3	3
T2W_TSE_SPIR coronal oblique	3658	120	28	320 x 256	3	0.3	3
Postcontrast Sagittal T1W_SPIR	593	9	38	512 x 256	3	0.3	2
Axial oblique	593	9	25	320 x 256	3	0.3	2
Coronal obliques	593	9	28	320 x 256	3	0.3	2

^aTR = Time Repetition, ^bTE= Time Echo, ^cFOV= Field of View, ^dNSA = Number of Average

To prevent the patient from vomit or discomfort during the examinations, the patient must have fasted for 4 hours before the examinations start. The patient has to fills out informed consent and the examination procedure must be explained to the patient right before examinations. for precautions of allergic reactions for contrast injection, patients must be doing an allergic test before examinations. A nurse did abocath installation. The abocath used size no. 22, which is placed on the right metacarpal. Three-way installation was carried out and connected to a double syringe injector. If needed before starting injections of sterile fluid (NaCl) in perianal fistulas.

Placing a marker (vitamin E capsule) where there is a suspected lump of boil or pus is coming out using the anal clock method. If the location is more than one, then the marker is also more than one according to the number of boils. Position the patient supine at the MRI examination table with head first into the gantry (head first). The collimator light parallel to the Mid Sagittal Plane (MSP) and the middle of the pelvic area. Attach the Sense Body Coil in the middle of the pelvic area with the upper limit of the iliac crista and the lower border of the pubic symphysis. Provide an emergency bell to communication between the radiographer and the patient and instruct the patient not to move during the examination.

After all the preparations, the next step is to complete the patient identity and parameter examination to create axial, sagittal, and coronal topograms. Do the parameter settings for taking the sagittal image first, then axial oblique and coronal oblique sections are made from the sagittal image. After the pre-contrast sequence is completed, it is continued with the contrast media administration and scanned for Sagittal, Coronal, and Axial Oblique images. The

contrast medium concentration of a gadoteric acid 0.5 mmol/ml was used in Pelvic MRI examination of perianal fistulas at the Radiology Department of Mayapada Hospital.

3. RESULTS AND DISCUSSION

The patient of 44 years old man and 60 kg weight with perianal fistula has present in this study, ureum and creatinine results showed that kidney function is in normal range for urea and creatinine laboratory test of 20 mg/dl and 0.97mg/dl, respectively. Then the patient can continue the examination. In this study, to obtained the image of perianal abscess or perianal fistula, three planar images of T2W TSE are important to made, it's very helpful to visualize fluid images. However, on the T2 image, there is fat, and the visualization results are also hyper-intense. Fat has a high signal on magnetic resonance images (MRI), high signal due to fat may be responsible for artifacts such as ghosting and chemical shift. Therefore, the SPIR fat suppression method is used to suppress the fat signal so that only fluid signals are visualized on imaging (Delfaut et al., 1999; Murphy, 2020)

T1W_SPIR Post contrast media three-planar sequence to visualize inflammation in the perianal abscess and perianal fistula area using the SPIR fat suppression method suppresses fat signals so that only fluid signals are visualized on imaging.

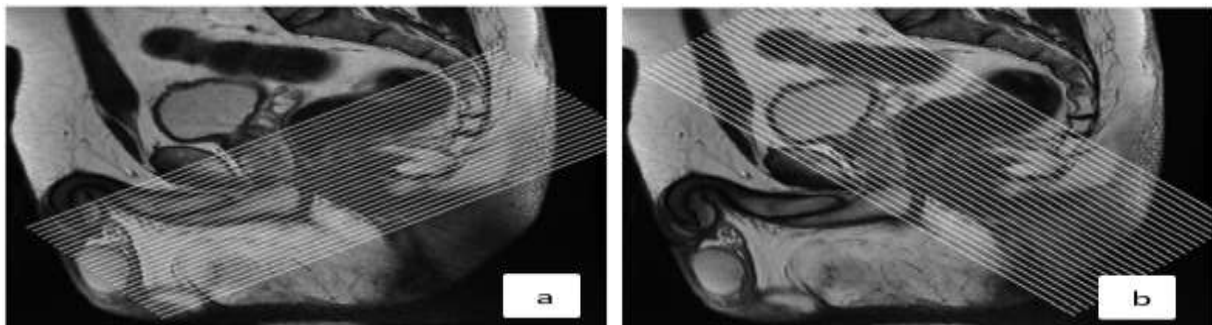


Figure 1. Sagittal MRI sequence images: a. T2W TSE, b. T1W TSE

The objective of the sagittal topogram in MRI is to determine the anatomical description of the pelvic organs and the fistula tract in axial and coronal image. Figure 1 shows that the sagittal image has been used to determine axial and coronal planes. Image (a), sagittal T2W TSE recommended guidance for axial MRI imaging of the anal canal. Position the oblique cross perpendicular to the anal canal to obtain a completely axial image, and image (b), T2W TSE, Recommended guidance for coronal MRI imaging of the anal canal. Coronal MRI imaging is implemented oblique or at 90° to the axial plane to acquire images parallel to the long axis of the anal canal (Criado et al., 2018).

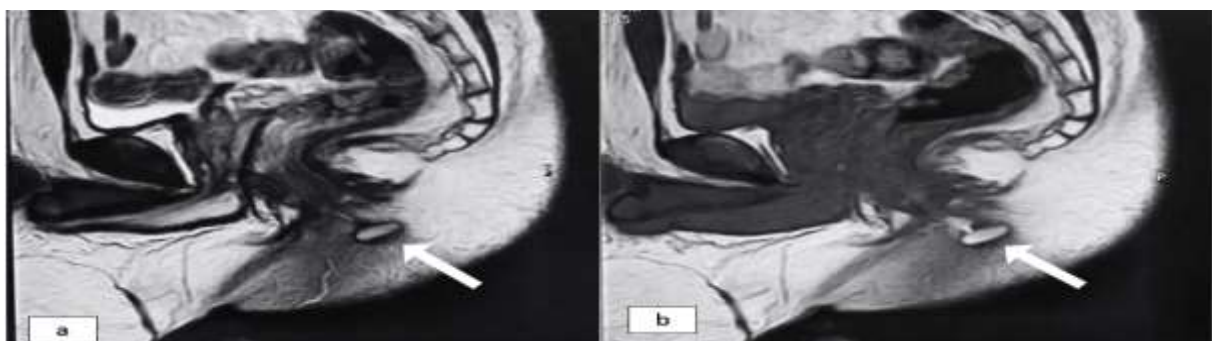


Figure 2. Image of vitamin E capsule in *Sagittal* sequence of a) T2 TSE and b) T1 TSE.

Figure 2 shows the vitamin E capsule markers in the T2 TSE and T1 TSE sagittal sequence images as shown by the arrows indicating the fistula opening to the surface of the skin.

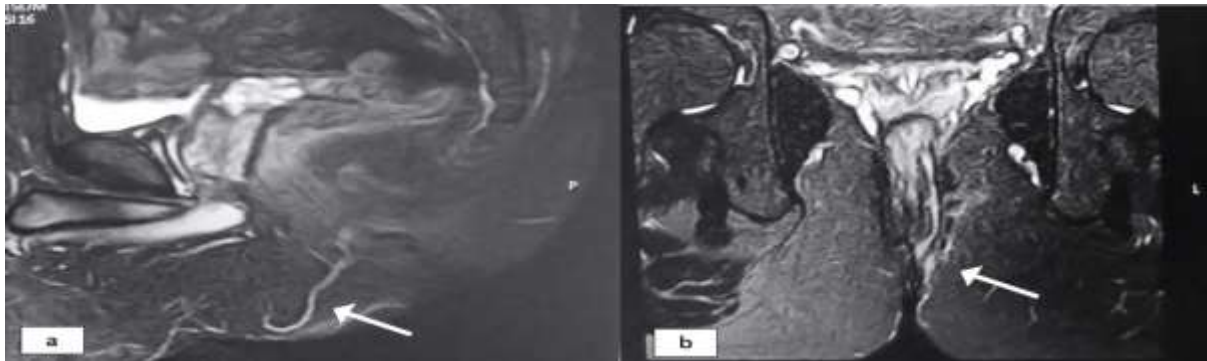


Figure 3. Image fat suppression of sequence images: a. T2 TSE SPIR *sagittal* and b. T2 TSE SPIR coronal oblique.

Figure 3 shows that the fat suppression method with the T2 TSE SPIR sagittal sequence (a), which shows the fistula path as shown by the arrows, and the T2 TSE SPIR (b) oblique coronal sequence images with the fat suppression method, the arrows show the fistula tract looking hyperintense.

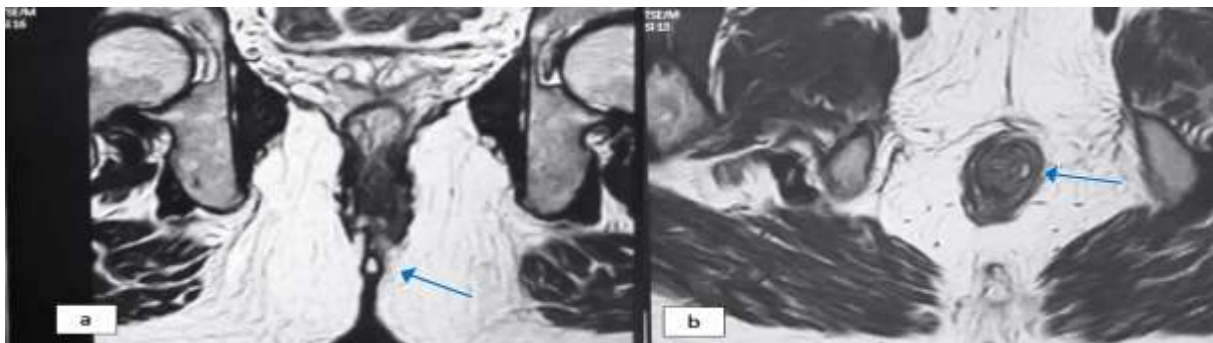


Figure 4. Sequence images of: a. coronal oblique T2 TSE and b. Axial oblique T2 TSE.

Figure 4 (a) shows the vitamin E capsule marker with hyperintense showing the location of the perianal fistula on the skin's surface, and (b) shows the interspinteric fistula indicated by arrows on a hyperintense view.

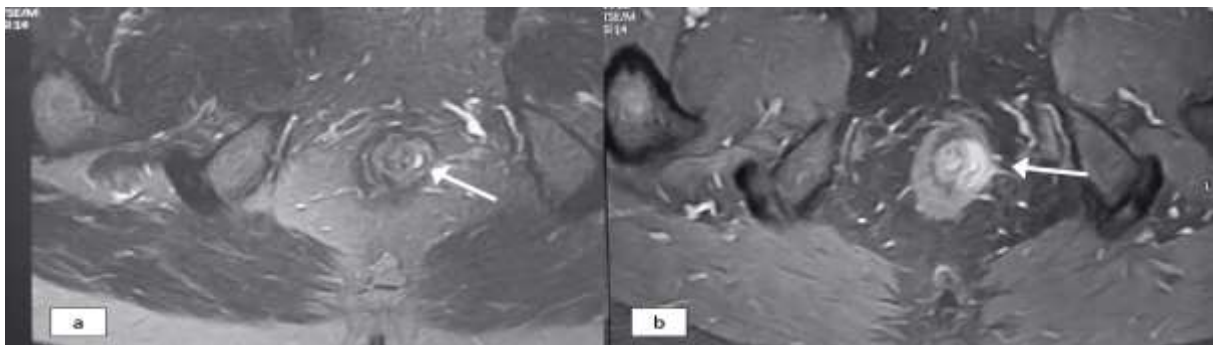


Figure 5. Interspinteric fistula Image: a. Axial oblique T2 TSE and b. coronal oblique T1 TSE SPIR + C.

Figure 5 (a) shows an interspinteric fistula with Axial oblique T2 TSE SPIR sequence shown by arrows and (b) Coronal oblique T1 TSE SPIR + C sequence image, with contrast media administration and fat suppression method, arrows showing active inflammation in the area around the fistula.

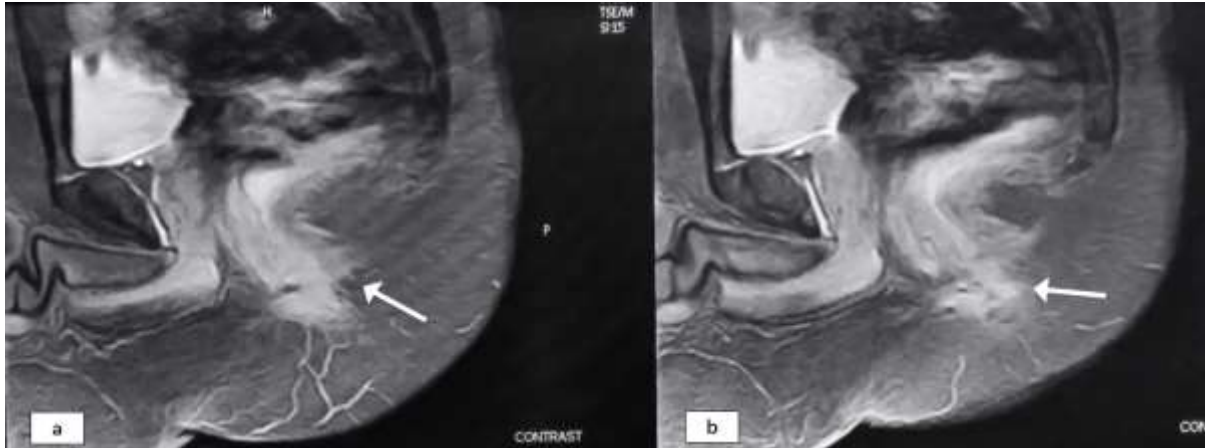


Figure 6. T1 TSE SPIR sagittal sequence images.

Figure 6 shows an image with the administration of contrast media and the T1 TSE SPIR + C sagittal fat suppression method and arrows showing active inflammation around the fistula.

Imaging technique of pelvis MRI at Radiology Department of Mayapada Hospital is in accordance with the theory by using the right topography. It began with obtaining the sagittal plane and was then used as a guidance to obtain other planes, such as axial oblique and coronal oblique (Deprest et al., 2021; Ho et al., 2019). The retriever is tilted anteriorly approximately 45° vertically in the sagittal plane to allow accurate assessment of fistula tract origin on axial and coronal images (Figure 1). There are several things that have been changed, namely the use of the T1 TSE sequence before and after the contrast as shown in Figure 2. The purpose of creating T1 TSE sequences is to assess anatomy in the pelvic area. After that, use the SPIR fat suppression method, which eliminates fat signals with an inversion time corresponding to the zero point of fat.

T2 images showed that there is fat which the visualization results are also hyper-intense, therefore we use the SPIR fat suppression method to suppress fat signals so that only fluid signals are visualized on imaging (Figure 3). The usage of pelvic MRI protocol of perianal fistula examination of perianal fistulas at the Mayapada Hospital consist of pre contrast media - sagittal T2 TSE, sagittal T2 TSE SPIR, sagittal T1 TSE, axial oblique T2 TSE, axial oblique T2 TSE SPIR, coronal oblique T2 TSE, Coronal oblique T2 TSE SPIR, Contrast media - Sagittal T1 TSE SPIR, axial oblique T1 TSE SPIR, and coronal oblique T1 TSE SPIR. Focus on MRI Pelvis perianal fistula, namely the presence of fluid, then use the T2 sequence to visualize the fluid image to become hyper-intense so that you can see fluid in the perianal abscess and perianal fistula Figure 4

The contrast media used in Pelvic MRI examination of perianal fistulas at the Radiology Department of Mayapada Hospital, South Jakarta, is contrast media with a gadoteric acid concentration of 0.5 mmol/ml (Braun et al., 2020; GE Health Care, 2017; Moon et al., 2021). The standard volume of contrast media used to visualize perianal abscesses and fistulas properly is around 10 ml, using an injector or manually assisted by a radiologist to inject contrast media. The purpose of contrast medium application is to visualize any active

inflammation that can be seen in a fistula. By injection appropriate contrast medium through the vein, the images of inflammation in the fistula is clearly enhanced, so the blood flow is high contrast in the fistula as shown in Figure 5 and Figure 6. Only in old perianal fistulas, the inflammation does not appear active.

Pelvic MRI examination techniques for perianal fistulas at the Radiology Department of Mayapada Hospital in South Jakarta mostly follow the theory. Starting with installing a vitamin E marker using the anal clock method on the boil area. If there is more than one boil, then the marker follows. Marker images on the T2 and T1 sequences will appear hyper-intense with a firm shape. But when using the SPIR sequence, the marker is not visualized because of fat suppression (fat suppression) Figure 6. According to the theory (Westbrook, 2013; Westbrook & Talbot, 2019), only using three planar T2W TSE sequences and three planar T2 TSE SPIR (sagittal, axial oblique, and coronal oblique) is sufficient to image abnormalities in perianal abscesses, but at Mayapada Hospital is necessary to add contrast medium to see whether inflammation in perianal fistulas is still new or old. What can be seen in the T1 TSE SPIR sequence are three planar (sagittal, axial oblique, and coronal oblique) if the fistula is new, the picture of the inflammation in the fistula clearly shows hyper-intense enhancement.

4. CONCLUSION

Based on the results of research conducted to analyze Pelvic MRI examination techniques for perianal fistulas at the Radiology Department of Mayapada Hospital, it was concluded that the pelvic MRI examination techniques for perianal fistulas are in accordance with several recent journals to produce informative images. The vitamin E as a marker was very helpful in visualizing the images of the perianal fistula on the surface of the skin, and it makes it easier for the radiologist to see the path of the perianal fistula Pelvic. MRI images of perianal fistulas show clear boundaries of perianal fistulas with the anal organs, sigmoid colon, bladder, and prostate between one organ and another. Better image are generated from the selection T2 TSE SPIR sequence to visualize fluid images to become hyper-intensive by suppressing fat signals so that only fluid is visible in the perianal abscess and fistula images.

REFERENCES

- Amarprakash, D., Zishan, A., Mayur, P., Nisha, T., Bibek, M., & Shivraj, N. (2022). Management of high anal complex Fistula by modified Kshar Sutra therapy. *International Journal of Health Sciences*, 13, 3341–3350. <https://doi.org/10.53730/ijhs.v6ns4.9565>
- Amato, A., Bottini, C., De Nardi, P., Giamundo, P., Lauretta, A., Realis Luc, A., & Piloni, V. (2020). Evaluation and management of perianal abscess and anal fistula: SICCR position statement. *Techniques in Coloproctology*, 24(2), 127–143. <https://doi.org/10.1007/s10151-019-02144-1>
- Braun, J., Busse, R., Darmon-Kern, E., Heine, O., Auer, J., Meyl, T., Maurer, M., Hamm, B., & de Bucourt, M. (2020). Baseline characteristics, diagnostic efficacy, and per-examinational safety of IV gadoteric acid MRI in 148,489 patients. *Acta Radiologica*, 61(7), 910–920. <https://doi.org/10.1177/0284185119883390>
- Cerit, M. N., Öner, A. Y., Yıldız, A., Cindil, E., Şendur, H. N., & Leventoğlu, S. (2020). Perianal fistula mapping at 3 T: volumetric versus conventional MRI sequences. *Clinical Radiology*, 75(7), 563.e1-563.e9. <https://doi.org/10.1016/j.crad.2020.03.034>
- Chen, I. E., Ferraro, R., Chow, L., & Bahrami, S. (2021). Guided tour of hidden tracts in the pelvis: exploring pelvic fistulas. *Archives of Gynecology and Obstetrics*, 304(4), 863–871. <https://doi.org/10.1007/s00404-021-06144-1>

- Criado, J. de M., del Salto, L. G., Rivas, P. F., del Hoyo, L. F. A., Velasco, L. G., Isabel Díez Pérez de las Vacas, M., Marco Sanz, A. G., Paradela, M. M., & Moreno, E. F. (2018). MR imaging evaluation of perianal fistulas: Spectrum of imaging features. *Radiographics*, *32*(1), 175–194. <https://doi.org/10.1148/rg.321115040>
- Das, G. C., & Chakrabarty, D. K. (2021). Best non-contrast magnetic resonance imaging sequence and role of intravenous contrast administration in evaluation of perianal fistula with surgical correlation. *Abdominal Radiology*, *46*(2), 469–475. <https://doi.org/10.1007/s00261-020-02616-1>
- Delfaut, E. M., Beltran, J., Johnson, G., Rousseau, J., Marchandise, X., & Cotten, A. (1999). Fat suppression in MR imaging: Techniques and pitfalls. *Radiographics*, *19*(2), 373–382. <https://doi.org/10.1148/radiographics.19.2.g99mr03373>
- Deprest, J., Page, A.-S., Wolthuis, A., & Housmans, S. (2021). Laparoscopic Pelvic Floor Surgery. In *Pelvic Floor Disorders*. https://doi.org/10.1007/978-3-030-40862-6_56
- GE Health Care. (2017). *Gadoteric Acid*. GE Healthcare AS. <https://www.gehealthcare.in/-/jssmedia/gehc/in/images/products/contrast-media/clariscan-pi.pdf?rev=1&hash=11CCB6CC88CE8582BA3F1DAF37160C5A>
- Halligan, S. (2020). Magnetic Resonance Imaging of Fistula-In-Ano. *Magnetic Resonance Imaging Clinics of North America*, *28*(1), 141–151. <https://doi.org/10.1016/j.mric.2019.09.006>
- Ho, E., Rickard, M. J. F. X., Suen, M., Keshava, A., Kwik, C., Ong, Y. Y., & Yang, J. (2019). Perianal sepsis: surgical perspective and practical MRI reporting for radiologists. *Abdominal Radiology*, *44*(5), 1744–1755. <https://doi.org/10.1007/s00261-019-01920-9>
- Hokkanen, S. R. K., Boxall, N., Khalid, J. M., Bennett, D., & Patel, H. (2019). Prevalence of anal fistula in the United Kingdom. *World Journal of Clinical Cases*, *7*(14), 1795–1804. <https://doi.org/10.12998/wjcc.v7.i14.1795>
- Hyde, B. J., Byrnes, J. N., Occhino, J. A., Sheedy, S. P., & VanBuren, W. M. (2018). MRI review of female pelvic fistulizing disease. *Journal of Magnetic Resonance Imaging*, *48*(5), 1172–1184. <https://doi.org/10.1002/jmri.26248>
- Kakani, S. S., Dahiphale, D. B., Padiya, S. G., Dugad, V. G., Pole, S. M., & Poddar, T. A. (2021). Role of magnetic resonance imaging in diagnosis and grading of perianal fistulas. *Asian Journal of Medical Sciences*, *12*(12), 140–146. <https://doi.org/10.3126/ajms.v12i12.39695>
- Konan, A., Onur, M. R., & Özmen, M. N. (2018). The contribution of preoperative MRI to the surgical management of anal fistulas. *Diagnostic and Interventional Radiology*, *24*(6), 321–327. <https://doi.org/10.5152/dir.2018.18340>
- Lee, M. J., Parker, C. E., Taylor, S. R., Guizzetti, L., Feagan, B. G., Lobo, A. J., & Jairath, V. (2018). Efficacy of Medical Therapies for Fistulizing Crohn's Disease: Systematic Review and Meta-analysis. *Clinical Gastroenterology and Hepatology*, *16*(12), 1879–1892. <https://doi.org/10.1016/j.cgh.2018.01.030>
- Madany, A. H., Murad, A. F., Kabbash, M. M., & Ahmed, H. M. (2023). Magnetic resonance imaging in the workup of patients with perianal fistulas. *Egyptian Journal of Radiology and Nuclear Medicine*, *54*(1). <https://doi.org/10.1186/s43055-023-00975-5>
- McRobbie, D. W., Moore, E. A., & Graves, M. J. (2017). MRI from picture to proton. In *MRI from Picture to Proton*. <https://doi.org/10.2214/ajr.182.3.1820592>
- Molteni, R. de A., Bonin, E. A., Baldin Júnior, A., Barreto, R. A. Y., Brenner, A. S., Lopes, T. L., Volpato, A. P. D. J., & Sartor, M. C. (2018). Usefulness of endoscopic ultrasound for perianal fistula in crohn's disease. *Revista Do Colegio Brasileiro de Cirurgioes*, *45*(6), 1–10. <https://doi.org/10.1590/0100-6991e-20181840>
- Moon, W. J., Cho, Y. A., Hahn, S., Son, H. M., Woo, S. K., & Lee, Y. H. (2021). The Pattern of Use, Effectiveness, and Safety of Gadoteric Acid (Clariscan) in Patients Undergoing

- Contrast-Enhanced Magnetic Resonance Imaging: A Prospective, Multicenter, Observational Study. *Contrast Media and Molecular Imaging*, 2021(March 2013). <https://doi.org/10.1155/2021/4764348>
- Murphy, A. (2020). *Fat suppressed imaging*. TREN MD. Retrieved from <https://radiopaedia.org/articles/fat-suppressed-imaging>
- Sarda, H., Pandey, A., Regmi, S., & Masood, S. (2022). Magnetic resonance imaging for fistulography in perianal fistula: clinicoradiological correlation. *International Surgery Journal*, 9(9), 1553. <https://doi.org/10.18203/2349-2902.isj20222094>
- Sarma, A. D. (2019). Role of MRI in Perianal Fistulas. *JASC : Journal of Applied Science and Computations*, VI(V1), 2493–2506.
- Shahzad, M., Anjum, N., Siraj, S., Omer, M., Shabbir, R., & Masood, A. (2021). Effectiveness of Radiological Imaging Techniques (X-Rays, Mdt, and Mri) for Diagnosis of Pelvic Fistula: a Systematic Review. *Biological and Clinical Sciences Research Journal*, 2021(1), 1–7. <https://doi.org/10.54112/bcsrj.v2021i1.62>
- Sharma, A., Yadav, P., Sahu, M., & Verma, A. (2020). Current imaging techniques for evaluation of fistula in ano: a review. *Egyptian Journal of Radiology and Nuclear Medicine*, 51(1). <https://doi.org/10.1186/s43055-020-00252-9>
- Sharma, U. K., Thapaliya, S., Pokhrel, A., Shrestha, M. B., Baskota, B. D., Thapa, D. K., & Rai, U. (2022). MR Imaging Evaluation of Perianal fistulae. *Medical Journal of Eastern Nepal*, 1(1), 1–6. <https://doi.org/10.3126/mjen.v1i1.45853>
- Singh, A., Kaur, G., Singh, J. I., & Singh, G. (2022). Role of Transcutaneous Perianal Ultrasonography in Evaluation of Perianal Fistulae with MRI Correlation. *Indian Journal of Radiology and Imaging*, 32(1), 51–61. <https://doi.org/10.1055/s-0042-1743111>
- Westbrook, C. (2013). *Handbook of MRI Technique* (Third Edit). Willey Blackwell.
- Westbrook, C., & Talbot, J. (2019). *MRI in Practice*. John Wiley & Sons.
- Wahyuningtiyas, I. M., & Apriantoro, N. H. (2020). Perbedaan Informasi Citra Anatomi Lumbal Sequence T2 Fat Suppression Antara Metode SPAIR dan Dixon. *2-TRIK: TUNAS-TUNAS Riset Kesehatan*, 10(4), 289-294. Retrieved from <http://2trik.jurnalelektronik.com/index.php/2trik/article/view/2trik10412>
- Włodarczyk, M., Włodarczyk, J., Sobolewska-Włodarczyk, A., Trzeciński, R., Dziki, Ł., & Fichna, J. (2021). Current concepts in the pathogenesis of cryptoglandular perianal fistula. *Journal of International Medical Research*, 49(2). <https://doi.org/10.1177/0300060520986669>