



Review – Prostate Cancer

MR-Guided Biopsy of the Prostate: An Overview of Techniques and a Systematic Review

Kirsten M. Pondman^a, Jurgen J. Fütterer^{b,c,*}, Bennie ten Haken^a, Leo J. Schultze Kool^c, J. Alfred Witjes^d, Thomas Hambroek^b, Katarzyna J. Macura^e, Jelle O. Barentsz^b

^a Department of BME and the Faculty of Science and Technology, University of Twente, Enschede, The Netherlands

^b Department of Radiology, Radboud University, Nijmegen Medical Centre, Geert Grooteplein zuid 10, NL 6500 HB, Nijmegen, The Netherlands

^c Department of Interventional Radiology, Radboud University, Nijmegen Medical Centre, Geert Grooteplein zuid 10, NL 6500 HB, Nijmegen, The Netherlands

^d Department of Urology, Radboud University, Nijmegen Medical Centre, Geert Grooteplein zuid 10, NL 6500 HB, Nijmegen, The Netherlands

^e The Russell H. Morgan Department of Radiology and Radiological Science, Johns Hopkins Medical Institutions, Baltimore, United States

Article info

Article history:

Accepted June 3, 2008

Published online ahead of print on June 12, 2008

Keywords:

Prostate cancer

Biopsy

Magnetic resonance

Abstract

Context: Systematic transrectal ultrasound-guided biopsy (TRUSBx) is the gold standard for detecting prostate cancer. This systematic approach is characterized by low sensitivity (39–52%) and high specificity (81–82%). Magnetic resonance (MR)-guided biopsy techniques are becoming more and more available, but there is no current consensus on the optimal technique.

Objective: This review presents an overview of MR-guided biopsy techniques for prostate cancer detection.

Evidence acquisition: Current literature was reviewed regarding MR-guided biopsy for prostate cancer detection. A literature search was performed using the commercially available MedLine online search engine. Combinations of the following search and Medical Subject Headings terms were applied to retrieve relevant articles: “magnetic resonance,” “prostatic neoplasms,” and “biopsy.” Review articles and studies describing techniques other than MR-guided biopsy were excluded.

Evidence synthesis: Biopsy of the prostate is an essential procedure for determining optimal treatment. Systematic TRUSBx is the gold standard, but it fails to detect numerous tumors. Diagnostic MR imaging provides more accurate selection of regions in which tumors are suspected. Using these diagnostic images during an MR-directed biopsy procedure improves quality of the biopsy. In open MR scanners, the prebiopsy images often must be registered to the real-time biopsy images because open MR scanners do not provide optimal tissue contrast; thus, the patient must first be examined in a closed MR scanner and then biopsied in an open scanner. The advantage of open MR over closed MR is that the physician has easy patient access. With special equipment, prostate MR-guided biopsy is also possible in a closed system. Closed MR scanners can be used for the prebiopsy scan as well as for the biopsy procedure.

Conclusions: The combination of a diagnostic MR examination and MR-guided biopsy is a promising tool and may be used in patients with previous negative TRUSBx.

© 2008 European Association of Urology. Published by Elsevier B.V. All rights reserved.

* Corresponding author. Tel. +31 24 3614545; Fax: +31 24 3540866.

E-mail address: J.Futterer@rad.umcn.nl (J.J. Fütterer).

1. Introduction

Prostate cancer is the most frequently diagnosed form of noncutaneous cancer in men [1]. Incidence increased dramatically after the introduction of the prostate-specific antigen (PSA) test [2,3]. Unfortunately, urologists face the dilemma of patients with elevated and/or rising PSA levels and negative biopsy results. Because the serum PSA level, used for early diagnosis of prostate cancer, is a very sensitive but unspecific test, other tests are necessary to diagnose prostate cancer. Transrectal ultrasound (TRUS) was introduced in 1968 as a means for diagnostic imaging of prostate cancer [4]. The sensitivity of this technique for prostate cancer detection is low (20–30% [5]) because more than 40% of prostate tumors are isoechoic and only the peripheral zone can be accurately detected [6,7]. TRUS Doppler and application of contrast agents increased the detection rate of prostate cancer to 74–98% [8–12].

Over 1.2 million prostate needle biopsies are executed every year in the United States [13]. Systematic TRUS-guided biopsy (TRUSBx) is the gold standard for detecting prostate cancer. This systematic approach is characterized by low sensitivity (39–52%) and high specificity (81–82%) [14]. In case of doubt, additional biopsy sessions are performed. In some cases, the systematic protocol is extended with additional biopsies targeting hypoechoic regions detected by TRUS, which increases the detection rate slightly [4].

The role of magnetic resonance imaging (MRI) in the detection of prostate cancer is increasing but profoundly debated [15]. Anatomical T2-weighted MRI has been disappointing in detecting and localizing prostate cancer. Estimates of the sensitivity of MRI for the detection of prostate cancer using T2-weighted sequences and endorectal coils vary from 60% to 96% [16]. Several groups have convincingly shown that dynamic contrast enhancement and spectroscopy each improve detection and that the sensitivity of MRI is comparable to and may exceed that of transrectal biopsy [16]. Various MRI techniques, such as proton magnetic resonance (MR) spectroscopy and dynamic contrast-enhanced MRI, have been applied for more accurate detection, localization, and staging of prostate cancer [17]. A recent study showed an area under the receiver operating curve of 0.67–0.69 for localizing prostate with regular 1.5 T anatomical MRI [17]. The localization accuracy increased to 0.80 and 0.91 using spectroscopic MRI and by applying contrast agent, respectively [17]. Diffusion-weighted MRI is increasingly used, which may lead to increased detection rates [18–20].

MR-guided biopsy techniques are becoming more and more available, but there is no current consensus on the optimal technique [21–23]. Open and closed MRI settings are used in tandem. Several different types of biopsy robots [24], some with complex software, are used to guide the needle. Target regions are determined using combinations of different MRI techniques. Some physicians use a transrectal approach, whereas others prefer a transperineal methodology. Movement of the prostate during the biopsy procedure is one of the biggest challenges in taking biopsies of the prostate [25]. Several solutions for this problem have been suggested, from fixation using needles to rendering real-time images [26].

Several MR-guided prostate biopsy approaches have been investigated, but thus far, there is no consensus for this technique. The purpose of this study is to summarize current technical and clinical applications of MR-guided biopsies of the prostate.

2. Methods

On April 4, 2008, a literature search was performed using the commercially available MedLine (WebSPIRS v. 5.12, Build 20060224, Ovid Technologies) online search engine. Combinations of the following search and Medical Subject Headings terms were applied to retrieve relevant articles: “magnetic resonance,” “prostatic neoplasms,” and “biopsy.” Review articles and studies describing techniques other than MR-guided biopsy were excluded. All other on-topic studies written in the English language were included in this review.

2.1. Robotics

Robotics is a new field in medicine due to stringent safety criteria. Robots are most often used in minimally invasive procedures, such as cardiac, bladder, prostate, and neurosurgery.

Using MRI for guiding a robot causes several additional problems: patient access is limited, and MR compatibility is very important. The robot may not interfere with the images obtained using the MR scanner. For this reason, ferromagnetic and electronic devices cannot be used inside the magnet. Furthermore, the robot must be registered to the MR images using a coordinate system to be able to target anatomical areas.

These challenges exclude manual and traditional electro-mechanical robot handling of the biopsy needle. Therefore, numerous new methods and devices have been developed including real-time, in-scanner guidance methods to operate the devices.

2.2. MR-guided biopsy in an open bore

Open-bore MR scanners simultaneously allow patient access and near-real-time MRI. Unfortunately, open MR scanners are known for a low signal-to-noise ratio related to low field

Table 1 – Summary of MR-guided biopsy systems

Researcher	D'Amico et al [22] Hata et al [27]	Zangos et al [28]	Haker et al [29]	Fichtinger et al [30]	Beyersdorf et al [21] Engelhard et al [31] Anastasiadis et al [32]	Krieger et al [34] Susil et al [35]	DiMaio et al [29,36]	Zangos et al [37]
MR system	Open	Open	Open	Closed	Closed	Closed	Closed	Closed
Biopsy device	Needle template	Needle guidance without device	Robotic assistant mounted above surgeon's head	Manually powered robotic arm	Manually powered robotic arm	Mechanical robotic arm	Mechanical robot	C-arm
Clinical experience	Transperineal Patients	Transgluteal 25 patients	Transperineal Patients	Transrectal Canine and phantom	Transrectal 12 patients, 37 patients, 27 patients	Transrectal 4 patients 3 patients	Transperineal Phantom	Transgluteal Cadaver
Number of cores	6 8	–	–	–	6–9 4–9 2–8	– 5	–	–
Time required	–	–	–	–	55 min 2 hours	– 76 min	–	–
Anesthesia	local	–	–	–	No	No	–	–
Positive	<ul style="list-style-type: none"> ◦ Easy to use ◦ Can be used for patients who have undergone rectal surgeries 	<ul style="list-style-type: none"> ◦ Needle can be seen in real time on images ◦ Easy patient access 	<ul style="list-style-type: none"> ◦ Positions calculated by computer ◦ Easy patient access 	<ul style="list-style-type: none"> ◦ Automatic actuation of the device using software and robot with 3 df 	<ul style="list-style-type: none"> ◦ Entire device visible on images 	<ul style="list-style-type: none"> ◦ Two needle paths, for distal and proximal biopsies ◦ Adjustments and insertion depth calculated by software ◦ Operator positions the robot from outside the scanner 	<ul style="list-style-type: none"> ◦ More relaxing position ◦ Needle can be adjusted without physical interaction of a physician 	<ul style="list-style-type: none"> ◦ Minimize the risk of injury to the bladder, bowel, and iliac vessels ◦ No intestinal germs are introduced into the prostate
Negative	<ul style="list-style-type: none"> ◦ Low resolution (needle can only be placed where there is a hole in the template) 	<ul style="list-style-type: none"> ◦ Low-resolution images; tumor not visible ◦ No guidance for needle ◦ High-resolution images have to be rendered 	<ul style="list-style-type: none"> ◦ Low resolution on open MR system ◦ High-resolution images have to be rendered 	<ul style="list-style-type: none"> ◦ Patient has to be withdrawn from the scanner to perform the biopsy 	<ul style="list-style-type: none"> ◦ Patient has to be withdrawn from scanner to adjust the position of the needle guide and to perform the biopsy ◦ Calculations of adjustments have to be done by the physician. 	<ul style="list-style-type: none"> ◦ Patient has to be withdrawn from the scanner to perform the biopsy 	<ul style="list-style-type: none"> ◦ Only 2 df, no rotation possible ◦ Not tested on patients 	<ul style="list-style-type: none"> ◦ Local or general anesthesia needed ◦ Longer biopsy pathway ◦ Patient has to be withdrawn from the scanner to perform the biopsy

strength (typically 0.5 T). The result is image quality that is too low to adequately localize tumors. To reliably identify the target regions, 1.5 T images must be obtained prior to the biopsy procedure by means of a closed-bore scanner.

One of the first devices for needle placement was used by D'Amico et al [22] in a 0.5 T open MR system with a patient who had undergone proctocolectomy (Table 1). The researchers performed a sextant biopsy with a needle grid with holes placed against the perineum. This transperineal approach is ideal for patients who have undergone rectal surgeries; however, this approach is more invasive than the conventional transrectal approach and requires general or regional anesthesia [27].

Hata et al [27] also used a needle-guidance template with holes spaced 5 mm apart in an open MR system for a targeted biopsy (Table 1). The template was registered to the MR scanner using an optical tracking system. Utilizing planning software, a hole was selected that would guide the biopsy needle through the perineum into the target. Images were obtained during the insertion of the needle to confirm the position of the needle and suspicious regions.

Zangos et al [28] used a 0.2 T open MR scanner for real-time needle tracking to perform transgluteal prostate biopsies on 25 patients (Table 1). The tumors were not visible during the intervention on the T1-weighted 0.2 T images, so the data had to be extracted from previously obtained 1.5 T images to find the target locations. The point of insertion was marked by taping a marker or by using a finger as an external marker during imaging.

Haker et al [29] used an interventional MR system to perform transperineal biopsies. The images were obtained with a 0.5 T interventional open magnet. The researchers developed an MR-compatible robotic assistant mounted above the surgeon's head. Two long, rigid arms formed a parallel linkage for manipulating the needle-holder guide. The device was coupled with planning and tracking software. Optical sensors measured the displacement of each motion stage. All coordinates were computed and automatically used to position the needle guide. When the guide was in position, the physician manually inserted the needle.

2.3. MR-guided biopsy in a closed bore

Fichtinger et al [30] developed a transrectal prostate biopsy device that can be used inside a conventionally used, open MR scanner. The patient lay in prone position, and a sheath was introduced in the rectum; the needle-guidance device can slide into the sheath. To guide the device, microcoil antennas wound around small capsules containing gadolinium solvent were used as active fiducials. The positions were used as rigid body markers on the device to calculate the exact orientation of the entire device. The needle-guiding device had 3 degrees of freedom (df); motion, translation, and rotation of the end-effector inside the rectum. The images were obtained in continuous mode. The computer calculated the motion parameters constantly, enabling real-time dynamic control. The motion stages are currently powered manually, but they may be motorized in the future.

An MR-compatible biopsy device used in clinical practice was used by Beyersdorff et al [21] (Fig. 1). A needle guide was inserted into the rectum and connected to this device. The



Fig. 1 – Biopsy device with base plate and cushion for patient positioning (Invivo, Schwerin, Germany).

device enables rotation, angulation, and translation of the needle. This guide contains no active fiducial coils, but the needle guide is visible on both T1- and T2-weighted MR images. A fast imaging method was used to detect the position of the needle guide. Beyersdorff et al [21] performed MR-guided biopsies with this device on 12 patients with elevated PSA levels and a previous negative TRUSx round (Fig. 2). In seven of these patients, the suspicious regions could be defined with the fast sequence; in the other five cases, the areas of interest were clearly visible in the prebiopsy images and could be marked on the images obtained during biopsy. Positioning the needle guide was time consuming. The guide must first be identified on a localizer image; then, to adjust the position of the device, the patient has to be slid in and out of the scanner. After repositioning of the needle guide, MR images in two perpendicular planes must be obtained to direct the guide to the target. Prostate cancer was detected in 5 of the 12 patients (42%).

Engelhard et al [31] used a similar and modified device in a study with 37 patients who had previous negative prostate biopsies. The researchers concluded that suspicious lesions with a diameter of ≥ 10 mm could be successfully punctured using this device. Prostate cancer was detected in 14 of 37 patients (38%). In a study of 27 patients with previous negative TRUSx, Anastasiadis et al [32] also used this device and found prostate cancer in 15 (55.5%) patients (Table 1). The detection rates after one negative biopsy round ranged between 38% and 55.5% [21,31,32]; these data are promising and demonstrate the potential clinical value of MR-guided biopsies. In the second TRUSx round, only 15% to 20% of prostate cancers will be detected; in the third biopsy round, only 8% will be detected [33].

The transrectal needle-guide system, called APT-MRI (standing for “access to prostate tissue under MRI guidance”) was developed by Krieger et al [34] and Susil et al [35]. It can be utilized in closed-bore 3 T magnets with patients in prone position. The needle placement device is, to some extent, similar to the device used by Beyersdorff et al [21] and Fichtinger et al [30]. The APT-MRI device incorporates an

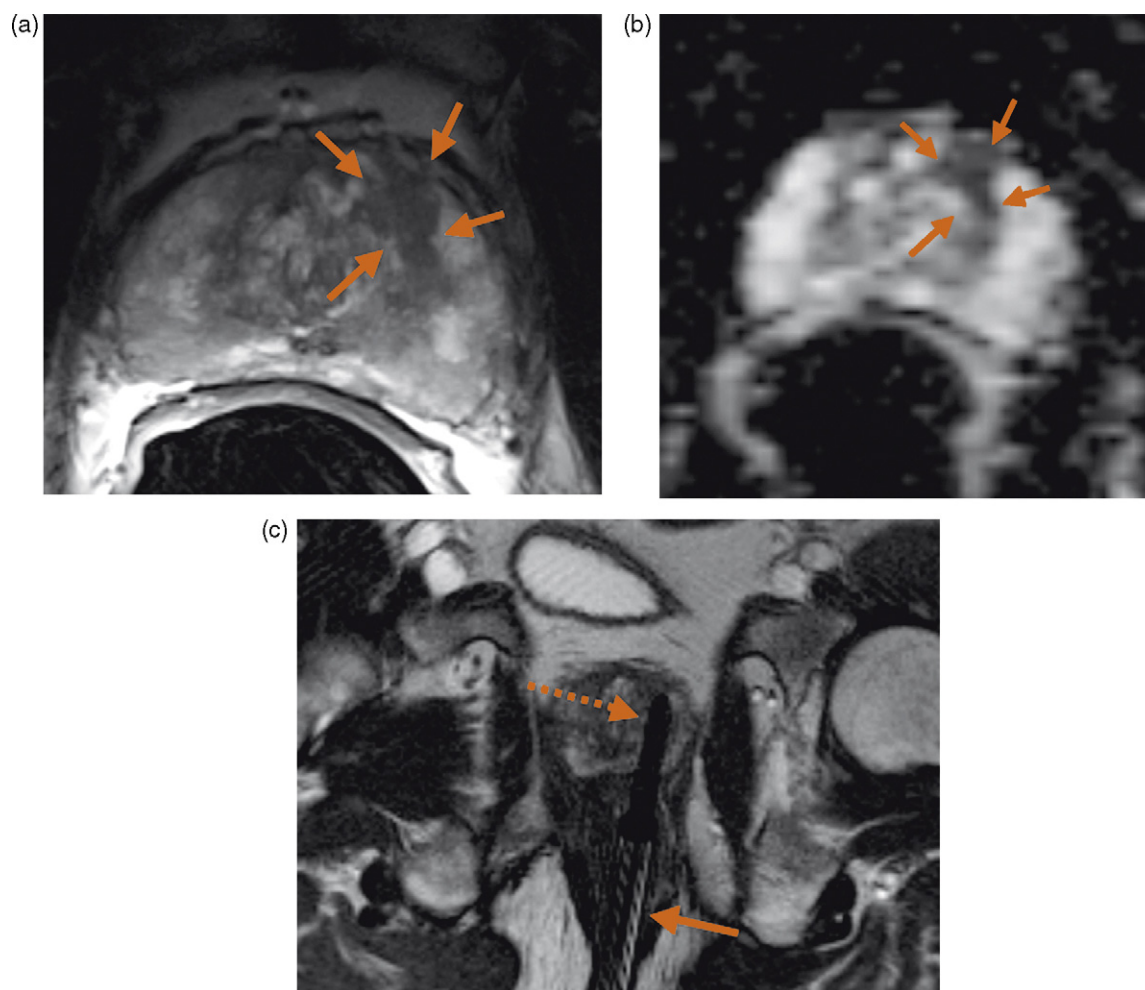


Fig. 2 – A 64-year-old male with elevated PSA level (14 ng/ml) and two negative TRUSBx sessions underwent MRI of the prostate and subsequent MR-guided biopsy: (a) axial T2-weighted MR image shows the presence of a suspicious area of low signal intensity (arrows) in the left central gland; (b) ADC map at the same level shows a significant reduction in ADC (arrows); (c) coronal T2-weighted MRI related to a biopsy (dotted arrow) of this area that was taken under MR guidance (arrow) and corresponded with prostate cancer (Gleason 4+3). Axial MR images could be obtained to show the needle tip in the area suspected for tumors (see Fig. 2a and b).

endorectal imaging coil and a hybrid tracking method that is composed of passive fiducial marker tracking and MR-compatible fiber optic joint encoders. Coordinates for the position of the interventional device in the scanner are obtained from MR images by segmenting gadolinium fiducial marker tubes incorporated into the main axis of the device and two marker tubes placed in line with the needle channel. Thin slabs of 1-mm isotropic, sagittal, proton-density-weighted TSE images in the plane of the markers are obtained. Automatic segmentation of the markers is achieved using custom targeting software, which reformats the sagittal images into the axial plane along the main axis of the interventional device and along the needle axis. The 3 df available to reach a target include rotation of the endorectal probe, pitch (angle) of the needle, and insertion depth of the needle. The targeting software provides necessary guiding parameters that are controlled through the manual adjustments of dials on the device (Fig. 3). Commercially available

MR-compatible core biopsy needles can be utilized with the APT-MRI device. In three biopsy procedures performed by Susil et al, the mean biopsy needle placement accuracy was 1.8 mm (range 0.4–4.0 mm) [34,35]. Using this device in a study with 13 patients with at least one previous negative prostate biopsy within the previous 12 months, Singh et al [20] found only one patient with a directed biopsy positive for prostate cancer.

DiMaio et al [29,36] and Fischer et al [23] designed a robotic manipulator to perform transperineal biopsies with the patient in supine position. This position may be more relaxing for the patient compared to the more commonly used prone position. The device consists of a visualization, planning, and navigation engine and a needle placement robot. This robot can be adjusted using pneumatic actuators. Position information is provided by passive tracking fiducials on the robot base. The system has proven to be MRI compatible. In free space, the localization accuracy of the needle tip is 0.25 mm and 0.5 mm.



Fig. 3 – APT-MRI device for transrectal prostate biopsy. Note the endorectal probe (black arrow), needle guide (arrowhead), and rotation and angle dials (white arrow) that are controlled manually based on output from the targeting software.

Zangos et al [37] used a device for transgluteal biopsies in a closed-bore system. Transgluteal biopsies minimize the risk of injury to the bladder, bowel, and iliac vessels, and no intestinal germs are introduced into the prostate. Disadvantages of this method are the need for local or general anesthesia and the longer biopsy pathway. The device uses markers on the hydrolic guiding arm, and a system cart to control the drives and optical sensors. Interactive Innomotion software is used for planning and for controlling the biopsy. This device was used in a cadaver study, in which the cadaver was placed in a prone or lateral position. The insertion point and target were marked on T2-weighted MR images, and the biopsy path was calculated automatically. The needle was inserted manually by the physician after the cadaver was removed from the scanner. The mean deviation of the needle tip was 0.35 mm (range 0.08–1.08 mm). In all cases, the target was reached on the initial attempt. This technique has not been used in clinical practice.

As mentioned above, prostate immobilization is a problem that affects targeting accuracy. Transrectal approaches seem to have some difficulty with prostate movement. The transrectal prostate biopsy devices used by Fichtinger et al [30] and by Krieger et al [34] were modified to account for this problem. The device used by Beyersdorff et al [21] is an MRI-compatible needle guide used for prostate biopsy. This device has been described as having problems with prostate motion during biopsy; however, the needle guide can be used to immobilize the prostate.

3. Discussion

MR-guided prostate biopsies will have an increasing role in diagnosing prostate cancer, and there is an important task for robotics. Extensive clinical studies are essential to review the value of MR-compatible robots. One of the largest challenges in taking biopsies of the prostate still is the correction for movements of the prostate tissue during the biopsy procedure. Research is needed to design and evaluate techniques for determining and reducing these motions. Lattouf et al [38] evaluated 26 patients to understand whether the use of endorectal MRI before TRUSx of the prostate increased the yield of cancer diagnoses in a high-risk population. They found that MRI before TRUSx tended to yield more cancer diagnoses, but the difference was not statistically significant. Reasons for this finding might include suboptimal localization of the MRI findings and the biopsy location. Real-time TRUS and MRI fusion-guided biopsy is proposed as a method for using the high-contrast-sensitive MR data to detect the tumor and the real-time character of TRUS to follow the motions of the prostate during biopsy [39,40].

The techniques used for biopsies can also be used for treatment of prostate cancer, such as with brachytherapy. In this case, accurate placement of seeds is very important to provide accurate dosage coverage; however, only a few reports are available with preliminary data. A study by Singh shows promising results in three patients with seed-implantation using MR data fused with computer-assisted tomography (CT) data for treatment planning [41]. Future studies should investigate the role of robot-guided treatment.

Robotic assistance for MR-guided interventions with the prostate in closed-bore, 3 T magnets has been investigated by researchers in the URobotics Laboratory, Department of Urology, at Johns Hopkins University, led by Dr Dan Stoianovici. The MR-compatible robotic device (MrBot; Fig. 4) uses a pneumatic-optical actuation and sensing mechanism and a pneumatic motor (PneuStep) [42]. The motor is completely decoupled from magnetism and electromagnetism because it is entirely constructed of nonmagnetic and dielectric components [42]. Pneumatic actuation is a perfect option for MRI compatibility as well as for achieving very high precision and reproducibility in accessing the target [43]. The robot tested with impressive accuracy for image-guided needle targeting in mock-up, ex vivo, and animal experiments [44]. Currently, a new holder is being developed for the robot to handle biopsy needles for transperineal access to the

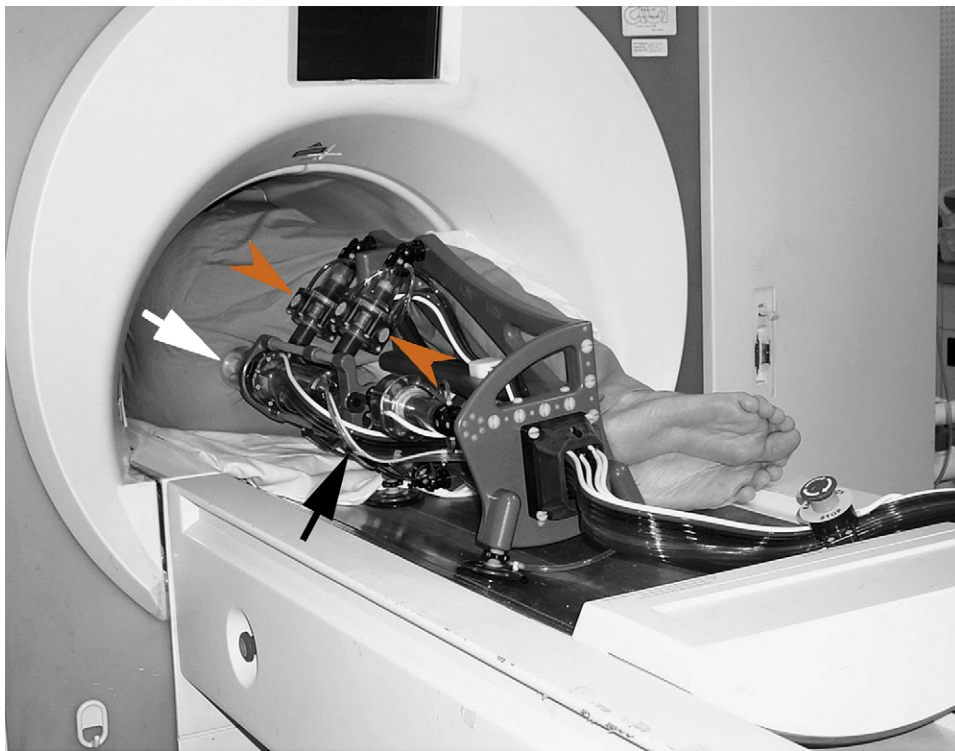

Fig. 4 – MrBot (black arrow) aligned with the patient in decubitus position. Pneumatic stepper motors (arrowheads) orient the end effector for transperineal intervention (white arrow) based on output from the guiding software. Courtesy of D. Stoianovici.

prostate. The robot mounts on the imager's table alongside the patient, who is placed in the decubitus position, and it is capable of orienting and operating a biopsy needle under direct MRI guidance (Fig. 4). The T2-weighted TSE sequence data transferred from the imager are used by custom software to define the targets and the entry points for the needle on the three-dimensional coordinate system of the MR image. The same software is used to calculate the coordinates for the respective positions in the coordinate system of the robot to guide the robot in performing automated, target-centered needle placements.

4. Conclusion

Biopsy of the prostate is an essential procedure for determining optimal treatment. Systematic TRUSBx is the gold standard, but it fails to detect numerous tumors. Diagnostic MRI provides a more accurate selection of regions in which tumors are suspected. Using these diagnostic images during an MR-directed biopsy procedure improves the quality of the biopsy. In open MR scanners, the prebiopsy images often must be registered to the real-time biopsy images because open MR scanners do not

provide optimal tissue contrast; thus, the patient must first be examined in a closed MR scanner, and then biopsied in an open scanner. The advantage of open MR over closed MR is that a physician has patient access. Closed MR scanners can be used for the prebiopsy scan as well as for the biopsy procedure.

A variety of MR-compatible robots have been developed. Most robots have a manual positioning system, which means that the patient has to be removed from the scanner in order to correct the position. Mechanically powered robots can be adjusted from outside the scanner. Needle insertion has to be executed manually in all investigated robots. Unfortunately, little is known about the accuracy of the robots.

The MR detection rates after one negative biopsy round using MR-guided biopsy ranged between 38% and 55.5%. The clinical value of MR-guided prostate biopsy lies in the fact that a high percentage of prostate cancers can be depicted using an MR-targeted biopsy technique, eliminating unnecessary systematic prostate biopsies for patients with elevated PSA levels and repeated tumor-negative TRUSBx.

In conclusion, the combination of a diagnostic MR examination and MR-guided biopsy is a promising

tool that may be used in patients with previous negative TRUSbx.

Author contributions: Jurgen J. Fütterer had full access to all the data in the study and takes responsibility for the integrity of the data and the accuracy of the data analysis.

Study concept and design: Pondman, Fütterer, Barentsz.

Acquisition of data: Pondman, Fütterer.

Analysis and interpretation of data: Pondman.

Drafting of the manuscript: Pondman, Fütterer, ten Haken, Witjes, Schultze Kool, Barentsz.

Critical revision of the manuscript for important intellectual content: Pondman, Fütterer, ten Haken, Witjes, Schultze Kool, Barentsz.

Statistical analysis: none.

Obtaining funding: none.

Administrative, technical, or material support: none

Supervision: Fütterer.

Other (specify): none.

Financial disclosures: I certify that all conflicts of interest, including specific financial interests and relationships and affiliations relevant to the subject matter or materials discussed in the manuscript (eg, employment/ affiliation, grants or funding, consultancies, honoraria, stock ownership or options, expert testimony, royalties, or patents filed, received, or pending), are the following: none.

Funding/Support and role of the sponsor: none.

References

- [1] Jemal A, Siegel R, Ward E, Murray T, Xu J, Thun MJ. Cancer statistics, 2007. *CA Cancer J Clin* 2007;57:43-66.
- [2] Barry MJ. Clinical practice. Prostate-specific-antigen testing for early diagnosis of prostate cancer. *N Engl J Med* 2001;344:1373-7.
- [3] Frankel S, Smith GD, Donovan J, Neal D. Screening for prostate cancer. *Lancet* 2003;361:1122-8.
- [4] Heijmink SW, van Moerkerk H, Kiemeny LA, Witjes JA, Frauscher F, Barentsz JO. A comparison of the diagnostic performance of systematic versus ultrasound-guided biopsies of prostate cancer. *Eur Radiol* 2006;16:927-38.
- [5] Terris MK, Wallen EM, Stamey TA. Comparison of mid-lobe versus lateral systematic sextant biopsies in the detection of prostate cancer. *Urol Int* 1997;59:239-42.
- [6] Salo JO, Rannikko S, Makinen J, Lehtonen T. Echogenic structure of prostatic cancer imaged on radical prostatectomy specimens. *Prostate* 1987;10:1-9.
- [7] Ellis WJ, Brawer MK. The significance of isoechoic prostatic carcinoma. *J Urol* 1994;152:2304-7.
- [8] de la Rosette JJ, Aarnink RG. New developments in ultrasonography for the detection of prostate cancer. *J Endourol* 2001;15:93-104.
- [9] Ismail M, Petersen RO, Alexander AA, Newschaffer C, Gomella LG. Color Doppler imaging in predicting the biologic behavior of prostate cancer: correlation with disease-free survival. *Urology* 1997;50:906-12.
- [10] Kimura G, Nishimura T, Kimata R, Saito Y, Yoshida K. Random systematic sextant biopsy versus power doppler ultrasound-guided target biopsy in the diagnosis of prostate cancer: positive rate and clinicopathological features. *J Nippon Med Sch* 2005;72:262-9.
- [11] Lavoipierre AM, Snow RM, Frydenberg M, et al. Prostatic cancer: role of color Doppler imaging in transrectal sonography. *AJR Am J Roentgenol* 1998;171:205-10.
- [12] Scattoni V, Zlotta A, Montironi R, Schulman C, Rigatti P, Montorsi F. Extended and saturation prostatic biopsy in the diagnosis and characterisation of prostate cancer: a critical analysis of the literature. *Eur Urol* 2007;52:1309-22.
- [13] Haker SJ, Mulkern RV, Roebuck JR, et al. Magnetic resonance-guided prostate interventions. *Top Magn Reson Imaging* 2005;16:355-68.
- [14] Norberg M, Egevad L, Holmberg L, Sparen P, Norlen BJ, Busch C. The sextant protocol for ultrasound-guided core biopsies of the prostate underestimates the presence of cancer. *Urology* 1997;50:562-6.
- [15] Schiebler ML, Schnall MD, Pollack HM, et al. Current role of MR imaging in the staging of adenocarcinoma of the prostate. *Radiology* 1993;189:339-52.
- [16] Kirkham APS, Emberton M, Allen C. How good is MRI at detecting and characterising cancer within the prostate? *Eur Urol* 2006;50:1163-75, discussion 1175.
- [17] Fütterer JJ, Heijmink SW, Scheenen TW, et al. Prostate cancer localization with dynamic contrast-enhanced MR imaging and proton MR spectroscopic imaging. *Radiology* 2006;241:449-58.
- [18] Hosseinzadeh K, Schwarz SD. Endorectal diffusion-weighted imaging in prostate cancer to differentiate malignant and benign peripheral zone tissue. *J Magn Reson Imaging* 2004;20:654-61.
- [19] Shimofusa R, Fujimoto H, Akamata H, et al. Diffusion-weighted imaging of prostate cancer. *J Comput Assist Tomogr* 2005;29:149-53.
- [20] Singh AK, Krieger A, Lattouf JB, et al. Patient selection determines the prostate cancer yield of dynamic contrast-enhanced magnetic resonance imaging-guided transrectal biopsies in a closed 3-Tesla scanner. *BJU Int* 2008;101:181-5.
- [21] Beyersdorff D, Winkel A, Hamm B, Lenk S, Loening SA, Taupitz M. MR imaging-guided prostate biopsy with a closed MR unit at 1.5 T: initial results. *Radiology* 2005;234:576-81.
- [22] D'Amico AV, Tempany CM, Cormack R, et al. Transperineal magnetic resonance image guided prostate biopsy. *J Urol* 2000;164:385-7.
- [23] Fischer GS, DiMaio SP, Iordachita II, Fichtinger G. Robotic assistant for transperineal prostate interventions in 3 T closed MRI. *Med Image Comput Comput Assist Interv Int Conf Med Image Comput Comput Assist Interv* 2007;10:425-33.
- [24] Cleary K, Melzer A, Watson V, Kronreif G, Stoianovici D. Interventional robotic systems: applications and technology state-of-the-art. *Minim Invasive Ther Allied Technol* 2006;15:101-13.

- [25] Stone NN, Roy J, Hong S, Lo YC, Stock RG. Prostate gland motion and deformation caused by needle placement during brachytherapy. *Brachytherapy* 2002;1:154–60.
- [26] Dattoli M, Waller K. A simple method to stabilize the prostate during transperineal prostate brachytherapy. *Int J Radiat Oncol Biol Phys* 1997;38:341–2.
- [27] Hata N, Jinzaki M, Kacher D, et al. MR imaging-guided prostate biopsy with surgical navigation software: device validation and feasibility. *Radiology* 2001;220:263–8.
- [28] Zangos S, Eichler K, Engelmann K, et al. MR-guided transgluteal biopsies with an open low-field system in patients with clinically suspected prostate cancer: technique and preliminary results. *Eur Radiol* 2005;15:174–82.
- [29] DiMaio SP, Pieper S, Chinzei K, et al. Robot-assisted needle placement in open MRI: system architecture, integration and validation. *Comput Aided Surg* 2007;12:15–24.
- [30] Fichtinger G, Krieger A, Susil RC, Tanacs A, Whitcomb LL, Atalar E. Transrectal prostate biopsy inside closed MRI scanner with remote actuation, under real-time image guidance. *Lecture Notes in Comput Sci* 2002;2488:91–8.
- [31] Engelhard K, Hollenbach HP, Kiefer B, Winkel A, Goeb K, Engehausen D. Prostate biopsy in the supine position in a standard 1.5-T scanner under real time MR-imaging control using a MR-compatible endorectal biopsy device. *Eur Radiol* 2006;16:1237–43.
- [32] Anastasiadis AG, Lichy MP, Nagele U, et al. MRI-guided biopsy of the prostate increases diagnostic performance in men with elevated or increasing PSA levels after previous negative TRUS biopsies. *Eur Urol* 2006;50:738–49, discussion 748–9.
- [33] Roehl KA, Antenor JA, Catalona WJ. Serial biopsy results in prostate cancer screening study. *J Urol* 2002;167:2435–9.
- [34] Krieger A, Susil RC, Menard C, et al. Design of a novel MRI compatible manipulator for image guided prostate interventions. *IEEE Trans Biomed Eng* 2005;52:306–13.
- [35] Susil RC, Menard C, Krieger A, et al. Transrectal prostate biopsy and fiducial marker placement in a standard 1.5 T magnetic resonance imaging scanner. *J Urol* 2006;175:113–20.
- [36] Dimaio S, Fischer GS, Haker S, et al. A system for MRI-guided prostate interventions. *Proceedings for the First IEEE/RAS-EMBS International Conference on Biomedical Robotics and Biomechatronics*. 2006:68–73.
- [37] Zangos S, Herzog C, Eichler K, et al. MR-compatible assistance system for puncture in a high-field system: device and feasibility of transgluteal biopsies of the prostate gland. *Eur Radiol* 2007;17:1118–24.
- [38] Lattouf JB, Grubb 3rd RL, Lee SJ, et al. Magnetic resonance imaging-directed transrectal ultrasonography-guided biopsies in patients at risk of prostate cancer. *BJU Int* 2007;99:1041–6.
- [39] Singh AK, Kruecker J, Xu S, et al. Initial clinical experience with real-time transrectal ultrasonography-magnetic resonance imaging fusion-guided prostate biopsy. *BJU Int* 2008;101:841–5.
- [40] Kaplan I, Oldenburg NE, Meskell P, Blake M, Church P, Holupka EJ. Real time MRI-ultrasound image guided stereotactic prostate biopsy. *Magn Reson Imaging* 2002;20:295–9.
- [41] Singh AK, Guion P, Sears-Crouse N, et al. Simultaneous integrated boost of biopsy proven, MRI defined dominant intra-prostatic lesions to 95 Gray with IMRT: early results of a phase I NCI study. *Radiat Oncol* 2007;2:36.
- [42] Stoianovici D, Song D, Petrisor D, et al. “MRI Stealth” robot for prostate interventions. *Minim Invasive Ther Allied Technol* 2007;16:241–8.
- [43] Stoianovici D. Multi-imager compatible actuation principles in surgical robotics. *Int J Med Robotics Comput Assist Surg* 2005;1:86–100.
- [44] Muntener M, Patriciu A, Petrisor D, et al. Transperineal prostate intervention: robot for fully automated MR imaging—system description and proof of principle in a canine model. *Radiology* 2008;47:543–9.

Editorial Comment on: MR-Guided Biopsy of the Prostate: An Overview of Techniques and a Systematic Review

Jonathan A. Coleman

Weill-Cornell Medical Center,

Memorial Sloan-Kettering Cancer Center,

Department of Surgery/Division of Urology,

New York, NY, USA

colemaj1@mskcc.org

There is a great need for an accurate imaging technique for prostate cancer. The prostate gland is easily accessible, allowing high-resolution imaging of the gland and surrounding pelvic anatomy with a variety of modalities. Of the currently available and immediately foreseeable radiographic technologies, magnetic resonance imaging (MRI) appears best suited to this application, offering

superior spatial resolution with potential for supplemental, quantifiable biological imaging. With further refinements, it is expected that MRI will be capable of providing tumor morphometrics and will play a central role in guiding treatment including surveillance and focal ablation strategies. Image-guided procedures are likewise needed, although instrumentation of any kind within the bore of a magnetic resonance (MR) scanner is fraught with technical challenges.

In their manuscript, Pondman and colleagues [1] provide an excellent overview of the considerable engineering and clinical efforts published to date involving MRI-guided prostate biopsy instrumentation and techniques. Several groups have focused on this field and produced a variety of devices that are capable of safely and accurately placing biopsy needles within the prostate gland to

allow tissue sampling of discrete regions of interest identified from MR images. These early results have provided proof-of-principle support to many of the design elements of these devices as well as allowed for validation studies of MRI in the characterization of prostate pathology. The true benefits of these endeavors have yet to be realized.

Development of MR-compatible instrumentation for imaging guided procedures provides a springboard for a myriad of diagnostic and therapeutic interventions for both benign and malignant diseases of the gland. Aside from biopsy, needle-based procedures, such as focal tissue ablation or injection-based therapeutics with monitoring of treatment effects, are possible when complemented with sophisticated imaging techniques, such as MR thermography. Similarly, other endocavity-based pelvic procedures, including gynecologic and colorectal procedures, may be adapted using these devices. The addition of remote actuation, or “robotic” automation, further

expands the potential of these approaches to include other forms of procedures and use in other organ systems.

What is clear is that success in this field hinges on the combined work of dedicated researchers from a variety of clinical, biomedical, and engineering backgrounds. The results from this level of cooperative multidisciplinary effort bode well for the future of these techniques and for the future of translational biomedical/bioengineering research in image-guided procedures.

Reference

- [1] Pondman KM, Fütterer JJ, ten Haken B, et al. MR-guided biopsy of the prostate: an overview of techniques and a systematic review. *Eur Urol* 2008;54:517–27.

DOI: [10.1016/j.eururo.2008.06.004](https://doi.org/10.1016/j.eururo.2008.06.004)

DOI of original article: [10.1016/j.eururo.2008.06.001](https://doi.org/10.1016/j.eururo.2008.06.001)

Editorial Comment on: MR-Guided Biopsy of the Prostate: An Overview of Techniques and a Systematic Review

Alessandro Sciarra

Department of Urology “U. Bracci”,
University of Rome “Sapienza”, Viale Policlinico,
00161 Rome, Italy
a.sciarra@lycos.it

A large number of studies [1,2] have recently shown that magnetic resonance (MR), in addition to proton 1H-spectroscopic analysis and dynamic contrast-enhanced imaging (DCEMR), could represent a powerful tool for the management of most aspects of prostate cancer, including initial diagnosis, cancer localization, road map for surgery and radiotherapy, and early detection of local recurrence. Ultrasound-guided biopsy is considered the preferred method for prostate cancer detection; however, most of the studies have reported that sextant biopsies missed up to 30% of cancers, and biopsy results showed a positive predictive value of 83% and a negative predictive value of 36% when compared to radical prostatectomy for tumor localization [3].

Although MR and MR spectroscopy imaging (MRSI) are not used at this time as a first approach to diagnose prostate cancer, they can be useful for directing targeted biopsies, especially for cases with prostate-specific antigen (PSA) levels that are

indicative of cancer and negative previous biopsy. In the present article, Pondman et al [4] summarized current technical and clinical application of MR-guided biopsies of the prostate. In some experiences [5,6], MR-guided biopsy techniques are becoming more and more available, but there is no current consensus on the optimal technique. Moreover, relevant problems remain: in particular, movement of the prostate during the biopsy procedure is one of the biggest challenges in taking biopsies of the gland. Robotic assistance for MR-guided intervention with the prostate may improve results, but the problem of cost could be more relevant.

For a long time, a valid diagnostic imaging procedure has not been available for prostate cancer. MRSI may reduce the rate of false-negative biopsies and decrease the need for more extensive biopsies or repeat biopsy procedures. MR-guided prostate biopsy will also have an increasing role in this field. Extensive clinical studies are essential for analyzing the real value and advantages of MR guidance for biopsy.

References

- [1] Kirkham APS, Emberton M, Allen C. How good is MRI at detecting and characterising cancer within the prostate? *Eur Urol* 2006;50:1163–75.

- [2] Sciarra A, Panebianco V, Saliccia S, et al. Role of dynamic contrast-enhanced magnetic resonance imaging and proton MR spectroscopic imaging in the detection of local recurrence after radical prostatectomy for prostate cancer. *Eur Urol* 2008;54:589–600.
- [3] Hricak H. MR imaging and MR spectroscopic imaging in the pre-treatment evaluation of prostate cancer. *Br J Radiol* 2005;78:103–11.
- [4] Pondman KM, Fütterer JJ, ten Haken B, et al. MR-guided biopsy of the prostate: an overview of techniques and a systematic review. *Eur Urol* 2008;54:517–27.
- [5] Hata N, Jinzaki M, Kacher D, et al. MR imaging-guided prostate biopsy with surgical navigation software: device validation and feasibility. *Radiology* 2001;220:263–8.
- [6] Zangos S, Eichler K, Engelmann K, et al. MR-guided transgluteal biopsies with an open low-field system in patient with clinically suspected prostate cancer: technique and preliminary results. *Eur Radiol* 2005;15:174–82.

DOI: [10.1016/j.eururo.2008.06.005](https://doi.org/10.1016/j.eururo.2008.06.005)

DOI of original article: [10.1016/j.eururo.2008.06.001](https://doi.org/10.1016/j.eururo.2008.06.001)