

University of Groningen

## Clinical consensus guideline on the management of pheochromocytoma and paraganglioma in patients harbouring germline SDHD pathogenic variants

Taïeb, David; Wanna, George B.; Ahmad, Maleeha; Lussey-Lepoutre, Charlotte; Perrier, Nancy D.; Nölting, Svenja; Amar, Laurence; Timmers, Henri J.L.M.; Schwam, Zachary G.; Estrera, Anthony L.

*Published in:*  
The Lancet Diabetes and Endocrinology

*DOI:*  
[10.1016/S2213-8587\(23\)00038-4](https://doi.org/10.1016/S2213-8587(23)00038-4)

**IMPORTANT NOTE: You are advised to consult the publisher's version (publisher's PDF) if you wish to cite from it. Please check the document version below.**

*Document Version*  
Publisher's PDF, also known as Version of record

*Publication date:*  
2023

[Link to publication in University of Groningen/UMCG research database](#)

### *Citation for published version (APA):*

Taïeb, D., Wanna, G. B., Ahmad, M., Lussey-Lepoutre, C., Perrier, N. D., Nölting, S., Amar, L., Timmers, H. J. L. M., Schwam, Z. G., Estrera, A. L., Lim, M., Pollom, E. L., Vitzthum, L., Bourdeau, I., Casey, R. T., Castinetti, F., Clifton-Bligh, R., Corssmit, E. P. M., de Krijger, R. R., ... Pacak, K. (2023). Clinical consensus guideline on the management of pheochromocytoma and paraganglioma in patients harbouring germline SDHD pathogenic variants. *The Lancet Diabetes and Endocrinology*, 11(5), 345-361.  
[https://doi.org/10.1016/S2213-8587\(23\)00038-4](https://doi.org/10.1016/S2213-8587(23)00038-4)

### **Copyright**

Other than for strictly personal use, it is not permitted to download or to forward/distribute the text or part of it without the consent of the author(s) and/or copyright holder(s), unless the work is under an open content license (like Creative Commons).

The publication may also be distributed here under the terms of Article 25fa of the Dutch Copyright Act, indicated by the "Taverne" license. More information can be found on the University of Groningen website: <https://www.rug.nl/library/open-access/self-archiving-pure/taverne-amendment>.

### **Take-down policy**

If you believe that this document breaches copyright please contact us providing details, and we will remove access to the work immediately and investigate your claim.



# Clinical consensus guideline on the management of pheochromocytoma and paraganglioma in patients harbouring germline *SDHD* pathogenic variants

David Taïeb, George B Wanna, Maleeha Ahmad, Charlotte Lussey-Lepoutre, Nancy D Perrier, Svenja Nölting, Laurence Amar, Henri J L M Timmers, Zachary G Schwam, Anthony L Estrera, Michael Lim, Erqi Liu Pollom, Lucas Vitzthum, Isabelle Bourdeau, Ruth T Casey, Frédéric Castinetti, Roderick Clifton-Bligh, Eleonora P M Corssmit, Ronald R de Krijger, Jaydira Del Rivero, Graeme Eisenhofer, Hans K Ghayee, Anne-Paule Gimenez-Roqueplo, Ashley Grossman, Alessio Imperiale, Jeroen C Jansen, Abhishek Jha, Michiel N Kerstens, Henricus P M Kunst, James K Liu, Eamonn R Maher, Daniele Marchioni, Leilani B Mercado-Asis, Ozgur Mete, Mitsuhide Naruse, Naris Nilubol, Neeta Pandit-Taskar, Frédéric Sebag, Akiyo Tanabe, Jiri Widimsky, Leah Meuter, Jacques W M Lenders, Karel Pacak

Patients with germline *SDHD* pathogenic variants (encoding succinate dehydrogenase subunit D; ie, paraganglioma 1 syndrome) are predominantly affected by head and neck paragangliomas, which, in almost 20% of patients, might coexist with paragangliomas arising from other locations (eg, adrenal medulla, para-aortic, cardiac or thoracic, and pelvic). Given the higher risk of tumour multifocality and bilaterality for pheochromocytomas and paragangliomas (PPGLs) because of *SDHD* pathogenic variants than for their sporadic and other genotypic counterparts, the management of patients with *SDHD* PPGLs is clinically complex in terms of imaging, treatment, and management options. Furthermore, locally aggressive disease can be discovered at a young age or late in the disease course, which presents challenges in balancing surgical intervention with various medical and radiotherapeutic approaches. The axiom—first, do no harm—should always be considered and an initial period of observation (ie, watchful waiting) is often appropriate to characterise tumour behaviour in patients with these pathogenic variants. These patients should be referred to specialised high-volume medical centres. This consensus guideline aims to help physicians with the clinical decision-making process when caring for patients with *SDHD* PPGLs.

## Introduction

Hereditary head and neck paragangliomas (HNPGs) are the most common tumours in patients with germline *SDHD* (encoding succinate dehydrogenase subunit D) pathogenic variants. They are typically slow-growing hypervascular tumours but have the potential to become locally aggressive. HNPGs can be found in all anatomical sites of distribution of parasympathetic paraganglia, such as in the middle ear cleft, in the jugular bulb, along the vagus nerve, and in the carotid body (figure 1). HNPGs are rarely functional and are inherited in 40–50% of patients. Patients with *SDHD* pathogenic variants might also develop thoracic, retroperitoneal, and pelvic paragangliomas (in fewer than 20% of patients and rarely in isolation), and, more rarely, gastrointestinal stromal tumours, renal cell carcinoma, and pituitary adenomas.<sup>1</sup> These tumours should be screened during the evaluation of patients. Multifocality of paragangliomas is observed in approximately 75% of patients; however, the overall risk of metastatic disease is approximately 5%. Disease penetrance is parent-of-origin dependent (ie, genomic imprinting). After a paternal transmission of *SDHD* pathogenic variants, the proportion of individuals that will develop pheochromocytomas and paragangliomas (PPGLs) within their life is 90–100%, whereas maternal transmission very rarely leads to tumour development. Genetic counselling and testing are recommended for individuals who are at risk, with PPGL screening for those with *SDHD* pathogenic variants, including instances of maternal inheritance.<sup>2</sup>

## Methods

The consensus included three chairpersons (DT, JWML, and KP) and one project manager (LM). The project was initiated in May, 2021, and started with the setting-up of the working groups (ie, determining the members of the steering and rating groups). The steering group included 12 members, GBW, MA, CL-L, NP, SN, LA, HJLMT, ZGS, ALE, ML, ELP, and LV. The rating group members included the remaining coauthors excluding DT, JWML, KP, and LM. All members of the steering and rating groups that participated in the development of the consensus are experts in PPGL and represent various countries, practice settings, and disciplines (ie, endocrinology, oncology, internal medicine, surgery, otolaryngology, radiotherapy, radiology, nuclear medicine, genetics, clinical chemistry, and pathology).

A first meeting with the steering group was held on Aug 18, 2021, during which the members were asked to perform literature searches with PubMed using proposed search strategies. The members of the steering group were also asked to review and critically analyse the available literature and draft relevant graded recommendations using the Grading of Recommendations Assessment, Development, and Evaluation (GRADE) framework for each thematic area, supported by a concise paragraph with the most relevant supporting evidence (eg, references, figures, and tables).

In February, 2022, the rating group members received the proposed recommendations with evidence and

*Lancet Diabetes Endocrinol* 2023; 11: 345–61

Published Online

March 31, 2023

[https://doi.org/10.1016/S2213-8587\(23\)00038-4](https://doi.org/10.1016/S2213-8587(23)00038-4)

Department of Neurosurgery

(M Ahmad MD, Prof M Lim MD),

Department of Physician

Assistant Studies (L Meuter BS),

and Department of Radiation

Oncology (E L Pollom MD,

L Vitzthum MD), Stanford

University School of Medicine,

Palo Alto, CA, USA; Université

Paris Cité, Inserm, PARCC,

Equipe Labellisée par la Ligue

contre le Cancer, Paris, France

(Prof L Amar MD,

Prof A-P Gimenez-Roqueplo MD,

Prof C Lussey-Lepoutre MD);

Unité d'hypertension artérielle

(Prof L Amar) and Département

de Médecine Génomique des

Tumeurs et des Cancers

(Prof A-P Gimenez-Roqueplo),

Hôpital Européen Georges

Pompidou, Assistance

Publique-Hôpitaux de Paris,

Paris, France; Division of

Endocrinology, Department of

Medicine and Research Center,

Centre Hospitalier de

l'Université de Montréal,

Montréal, QC, Canada

(Prof I Bourdeau MD);

Department of Medical

Genetics, NIHR Cambridge

Biomedical Research Centre,

Cancer Research UK Cambridge

Centre, Cambridge Biomedical

Campus, University of

Cambridge, Cambridge, UK

(R T Casey PhD,

Prof E R Maher MD);

Department of Endocrinology,

Royal North Shore Hospital,

Sydney, NSW, Australia

(Prof R Clifton-Bligh PhD);

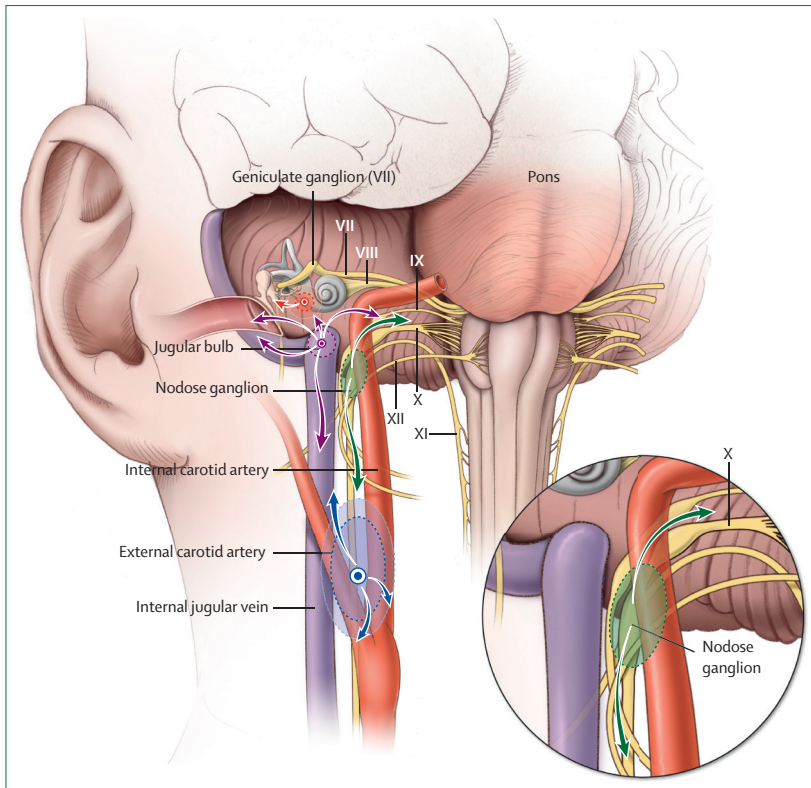
Cancer Genetics Laboratory,

Kolling Institute, University of

Sydney, Sydney, NSW, Australia

(Prof R Clifton-Bligh);

Department of Endocrinology,



**Figure 1: Different potential locations of HNPGLs**

HNPGLs can arise from the carotid bifurcation (blue), the nodose ganglion (green), jugular bulb (purple), and middle ear (red), and invade adjacent structures within the head and neck. The nodose ganglion corresponds to the inferior ganglion of the vagus nerve. Arrows indicate the potential patterns of local tumour extension for a given tumour type. Roman numerals refer to the relevant cranial nerves. HNPGLs=head and neck paragangliomas.

Center of Endocrine Tumors  
Leiden (E P M Corssmit MD) and  
Department of  
Otorhinolaryngology  
(Prof J C Jansen MD), Leiden  
University Medical Centre,  
Leiden, Netherlands;  
Department of Pathology,  
University Medical Center  
Utrecht, Utrecht, Netherlands  
(R R de Krijger MD); Princess  
Máxima Center for Pediatric  
Oncology, Utrecht,  
Netherlands (R R de Krijger);  
Developmental Therapeutics  
Branch, Rare Tumor Initiative,  
Center for Cancer Research,  
National Cancer Institute  
(J Del Rivero MD), Section on  
Medical Neuroendocrinology,  
Eunice Kennedy Shriver  
National Institute of Child  
Health and Human  
Development  
(Prof K Pacak MD, A Jha MBBS),  
and Surgical Oncology  
Program, National Cancer  
Institute (N Nilubol MD),  
National Institutes of Health,  
Bethesda, MD, USA; Institute

supplementary tables, but without the ratings of the strength of grading and quality of evidence. Each member of the rating group voted whether they agreed or disagreed with the narrative forms of the recommendations (ie, strongly agree, agree, neither agree nor disagree, disagree, strongly disagree, and do not know or other), and then rated the strength of the proposed grading (1=strong, 2=weak) and the quality of the evidence with the GRADE framework (rated 1 to 4 with 1 being the weakest).<sup>3</sup> They could also leave further comments or suggestions about the reasoning of their voting choices (eg, not having or having little expertise in a specific topic).

The results of the responses from the members of the rating group were presented to the members of the steering and rating groups during two meetings on May 2 and May 18, 2022. During these meetings, any discordances between the rating and steering groups were discussed to find consensus on the phrasing of the recommendations and grades regarding the strength of the proposal and quality of the evidence. After this initial period, two additional rounds of voting were conducted with the rating group. Rating group members were requested to indicate their agreement or disagreement with the phrasing of the recommendations, strength of GRADE recommendation,

and quality of evidence. Two additional meetings on June 22, 2022, and Sept 9, 2022, were conducted with the members of the rating and steering groups to find a consensus. After the last meeting in September, 2022, the chairpersons and project manager drafted the final version of the consensus statement and sent the manuscript and supplemental files to all members of the steering and rating groups for a final review and approval.

## Recommendations

### Health-care environment for patients with SDHD PPGLs Recommendation 1

We recommend that all decisions regarding patients with SDHD PPGLs are discussed and managed by an interdisciplinary tumour team of experts familiar with the disease to ensure favourable outcomes and appropriate follow-up (grade strength=1; quality of evidence rating=1).

#### Evidence for recommendation 1

There is no solid evidence from clinical studies showing favourable outcomes if patients are managed by an interdisciplinary team with expertise in PPGL. However, PPGL is a complex and heterogeneous disease involving many organs in a variable way. Most physicians will have little experience in this field due to the rarity of these tumours, particularly experience that covers the competencies of the different specialties involved. Therefore, this recommendation is mainly based on the experience and opinion of many international experts that interdisciplinary discussion of the management decisions of patients with PPGL is the optimal approach. Such approach facilitates the tailoring of clinical management to the individual patient level, which extends beyond diagnosis and treatment to offering the most appropriate individualised follow-up and surveillance.<sup>4,5</sup> Expert interdisciplinary teams are operative in clinical centres that specialise in PPGL, including the European Network for the Study of Adrenal Tumors Centers of Excellence and the Clinical Centers of Excellence accredited by the Pheochromocytoma Paraganglioma Alliance and any clinical centre in which regular team discussions of interdisciplinary experts are operational.

### Initial tests for patients with SDHD PPGLs

#### Recommendation 2

We recommend that patients with PPGL and germline SDHD pathogenic variants are evaluated by clinical assessment and biochemical measurements (ie, metanephrines in plasma or urine and plasma methoxytyramine; grade strength=1; quality of evidence rating=3).

#### Recommendation 3

We recommend performing head and neck MRI as the first method for patients with HNPGL to screen for multifocality and tumour extension (grade strength=1; quality of evidence rating=3).

#### Recommendation 4

To search for *SDHD* PPGL in patients on a whole-body scale, we recommend performing whole-body anatomical imaging with PET–CT, preferably with radiolabelled somatostatin analogues, as the first choice (grade strength=1; quality of evidence rating=3).

#### Evidence for recommendations 2–4

In patients with *SDHD* HNPGL, symptoms and signs are often delayed and related to local mass effects caused by large tumours rather than an excess of catecholamines.

Patients with HNPGL with plasma normetanephrine concentrations more than double the upper reference limit are rare (2–3%). Therefore, increased concentrations of normetanephrine in patients with *SDHD* pathogenic variants are more likely to be related to the presence of paragangliomas outside the head and neck region.<sup>6</sup> Furthermore, up to 30% of HNPGLs produce dopamine, indicated by increases in plasma methoxytyramine.<sup>6–8</sup> Urine methoxytyramine is not a useful biomarker of tumoural dopamine production in these tumours because urine dopamine is derived almost exclusively from renal uptake and decarboxylation of circulating 3,4-dihydroxyphenylalanine. Biochemical assessments should include plasma (usually preferred) or urine metanephrines and plasma methoxytyramine.<sup>9–11</sup>

Imaging has a crucial role in the evaluation of patients with *SDHD* PPGLs. Imaging should encompass the base of the skull to the pelvis. MRI with angiography sequences (MRA) are the most sensitive radiological techniques for HNPGL staging.<sup>11–14</sup> Various magnetic resonance acquisition protocols have been described in the literature, including one large study that evaluated MRA in 157 patients with HNPGL with germline pathogenic variants (63 patients [40%] with germline *SDHD* pathogenic variants). In this study, a combination of contrast-enhanced three-dimensional time-of-flight angiography at the arterial phase and axial-plane fast spin-echo T1-weighted sequence with fat saturation showed a sensitivity of 88.7% and a specificity of 93.7%.<sup>12</sup> For patients with skull base HNPGLs, temporal bone CT provides irreplaceable information on the extent of bone involvement. Cervico-thoraco-abdominal-pelvic PPGLs can also be visualised with CT scans. CT with intravenous contrast is less costly and time consuming than MRI and particularly useful for perioperative planning. Therefore, CT is often preferred to MRI at the initial evaluation of patients, except for some paediatric patients or during pregnancy.

Functional imaging complements anatomical imaging for whole-body disease staging and can exclude other potential diagnoses. Patients with *SDHD* PPGLs typically exhibit strong somatostatin receptor (SSTR) subtype 2 expressions, which is reflected by the high sensitivity of SSTR-guided PET–CT with <sup>68</sup>Ga-radiolabelled somatostatin analogues.<sup>15–18</sup> The sensitivity

#### Panel: Potential pitfalls in the interpretation of PET imaging by use of labeled somatostatin receptor (SSTR) ligands and 6-[<sup>18</sup>F]fluoro-3,4-dihydroxyphenylalanine

##### SSTR analogues

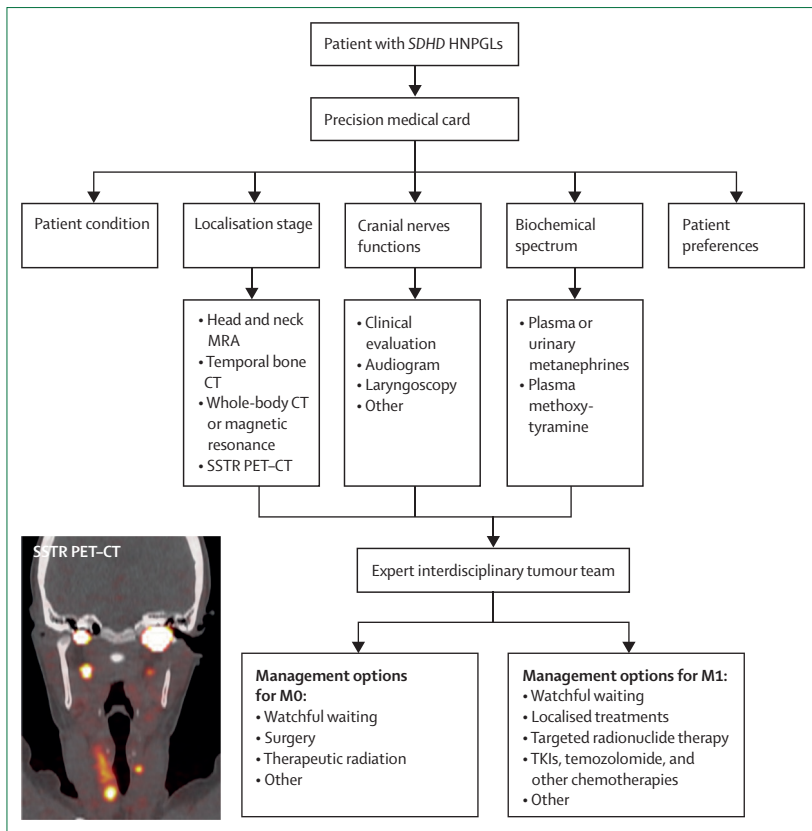
- Uncinate process
- Stellate ganglia
- Splenunculi (accessory spleens) and splenosis
- Pancreatic heterotopia
- Pancreatic serous cystadenoma
- Bone haemangioma, enchondroma, and fibrous dysplasia
- Active chronic inflammation (eg, sarcoidosis, tuberculosis, Hashimoto's thyroiditis)
- Other tumours (eg, meningioma, breast cancer, renal cancer, lymphoma, thyroid neoplasms, glioma, and neuroblastoma)

##### 6-[<sup>18</sup>F]fluoro-3,4-dihydroxyphenylalanine

- Solid pseudopapillary tumour of the pancreas
- Thyroid neoplasm
- Pituitary adenoma
- Squamous cell carcinoma
- Poorly differentiated adenocarcinoma
- Melanoma
- Multiple myeloma
- Hepatocellular carcinoma
- Schwannoma
- Chondrosarcoma
- Primary brain tumours (eg, glioma, astrocytoma, and glioblastoma multiforme)

approaches 100% for HNPGL and metastatic PPGL, but appears to be less sensitive for primary pheochromocytomas and abdominal paragangliomas.<sup>19</sup> However, more extensive imaging data for patients with *SDHD* pathogenic variants are still needed. 6-[<sup>18</sup>F]fluoro-3,4-dihydroxyphenylalanine ([<sup>18</sup>F]-FDOPA)-PET–CT has also shown high sensitivity in the detection of *SDHD* HNPGLs (sensitivity approaching 100%)<sup>20,21</sup> and is a good alternative to SSTR PET–CT with <sup>68</sup>Ga-radiolabelled somatostatin analogues if unavailable.<sup>22</sup> However, [<sup>18</sup>F]-FDOPA-PET–CT overlooks some symptomatic PPGLs (ie, outside the head and neck area).<sup>23,24</sup> [<sup>18</sup>F]fluorodeoxyglucose ([<sup>18</sup>F]FDG)-PET–CT has shown excellent results in the evaluation of patients with PPGLs harbouring germline pathogenic variants in one of the four genes that encode the SDH complex (collectively termed as *SDHx*).<sup>25–28</sup> However, this imaging method has been surpassed by SSTR PET–CT,<sup>16</sup> especially in the detection of *SDHD* HNPGLs (sensitivity ranging 70–90% for [<sup>18</sup>F]-FDG-PET–CT versus nearly 100% for SSTR PET–CT). The lower clinical value of [<sup>18</sup>F]-FDG-PET–CT is because of the less favourable tumour-to-background uptake ratio than those of specific radiopharmaceuticals and the potential drawbacks because of uptake by brown

of Clinical Chemistry and Laboratory Medicine (Prof G Eisenhofer PhD) and Department of Medicine III (Prof J W M Lenders MD), University Hospital Carl Gustav Carus, Technische Universität Dresden, Dresden, Germany; Department of Cardiothoracic and Vascular Surgery, UTHealth Houston, McGovern Medical School, Memorial Hermann Hospital Heart and Vascular Institute, Houston, TX, USA (Prof A L Estera MD); Division of Endocrinology and Metabolism, Department of Medicine, Malcom Randall VA Medical Center, University of Florida, Gainesville, FL, USA (H K Ghayee DO); Green Templeton College, University of Oxford, Oxford, UK (Prof A Grossman FmedSci); NET Unit, Royal Free Hospital, London, UK (Prof A Grossman); Department of Nuclear Medicine and Molecular Imaging, Institut de Cancérologie de Strasbourg Europe, IPHC, UMR 7178, CNRS, University of Strasbourg, Strasbourg, France (Prof A Imperiale MD); Department of Endocrinology, University Medical Center Groningen, Groningen, Netherlands (M N Kerstens MD); Department of Otolaryngology and Head & Neck Surgery, Dutch Academic Alliance Skull Base Pathology (Prof H P M Kunst MD) and Department of Internal Medicine (Prof J W M Lenders, Prof H J L M Timmers MD), Radboud University Medical Center, Nijmegen, Netherlands; Department of Otolaryngology and Head & Neck Surgery, Dutch Academic Alliance Skull Base Pathology, Maastricht University Medical Center, Maastricht, Netherlands (Prof H P M Kunst); Department of Neurosurgical Surgery, Rutgers New Jersey Medical School, Newark, NJ, USA (Prof J K Liu MD); Department of Nuclear Medicine, Pitié-Salpêtrière Hospital, Sorbonne University, Paris, France (Prof C Lussey-Lepoutre); Department of Otorhinolaryngology and Head and Neck Surgery, University Hospital of Verona, Verona, Italy (Prof D Marchioni MD); Section of Endocrinology and Metabolism, Department of Medicine, Faculty of Medicine



**Figure 2: Current synthesis of the important clinical facts that contribute to the decision-making process**  
 The SSTR PET-CT image shows a multifocal HNPGL with bilateral tumours, a situation that typical occurs in patients harbouring germline SDHD pathogenic variants. HNPGLs=head and neck paragangliomas. MO=absence of metastasis. M1=presence of metastasis. MRA=magnetic resonance angiography. SDHD=encoding succinate dehydrogenase subunit D. SSTR=somatostatin receptor. TKIs=tyrosine kinase inhibitors.

& Surgery, University of Santo Tomas Hospital, University of Santo Tomas, Manila, Philippines (Prof L Mercado-Asis MD); Department of Laboratory Medicine and Pathobiology, University of Toronto, Toronto, ON, Canada (Prof O Mete MD); Endocrine Pathology Society, Toronto, ON, Canada (Prof O Mete); Medical Center and Endocrine Center, Ijinkai Takeda General Hospital, Kyoto, Japan (M Naruse MD); Svenja Nölting, Department of Endocrinology, Diabetology, and Clinical Nutrition, University Hospital Zurich and University of Zurich, Zurich, Switzerland (Prof S Nölting MD); Department of Surgical Oncology, MD Anderson Cancer Center, Houston, TX, USA (Prof N D Perrier MD); Department of Radiology, Molecular Imaging and Therapy

adipose tissue and reactive lymph nodes. Functional imaging findings should be interpreted by a physician who is experienced in PPGL imaging and should consider possible pitfalls, variants, and caveats (panel). Compared with PET-CT imaging, <sup>123</sup>I-metaiodobenzylguanidine (<sup>123</sup>I-MIBG) and <sup>111</sup>In-pentetreotide scintigraphy are suboptimal and should not be used in a purely diagnostic setting.

**Evaluation of surgical interventions for patients with SDHD HNPGLs**

**Recommendation 5**

We recommend that patients with vagal paragangliomas rarely be considered for resection due to the high risk of resultant vocal cord paralysis (grade strength=1; quality of evidence rating=2).

**Recommendation 6**

We recommend that newly diagnosed patients with jugular, vagal, and carotid paragangliomas without compelling indications for treatment undergo an initial trial of observation to characterise tumour behaviour (grade strength=1; quality of evidence rating=2).

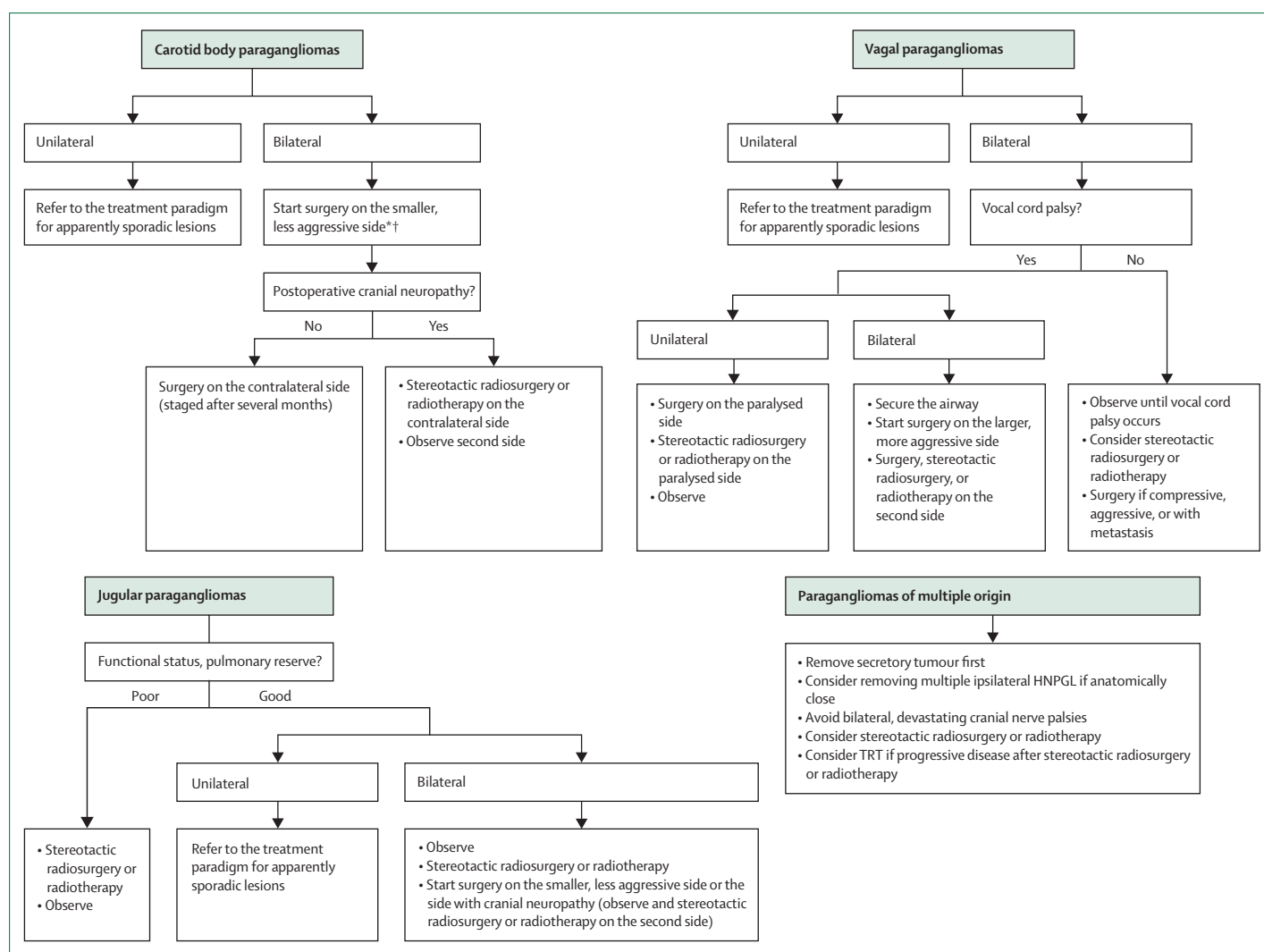
**Evidence for recommendations 5 and 6**

Because of characteristic slow growth, the axiom—first, do no harm—is particularly relevant to the management of patients with HNPGLs (figure 2). Newly diagnosed patients with germline SDHD pathogenic variants, notably patients with non-tympanicum HNPGL, and patients without an urgent indication for resection (eg, severe or progressive symptoms from cranial neuropathies, brainstem compression, severe pain, bleeding, and brain ischaemia), are good candidates for an initial observation trial. Patients with tympanic paragangliomas often present with hearing loss and pulsatile tinnitus. Resection is safe when performed by an experienced surgeon, is often done on an outpatient basis, and has a low incidence of complications.

Elective surgical resection of HNPGL should be avoided in older and debilitated patients and in patients with an inability to tolerate specific cranial neuropathies.<sup>29–34</sup> Thus, particular attention must be paid to the patient’s swallowing function and pulmonary reserve as clinically significant dysphagia and aspiration might result from damage to or sacrifice of the lower cranial nerves.<sup>30,31,35</sup> As these lesions are typically benign and indolent, a trial of observation in these populations is reasonable and justified.<sup>33,36,37</sup> Vagal paragangliomas, in particular, pose a challenge as resection in most patients by default results in vagal nerve sacrifice and resultant vocal cord paralysis.<sup>38,39</sup> Surgical intervention on such lesions, should it occur, is generally only performed after the vocal cord is already immobile and is not done on bilateral lesions as bilateral vocal cord paralysis often leads to the need for tracheostomy.<sup>30</sup> Similar caution should be exercised in other scenarios in which bilateral or multifocal lateral skull base disease is present; an extant cranial neuropathy on the unoperated or previously operated side can be devastating for recovery should bilateral paralysis arise after intervention.<sup>29,30,33</sup> Exceptions can be made for patients with bilateral carotid or jugular paragangliomas in which a staged approach is taken and there is minimal morbidity from resection of the initial side (figures 1, 2). Primary lesions with distant metastasis and metastases themselves, although rare, should be operated on only in select circumstances; this intervention is generally done with palliative intent and should not cause more harm than relief.<sup>29</sup> Additional consideration should be given to the patient’s preference. There are no clear size cutoffs for when to refrain from operating on HNPGLs; we recommend that patients be referred to an experienced team.

**Recommendation 7**

We recommend intervention, which could include surgical resection, for patients with HNPGL that shows sustained growth or compression of vital head and neck structures and lesions that progress after radiation (grade strength=1; quality of evidence rating=2).



**Figure 3: Management of patients with SDHD HNPGLs with special emphasis on tumour multifocality**

Jugular paragangliomas are also known as jugulotympanic paragangliomas. Stereotactic radiosurgery is the preferred radiotherapeutic option. Radiotherapy refers to conventional fractionated external-beam radiation therapy and the term stereotactic radiosurgery includes linear accelerator-based radiosurgery, Gamma Knife, and CyberKnife. HNPGLs=head and neck paragangliomas. SDHD= gene encoding succinate dehydrogenase subunit D. TRT=targeted radionuclide therapy. \*For patients without preoperative neuropathy. †Some clinicians prefer to start on the side of the larger tumour.

### Recommendation 8

We recommend that for patients with any jugular and large carotid or vagal paragangliomas who are undergoing surgery, preoperative angiography with embolisation be considered. Balloon occlusion testing should be considered if internal carotid artery sacrifice with reconstruction is contemplated (grade strength=1; quality of evidence rating=2).

### Recommendation 9

We recommend an individualised, multidisciplinary approach for patients with multifocal HNPGLs, with particular attention to avoid compromise of important neurovascular structures. Staging resection is key to minimising potential morbidity (grade strength=1; quality of evidence rating=1).

### Evidence for recommendations 7–9

Indications for surgery include active signs and symptoms, such as compression of head and neck structures, sustained (especially more rapid) growth, intractable pain, progression after radiation, extensive cranial neuropathy, catecholamine secretion or a low likelihood of postoperative cranial neuropathies, and other sources of morbidity.<sup>30,32,39,40</sup> Young and otherwise healthy patients with small tumours are generally ideal surgical candidates, with high rates of local control.<sup>30</sup> The surgeon should evaluate the risk of new cranial neuropathies and make informed decisions with the patient and team. For example, for carotid paragangliomas, lesions with a higher Shamblin classification (ie, degree of involvement of the carotid artery) have a higher risk of cranial neuropathy.<sup>39</sup> Additionally, tumours more than 5 cm in size have

Service, Memorial Sloan Kettering Cancer Center, New York, NY, USA (Prof N Pandit-Taskar MD); Department of Endocrinology (Prof F Castinetti MD), Department of Endocrine Surgery (Prof F Sebag MD), and INSERM U1251 (Prof F Castinetti), Aix-Marseille University, Conception University Hospital, Marseille, France; Department of Nuclear Medicine, Aix-Marseille University, La Timone University Hospital, Marseille, France (Prof D Taïeb MD); Division of Diabetes, Endocrinology, and Metabolism, National Center

for Global Health and Medicine, Tokyo, Japan (A Tanabe MD); Department of Otolaryngology—Head and Neck Surgery, Icahn School of Medicine at Mount Sinai, New York, NY, USA (Z G Schwam MD, Prof G B Wanna MD); Third Department of Medicine, Department of Endocrinology and Metabolism of the First Faculty of Medicine, Charles University and General University Hospital in Prague, Prague, Czech Republic (Prof J Widimsky MD)

Correspondence to: Prof Karel Pacak, Section on Medical Neuroendocrinology, Eunice Kennedy Shriver National Institute of Child Health and Human Development, National Institutes of Health, Bethesda, MD 20892-1109, USA  
karel@mail.nih.gov

a higher cranial neuropathy rate (67%) than lesions smaller than 5 cm (14%).<sup>30,41</sup> When these rates are compared with the natural history of other HNPGs, new or progressive deficits are seen in 30–33% of patients.<sup>36,37,42</sup> Being able to compare the nerve deficit rates across methods is an important component of preoperative counselling and decision making. To standardise reporting and outcomes, jugulotympanic paragangliomas could be classified according to the Fisch<sup>43</sup> and Glasscock-Jackson staging systems.<sup>44</sup>

Additionally, anticipating the extent of resection and involving the appropriate surgical services is paramount. Collaboration with vascular surgery should occur any time there is a question as to the need for carotid artery sacrifice<sup>45</sup> and neurosurgery should be available for skull base lesions with intracranial extent. Carotid stenting or sacrifice with subsequent reconstruction should only be used in select circumstances and for patients with adequate collateral intracranial circulation.

The classic approach to patients with jugular paragangliomas requires overclosure of the ear canal and facial nerve mobilisation, resulting in facial paresis and substantial conductive hearing loss. To minimise morbidity, subtotal resection, particularly of large jugular paragangliomas with preservation of the lower cranial nerves, might be considered.<sup>32,37</sup>

Preoperative angiography with embolisation is recommended for all jugular, large (ie, >4 cm), or locally invasive carotid or vagal paragangliomas. Balloon occlusion testing is recommended for lesions that encase the internal carotid artery and in patients for whom carotid artery sacrifice and reconstruction are a remote possibility. The primary goal of preoperative embolisation of HNPGs is to help achieve a dry surgical field to visualise key neurovascular structures crucial for reducing surgical morbidity and increasing the probability of gross total resection.<sup>33,39,46</sup> Angiography and embolisation are not without risk, nor are they guaranteed to be reflective of the body's response to internal carotid artery disruption, and temporary or permanent cranial neuropathy could occur even with super-selective embolisation due to the migration of particles to the vasa nervorum of the affected nerves.

There is no simple algorithm that best addresses the therapeutic strategy in patients with multifocal HNPGs (figure 3).<sup>29</sup> An individualised approach is recommended, as is the use of an experienced interdisciplinary team that includes various surgical teams, endocrinology, radiation oncology, and speech and swallow therapy. The estimation of when and how to intervene is particularly difficult given that all lesions are not present simultaneously. The possibility of future metachronous lesions further complicates the clinical case.<sup>29</sup>

Important determinants of treatment include the patient's life expectancy, behaviour of the tumour, baseline neurological and cranial nerve status, swallowing function, and pulmonary reserve.<sup>29,30</sup> The overarching

goals of treatment should be to exercise appropriate restraint, minimise the risk of multiple or bilateral nerve deficits, and not compromise the major cerebral vasculature. In the instance of bilateral tumours, staging should be implemented to minimise bilateral, potentially devastating cranial neuropathies.<sup>29,30,39</sup> Although there is no wide consensus on special circumstances, some groups advocate resecting multiple head and neck tumours in a single stage if they are ipsilateral and anatomically close.<sup>29,39</sup> Regarding bilateral tumours, some authors recommend operating on the side with existing cranial neuropathies and observing or radiating the contralateral side to avoid bilateral nerve palsies. If no neuropathies exist preoperatively, resection of the smaller of the two lesions poses a lower risk to the cranial nerves. If there is no nerve deficit, the contralateral side could be subsequently attempted. If there is a postoperative deficit, the contralateral lesion should be observed or radiated.<sup>29,39</sup> Special consideration should be given to avoid baroreflex failure in patients with bilateral carotid paragangliomas and intracranial hypertension in patients with bilateral jugular paragangliomas. Resecting one side and staging resection of the contralateral tumour several months later can decrease these complications and allow for compensation.<sup>29</sup> If observation is chosen, median growth rates in these lesions could be as low as 1 mm per year with a median doubling time of 4.2–5.7 years<sup>37</sup> depending on the method of comparison (ie, linear measurements vs volumes) and the assumptions of the mathematical models used.

#### Recommendation 10

We recommend a thorough examination of the cranial nerves and laryngoscopy before and after surgical intervention or radiotherapy for patients with HNPG (grade strength=1; quality of evidence rating=2).

#### Recommendation 11

We recommend that in patients with postoperative facial nerve palsy, corneal protection is prioritised to avoid exposure keratitis or corneal abrasion (grade strength=1; quality of evidence rating=3).

#### Evidence for recommendations 10 and 11

Routine preoperative and postoperative screenings for cranial neuropathies are recommended, with a focused evaluation of the nerves at risk from surgical intervention. All patients should be evaluated for palsies of nerves VII–XII, measured by symmetric facial movement, audiogram, evaluation of swallow dysphagia, flexible bedside laryngoscopy,<sup>30</sup> and evaluation of palate rise, shoulder elevation, and tongue mobility. Additional facets of the neurological examination might be incorporated depending on the specific lesions.

New cranial neuropathies are rather common after surgical intervention of patients with HNPGs, with particularly high rates in jugular paragangliomas

with intracranial extension,<sup>47–49</sup> large or invasive carotid body paragangliomas,<sup>30,41</sup> and virtually all vagal paragangliomas. However, new or progressive deficits are also detected in 30–33% of patients with observed lesions.<sup>36,42</sup> Cranial neuropathies causing dysphagia, aspiration, or facial paralysis after HNPGLs resection might prolong hospitalisation and recovery and have a profound effect on quality of life.

### Patients with SDHD non-HNPGLs and pheochromocytomas

#### Recommendation 12

We recommend that functional PPGLs, which are predominantly retroperitoneal, are resected as an initial priority in patients with multifocal disease including HNPGLs (grade strength=1; quality of evidence rating=3).

#### Recommendation 13

We recommend that patients with non-HNPGL (retroperitoneal, pelvic, or thoracic) and pheochromocytoma are offered appropriate surgical consultation with an experienced surgeon with knowledge of this specific disease. Tumour resection should be considered when there are no absolute contraindications, especially when complete tumour removal is possible (grade strength=1; quality of evidence rating=3).

#### Recommendation 14

We recommend that there is a limited role for palliative debulking in patients with locally aggressive, large tumours with a high probability of incomplete surgical resection or in patients with metastatic disease, but this palliative debulking can be considered in patients who are not responsive to medical management or have debilitating sequelae, such as pain or mass effects that worsen the quality of life (grade strength=1; quality of evidence rating=2).

#### Evidence for recommendations 12–14

Carriers with SDHD pathogenic variants have a high incidence of multifocality and a thorough preoperative cross-sectional nuclear medicine evaluation should be performed for complete surgical planning. Biochemically positive PPGLs can be present in the context of pathogenic variants and are mostly related to retroperitoneal PPGLs. These tumours should be resected before other surgical interventions due to the risk of a perioperative hypertensive crisis (see recommendation 21).

The main objective of surgical resection for patients with SDHD PPGLs is to improve symptoms by removing the source of excess catecholamine secretion, preventing further tumour growth, and minimising the risk of metastatic disease. The current estimated rates of metastatic behaviour in patients with SDHD-associated PPGLs range between 4.5% and 7.7%.<sup>50–52</sup>

Pheochromocytoma treatment is typically surgical and often amenable via minimally invasive surgery. The

technical approach can be either anterior or posterior, depending on surgical expertise. There are no modalities to ensure the complete removal of the adrenal medullary tissue unless the entire gland is removed. Because of multifocality and potential for missing small tumours, a cortical-sparing technique might not be always ideal. These factors should be taken into consideration and weighed against the risk of potential adrenal insufficiency if contralateral tumour develops.

An open approach is recommended rather than a laparoscopic approach for most patients with primary SDHD PPGLs when the size is more than 5 to 6 cm due to the need to assess locoregional nodal disease.<sup>53,54</sup>

Retroperitoneal extra-adrenal SDHD and other paragangliomas can be locally invasive with major vessel involvement of the inferior vena cava, aorta, renal vein, and superior mesenteric artery or vein. When technically possible, complete resection could require vascular reconstruction. In a retrospective study including 29 patients with paragangliomas and major blood vessel involvement, the authors report that overall survival was higher in patients who underwent complete tumour resection than in patients who underwent only medical management.<sup>55</sup> No prospective clinical trials have directly compared laparoscopic or robotic versus open adrenalectomy for patients with paragangliomas. A few case reports have shown the effectiveness and safety of laparoscopic surgery for patients with small tumours and no invasion into any surrounding structure.<sup>56</sup> The difficulty lies in the inadequacy of the preparation for intraoperative identification of tumours that encroach on surrounding structures. These tumours are more likely to be adherent without distinguishable tissue planes and require proximal and distal vascular control, multiple vessel ligation, and potential vascular reconstruction. Safe resection requires manual assessment, palpation, careful retraction, and the ability to cross-clamp large vessels. Common locations of extra-adrenal SDHD PPGLs include the bladder, heart, and the area between or above the aortic bifurcation (eg, the inferior mesenteric artery [the organ of Zuckerkandl]). Patients with paragangliomas that arise in the pelvis can have unique presentations and require special attention during surgery; given the proximity of these tumours to the parasympathetic region, especially in males, subsequent sexual dysfunction should be considered and appropriately discussed with a patient. Additionally, sexual dysfunction has been reported as a potential complication after other pelvic and aortic surgeries, which should be discussed, especially for patients with a paraganglioma located in the organ of Zuckerkandl.

The management of patients with thoracic SDHD paragangliomas is complex and technically challenging. Complete anatomical involvement of the tumour should be determined before resection. En bloc removal provides the best long-term outcome and freedom from recurrence. Cardiac SDHD paragangliomas, although rarely malignant, often involve cardiac structures such as the left



atrium and ventricle, pulmonary artery, and coronary arteries without a distinct border.<sup>57</sup> Imaging often underestimates the actual involvement at the time of operative resection. Multiple cardiac chamber reconstruction might be required with coronary artery bypass if coronary vessels are involved, and in rare cases, cardiac autotransplantation might be required. En bloc resection of the tumour is required in all patients. For patients with thoracic, para-aortic, and pelvic paragangliomas, open operations allow for the manual interpretation of two important aspects of the technical procedure: assessment of the extent of vascular wall invasion and for the presence of lymph node disease. Interpretation of imaging and anticipation of invasion or adherence to vessels are paramount in planning. The reactive formation, particularly in chest structures, seems to be locally more difficult and requires specialised cardiac surgical expertise.

On occasion, *SDHD* paragangliomas might occur in a location where surgical resection cannot be safely accomplished and other therapies are required to control both hormone hypersecretion and tumour growth.

A perioperative haemodynamic management plan should be devised to prevent instability and complications during the perioperative period. Beyond pharmacological preparation, this plan requires good communication among multiple specialties, including the availability of experienced anaesthesiologists. Excellent intraoperative communication with the surgical team and understanding the half-life and effects of pharmacological agents are important factors in the management of intravascular volume, heart rate, and blood pressure.

Palliative debulking rarely grants pharmacological independence; one study showed that aggressive debulking for biochemical management alone might not be effective as only seven of 24 patients had a partial biochemical response, with six of seven tumours recurring within 12 months.<sup>58</sup> The authors also reported that resection can selectively relieve some tumour-associated symptoms and signs, such as pain.

### Therapeutic radiation for patients with *SDHD* HNPGLs

#### Recommendation 15

We recommend therapeutic radiation as a treatment for patients with *SDHD* HNPGLs, more specifically for patients with radiologically progressive or symptomatic *SDHD* HNPGLs. Older patients with multiple comorbidities or highly complex surgical resectability of tumours with cranial nerve palsies, such as vagus nerve involvement and contralateral lower cranial neuropathies, are strong candidates for primary therapeutic radiation (grade strength=1; quality of evidence rating=2).

#### Recommendation 16

We recommend therapeutic radiation for patients with post-surgical residual and recurrent *SDHD* HNPGLs with progressive disease (grade strength=1; quality of evidence rating=2).

#### Evidence for recommendation 15 and 16

We recommend a multidisciplinary discussion on therapeutic radiation for each patient with *SDHD* HNPGLs (figure 2). In this guideline, we use the term therapeutic radiation to refer to both radiotherapy (ie, conventional fractionated external-beam radiation therapy) and stereotactic radiosurgery. Therapeutic radiation, specifically stereotactic radiosurgery, should be considered the primary treatment for all patients with *SDHD* HNPGLs, including in older patients, those with clinically significant comorbidities, or those with cranial neuropathies.<sup>59-61</sup> Hypofractionated stereotactic radiosurgery might be preferred in patients with contralateral lower cranial neuropathies or multifocal disease involving the bilateral vagal nerves as it is an effective method to preserve cranial nerves, even in large tumours.<sup>62,63</sup>

Therapeutic radiation should be considered as a secondary treatment for progressive lesions after surgical resection<sup>30</sup> or planned as an adjuvant treatment 8–12 weeks after subtotal resection.<sup>62</sup> Single-fraction stereotactic radiosurgery is most effective in smaller tumours (ie, maximum diameter <3 cm)<sup>63</sup> but has also shown efficacy in residual tumours with a volume 4 cm<sup>3</sup> or less. These series found a median marginal tumour dose of 14 Gy with 80% of patients showing tumour stability and 20% with shrinkage and no clinical progression.<sup>64</sup> Gamma Knife (Elekta; Stockholm, Sweden) radiosurgery in patients with post-surgical jugulotympanic paragangliomas also showed volumetric tumour control in 94.8% of patients and clinical control in 91.4% of patients.<sup>65</sup>

#### Recommendation 17

We recommend stereotactic radiosurgery as the primary or complementary treatment for surgical resection. Conventional radiotherapy could be recommended for patients with larger *SDHD* HNPGLs (grade strength=1; quality of evidence rating=3).

#### Evidence for recommendation 17

Radiation therapy is a treatment method that works with ionising radiation, generating free radicals that cause breaks in DNA and cell death through apoptosis and via mitotic cell death.<sup>61,66</sup> Conventional fractionated external beam radiation therapy is typically delivered as intensity-modulated radiation therapy (IMRT). IMRT has been reported to have control rates and toxicities similar to those of stereotactic radiosurgery.<sup>65,67,68</sup> Compared with traditional multifraction IMRT occurring over several weeks, stereotactic radiosurgery is one to five fractions. Each fraction is a single daily fraction, thereby having generally no more than 5 days of stereotactic radiosurgery treatment for the same efficacy of radiation therapy compared with IMRT. Furthermore, stereotactic radiosurgery has several advantages over IMRT. First, stereotactic radiosurgery uses larger doses per fraction which might have a therapeutic advantage for slower growing tumours, such as HNPGLs. Second, stereotactic

radiosurgery also provides submillimetre accuracy of the tumour target with a steep dose gradient, minimizing radiation exposure to nearby critical structures. Single-fraction stereotactic radiosurgery is considered most effective in smaller tumours (ie, maximum diameter <3 cm) and has also been shown to be equally efficacious, with toxicity rates similar to or lower than those of hypofractionated radiotherapy.<sup>63,69</sup>

There are multiple equivalents of stereotactic radiosurgery, such as linear accelerator, Gamma Knife, and CyberKnife (Accuray; Sunnyvale, CA, USA) being the most common.<sup>70</sup> A meta-analysis that examined radiosurgical treatment of patients with jugular paragangliomas showed that Gamma Knife, linear accelerator, and CyberKnife technologies all exhibited similarly high rates of tumour control (95%) and clinical control (97%) across all studies.<sup>71</sup>

A meta-analysis of 15 studies reviewing the treatment of patients with jugular paragangliomas with stereotactic radiosurgery as the primary treatment showed tumour control in 92% of patients, symptom control in 93% of patients, and complications in 8% of patients.<sup>72</sup> The analysis also showed that smaller tumour volumes predicted symptomatic improvement. The North American Gamma Knife Consortium collated the outcomes of eight Gamma Knife radiosurgical centres that had treated patients with jugular paragangliomas with a median tumour margin dose of 15 Gy (n=132, 134 procedures) and showed actuarial tumour control of 88% 5 years after radiosurgery. Improvement in pre-existing cranial nerve deficits was observed in 11% of patients, new or progressive cranial neuropathies were seen in 15%, and no mortality was noted (appendix p 2).<sup>73</sup> In other smaller series of patients with jugular paragangliomas, tumour control was noted to be 94.7–100%.<sup>74–76</sup> Additionally, in previous small series reports, linear accelerator radiosurgery treatment of patients with jugular paragangliomas showed tumour control rates of 91–100%.<sup>77–79</sup> A long-term series of jugular paragangliomas treated with frameless linear accelerator-based stereotactic radiosurgery over nearly two decades showed a 7-year progression-free survival of 97.0% of patients and grade 1 and 2 toxicities in 7.7% of patients (Common Terminology Criteria for Adverse Events system).<sup>80</sup>

Because *SDHD* paragangliomas of the carotid body are the most common type of HNPGLs, surgical resection is the most common treatment. Up to now, only one systematic review has compared the results of surgical resection to the results of IMRT (not only patients with *SDHD* pathogenic variants).<sup>81</sup> In a systematic review on management of carotid body paragangliomas, long-term tumour control was noted in 120 (94.5%) of 127 IMRT patients and 1846 (93.8%) of 1968 surgical patients. However, surgically induced cranial neuropathies are four times more common than those induced by IMRT.

In a meta-analysis examining treatment outcomes for patients with vagal paragangliomas, local tumour control

rates were similar between surgery and therapeutic radiation (93.3%), with a mean follow-up of 86.7 months.<sup>61</sup> Radiation-induced malignancy rates have been historically difficult to assess because of variability in follow-up, rarity of HNPGLs, and varying methods of radiotherapeutic treatment.<sup>82</sup> The Mayo Clinic reviewed the institutional data of all HNPGLs patients who received either external beam radiation therapy or stereotactic radiosurgery and found no radiation-induced malignancy.<sup>83</sup> These findings are consistent with the historical risk of 0.28%<sup>84</sup> and a publication indicating that stereotactic radiosurgery is likely to have a lower risk of radiation-induced malignancy than traditional external beam therapy because of a lower median dose.<sup>85</sup>

### Therapeutic radiation for patients with *SDHD* non-HNPGLs

#### Recommendation 18

We suggest considering therapeutic radiation for patients with symptomatic or progressive chest, abdomen, and pelvis *SDHD* paragangliomas that cannot be resected (grade strength=2; quality of evidence rating=1).

#### Evidence for recommendation 18

Literature to support the role of therapeutic radiation in the treatment of patients with paragangliomas below the neck is scarce because these tumours are generally managed with surgical resection. Radiation can provide high rates of local control for patients with advanced and unresectable paragangliomas to both primary and metastatic sites.<sup>86–88</sup> Although dose and fractionation data can be extrapolated from the HNPGL literature, radiation to the chest and abdomen has unique considerations, including respiratory motion and interfraction deformation of anatomy and organs at risk. Higher radiation doses have been associated with improved local control.<sup>86</sup> The use of advanced radiation technologies, including IMRT and stereotactic body radiotherapy with adequate motion management, can allow safe dose escalation in the setting of radiosensitive structures, such as the small bowel. Published series on radiation for patients with non-HNPGLs have used standard fractionation (1.8–2.0 Gy per fraction) or fractionated stereotactic ablative radiotherapy rather than single fraction stereotactic radiosurgery, as is commonly used in patients with HNPGLs.

See Online for appendix

### Medical management of patients with *SDHD* PPGLs

#### Recommendation 19

We recommend the use of  $\alpha$ -adrenoceptor blockers as medical treatment for the management of norepinephrine-associated manifestations (grade strength=1; quality of evidence rating=2).

#### Recommendation 20

We recommend avoiding the use of medications that might elicit a catecholamine crisis in patients with catecholamine-producing *SDHD* PPGLs who do

not receive appropriate adrenoceptor blockade (grade strength=1; quality of evidence rating=1).

#### Recommendation 21

We recommend the use of  $\alpha$ -adrenoceptor blockers before any surgical and non-surgical treatment interventions in patients with *SDHD* PPGLs showing norepinephrine production (grade strength=1; quality of evidence rating=2).

#### Recommendation 22

We do not recommend the use of medical treatment before interventions for patients with exclusively dopamine-producing *SDHD* PPGLs (as indicated by isolated elevation of plasma methoxytyramine; grade strength=1; quality of evidence rating=1).

#### Evidence for recommendations 19–22

Preoperative biochemical screening is mandatory to avoid rare but catastrophic perioperative complications in patients treated surgically, regardless of the presence of symptoms and signs. Patients with norepinephrine-producing *SDHD* PPGLs should be treated with  $\alpha$ -adrenoceptor blockade before any therapeutic intervention. Norepinephrine production is defined and recognised by an elevation of normetanephrine in the plasma, urine, or both. Some patients also have concurrent elevation of norepinephrine in the plasma or urine. Tumours displaying norepinephrine production, as reflected by elevated normetanephrine, require pretreatment.<sup>89</sup>

In the event of tachycardia during  $\alpha$ -adrenoceptor blockade, a  $\beta$ -adrenoceptor blocker could be added. Metyrosine, which inhibits tyrosine hydroxylase and thereby catecholamine biosynthesis, can be used as an add-on drug when available. Monotherapy with non-selective  $\beta$ -adrenoceptor blockers can elicit hypertension and is contraindicated. The exclusive production and subsequent secretion of dopamine by HNPGLs is unlikely to provoke any substantial haemodynamic effects.<sup>90</sup>

In rare instances, patients with larger dopamine-only producing *SDHD* PPGLs, or in isolated metastatic disease with overwhelming dopamine excess, are typically normotensive or even hypotensive.<sup>91–93</sup> Therefore, in patients with dopamine-only *SDHD* HNPGLs, management with  $\alpha$ -adrenoceptor blockers before any type of treatment is not advised.

Contrastingly, preoperative adrenoceptor blockade should be considered in patients with norepinephrine-producing *SDHD* HNPGLs. It should be ascertained that there are no additional sympathetic PPGLs as a source of norepinephrine for which surgical treatment might be prioritised. In a single-centre series of 152 patients with 182 HNPGLs,<sup>94</sup> 14 (9.2%) of patients were deemed clinically significant secretors of catecholamines. This subgroup was treated with  $\alpha$ -adrenoceptor and  $\beta$ -adrenoceptor blockade before

surgery, whereas pretreatment was omitted in 13 patients with clinically insignificant increases of normetanephrine concentrations. A review of anaesthesia records showed no instances of haemodynamic instability requiring vasopressors, aggressive fluid resuscitation, or antihypertensives in the small number of patients with clinically insignificant elevations of catecholamines. Whether these latter patients should also receive perioperative blockade remains debatable.

To our knowledge, a catecholamine crisis elicited by radiation therapy or systemic therapy for patients with *SDHD* PPGL is not common. Nevertheless, in the event of norepinephrine production usually reflected by elevated plasma normetanephrine but not necessarily plasma norepinephrine, treatment with appropriate adrenoceptor blockade should be considered before these interventions. Therefore, patients should be carefully monitored before, during, and after any procedure, and vigorously treated in instances of haemodynamic instability. Postoperative baroreflex failure is associated with surgery and radiotherapy for patients with *SDHD* bilateral carotid body paragangliomas; thus, haemodynamic complications should be carefully considered.<sup>95</sup>

To control the symptoms and signs of catecholamine excess and to prevent complications of therapeutic interventions,  $\alpha$ -adrenoceptor blockers are widely used as the primary treatment. Both  $\alpha$ 1-selective and competitive adrenoceptor blockers, such as doxazosin, prazosin, or terazosin, and the non-selective and non-competitive  $\alpha$ 1- and  $\alpha$ 2-adrenoceptor blocker phenoxybenzamine, are used. These drugs are typically started at least 7–14 days preoperatively with gradually increasing doses until blood pressure targets are achieved.<sup>96</sup> The efficacy of phenoxybenzamine and doxazosin has been investigated in PRESCRIPT, the first randomised controlled trial on presurgical treatment in patients with PPGLs.<sup>97</sup> The primary endpoint was defined as the total time a patient's blood pressure was outside a predefined range intraoperatively. Although there was no difference between the two drugs, there was less intraoperative haemodynamic instability with phenoxybenzamine. Additionally, metyrosine and calcium channel blockers can be used.<sup>98</sup> Calcium channel blockers can be used either as an adjunct to  $\alpha$ -adrenoceptor blockers to control refractory hypertension or as presurgical monotherapy in patients with typical, mildly elevated blood pressure values or patients with severe orthostatic hypotension when an  $\alpha$ -adrenoceptor blocker is used. Tachycardia is treated with either non-selective  $\beta$ -adrenoceptor blocker or, preferably,  $\beta$ 1-selective adrenoceptor blocker. To reduce the risk of preoperative orthostatic hypotension and postoperative hypotension, common practice is to give a high-sodium diet, administer 1–2 L of saline 24 h before surgery, and use compressive stockings.<sup>98</sup>

### Surveillance of patients with non-metastatic *SDHD* PPGLs

#### Recommendation 23

We suggest that treatment-naive patients with *SDHD* PPGLs with no compelling indication for treatment are imaged at 3–6 months after diagnosis and again at 1 year after diagnosis to document the disease course and decide on treatment options (grade strength=2; quality of evidence rating=1).

#### Recommendation 24

We suggest that patients who have been surgically treated for primary functional PPGLs undergo measurement of plasma or urine metanephrines and plasma methoxytyramine by 8 weeks post-treatment. Imaging could be done at 3–6 months for such patients, as well as for patients in whom the PPGL was not functional (grade strength=2; quality of evidence rating=1).

#### Evidence for recommendation 23 and 24

After patients with *SDHD* PPGLs have received a diagnosis, approximately 50% of patients undergo treatment and the remaining undergo surveillance.<sup>99</sup> Most patients with functional HNPGLs are recognised by an elevation of plasma or urinary normetanephrine and methoxytyramine, even if they do not have catecholamine-related signs and symptoms. Non-functionality is defined as normal plasma and urinary normetanephrine and methoxytyramine or as the sum of plasma metanephrines that is too low according to tumour size.<sup>100</sup>

For patients with functional *SDHD* PPGLs, measurement of metanephrines should be performed 2–8 weeks postoperatively.<sup>4,101</sup> In patients with non-functional tumours who have completely normal preoperative biochemistry, imaging should be done at 3–6 months to check whether surgery was complete. Repeat imaging should be done 3–6 months after any therapy.

In patients with non-metastatic (ie, M0) *SDHD* paraganglioma, whole-body imaging should be repeated at 3–6 months postoperatively because there are no clinically reliable predictors of metastasis. This advice is particularly important in patients with large *SDHD* PPGLs. If the disease is stable, annual imaging findings should be considered. The estimated median volume growth rate is 10–12% per year<sup>102,103</sup> despite no progression in 60% of *SDHD* paragangliomas.<sup>103</sup>

#### Recommendation 25

We recommend that patients with *SDHD* PPGLs, regardless of surgical history, undergo annual blood pressure measurements, clinical assessment, and biochemical measurements to detect new PPGLs, metastases, or progression (grade strength=1; quality of evidence rating=2).

#### Recommendation 26

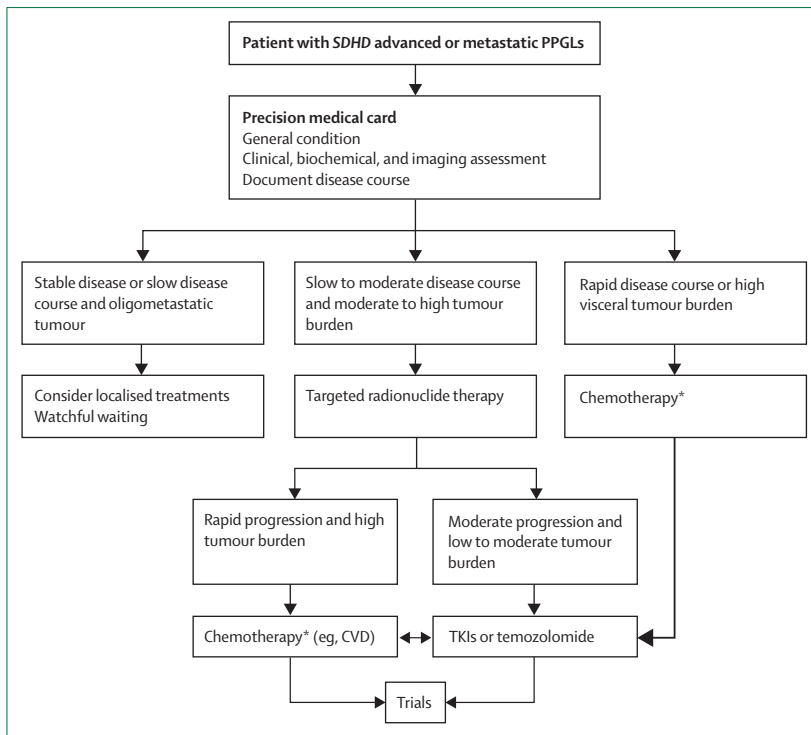
We recommend that a whole-body MRI is performed at least every 2–3 years to detect new *SDHD* PPGLs, metastases, or progression. Initially, more frequent imaging follow-up is recommended for patients with unoperated PPGLs or metastases (grade strength=1; quality of evidence rating=2).

#### Recommendation 27

We suggest the use of SSTR PET–CT on an individual basis to screen for disease progression in patients with non-metastatic PPGLs (grade strength=2; quality of evidence rating=1).

#### Evidence for recommendation 25–27

Overall, the prognosis of patients with *SDHD* PPGLs remains excellent, with no substantial increase in mortality observed in a Dutch sample of *SDHD* pathogenic variant carriers.<sup>104</sup> However, patients with *SDHD* are at risk of developing recurrence, metastasis, or progression. Therefore, patients should receive lifelong follow-up and the quality of life should be monitored. In one meta-analysis, the pooled risk for metastasis was 4% for patients with *SDHD* paragangliomas versus 13% for patients with *SDHB* paragangliomas.<sup>52</sup> A postoperative analysis of 47 *SDHx* patients (33 patients with *SDHD*) followed for a median of 2.7 years showed that 5 patients (11%) developed local recurrence.<sup>99</sup> Disease penetrance was high in the presence of *SDHD* paragangliomas, but the occurrence of metachronous tumours might be delayed.<sup>105–107</sup> A study that included 93 patients with *SDHD* HNPGLs found that a diagnosis of biochemically positive PPGLs was made in 30% of patients (with five glomus paragangliomas).<sup>107</sup> The diagnosis was made at the initial screening in 63% of patients, whereas in 37% of patients the PPGLs were detected after repeated biochemical screening. In this study, only patients in whom urinary excretion of catecholamines or metabolites was above the reference limit were subjected to imaging.<sup>107</sup> In a follow-up study performed over 22 years, new paragangliomas were found in 73% patients, most of which were HNPGLs. Eight patients (4%) developed pheochromocytomas, and 12 (5%) developed sympathetic paragangliomas.<sup>108</sup> The diagnosis of a biochemically positive lesion is crucial to avoid risks related to catecholamine crises. Therefore, an annual assessment of plasma metanephrines in the follow-up of patients with *SDHD* should be mandatory.<sup>109</sup> To limit radiation exposure to patients, whole-body MRI or multiple-standard MRIs should be performed first.<sup>109,110</sup> If possible, and on the basis of current clinical assessment, the administration of gadolinium-based contrast agents could be avoided due to the risk of deposition in the brain. PET–CT can be performed every 3–5 years on an individual basis to screen for multifocality and metastasis.<sup>111</sup>



**Figure 4: Management of patients with metastatic SDHD PPGLs**  
PPGLs= phaeochromocytomas and paragangliomas. SDHD=encoding succinate dehydrogenase subunit D. TKIs=tyrosine kinase inhibitors. \*In patients for whom chemotherapy with cyclophosphamide, vincristine, and dacarbazine (CVD) is not tolerated, not wanted by the patient, or if there are contraindications to CVD, tyrosine kinase inhibitors (eg, sunitinib) or temozolomide can be used as alternative agents while carefully evaluating their adverse effects.

### Surveillance and management of patients with advanced or metastatic SDHD PPGLs

#### Recommendation 28

We recommend the use of SSTR PET–CT to evaluate disease progression in patients with metastatic PPGL (grade strength=1; quality of evidence rating=2).

#### Recommendation 29

We recommend characterising disease progression in the setting of an interdisciplinary tumour team with clinical information, biochemistry, and imaging (grade strength=1; quality of evidence rating=2).

#### Recommendation 30

We recommend active surveillance for patients with asymptomatic metastatic lesions (or stable symptoms and signs), or stable or very slow-growing metastatic lesions (ie, stable disease for >12 months), particularly in patients with low tumour burden (grade strength=1; quality of evidence rating=2).

#### Recommendation 31

We recommend considering local therapies (eg, surgery, therapeutic radiation, and interventional radiology procedures) for patients with symptomatic oligometastatic SDHD PPGL without contraindication

that cannot be otherwise controlled or in those with lesions at risk of severe local complications (grade strength=1; quality of evidence rating=2).

#### Recommendation 32

We recommend targeted radionuclide therapy as the first-line systemic therapy for SSTR-positive or  $^{123}\text{I}$ -MIBG-positive metastatic tumours with moderate to high tumour burden and without evidence of rapidly progressive disease (grade strength=1; quality of evidence rating=2).

#### Recommendation 33

We recommend chemotherapy as the first-line therapy in patients with rapid progression or high visceral tumour burden and possibly as second-line therapy if there is rapid progression after other systemic therapies (grade strength=1; quality of evidence rating=2). In patients for whom chemotherapy with cyclophosphamide, vincristine, and dacarbazine (CVD) is not tolerated, not wished for by the patient, or if there are contraindications to CVD, tyrosine kinase inhibitors (eg, sunitinib) or temozolomide can be used as alternative agents while carefully evaluating their adverse effects.

#### Recommendation 34

We recommend either tyrosine kinase inhibitors (eg, sunitinib; grade strength=1; quality of evidence rating=3) or temozolomide (grade strength=1; quality of evidence rating=2) in patients with progressing tumours who are not eligible for peptide receptor radionuclide therapy (PRRT) or  $^{131}\text{I}$ -MIBG or following progression to radionuclide therapy or CVD.

#### Evidence for recommendations 28–34

Assessment of disease progression mainly relies on anatomical and functional imaging in selected patients (preferably PET–CT with somatostatin analogues). The Consensus on Molecular Imaging and Theranostics in Neuroendocrine Tumors has proposed that the detection of new lesions, after the exclusion of pitfalls, by functional imaging with the same tracer can be considered sufficient to define progression.<sup>112</sup> However, data are too scarce to provide any recommendation in the setting of patients with metastatic SDHx PPGLs.

In a study that included therapy-naïve patients with metastatic PPGLs, 87% of patients who experienced progressive disease at one year had progressive disease at baseline.<sup>113</sup> Therefore, an imaging assessment 3 months after the diagnosis of metastatic disease might be recommended. As SDHD PPGL metastases are often associated with slow progression, active surveillance might be reasonable for patients with low tumour burden (figure 4).

Surgery for the primary tumour (see recommendation 14) and locoregional treatments should be considered on an individual basis in an interdisciplinary tumour

board meeting. Patient preparation was recommended for all local interventions, similar to that for surgery.

The European Society of Hypertension recommends targeted radionuclide therapy for patients with slow or moderate disease progression with a moderate tumour burden (figure 4).<sup>4</sup> Targeted radionuclide therapy of metastatic or inoperable PPGLs is a palliative treatment with patients rarely showing complete responses. The goals of therapy are the stabilisation and regression of progressive, metastatic, or inoperable tumours, amelioration of symptoms, and control of disease-specific cardiovascular effects. The choice between the two systemic radiotherapeutic options, PRRT or <sup>131</sup>I-MIBG, is mainly dependent on the imaging phenotypes seen on SSTR PET-CT and <sup>123</sup>I-MIBG scintigraphy.<sup>114</sup> A radiopharmaceutical is favoured if it is superior in targeting most or all of a patient's lesions. If both radiopharmaceuticals localise similarly, other issues related to toxicity and morbidity should be considered. Additional issues to be considered are reimbursement and inpatient versus outpatient therapies. PRRT is favoured when the patient has a low bone marrow reserve or baseline leukopenia or thrombocytopenia due to a lower potential for bone marrow toxicity, especially compared with 18.5 GBq <sup>131</sup>I-MIBG. Owing to the less differentiated nature of *SDHD* PPGLs and their usual parasympathetic origin, PRRT is used more than <sup>131</sup>I-MIBG therapy in this setting. The results from clinical studies investigating PRRT, low-specific and high-specific activity <sup>131</sup>I-MIBG therapy, and potential side effects are summarised in the appendix (pp 3–7). The disease control rate (DCR) for patients with PPGLs with PRRT in most retrospective studies was at least 80%, and the progression-free survival (PFS) was 17–39 months. In the largest meta-analysis of 234 pooled patients with PPGLs treated with PRRT, a high DCR of 90% was reported.<sup>115</sup> However, only 166 (74%) of 225 patients showed progressive disease at treatment initiation, which makes drawing conclusions complicated. Another meta-analysis of 201 pooled patients with PPGLs treated with PRRT reported an overall response rate of 25% and DCR of 84%.<sup>116</sup>

For rapidly progressing disease or high visceral tumour burden, chemotherapy with cyclophosphamide, vincristine, and dacarbazine (CVD) is the recommended first-line therapy.<sup>4,117–123</sup> CVD should be the second-line therapy following progression to targeted radionuclide therapy in patients with rapid progression or high visceral tumour burden (figure 4).

Targeted systemic therapies (ie, tyrosine kinase inhibitors [TKIs]) or temozolomide should be considered following progression after targeted radionuclide therapy or subsequent progression after CVD (figure 4). For sunitinib, the first randomised, placebo-controlled clinical trial (FIRST-MAPP [NCT01371201]; 78 patients) showed a DCR of 35.9% over 12 months and a clinically significant improvement in median PFS in the sunitinib

group (8.9 months) compared with the placebo group (3.6 months).<sup>124</sup> At the time of writing, the results of the FIRST-MAPP trial have yet to be published in a peer-reviewed journal. Another prospective clinical trial including 25 patients investigated sunitinib in patients with PPGLs and reported a partial or complete response rate in 3 (13%) of 23 patients, stable disease in 16 (70%) of 23 patients over 3 months (DCR 83%), and a DCR of 61% over 6 months. All patients with *SDHx* PPGLs showed partial response or stable disease.<sup>125</sup>

For temozolomide, two retrospective studies indicate efficacy in patients with metastatic PPGLs, including patients with *SDHx* pathogenic variants: one study of 15 patients, including 10 patients with *SDHB*, reported an overall DCR of 80% with a partial response rate of 33% (according to RECIST plus PERCIST), with all responders being carriers of *SDHB* pathogenic variants (overall PFS=13.3 months, with a significantly longer PFS of 19.7 months in *SDHB* pathogenic variants carriers vs 2.9 months in non-*SDHB* pathogenic variants carriers).<sup>126</sup> Another retrospective study of 17 patients (one patient with a *SDHA* pathogenic variant, one patient with a *SDHC* pathogenic variant, and seven patients with *SDHB* pathogenic variants; 15 patients evaluable by RECIST; and one *SDHC* partial response and one *SDHB* partial response) reported a DCR of 67% (partial response in 40% of patients; stable disease in 27% of patients; overall median PFS 2.2 years, median PFS 1.3 years for carriers of *SDH* pathogenic variants, and median PFS 5.5 years for non-carriers).<sup>127</sup> Thus, whether temozolomide has a specific benefit for *SDH* pathogenic variant carriers remains unclear. Other studies are described in the appendix (pp 3–7).

TKIs might worsen hypertension; thus, careful follow-up and aggressive antihypertensive dosage adjustment

#### Search strategy and selection criteria

The steering group members were asked to conduct their own literature searches in PubMed using search strategies with controlled vocabulary MeSH terms and keywords for the condition of interest and section topic. Searches were limited to articles published from 2000 to 2022. The search strategies combined the term paraganglioma and the following terms into separate searches for each section topic: "Succinate Dehydrogenase", "SDHD", "positron emission tomography", "PET/CT", "Radiotherapy"[MeSH], "Endocrine Surgical Procedures"[MeSH], "General Surgery"[MeSH], "Radiofrequency", "Chemoembolization", "Cryoablation", "Thermal Ablation", "Surveillance", "Follow-up", "Chemotherapy", "Sunitinib", "Temozolomide", "Immunotherapy", "Peptide receptor radionuclide therapy", "PRRT", "DOTATATE", "DOTATOC", "Somatostatin", and "MIBG". During screening of the results, articles were excluded if they were animal studies, case reports, or case series, and not published in English.

before and during TKI therapy are needed. In patients with progression following sunitinib or temozolomide treatment, an alternative treatment can be used. Following the progression of both approaches, inclusion in a clinical trial should be investigated. Similar to other neuroendocrine tumours, antiresorptive therapies are recommended for patients with *SDHD* PPGL with widespread bone metastases.<sup>128</sup>

## Conclusion

All patients with *SDHD* pathogenic variants should be managed by an expert interdisciplinary team and require clinical, endocrine, and imaging assessments to screen and diagnose PPGL at a whole-body scale. This screening can be achieved by a combination of morphological imaging and, in most patients, by SSTR PET-CT. In patients with HNPGL, long-term preservation of cranial nerve function is a main concern when considering treatment. Therapeutic radiation can complement or be an alternative to surgery in some situations. Life-long surveillance is important to screen for new PPGL, disease progression, and metastases. The management of metastatic PPGL mainly relies on hormonal secretion, disease extension, and pace of growth. This guideline should help to standardise high-quality care for patients with PPGLs with *SDHD* pathogenic variants.

### Contributors

DT, JWML, and KP were the chairpersons of the guideline and organised and oversaw all procedures. LM was the project manager. The steering committee members, GBW, MA, CL-L, NDP, SN, LA, HJLMT, ZGS, ALE, ML, ELP, and LV, conducted the literature search and wrote the original draft of the manuscript. The rating group members, IB, RTC, FC, RC-B, EPMC, RRdK, JDR, GE, HKG, A-PG-R, AG, AI, JCJ, AJ, MNK, HPMK, ERM, DM, LBM-A, OM, MN, NN, NP-T, FS, AT, and JW participated in the rounds of voting. All authors took part in the discussions and provided comments on the narrative form of the recommendations and evidence sections. The steering committee members revised the manuscript according to votes and comments. All authors approved the final manuscript for submission.

### Declaration of interests

DT has received personal honoraria for lectures and consulting and support for meeting attendance from Advanced Accelerator Applications and Novartis. CL-L has received personal honoraria for lectures and support for meeting attendance from Ipsen. SN has received research grant to their institution from German Research Foundation. LA has received personal honoraria for lectures from Servier and Ipsen. ALE has received fees for consulting from WL Gore and fees for participation on an advisory board from Artivion. ML has received research grants to their institution from Arbor, Bristol Myers Squibb, Accuray, Biohaven, and Urogen; honoraria for research consulting from VBI Vaccines, InCephalo Therapeutics, Merck, Pyramid Bio, Insightec, Biohaven, Sanianoia, Hemispherian, Novocure, Noxxon, InCando, Century Therapeutics, and CraniUs; honoraria for non-research consulting from Stryker; is a shareholder of Egret Therapeutics; holds patents for the combination of immunotherapy and local chemotherapy to treat malignancies (10864180) and focused radiation to augment immune-based strategies against cancer (9132281); and is a member of the data and safety monitoring board of Cellularity. ELP has received fees for participation on an advisory board from Vysioneer. RTC has received personal honoraria for lectures from Novartis, support for meeting attendance from Ipsen, and serves as a board member for the Society for Endocrinology clinical committee and the UK and Ireland Neuroendocrine Tumour Society clinical committee. JKL has received honoraria for lectures from and is a consultant for Stryker. ERM has

received fees for consulting and personal honoraria for lectures from MSD. NN has received an intramural research grant from the National Institutes of Health. NP-T has received research grants to their institution from Innervate, Clarity pharma; fees for consulting from Progenics, Lantheus, and Innervate Lifesciences. NP-T is a member of the data and safety monitoring board of Progenics and Lantheus, and serves as a board member for Society of Nuclear Medicine and Molecular Imaging. All other authors declare no competing interests.

### Acknowledgments

We thank Alicia A Livinski of the National Institutes of Health Library (Bethesda, MD, USA) for assistance with this project and manuscript. This work was supported by the Intramural Research Program of the National Institutes of Health Eunice Kennedy Shriver National Institute of Child Health and Human Development.

### References

- Mannelli M, Canu L, Ercolino T, et al. DIAGNOSIS OF ENDOCRINE DISEASE: *SDHx* mutations: beyond pheochromocytomas and paragangliomas. *Eur J Endocrinol* 2018; **178**: R11–17.
- Burnichon N, Mazzella JM, Druil D, et al. Risk assessment of maternally inherited *SDHD* paraganglioma and pheochromocytoma. *J Med Genet* 2017; **54**: 125–33.
- Atkins D, Best D, Briss PA, et al. Grading quality of evidence and strength of recommendations. *BMJ* 2004; **328**: 1490.
- Lenders JWM, Kerstens MN, Amar L, et al. Genetics, diagnosis, management and future directions of research of pheochromocytoma and paraganglioma: a position statement and consensus of the Working Group on Endocrine Hypertension of the European Society of Hypertension. *J Hypertens* 2020; **38**: 1443–56.
- Lenders JW, Duh QY, Eisenhofer G, et al. Pheochromocytoma and paraganglioma: an endocrine society clinical practice guideline. *J Clin Endocrinol Metab* 2014; **99**: 1915–42.
- Richter S, Qiu B, Ghering M, et al. Head/neck paragangliomas: focus on tumor location, mutational status and plasma methoxytyramine. *Endocr Relat Cancer* 2022; **29**: 213–24.
- Där R, Pamporaki C, Peitzsch M, et al. Biochemical diagnosis of pheochromocytoma using plasma-free normetanephrine, metanephrine and methoxytyramine: importance of supine sampling under fasting conditions. *Clin Endocrinol* 2014; **80**: 478–86.
- Rao D, Peitzsch M, Prejbisz A, et al. Plasma methoxytyramine: clinical utility with metanephrines for diagnosis of pheochromocytoma and paraganglioma. *Eur J Endocrinol* 2017; **177**: 103–13.
- Eisenhofer G, Prejbisz A, Peitzsch M, et al. Biochemical diagnosis of chromaffin cell tumors in patients at high and low risk of disease: plasma versus urinary free or deconjugated o-methylated catecholamine metabolites. *Clin Chem* 2018; **64**: 1646–56.
- Andrews KA, Ascher DB, Pires DEV, et al. Tumour risks and genotype-phenotype correlations associated with germline variants in succinate dehydrogenase subunit genes *SDHB*, *SDHC* and *SDHD*. *J Med Genet* 2018; **55**: 384–94.
- Gimenez-Roqueplo AP, Caumont-Prim A, Houzard C, et al. Imaging work-up for screening of paraganglioma and pheochromocytoma in *SDHx* mutation carriers: a multicenter prospective study from the PGL. *J Clin Endocrinol Metab* 2013; **98**: E162–73.
- Gravel G, Niccoli P, Rohmer V, et al. The value of a rapid contrast-enhanced angio-MRI protocol in the detection of head and neck paragangliomas in *SDHx* mutations carriers: a retrospective study on behalf of the PGL. EVA investigators. *Eur Radiol* 2016; **26**: 1696–704.
- van den Berg R, Schepers A, de Bruine FT, et al. The value of MR angiography techniques in the detection of head and neck paragangliomas. *Eur J Radiol* 2004; **52**: 240–45.
- Neves F, Huwart L, Jourdan G, et al. Head and neck paragangliomas: value of contrast-enhanced 3D MR angiography. *AJNR Am J Neuroradiol* 2008; **29**: 883–89.
- Jha A, Ling A, Millo C, et al. Superiority of <sup>68</sup>Ga-DOTATATE over <sup>18</sup>F-FDG and anatomic imaging in the detection of succinate dehydrogenase mutation (*SDHx*)-related pheochromocytoma and paraganglioma in the pediatric population. *Eur J Nucl Med Mol Imaging* 2018; **45**: 787–97.
- Janssen I, Chen CC, Taieb D, et al. <sup>68</sup>Ga-DOTATATE PET/CT in the localization of head and neck paragangliomas compared with other functional imaging modalities and CT/MRI. *J Nucl Med* 2016; **57**: 186–91.

- 17 Archier A, Varoquaux A, Garrigue P, et al. Prospective comparison of  $^{68}\text{Ga}$ -DOTATATE and  $^{18}\text{F}$ -FDOPA PET/CT in patients with various pheochromocytomas and paragangliomas with emphasis on sporadic cases. *Eur J Nucl Med Mol Imaging* 2016; **43**: 1248–57.
- 18 Han S, Suh CH, Woo S, Kim YJ, Lee JJ. Performance of  $^{68}\text{Ga}$ -DOTA-conjugated somatostatin receptor-targeting peptide PET in detection of pheochromocytoma and paraganglioma: a systematic review and metaanalysis. *J Nucl Med* 2019; **60**: 369–76.
- 19 Gild ML, Naik N, Hoang J, et al. Role of DOTATATE-PET/CT in preoperative assessment of pheochromocytoma and paragangliomas. *Clin Endocrinol* 2018; **89**: 139–47.
- 20 King KS, Chen CC, Alexopoulos DK, et al. Functional imaging of *SDHx*-related head and neck paragangliomas: comparison of  $^{18}\text{F}$ -fluorodihydroxyphenylalanine,  $^{18}\text{F}$ -fluorodopamine,  $^{18}\text{F}$ -fluoro-2-deoxy-D-glucose PET,  $^{123}\text{I}$ -metaiodobenzylguanidine scintigraphy, and  $^{111}\text{In}$ -pentetate scintigraphy. *J Clin Endocrinol Metab* 2011; **96**: 2779–85.
- 21 Amodru V, Romanet P, Scemama U, et al. Tumor multifocality with vagus nerve involvement as a phenotypic marker of *SDHD* mutation in patients with head and neck paragangliomas: a  $^{18}\text{F}$ -FDOPA PET/CT study. *Head Neck* 2019; **41**: 1565–71.
- 22 Taïeb D, Hicks RJ, Hindié E, et al. European Association of Nuclear Medicine practice guideline/Society of Nuclear Medicine and Molecular Imaging procedure standard 2019 for radionuclide imaging of pheochromocytoma and paraganglioma. *Eur J Nucl Med Mol Imaging* 2019; **46**: 2112–37.
- 23 Gabriel S, Blanchet EM, Sebag F, et al. Functional characterization of nonmetastatic paraganglioma and pheochromocytoma by  $^{18}\text{F}$ -FDOPA PET: focus on missed lesions. *Clin Endocrinol* 2013; **79**: 170–77.
- 24 Miederer M, Fottner C, Rossmann H, et al. High incidence of extraadrenal paraganglioma in families with *SDHx* syndromes detected by functional imaging with  $^{18}\text{F}$  fluorodihydroxyphenylalanine PET. *Eur J Nucl Med Mol Imaging* 2013; **40**: 889–96.
- 25 Blanchet EM, Gabriel S, Martucci V, et al.  $^{18}\text{F}$ -FDG PET/CT as a predictor of hereditary head and neck paragangliomas. *Eur J Clin Invest* 2014; **44**: 325–32.
- 26 Timmers HJ, Chen CC, Carrasquillo JA, et al. Staging and functional characterization of pheochromocytoma and paraganglioma by  $^{18}\text{F}$ -fluorodeoxyglucose ( $^{18}\text{F}$ -FDG) positron emission tomography. *J Natl Cancer Inst* 2012; **104**: 700–08.
- 27 Timmers HJ, Chen CC, Carrasquillo JA, et al. Comparison of  $^{18}\text{F}$ -fluoro-L-DOPA,  $^{18}\text{F}$ -fluoro-deoxyglucose, and  $^{18}\text{F}$ -fluorodopamine PET and  $^{123}\text{I}$ -MIBG scintigraphy in the localization of pheochromocytoma and paraganglioma. *J Clin Endocrinol Metab* 2009; **94**: 4757–67.
- 28 Timmers HJ, Kozupa A, Chen CC, et al. Superiority of fluorodeoxyglucose positron emission tomography to other functional imaging techniques in the evaluation of metastatic *SDHB*-associated pheochromocytoma and paraganglioma. *J Clin Oncol* 2007; **25**: 2262–69.
- 29 Álvarez-Morujó RJ, Ruiz MA, Serafini DP, Delgado IL, Friedlander E, Yurrita BS. Management of multicentric paragangliomas: review of 24 patients with 60 tumors. *Head Neck* 2016; **38**: 267–76.
- 30 Moore MG, Netterville JL, Mendenhall WM, Isaacson B, Nussenbaum B. Head and neck paragangliomas: an update on evaluation and management. *Otolaryngol Head Neck Surg* 2016; **154**: 597–605.
- 31 Sniezek JC, Netterville JL, Sabri AN. Vagal paragangliomas. *Otolaryngol Clin North Am* 2001; **34**: 925–39.
- 32 Wanna GB, Sweeney AD, Carlson ML, et al. Subtotal resection for management of large jugular paragangliomas with functional lower cranial nerves. *Otolaryngol Head Neck Surg* 2014; **151**: 991–95.
- 33 Wanna GB, Sweeney AD, Haynes DS, Carlson ML. Contemporary management of jugular paragangliomas. *Otolaryngol Clin North Am* 2015; **48**: 331–41.
- 34 Lloyd S, Obholzer R, Tysome J, Group BC. British Skull Base Society clinical consensus document on management of head and neck paragangliomas. *Otolaryngol Head Neck Surg* 2020; **163**: 400–09.
- 35 Netterville JL, Jackson CG, Miller FR, Wanamaker JR, Glasscock ME. Vagal paraganglioma: a review of 46 patients treated during a 20-year period. *Arch Otolaryngol Head Neck Surg* 1998; **124**: 1133–40.
- 36 Carlson ML, Sweeney AD, Wanna GB, Netterville JL, Haynes DS. Natural history of glomus jugulare: a review of 16 tumors managed with primary observation. *Otolaryngol Head Neck Surg* 2015; **152**: 98–105.
- 37 Jansen JC, van den Berg R, Kuiper A, van der Mey AG, Zwinderman AH, Cornelisse CJ. Estimation of growth rate in patients with head and neck paragangliomas influences the treatment proposal. *Cancer* 2000; **88**: 2811–16.
- 38 Langerman A, Athavale SM, Rangarajan SV, Sinard RJ, Netterville JL. Natural history of cervical paragangliomas: outcomes of observation of 43 patients. *Arch Otolaryngol Head Neck Surg* 2012; **138**: 341–45.
- 39 Taïeb D, Kaliski A, Boedeker CC, et al. Current approaches and recent developments in the management of head and neck paragangliomas. *Endocr Rev* 2014; **35**: 795–819.
- 40 Hu K, Persky MS. Multidisciplinary management of paragangliomas of the head and neck, part 1. *Oncology* 2003; **17**: 983–93.
- 41 Paspasyrou K, Mewes T, Rossmann H, et al. Head and neck paragangliomas: report of 175 patients (1989–2010). *Head Neck* 2012; **34**: 632–37.
- 42 Prasad SC, Mimouni HA, D’Orazio F, et al. The role of wait-and-see and the efficacy of radiotherapy in the treatment of temporal bone paragangliomas. *Otol Neurotol* 2014; **35**: 922–31.
- 43 Fisch U, Mattox D. Microsurgery of the skull base. Stuttgart, New York: Georg Thieme Verlag, 1988: 148–281.
- 44 Jackson CG, Glasscock ME 3rd, Harris PF. Glomus tumors. Diagnosis, classification, and management of large lesions. *Arch Otolaryngol* 1982; **108**: 401–10.
- 45 Kasper GC, Welling RE, Wladis AR, et al. A multidisciplinary approach to carotid paragangliomas. *Vasc Endovascular Surg* 2006; **40**: 467–74.
- 46 Murphy TP, Brackmann DE. Effects of preoperative embolization on glomus jugulare tumors. *Laryngoscope* 1989; **99**: 1244–47.
- 47 Fayad JN, Keles B, Brackmann DE. Jugular foramen tumors: clinical characteristics and treatment outcomes. *Otol Neurotol* 2010; **31**: 299–305.
- 48 Jackson CG, McGrew BM, Forest JA, Netterville JL, Hampf CF, Glasscock ME 3rd. Lateral skull base surgery for glomus tumors: long-term control. *Otol Neurotol* 2001; **22**: 377–82.
- 49 Moe KS, Li D, Linder TE, Schmid S, Fisch U. An update on the surgical treatment of temporal bone paraganglioma. *Skull Base Surg* 1999; **9**: 185–94.
- 50 Benn DE, Gimenez-Roqueplo AP, Reilly JR, et al. Clinical presentation and penetrance of pheochromocytoma/paraganglioma syndromes. *J Clin Endocrinol Metab* 2006; **91**: 827–36.
- 51 Lee H, Jeong S, Yu Y, et al. Risk of metastatic pheochromocytoma and paraganglioma in *SDHx* mutation carriers: a systematic review and updated meta-analysis. *J Med Genet* 2020; **57**: 217–25.
- 52 van Hulsteijn LT, Dekkers OM, Hes FJ, Smit JW, Corssmit EP. Risk of malignant paraganglioma in *SDHB*-mutation and *SDHD*-mutation carriers: a systematic review and meta-analysis. *J Med Genet* 2012; **49**: 768–76.
- 53 Schovanek J, Martucci V, Wesley R, et al. The size of the primary tumor and age at initial diagnosis are independent predictors of the metastatic behavior and survival of patients with *SDHB*-related pheochromocytoma and paraganglioma: a retrospective cohort study. *BMC Cancer* 2014; **14**: 523.
- 54 Hamidi O, Young WF Jr, Iñiguez-Ariza NM, et al. Malignant pheochromocytoma and paraganglioma: 272 patients over 55 years. *J Clin Endocrinol Metab* 2017; **102**: 3296–305.
- 55 Hu H, Huang B, Zhao J, Yuan D, Yang Y, Xiong F. En bloc resection with major blood vessel reconstruction for locally invasive retroperitoneal paragangliomas: a 15-year experience with literature review. *World J Surg* 2017; **41**: 997–1004.
- 56 Castillo OA, Vitagliano G, Olivares R, Soffia P, Contreras M. Laparoscopic resection of an extra-adrenal pheochromocytoma. *Surg Laparosc Endosc Percutan Tech* 2007; **17**: 351–53.
- 57 Ramlawi B, David EA, Kim MP, et al. Contemporary surgical management of cardiac paragangliomas. *Ann Thorac Surg* 2012; **93**: 1972–76.
- 58 Ellis RJ, Patel D, Prodanov T, et al. Response after surgical resection of metastatic pheochromocytoma and paraganglioma: can postoperative biochemical remission be predicted? *J Am Coll Surg* 2013; **217**: 489–96.



- 59 Lieberson RE, Adler JR, Soltys SG, Choi C, Gibbs IC, Chang SD. Stereotactic radiosurgery as the primary treatment for new and recurrent paragangliomas: is open surgical resection still the treatment of choice? *World Neurosurg* 2012; **77**: 745–61.
- 60 Varma A, Nathoo N, Neyman G, et al. Gamma Knife radiosurgery for glomus jugulare tumors: volumetric analysis in 17 patients. *Neurosurgery* 2006; **59**: 1030–36.
- 61 Suárez C, Rodrigo JP, Bödeker CC, et al. Jugular and vagal paragangliomas: systematic study of management with surgery and radiotherapy. *Head Neck* 2013; **35**: 1195–204.
- 62 Maarouf M, Voges J, Landwehr P, et al. Stereotactic linear accelerator-based radiosurgery for the treatment of patients with glomus jugulare tumors. *Cancer* 2003; **97**: 1093–98.
- 63 Hu K, Persky MS. Treatment of head and neck paragangliomas. *Cancer Contr* 2016; **23**: 228–41.
- 64 Navarro Martín A, Maitz A, Grills IS, et al. Successful treatment of glomus jugulare tumours with Gamma Knife radiosurgery: clinical and physical aspects of management and review of the literature. *Clin Transl Oncol* 2010; **12**: 55–62.
- 65 Gandía-González ML, Kusak ME, Moreno NM, Sárraga JG, Rey G, Álvarez RM. Jugulotympanic paragangliomas treated with Gamma Knife radiosurgery: a single-center review of 58 cases. *J Neurosurg* 2014; **121**: 1158–65.
- 66 Dupin C, Lang P, Dessard-Diana B, et al. Treatment of head and neck paragangliomas with external beam radiation therapy. *Int J Radiat Oncol Biol Phys* 2014; **89**: 353–59.
- 67 Anderson JL, Khattab MH, Anderson C, et al. Long-term outcomes for the treatment of paragangliomas in the upfront, adjuvant, and salvage settings with stereotactic radiosurgery and intensity-modulated radiotherapy. *Otol Neurotol* 2020; **41**: 133–40.
- 68 Fuks Z, Kolesnick R. Engaging the vascular component of the tumor response. *Cancer Cell* 2005; **8**: 89–91.
- 69 Pollock BE. Stereotactic radiosurgery in patients with glomus jugulare tumors. *Neurosurg Focus* 2004; **17**: E10.
- 70 Fatima N, Pollom E, Soltys S, Chang SD, Meola A. Stereotactic radiosurgery for head and neck paragangliomas: a systematic review and meta-analysis. *Neurosurg Rev* 2021; **44**: 741–52.
- 71 Guss ZD, Batra S, Limb CJ, et al. Radiosurgery of glomus jugulare tumors: a meta-analysis. *Int J Radiat Oncol Biol Phys* 2011; **81**: e497–502.
- 72 Shapiro S, Kellermeyer B, Ramadan J, Jones G, Wiseman B, Cassis A. Outcomes of primary radiosurgery treatment of glomus jugulare tumors: systematic review with meta-analysis. *Otol Neurotol* 2018; **39**: 1079–87.
- 73 Sheehan JP, Tanaka S, Link MJ, et al. Gamma knife surgery for the management of glomus tumors: a multicenter study. *J Neurosurg* 2012; **117**: 246–54.
- 74 Eustacchio S, Trummer M, Unger F, Schröttner O, Sutter B, Pendl G. The role of Gamma Knife radiosurgery in the management of glomus jugular tumours. *Acta Neurochir Suppl* 2002; **84**: 91–97.
- 75 Sheehan J, Kondziolka D, Flickinger J, Lunsford LD. Gamma Knife surgery for glomus jugulare tumors: an intermediate report on efficacy and safety. *J Neurosurg* 2005; **102** (suppl): 241–46.
- 76 Sharma MS, Gupta A, Kale SS, Agrawal D, Mahapatra AK, Sharma BS. Gamma Knife radiosurgery for glomus jugulare tumors: therapeutic advantages of minimalism in the skull base. *Neurol India* 2008; **56**: 57–61.
- 77 Lior U, Rotem H, Uzi N, Roberto S. LINAC radiosurgery for glomus jugulare tumors: retrospective—cohort study of 23 patients. *Acta Neurochir* 2020; **162**: 839–44.
- 78 Wegner RE, Rodriguez KD, Heron DE, Hirsch BE, Ferris RL, Burton SA. Linac-based stereotactic body radiation therapy for treatment of glomus jugulare tumors. *Radiother Oncol* 2010; **97**: 395–98.
- 79 Hurmuz P, Cengiz M, Ozyigit G, et al. Robotic stereotactic radiosurgery in patients with unresectable glomus jugulare tumors. *Technol Cancer Res Treat* 2013; **12**: 109–13.
- 80 Patel AK, Rodríguez-López JL, Hirsch BE, Burton SA, Flickinger JC, Clump DA. Long term outcomes with linear accelerator stereotactic radiosurgery for treatment of jugulotympanic paragangliomas. *Head Neck* 2021; **43**: 449–55.
- 81 Suárez C, Rodrigo JP, Mendenhall WM, et al. Carotid body paragangliomas: a systematic study on management with surgery and radiotherapy. *Eur Arch Otorhinolaryngol* 2014; **271**: 23–34.
- 82 Capatina C, Ntali G, Karavitaki N, Grossman AB. The management of head-and-neck paragangliomas. *Endocr Relat Cancer* 2013; **20**: R291–305.
- 83 Krych AJ, Foote RL, Brown PD, Garces YI, Link MJ. Long-term results of irradiation for paraganglioma. *Int J Radiat Oncol Biol Phys* 2006; **65**: 1063–66.
- 84 Springate SC, Weichselbaum RR. Radiation or surgery for chemodectoma of the temporal bone: a review of local control and complications. *Head Neck* 1990; **12**: 303–07.
- 85 Lekovic GP, Mehta GU, Maxwell AK, Peng KA, Brackmann DE. Radiation-induced malignant peripheral nerve sheath tumor of the vagus nerve following radiation treatment of cervical paraganglioma. *J Neurol Surg Rep* 2020; **81**: e66–70.
- 86 Breen W, Bancos I, Young WF Jr, et al. External beam radiation therapy for advanced/unresectable malignant paraganglioma and pheochromocytoma. *Adv Radiat Oncol* 2017; **3**: 25–29.
- 87 Vogel J, Atanacio AS, Prodanov T, et al. External beam radiation therapy in treatment of malignant pheochromocytoma and paraganglioma. *Front Oncol* 2014; **4**: 166.
- 88 Fishbein L, Bonner L, Torigan DA, et al. External beam radiation therapy (EBRT) for patients with malignant pheochromocytoma and non-head and -neck paraganglioma: combination with <sup>131</sup>I-MIBG. *Horm Metab Res* 2012; **44**: 405–10.
- 89 Isaacs M, Lee P. Preoperative alpha-blockade in pheochromocytoma and paraganglioma: is it always necessary? *Clin Endocrinol* 2017; **86**: 309–14.
- 90 van der Horst-Schrivers AN, Osinga TE, Kema IP, van der Laan BF, Dullaart RP. Dopamine excess in patients with head and neck paragangliomas. *Anticancer Res* 2010; **30**: 5153–58.
- 91 Bonnet S, Durand X, Baton O, et al. Malignant hereditary paraganglioma: problems raised by non-functional forms management. *Ann Chir* 2006; **131**: 626–30.
- 92 Eisenhofer G, Goldstein DS, Sullivan P, et al. Biochemical and clinical manifestations of dopamine-producing paragangliomas: utility of plasma methoxytyramine. *J Clin Endocrinol Metab* 2005; **90**: 2068–75.
- 93 Foo SH, Chan SP, Ananda V, Rajasingam V. Dopamine-secreting pheochromocytomas and paragangliomas: clinical features and management. *Singapore Med J* 2010; **51**: e89–93.
- 94 Smith JD, Ellsperman SE, Basura GJ, Else T. Re-evaluating the prevalence and factors characteristic of catecholamine secreting head and neck paragangliomas. *Endocrinol Diabetes Metab* 2021; **4**: e00256.
- 95 Shah-Becker S, Pennock M, Sinoway L, Goldenberg D, Goyal N. Baroreceptor reflex failure: review of the literature and the potential impact on patients with head and neck cancer. *Head Neck* 2017; **39**: 2135–41.
- 96 Berends AMA, Kerstens MN, Lenders JWM, Timmers H. Approach to the patient: perioperative management of the patient with pheochromocytoma or sympathetic paraganglioma. *J Clin Endocrinol Metab* 2020; **105**: 3088–102.
- 97 Buitenwerf E, Osinga TE, Timmers HJLM, et al. Efficacy of  $\alpha$ -blockers on hemodynamic control during pheochromocytoma resection: a randomized controlled trial. *J Clin Endocrinol Metab* 2020; **105**: 2381–91.
- 98 Pacak K. Preoperative management of the pheochromocytoma patient. *J Clin Endocrinol Metab* 2007; **92**: 4069–79.
- 99 Sen I, Young WF Jr, Kasperbauer JL, et al. Tumor-specific prognosis of mutation-positive patients with head and neck paragangliomas. *J Vasc Surg* 2020; **71**: 1602–1612.e2.
- 100 Constantinescu G, Preda C, Constantinescu V, et al. Silent pheochromocytoma and paraganglioma: systematic review and proposed definitions for standardized terminology. *Front Endocrinol* 2022; **13**: 1021420.
- 101 Plouin PF, Amar L, Dekkers OM, et al. European Society of Endocrinology Clinical Practice guideline for long-term follow-up of patients operated on for a pheochromocytoma or a paraganglioma. *Eur J Endocrinol* 2016; **174**: G1–10.
- 102 Michałowska I, Cwikła JB, Michalski W, et al. Growth rate of paragangliomas related to germline mutations of the *SDHx* genes. *Endocr Pract* 2017; **23**: 342–52.
- 103 Heesterman BL, de Pont LMH, Verbist BM, et al. Age and tumor volume predict growth of carotid and vagal body paragangliomas. *J Neurol Surg B Skull Base* 2017; **78**: 497–505.

- 104 van Hulsteijn LT, Heesterman B, Jansen JC, et al. No evidence for increased mortality in *SDHD* variant carriers compared with the general population. *Eur J Hum Genet* 2015; **23**: 1713–16.
- 105 van Hulsteijn LT, den Dulk AC, Hes FJ, Bayley JP, Jansen JC, Corssmit EP. No difference in phenotype of the main Dutch *SDHD* founder mutations. *Clin Endocrinol* 2013; **79**: 824–31.
- 106 Saie C, Buffet A, Abeillon J, et al. Screening of a large cohort of asymptomatic *SDHx* mutation carriers in routine practice. *J Clin Endocrinol Metab* 2021; **106**: e1301–15.
- 107 Havekes B, van der Klaauw AA, Weiss MM, et al. Pheochromocytomas and extra-adrenal paragangliomas detected by screening in patients with *SDHD*-associated head-and-neck paragangliomas. *Endocr Relat Cancer* 2009; **16**: 527–36.
- 108 Heesterman BL, de Pont LMH, van der Mey AG, et al. Clinical progression and metachronous paragangliomas in a large cohort of *SDHD* germline variant carriers. *Eur J Hum Genet* 2018; **26**: 1339–47.
- 109 Amar L, Pacak K, Steichen O, et al. International consensus on initial screening and follow-up of asymptomatic *SDHx* mutation carriers. *Nat Rev Endocrinol* 2021; **17**: 435–44.
- 110 Tufton N, Sahdev A, Akker SA. Radiological surveillance screening in asymptomatic succinate dehydrogenase mutation carriers. *J Endocr Soc* 2017; **1**: 897–907.
- 111 Tufton N, Sahdev A, Drake WM, Akker SA. Can subunit-specific phenotypes guide surveillance imaging decisions in asymptomatic *SDH* mutation carriers? *Clin Endocrinol* 2019; **90**: 31–46.
- 112 Ambrosini V, Kunikowska J, Baudin E, et al. Consensus on molecular imaging and theranostics in neuroendocrine neoplasms. *Eur J Cancer* 2021; **146**: 56–73.
- 113 Hescot S, Leboulleux S, Amar L, et al. One-year progression-free survival of therapy-I patients with malignant pheochromocytoma and paraganglioma. *J Clin Endocrinol Metab* 2013; **98**: 4006–12.
- 114 Jha A, Taïeb D, Carrasquillo JA, et al. High-specific-activity-<sup>131</sup>I-MIBG versus <sup>177</sup>Lu-DOTATATE targeted radionuclide therapy for metastatic pheochromocytoma and paraganglioma. *Clin Cancer Res* 2021; **27**: 2989–95.
- 115 Taïeb D, Jha A, Treglia G, Pacak K. Molecular imaging and radionuclide therapy of pheochromocytoma and paraganglioma in the era of genomic characterization of disease subgroups. *Endocr Relat Cancer* 2019; **26**: R627–52.
- 116 Satapathy S, Mittal BR, Bhansali A. Peptide receptor radionuclide therapy in the management of advanced pheochromocytoma and paraganglioma: a systematic review and meta-analysis. *Clin Endocrinol* 2019; **91**: 718–27.
- 117 Huang H, Abraham J, Hung E, et al. Treatment of malignant pheochromocytoma/paraganglioma with cyclophosphamide, vincristine, and dacarbazine: recommendation from a 22-year follow-up of 18 patients. *Cancer* 2008; **113**: 2020–28.
- 118 Averbuch SD, Steakley CS, Young RC, et al. Malignant pheochromocytoma: effective treatment with a combination of cyclophosphamide, vincristine, and dacarbazine. *Ann Intern Med* 1988; **109**: 267–73.
- 119 Niemeijer ND, Alblas G, van Hulsteijn LT, Dekkers OM, Corssmit EP. Chemotherapy with cyclophosphamide, vincristine and dacarbazine for malignant paraganglioma and pheochromocytoma: systematic review and meta-analysis. *Clin Endocrinol* 2014; **81**: 642–51.
- 120 Asai S, Katabami T, Tsuiki M, Tanaka Y, Naruse M. Controlling tumor progression with cyclophosphamide, vincristine, and dacarbazine treatment improves survival in patients with metastatic and unresectable malignant pheochromocytomas/paragangliomas. *Horm Cancer* 2017; **8**: 108–18.
- 121 Deutschbein T, Fassnacht M, Weismann D, Reincke M, Mann K, Petersenn S. Treatment of malignant pheochromocytoma with a combination of cyclophosphamide, vincristine and dacarbazine: own experience and overview of the contemporary literature. *Clin Endocrinol* 2015; **82**: 84–90.
- 122 Tanabe A, Naruse M, Nomura K, Tsuiki M, Tsumagari A, Ichihara A. Combination chemotherapy with cyclophosphamide, vincristine, and dacarbazine in patients with malignant pheochromocytoma and paraganglioma. *Horm Cancer* 2013; **4**: 103–10.
- 123 Jawed I, Velarde M, Därr R, et al. Continued tumor reduction of metastatic pheochromocytoma/paraganglioma harboring succinate dehydrogenase subunit B mutations with cyclical chemotherapy. *Cell Mol Neurobiol* 2018; **38**: 1099–106.
- 124 Baudin E, Goichot B, Berruti A, et al. First International Randomized Study in Malignant Progressive Pheochromocytoma and Paragangliomas (FIRSTMAPPP): an academic double-blind trial investigating sunitinib. *Ann Oncol* 2021; **32** (suppl 5): S621–25.
- 125 O’Kane GM, Ezzat S, Joshua AM, et al. A phase 2 trial of sunitinib in patients with progressive paraganglioma or pheochromocytoma: the SNIPP trial. *Br J Cancer* 2019; **120**: 1113–19.
- 126 Hadoux J, Favier J, Scoazec JY, et al. *SDHB* mutations are associated with response to temozolomide in patients with metastatic pheochromocytoma or paraganglioma. *Int J Cancer* 2014; **135**: 2711–20.
- 127 Perez K, Jacene H, Hornick JL, et al. *SDHx* mutations and temozolomide in malignant pheochromocytoma and paraganglioma. *Endocr Relat Cancer* 2022; **29**: 533–44.
- 128 Ayala-Ramirez M, Palmer JL, Hofmann MC, et al. Bone metastases and skeletal-related events in patients with malignant pheochromocytoma and sympathetic paraganglioma. *J Clin Endocrinol Metab* 2013; **98**: 1492–97.

Copyright © 2023 Published by Elsevier Ltd. All rights reserved.