

CASE REPORT

A pediatric case of infliximab-resistant ulcerative colitis successfully treated using vedolizumab

Shoko Fukura¹, Mikiko Takei^{1,2}, Shunsuke Takeuchi¹, Takahiro Tayama¹, Akemi Ono¹, Yuko Ichihara¹, Koichi Shichijo¹, Yasuhiro Suzuki³, Kazuhiro Mori¹, and Shuji Kondo¹

¹Department of Pediatrics, Tokushima Prefectural Central Hospital, Japan, ²Department of Pediatrics, Tokushima Municipal Hospital, Japan,

³Department of Gastroenterology, Tokushima Prefectural Central Hospital, Japan

Abstract : Pediatric ulcerative colitis is likely to be more severe than adult ulcerative colitis. Failure to thrive should be considered during therapy. A 10-year-old boy was diagnosed with ulcerative colitis based on his clinical presentation and colonoscopy and biopsy results. The administration of 5-aminosalicylic acid and prednisolone resulted in remission; however, the symptoms reappeared after the discontinuation of prednisolone. Then, infliximab was administered; however, the patient was resistant to it and appeared to be dependent on prednisolone. Vedolizumab, a monoclonal antibody against $\alpha 4\beta 7$ integrin, was administered, which resulted in rapid remission. A steady decrease in prednisolone followed, and remission was maintained even after prednisolone discontinuation. Vedolizumab may be effective in pediatric patients with moderate-to-severe refractory ulcerative colitis. Vedolizumab prevents lymphocytes from binding to MAdCAM-1, which is selectively expressed in the gastrointestinal submucosa, leading to the mitigation of the systemic side effects of immunosuppression, such as infections. In Japan, vedolizumab use is not yet approved for use in children, but its effectiveness and safety in children is expected to be investigated in the future. *J. Med. Invest.* 70:294-297, February, 2023

Keywords : Ulcerative colitis, Inflammatory bowel disease, Vedolizumab, Infliximab, Pediatric IBD

INTRODUCTION

Pediatric ulcerative colitis is likely more severe than ulcerative colitis seen in adults. Monoclonal antibodies against tumor necrosis factor alpha (TNF α), such as infliximab (IFX), showed breakthrough results by inducing and maintaining remission in moderate-to-severe pediatric ulcerative colitis (1). One-third of patients with Crohn's disease or ulcerative colitis receiving anti-TNFs do not respond to treatment, and a relevant proportion experience loss of response or intolerance (2). Vedolizumab (VDZ), a monoclonal antibody against $\alpha 4\beta 7$ integrin, was approved for use in the treatment of adult ulcerative colitis in Japan in 2018. VDZ has been reported to have a potential role in treating patients with ulcerative colitis who had a failed response to TNF α antagonist (3). Additionally, VDZ is considered to have less adverse effects due to its mechanism of action and expected to be approved for use in children (3). However, it is rarely used in Japan. Here, we report the case of a child with infliximab-resistant ulcerative colitis who was successfully treated with VDZ.

CASE REPORT

A 10-year-old boy who developed fever and bloody diarrhea was treated with oral antibiotics at a clinic, but his condition did not improve. Colonoscopy was performed 2 months later and the findings suggested ulcerative colitis. Because inflammatory bowel disease was suspected from the results of colonoscopy, the

patient was administered 1.5 g/day of 5-aminosalicylic acid (5-ASA) and his symptoms improved. When he forgot to take, his bloody diarrhea worsened to ten times a day, and he was referred to our hospital 4 months after the onset of his complaints. His maternal grandmother had ulcerative colitis and his past medical history was unremarkable. At his first visit to our hospital, he was 138.5 cm tall (-0.1 SD) and weighed 29.5 kg (-0.7 SD). He had no oral aphthous ulcers, rashes, or perianal lesions. Blood tests showed a mild elevation of C-reactive protein. Fecal occult blood was positive (Table 1). Bowel ultrasonography showed thickening of the submucosal layer from the ascending colon to the sigmoid colon with enlarged regional lymph nodes of approximately 1 cm in the largest dimension (Fig. 1). Colonoscopy showed a hyperemic mucosa that easily bled on touch and multiple ulcers from the cecum to the rectum. (Fig. 2A, B). Multiple mucosal biopsies were taken from the cecum, ascending colon, transverse colon, descending colon, sigmoid colon, and rectum. On pathological examination, infiltration of plasma cells and cryptitis, including crypt atrophy and twist, were observed (Fig. 2C). The patient was diagnosed with ulcerative pancolitis (Mayo endoscopic score 3).

The patient complained of unbearably severe abdominal pain, and his daily activities were sometimes severely restricted. He defecated 6 to 8 times a day, day and night, with scanty blood in every motion. The nature of the stool was completely watery. Considering these findings, the Pediatric Ulcerative Colitis Activity Index (PUCAI) score was as high as 65. Therefore, we diagnosed the case as severe ulcerative pancolitis. The patient was put on nothing per os and treatment with 3.0 g/day of 5-ASA was initiated accompanied with intravenous administration of prednisolone (PSL) 45 mg/day. His symptoms rapidly improved and a low-residue diet was started on the third day of hospitalization. Two weeks later, PUCAI score improved to 0. The dose of PSL was reduced by 5 mg every 2 weeks. One month after admission, the patient was discharged and switched to oral PSL

Received for publication August 23, 2022; accepted February 3, 2023.

Address correspondence and reprint requests to Shoko Fukura, Takamatsu municipal hospital, 847-1, Ko, Busshozan, Takamatsu, Kagawa, 761-8538, Japan and Fax : +81-87-813-7141. E-mail : out.ms2@gmail.com

Table 1. Laboratory findings on admission

Blood test					
WBC	10,700	/ μ L	Na	149.6	mEq/L
Neutro	57.7	%	K	4.0	mEq/L
Eosino	6.3	%	Cl	104.8	mEq/L
Lympho	24.8	%	Fe	16	μ g/dL
Hb	11.0	g/dL	UIBC	273	μ g/dL
Plt	420×10^3	/ μ L	Ferritin	37.8	ng/mL
T-Bil	0.2	mg/dL	TP	6.7	g/dL
AST	15	U/L	Alb	4.1	g/dL
ALT	8	U/L	CRP	2.4	mg/dL
LDH	177	U/L	Stool test		
CK	74	U/L	Fecal occult blood	+	
UN	7.0	mg/dL	CD toxin	-	
Cre	0.44	mg/dL	Stool culture	Escherichia coli, enterococci	

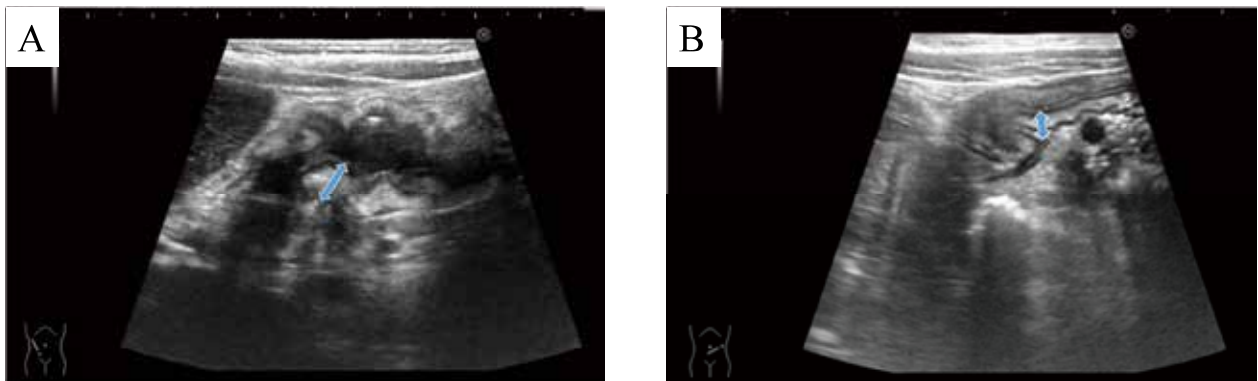


Figure 1. Abdominal ultrasonography
A : Ascending colon, B : Sigmoid colon

Swelling of the submucosal layer from the ascending colon to the sigmoid colon is observed. The diameter of the intestinal wall (\leftrightarrow) is 7.3 mm (ascending colon) and 6.0 mm (sigmoid colon).

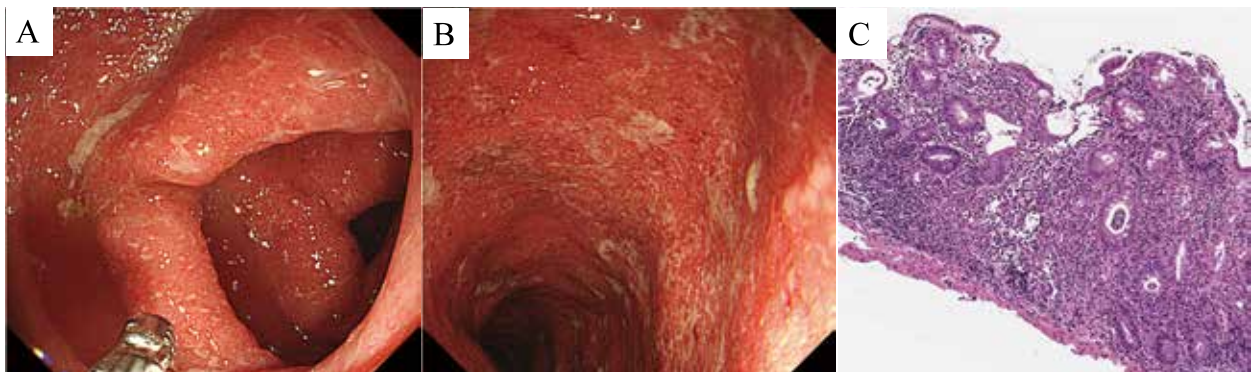

Figure 2. Colonoscopy

A : Ascending colon B : Descending colon

Inflammatory findings in the form of erythema, erosions, and ulcers with friability, bleeding on touch, and loss of vascular pattern are observed. These lesions were observed from the cecum to the rectum with no skip areas.

C : Pathological findings (H&E staining) : ascending colon crypt abscess was inconspicuous, but crypt atrophy and twist were also observed with prominent plasma cell infiltration.

administration.

PSL was discontinued 2.5 months after admission ; however, the patient experienced a relapse of symptoms. Administration of steroid enema did not improve symptoms much and exacerbations recurred. Fifteen months after admission, his condition worsened to PUCAI score 65 ; thus, we treated him with systemic administration of PSL and azathioprine (AZA). His symptoms recurred with tapering PSL, which suggested that his condition is PSL-dependent. Eighteen months after admission, infliximab (IFX) combined with PSL was introduced. IFX and PSL partially improved his symptoms ; however, complete remission never occurred, and the symptoms worsened after tapering PSL. His disease condition was in a state of IFX resistance. Two years after admission, vedolizumab (VDZ) treatment was initiated. Because VDZ use is not approved for children in Japan, written informed consent was obtained from the patient and his parents. The ethical aspect of the use of VDZ was reviewed and approved by the Tokushima Prefectural Central Hospital Ethics Review Board (approval number 21-25).

VDZ was administered in a dose of 300 mg, intravenously, 2 and 6 weeks after the first administration and repeated every 8 weeks thereafter. After the second dose of VDZ, his PUCAI score improved to 0, and good condition was maintained thereafter. PSL dose was gradually reduced and completely discontinued 11 months after the start of VDZ. No adverse events related to VDZ were observed, and the patient remained in remission even after PSL discontinuation (Fig. 3).

DISCUSSION

Ulcerative colitis is a chronic idiopathic inflammatory disease that affects the colon and is characterized by relapsing and remitting mucosal inflammation, erosions, and ulcerations. Symptoms include tenesmus, bloody stools, diarrhea, abdominal pain, and fever (4). Compared with adults, children are more

likely to develop severe total pan colitis in a shorter period of time (5). Hence, it is necessary to establish an effective early treatment strategy suitable for children. PUCAI score of 50 or higher is diagnostic for moderate or severe ulcerative colitis. In case it is moderate or severe, systemic administration of steroids in combination with oral 5-ASA should be initiated early from the beginning of treatment (5-7).

Thiopurines are recommended for maintaining remission in children who are steroid-dependent, relapsing frequently despite optimal 5-ASA treatment, or intolerant to 5-ASA drugs (5-7). IFX is considered in chronically active or steroid-dependent patients and those who are resistant to 5-ASA and thiopurines for the induction and maintenance of remission. VDZ is considered in chronically active or steroid-dependent patients as second-line biologic therapy after anti-TNF failure (5). In Japan, biologics for pediatric ulcerative colitis were approved for IFX in June 2010 and adalimumab (ADA) in September 2021.

VDZ is a monoclonal antibody against $\alpha4\beta7$ integrin (2). The $\alpha4\beta7$ integrin is expressed on T cells and binds to MAdCAM-1, which is expressed on the surface of vascular endothelial cell of the intestinal mucosa. During inflammatory conditions, T cells migrate to the mucosa of small intestine and colon and exacerbate their inflammation. By acting on $\alpha4\beta7$ integrin, VDZ inhibits the binding of T cells to MAdCAM-1 and suppresses inflammation. Because the expression of MAdCAM-1 is selectively limited in gastrointestinal mucosa, there are few systemic side effects of VDZ use (8, 9).

In a phase III clinical trial of VDZ for adult ulcerative colitis in Japan, clinical remission rate 60 weeks after VDZ administration was significantly higher than that of the placebo group (56.1% vs. 31.0%) (9). The first study to investigate the treatment course of VDZ for pediatric inflammatory bowel disease in Spain demonstrated that 71% of patients with ulcerative colitis who were resistant to anti-TNF- α treatment entered a clinical remission at week 52 of follow-up. About 60.7% were in remission at 14 weeks. Of them, 84.5% maintained remission at 52 weeks. The

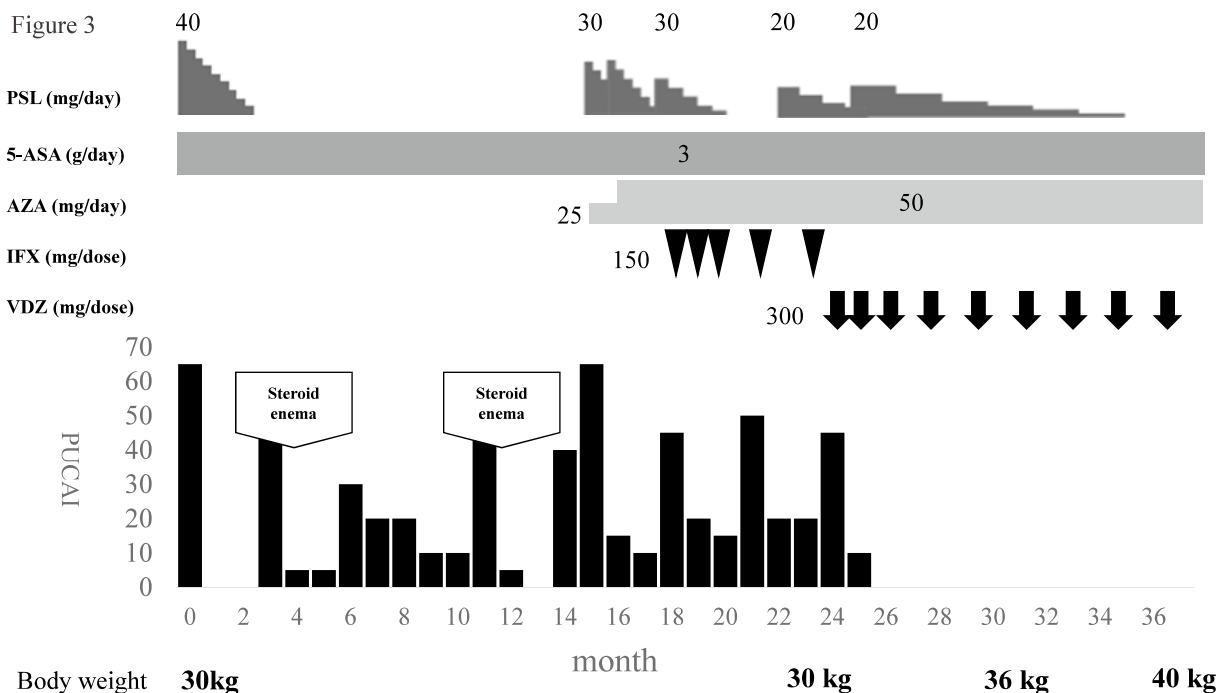


Figure 3. Clinical course
 PSL : prednisolone, 5-ASA : 5-aminosalicylic acid, AZA : azathioprine, IFX : infliximab, VDZ : vedolizumab

only side effects were headache, alopecia, anemia, and dermatitis, suggesting the usefulness and safety of VDZ for refractory pediatric ulcerative colitis (10).

Although the use of either ADA or VDZ is considered in IFX-resistant patients, the VARSITY study, which directly compared ADA and VDZ for adult ulcerative colitis, showed that 31.3% of patients receiving VDZ achieved the primary endpoint of clinical remission compared with 22.5% of patients treated with ADA at week 52, and the difference was statistically significant ($p = 0.0061$). While the VARSITY study was not powered to compare the safety of the two biologics, patients treated with VDZ had a lower rate of overall adverse events over 52 weeks than patients treated with ADA (62.7% vs. 69.2%), with a lower rate of infections in patients treated with VDZ (33.5% vs. 43.5%) as well as a lower rate of serious adverse events in these patients (11.0% vs. 13.7%) (11).

Our case showed a PUCAI score of 65 at the time of diagnosis and corresponded to severe ulcerative colitis. Because no clinical response was obtained via IFX treatment and due to the frequent recurrences and exacerbations after steroid discontinuation, the disease condition was considered to be steroid-dependent and IFX-resistant. At the time, neither ADA nor VDZ was approved for use in children in Japan. However, due to the failure of IFX, the anti-TNF- α agent, and due to the need for prolonged high-dose steroids even after IFX administration, ADA treatment was not expected to be effective. By taking these considerations into account and by revising the VARSITY study, a previous Japanese case report about the efficacy and safety of VDZ administration in pediatric ulcerative colitis (12), VDZ treatment was selected as the second-line treatment in our case.

After VDZ administration, the patient entered a remission state rapidly and PSL was tapered and discontinued. No side effects were observed during the treatment period. Our case also suggested the effectiveness of VDZ for steroid-dependent and IFX-resistant cases.

CONCLUSION

The administration of VDZ to pediatric patients with severe ulcerative colitis seems to be safe and effective. Its use could be considered as a second-line therapy after the failure of anti-TNF- α agents in steroid-dependent patients. However, further prospective randomized trials are required for further investigating the efficacy and safety of VDZ.

CONFLICT OF INTEREST

No competing interests.

REFERENCES

- Tajiri H, Arai K, Kagimoto S, Kunisaki R, Hida N, Sato N, Yamada H, Nagano M, Susuta Y, Ozaki K, Kondo K, Hibi T : Infliximab for pediatric patients with ulcerative colitis : a phase 3, open-label, uncontrolled, multicenter trial in Japan. *BMC Pediatr* 19 : 351, 2019
- Gisbert JP, Marin AC, McNicholl AG, Chaparro M : Systematic review with meta-analysis : the efficacy of a second anti-TNF in patients with inflammatory bowel disease whose previous anti-TNF treatment has failed. *Aliment Pharmacol Ther* 7 : 613-623, 2015
- Conrad MA, Stein RE, Maxwell EC, Albenberg L, Baldassano RN, Dawany N, Grossman AB, Mamula P, Piccoli DA, Kelsen JR : Vedolizumab therapy in severe pediatric inflammatory bowel disease. *Inflamm Bowel Dis* 10 : 2425-2431, 2016
- Ungaro R, Mehandru S, Allen PB, Peyrin-Biroulet L, Colombel JF : Ulcerative colitis. *Lancet* 389 : 1756-1770, 2017
- Turner D, Ruemmele FM, Orlanski-Meyer E, Griffiths AM, de Carpi JM, Bronsky J, Veres G, Aloï M, Strisciuglio C, Braegger CP, Assa A, Romano C, Hussey S, Stanton M, Pakarinen M, de Ridder L, Katsanos K, Croft N, Navas-López V, Wilson DC, Lawrence S, Russell RK : Management of paediatric ulcerative colitis, part 1 : ambulatory care - an evidence-based guideline from European Crohn's and Colitis Organization and European Society of Paediatric Gastroenterology, Hepatology and Nutrition. *J Pediatr Gastroenterol Nutr* 67 : 257-291, 2018
- Turner D, Ruemmele FM, Orlanski-Meyer E, Griffiths AM, de Carpi JM, Bronsky J, Veres G, Aloï M, Strisciuglio C, Braegger CP, Assa A, Romano C, Hussey S, Stanton M, Pakarinen M, de Ridder L, Katsanos K, Croft N, Navas-López V, Wilson DC, Lawrence S, Russell RK : Management of paediatric ulcerative colitis, part 2 : acute severe colitis - an evidence-based consensus guideline from the European Crohn's and Colitis Organization and the European Society of Paediatric Gastroenterology, Hepatology and Nutrition. *J Pediatr Gastroenterol Nutr* 67 : 292-310, 2018
- Turner D, Otley AR, Mack D, Hyams J, de Bruijne J, Uusoue K, Walters TD, Zachos M, Mamula P, Beaton DE, Steinhart AH, Griffiths AM : Development, validation, and evaluation of a pediatric ulcerative colitis activity index : a prospective multicenter study. *Gastroenterology* 133 : 423-432, 2007
- Colombel JF, Sands BE, Rutgeerts P, Sandborn W, Danese S, D'Haens G, Panaccione R, Loftus EV Jr, Sankoh S, Fox I, Parikh A, Milch C, Abhyankar B, Feagan BG : The safety of vedolizumab for ulcerative colitis and crohn's disease. *Gut* 66 : 839-851, 2017
- Motoya S, Watanabe K, Ogata H, Kanai T, Matsui T, Suzuki Y, Shikamura M, Sugiura K, Oda K, Hori T, Araki T, Watanabe M, Hibi T : Vedolizumab in Japanese patients with ulcerative colitis : a phase 3, randomized, double-blind, placebo-controlled study. *PLoS ONE* 14 : e0165435, 2019
- Garcia-Romero R, Martinez de Zabarte Fernandez JM, Pujol-Muncunill G, Donat-Aliaga E, Segarra-Cantón O, Irastorza-Terradillos I, Medina-Benitez E, Ruiz-Hernández CJ, Carrillo-Palau M, Ros-Arnal I, Rodriguez-Martínez A : Safety and effectiveness of vedolizumab in paediatric patients with inflammatory bowel disease : an observational multicentre Spanish study. *Eur J Pediatr* 180 : 3029-3038, 2021
- Sands BE, Peyrin-Biroulet L, Loftus EV Jr, Danese S, Colombel JF, Törüner M, Jonaitis L, Abhyankar B, Chen J, Rogers R, Lirio RA, Bornstein JD, Schreiber S ; VARSITY Study Group : Vedolizumab versus adalimumab for moderate-to-severe ulcerative colitis. *N Engl J Med* 381 : 1215-1226, 2019
- Ikeuchi A, Kakiuchi T, Ibi A, Matsuo M : A pediatric case of moderate active ulcerative colitis successfully treated with vedolizumab in Japan. *Clin J Gastroenterol* 14 : 146-151, 2021