




ACTAS Derma-Sifiliográficas

Full English text available at
www.actasdermo.org



E-CLINICAL CASE

Cutaneous Infection with *Alternaria triticina* in a Bilateral Lung Transplant Recipient



M.C. González-Vela^a, S. Armesto^b, F. Unda-Villafuerte^c, J.F. Val-Bernal^{a,*}

^a Departamento de Anatomía Patológica, Hospital Universitario Marqués de Valdecilla, Universidad de Cantabria e IFIMAV, Santander, Spain

^b Servicio de Dermatología, Hospital Universitario Marqués de Valdecilla, Universidad de Cantabria, Santander, Spain

^c Servicio de Microbiología, Hospital Universitario Marqués de Valdecilla, Santander, Spain

KEYWORDS

Phaeophycomycoses;
Organ
transplantation;
Cutaneous
alternariosis;
Alternaria triticina

Abstract We report the case of a 60-year-old man who was receiving immunosuppressive therapy for a bilateral lung transplant and presented with a crusted, violaceous plaque on the left hand. Based on histopathology and microbiological culture the patient was diagnosed with infection by *Alternaria* species. Treatment with itraconazole led to complete resolution of the skin lesion. Forty months later he developed four reddish, nodular, skin lesions on the left leg. Analysis of a biopsy from one of these lesions using histopathologic and molecular techniques identified a mold that shared 98% homology with a strain of *Alternaria triticina*. *Alternaria* species belong to a group of dematiaceous fungi that cause opportunistic infections in humans. The incidence of these infections is increasing, mainly in transplant centers. To the best of our knowledge, this is the first reported case of a human infection caused by *A. triticina*.

© 2013 Elsevier España, S.L.U. and AEDV. All rights reserved.

PALABRAS CLAVE

Feohifomicosis;
Trasplante de
órganos;
Alternariosis cutánea;
Alternaria triticina

Infección cutánea por *Alternaria triticina* en un paciente con trasplante bilateral de pulmón

Resumen Presentamos el caso de un hombre de 60 años en tratamiento inmunosupresor por un trasplante pulmonar bilateral que presentó una placa violácea costrosa en la mano. Se diagnosticó de infección por *Alternaria* spp mediante estudio histopatológico y cultivo microbiológico. El tratamiento con itraconazol condujo a la resolución completa de la lesión cutánea. Cuarenta meses más tarde el paciente desarrolló 4 lesiones nodulares rojizas en la pierna izquierda. Las muestras obtenidas de una de las lesiones fueron estudiadas mediante histopatología y técnicas moleculares. La secuencia de ADN que se obtuvo del germen causal mostraba una homología del 98% con una cepa de *Alternaria triticina*. Las especies de *Alternaria* forman parte del grupo de hongos que componen las feohifomicosis susceptibles de causar infecciones oportunistas humanas. La incidencia de estas infecciones está aumentando, sobre todo en centros de trasplante. De acuerdo con nuestra información el presente caso es el primero en el que *A. triticina* es causante de una infección humana.

© 2013 Elsevier España, S.L. and AEDV. Todos los derechos reservados.

* Corresponding author.

E-mail addresses: apavbj@humv.es, valbernal@gmail.com (J.F. Val-Bernal).

Introduction

The incidence of phaeohyphomycoses, opportunistic infections caused by dematiaceous molds,¹ has increased in recent years. Fungi belonging to the genus *Alternaria* are increasingly associated with opportunistic mycosis in immunocompromised hosts.² The most common clinical manifestations are cutaneous and subcutaneous infections, as well as oculomycosis, rhinosinusitis, and onychomycosis.³ The most important risk factors for cutaneous and subcutaneous infections are Cushing syndrome and solid organ transplant.³ We report a case of cutaneous infection by *Alternaria triticina* in a bilateral lung transplant patient. To the best of our knowledge, this is the first case of human infection with this kind of organism reported to date.

Case description

A 60-year-old man presented with a crusted, purple plaque on the left hand (Fig. 1). The lesion was painless and the patient could recall no history of injury at that site. He had undergone bilateral lung transplantation 4 months previously and was receiving immunosuppressive therapy (500 mg mycophenolate mofetil, 1 mg tacrolimus, and 15 mg prednisone daily). A skin biopsy was taken for histopathological examination and microbiological culture. Histopathology revealed suppurative, granulomatous inflammation in the

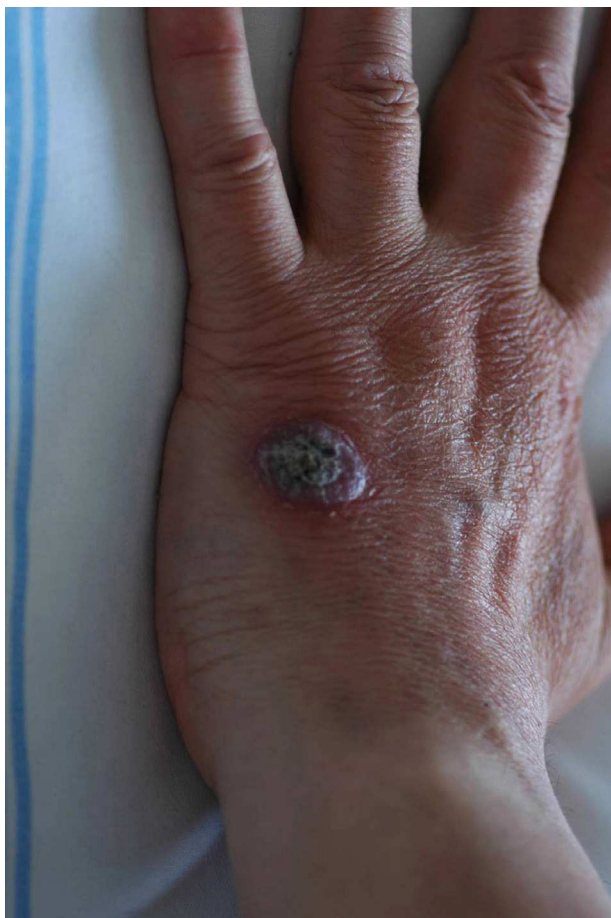

Figure 1 Crusted, purple plaque on the left hand.

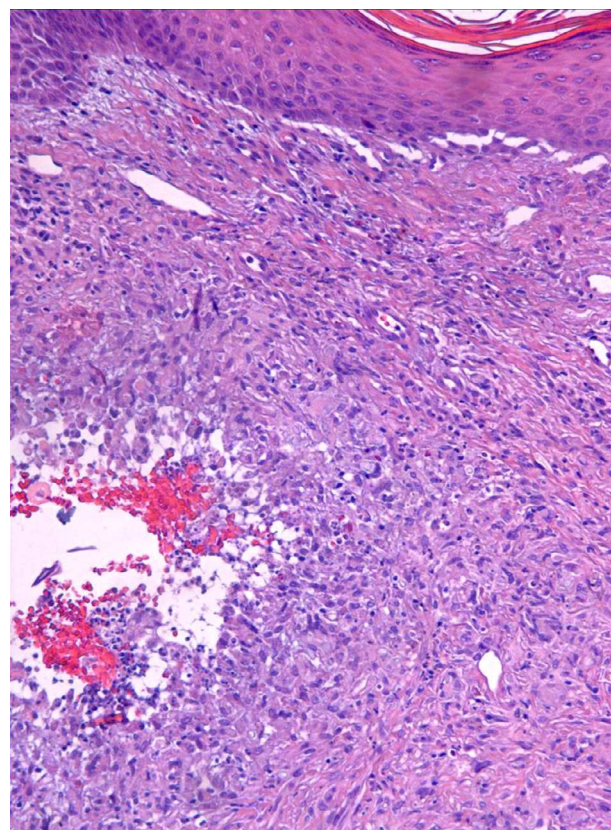


Figure 2 Florid, suppurative, granulomatous inflammation in the dermis and hypodermis (hematoxylin–eosin, original magnification 100×).

dermis and hypodermis. The lesion was composed of lymphocytes, epithelioid macrophages, multinucleated giant cells, and aggregates of neutrophils in the center of the granulomas (Fig. 2). Periodic acid-Schiff (PAS) stain revealed round-shaped, occasionally septate, fungal structures within the cytoplasm of some giant cells that were associated with extracellular fungal hyphae (Fig. 3).

Fungal cultures were performed on Sabouraud dextrose agar. Velvety, yellowish-white colonies with an olive-green reverse, suggesting the presence of dematiaceous fungi, developed after 12 days of incubation. Microscopic examination of these colonies revealed brown, septate hyphae without conidia. The diagnosis was infection with *Alternaria* species. The patient was treated with 100 mg itraconazole twice a day for 6 months, leading to complete resolution of the lesion.

Forty months later the patient developed four reddish, nodular skin lesions on the lower left leg (Fig. 4). A biopsy of one of these lesions was performed, and histopathology revealed suppurative, granulomatous inflammation in the dermis. Grocott's methenamine silver nitrate staining showed diffusely distributed fungal elements (Fig. 5). Samples were subcultured on Sabouraud dextrose agar and produced fast-growing, fungal colonies with an olive-green undersurface. Direct species differentiation was hampered by the absence of conidia, and so molecular techniques were used. DNA was extracted from the biopsy and the Internal Transcribed Spacer (ITS) 1–2 region, which includes the 5.8S ribosomal DNA gene, was amplified using universal

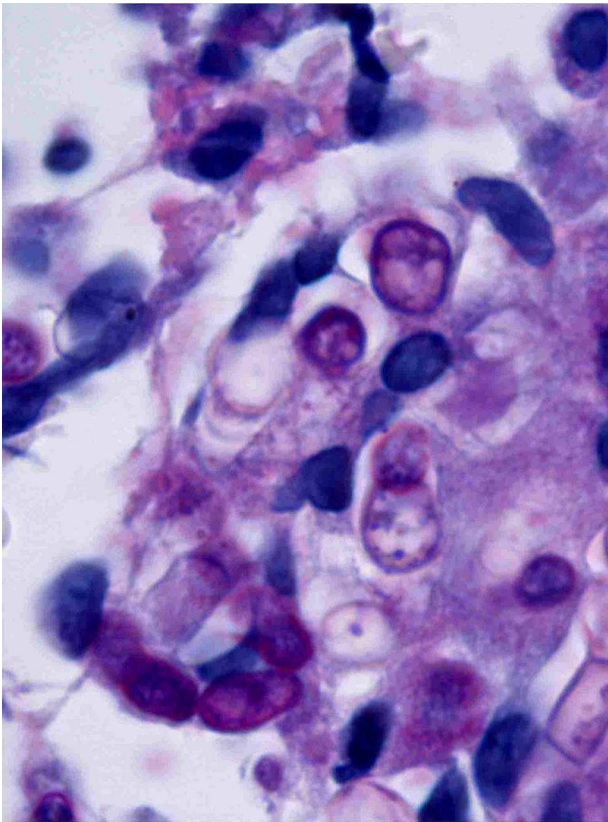


Figure 3 Round, fungal structures within a granuloma. One of the round structures is septate (periodic acid-Schiff 1000×).

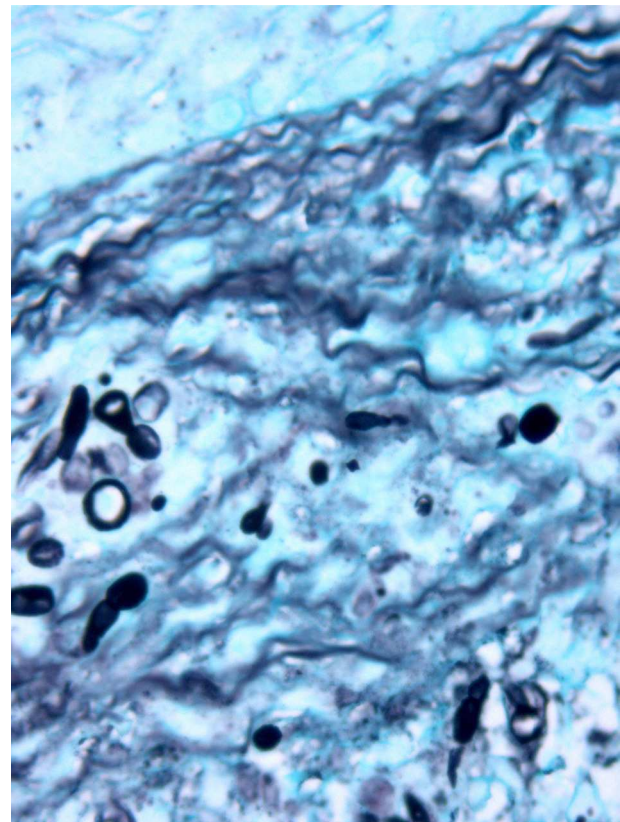


Figure 5 Numerous fungi, thick-walled budding cells, and oval-shaped structures (Grocott 400×).

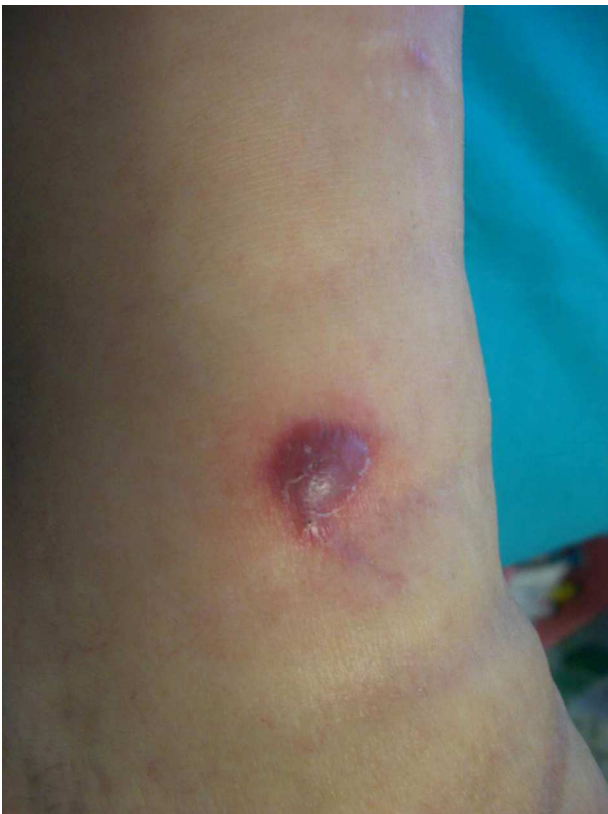

Figure 4 Reddish nodular skin lesion on the left leg.

primers ITS1-4.⁴ The sequence obtained (552 base pairs) was compared with those in the GenBank DNA database (www.ncbi.nlm.nih.gov). This sequence showed 98% homology with a strain of *A. triticina*. The colonies were then transferred to Czapek agar (Difco) and analyzed by microscope, which revealed oval, brown conidia with horizontal and longitudinal septa.

The strain was also sent for analysis to the Instituto Nacional de Salud Carlos III, Madrid, a center with an extensive microorganism database. Analyses performed there using molecular techniques confirmed our own findings. The ribosomal RNA gene sequences of ITS1-5.8S and ITS-2 regions of the clinical isolate described here (isolate HUMV 59512) have been deposited in GenBank (accession number GU318225).

The patient was treated twice per day for 10 months with 200 mg oral voriconazole, which resulted in complete resolution of all cutaneous lesions. No recurrences have been reported after 25 months of follow-up.

Discussion

Alternaria is a very large and complex genus that encompasses hundreds of species, only a few of which have been involved in human or animal infections. The most common species implicated in human disease are *Alternaria alternata* and *Alternaria infectoria*, although in many reported cases of alternariosis the species has not been determined.³

A. triticina, the species isolated from the cultures in the present case, has not been previously described as a human

pathogen. To the best of our knowledge, this is the first such case reported in the literature.

A. triticina is a plant pathogen that causes leaf blight on wheat. It was first identified in India in 1962 and continues to cause significant wheat crop yield losses on the Indian subcontinent.⁵ The disease causes necrotic leaf lesions and in severe cases seeds become shriveled. *Alternaria triticina* can be distinguished from other *Alternaria* species by agarose gel electrophoresis.⁶

Most cases of human *Alternaria* infection involve immunocompromised individuals. Cutaneous alternariosis has been described in organ transplant recipients and in patients with Cushing syndrome, lymphoproliferative disorders, and AIDS.^{3,7,8}

Two routes of cutaneous infection have been proposed: exogenous, following traumatic inoculation with fungal elements (e.g., through injury with a plant spine) or after colonization of pathologically altered skin; and endogenous, caused by inhalation of fungal conidia and subsequent systemic spread, which eventually results in secondary cutaneous involvement.⁷

Cutaneous alternariosis can range from local skin lesions to invasive and disseminated infection. Clinical features include verruciform, eczematous, or ulcerating plaques, as well as vegetating or nodular lesions.⁷ Skin lesions can be single or multiple and usually develop on exposed sites or bone prominences such as the feet, knees, legs, backs of the hands, forearms, and less frequently, the face. Histopathologically, cutaneous *Alternaria* infections usually manifest with noncaseating granulomas and chronic inflammation in the dermis, often with microabscesses. Ulceration or pseudoepitheliomatous hyperplasia of the epidermis may be observed. Melanized hyphae and round-to-oval refractile structures within the histiocytes are common features of fungal infections, including phaeohyphomycoses. Samaniego González et al.⁸ proposed that these refractile structures, which may appear septate depending on type of section analyzed, correspond to muriform conidia in culture, and serve as a diagnostic clue in cases of cutaneous alternariosis. However, culture is essential for the correct identification of *Alternaria* species.

Treatment of cutaneous alternariosis is controversial. Attenuation of immunosuppression or surgical excision of localized lesions can be sufficient to resolve the infection.³ Many antifungal drugs have been used with varying degrees of success and itraconazole is considered the treatment of choice.^{9,10} However, the dose and treatment duration are not well standardized. In some cases, surgery is necessary as an adjuvant to oral therapy.¹¹ Relapses can occur even after long-term treatment. In these types of cases, voriconazole and liposomal amphotericin B may be an alternative treatment option.

The genus *Alternaria* belongs to a group of dematiaceous fungi that cause phaeohyphomycoses and are increasingly associated with opportunistic mycoses in immunocompromised hosts. A high index of suspicion is warranted when examining unusual skin lesions on exposed parts of the limbs of transplant recipients. The diagnosis of cutaneous alternariosis requires a positive tissue culture and histological identification. Early detection and treatment is important to avoid disseminated cutaneous lesions.

Ethical disclosures

Protection of human and animal subjects. The authors declare that no experiments were performed on humans or animals for this investigation.

Confidentiality of data. The authors declare that they have followed the protocols of their hospitals concerning the publication of patient data, and that all the patients included in this study were appropriately informed and gave their written informed consent.

Right to privacy and informed consent. The authors declare that no private patient data appears in this article.

Conflict of interest

The authors declare no conflict of interest.

Acknowledgement

We thank Manuel Cuenca Estrella and Emilia Mellado of the Instituto Nacional de Salud Carlos III in Madrid for confirmation of the identity of the fungus.

References

1. McGinnis MR. Chromoblastomycosis and phaeohyphomycosis: new concepts, diagnosis, and mycology. *J Am Acad Dermatol.* 1983;8:1–16.
2. De Bièvre C. Les *Alternaria* pathogènes pour l'homme: mycologie épidémiologique. *J Mycol Med.* 1991;1:50–8.
3. Pastor FJ, Guarro J. *Alternaria* infections: laboratory diagnosis and relevant clinical features. *Clin Microbiol Infect.* 2008;14:734–46.
4. White TJ, Bruns T, Lee S, Taylor J. Amplification and direct sequencing of fungal ribosomal RNA genes for phylogenetics. In: Innis M, Gelfand D, Snisky J, White T, editors. *PCR protocols: a guide to methods and applications.* San Diego: Academic Press; 1990. p. 315–22.
5. Prasada R, Prabhu AS. Leaf blight of wheat caused by a new species of *Alternaria*. *Indian Phytopathol.* 1962;15:292–3.
6. Mercado Vernes D, Renard ME, Duveiller E, Maraite H. Identification of *Alternaria* species on wheat by pathogenicity assays and sequencing. *Plant Pathol.* 2006;55:485–93.
7. Gilaberte M, Bartralot R, Torres JM, Reus FS, Rodríguez V, Alomar A, et al. Cutaneous alternariosis in transplant recipients: clinicopathologic review of 9 cases. *J Am Acad Dermatol.* 2005;52:653–9.
8. Samaniego González E, Crespo Erchiga V, Gómez Moyano, Sanz Trelles A. Clave diagnóstica en alternariosis cutánea. *Rev Iberoam Micol.* 2008;25:264.
9. Acland KM, Hay RJ, Groves R. Cutaneous infection with *Alternaria alternata* complicating immunosuppression: successful treatment with itraconazole. *Br J Dermatol.* 1998;138:354–6.
10. Duffill MB, Coley KE. Cutaneous phaeohyphomycosis due to *Alternaria alternata* responding to itraconazole. *Clin Exp Dermatol.* 1993;18:156–8.
11. Boyce RD, Deziel PJ, Otley CC, Wilhelm MP, Eid AJ, Wengenack NL, et al. Phaeohyphomycosis due to *Alternaria* species in transplant recipients. *Transpl Infect Dis.* 2010;12:242–50.