

Sonoelastography: the method of choice for evaluation of tissue elasticity

Fahrudin Smajlovic^{1*}, Aladin Carovac¹, Deniz Bulja²

¹ Ultrasound private practice "Doc. Dr Smajlovic", Stari drum 14, 71000 Sarajevo, Bosnia and Hercegovina

² Department of Radiology, Clinical Center of University of Sarajevo, Bolnicka 25, 71000 Sarajevo, Bosnia and Hercegovina

Abstract

Ultrasound devices and methodologies have been continuously evolving and becoming more important as tools in diagnostic medicine. Recently a new ultrasound diagnostic technique has been developed. Named sonoelastography, the technique enables evaluation of tissue elasticity and is based on differences in stiffness (hardness, compressibility, elasticity) of pathological changes and normal adjacent tissue. Sonoelastography (SE) is also known as Real-time tissue elastography (RTE), Real-time sonoelastography (RTSE), Tissue type imaging (TTI) and Ultrasound Strain Imaging Technology. It has been found useful in many medicine fields and adopted readily by clinicians of different specialties. It gives more information than conventional ultrasound in evaluation of tumors, liver disease, skeletal muscles, rheumatoid nodules and other pathological changes. This review covers the basics of elastography, its applications, instruments, techniques, the scoring system and the indications for elastography.

© 2011 University of Sarajevo Faculty of Health Studies

Keywords: ultrasound, elastography, sonoelastography

Introduction

A number of ultrasound modalities have been developed on the basis of knowledge about the physical properties of ultrasonic waves and their changes during the passing through an insonated region. Ultrasound (US) was first used in medical application more than 50 years ago by Dr George Ludwig in United States of America. Since that time, US devices and methodologies have been continuously evolving and becoming more important as tools in diagnostic medicine. The second half of twentieth century is characterized by development of many digital methods in medical diagnostics, such as ultrasound. Each of them (us, CT, MRI, DSA, termovision, nuclear medicine) has its advantages and limits, which resulted with their multi dependencies (1, 2). Continuous technical advancements improved diagnostically quality of methods mentioned above. Since 1950th many innovations resulted in diagnostic improvements of ultrasound: B-mode, Doppler and 3d modality, harmonic imagining and contrast (3). In last couple of years, big improvement was brought by introduction of sonoelastography, which is used for precise identification of character of pathoanatomical changes, as well as their stages.

Anatomical images obtained by US devices are the result of the digital processing of reflected waves from the part of the body investigated. The images are composed of gray-scale structures and shapes of the organs, as a result of different properties of the reflected waves which are caused by variations in tissue absorption, and thus wave diffraction and reflection. Doppler modality is developed based on the modified frequency of transmitted and reflected waves, resulting from interaction with mobile media in the body (3, 4). Harmonic imaging has led to improvements in image resolution due to digital processing of higher frequency of reflected and transmitted waves. Recently a new technique in ultrasound diagnostics, called sonoelastography, has been developed. Sonoelastography evaluates tissue elasticity and thus provides additional information to that offered by conventional ultrasound images (5-7). It is based on the mechanical effect of ultrasound in the human body and its changes depending on transmitting media (8). Elastography analysis can also be done by magnetic resonance (MR Elastography) ehoplanar using short sequences and low frequency (65 Hz) of longitudinal mechanical waves (9). Elastography in terms of transmission resembles Hippocrates' palpation, used to determine the size, shape, hardness and flexibility of pathological changes.

Sonoelastography

Sonoelastography (SE) is also known as Real-time tissue elastography (RTE) (Hitachi), Real-time sonoelastogra-

* Corresponding author: Fahrudin Smajlovic; Ultrasound private practice "Doc. Dr Smajlovic", Stari drum 14, 71000 Sarajevo, Bosnia and Hercegovina; Tel: +387 62 790 300 Fax: +387 33 264 821; Email: charovatz@gmail.com

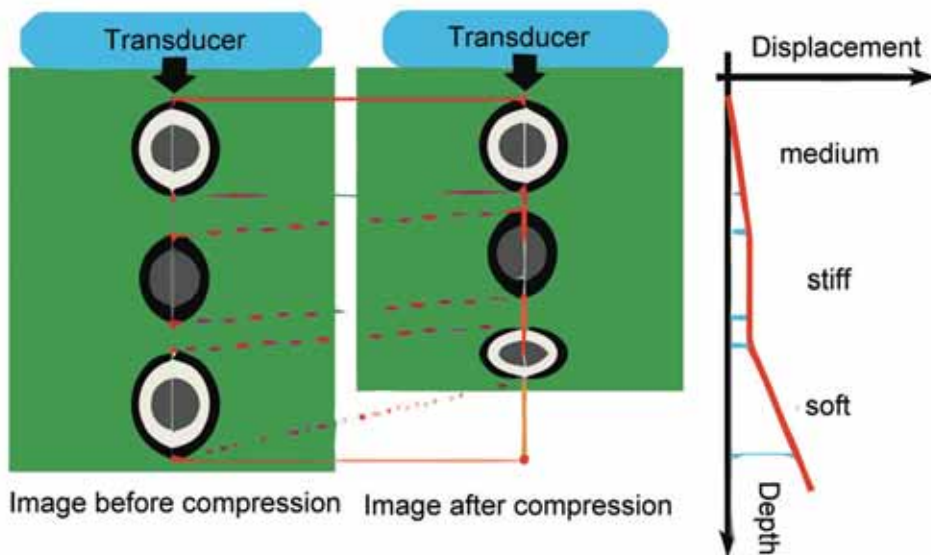


FIGURE 1. Displacement due to compression varies according to tissue stiffness. displacement in soft tissue is high, whereas stiff tissue show no or very little displacement.

phy (RTSE), Tissue type imaging (TTI) and Ultrasound Strain Imaging Technology (Siemens). Elastography is based on differences in stiffness (hardness, compressibility, elasticity) of pathological changes and a normal adjacent tissue (10, 11). A tumor or a suspicious cancerous growth is normally 5-28 times stiffer than the background of normal soft tissue. Other pathological changes in tissue also differ in elasticity from normal background tissue, which is a basis for their detection and characterization. When a mechanical compression or vibration is applied, the tumor deforms less than the surrounding tissue which means that the strain in the tumor is less than the surrounding tissue. Elastograms (images of tissue strain) have been shown to be affected by the degree of adherence of the tumor to its surroundings, indicating a potential to extend elastography to tumor mobility characterisation to improve diagnostic accuracy and surgical guidance. Medical applications of sonoelastography are growing in their number every day. Many studies in different fields of medicine are exploring the possibilities to use this imaging technique, as it is safe and gives important information. Sonoelastography has enabled new aspects in the structural and functional analysis of testicular tissue and therefore male fertility. Schurich et al. found different elasticity values dependent on testicular volume and function (12). The value of real-time elastography in the diagnosis of prostate cancer is the matter of current research and it is possible that this technique will be reliable diagnostic procedure in prostate cancer detection (13, 14). Prospective study from Isserman et al. researching breast lesion sizing by B-mode imaging and sonoelastography in comparison to histopathological

sizing, has found that there was a low interobserver variability of results, which favors sonoelastography for preoperative diagnostics of breast tumors, since it may be less dependent on the observer than conventional B-mode imaging (15). Combined with BI-RADS(R)-US classification system sonoelastography shows improved diagnostic performance in differentiating benign and malignant breast lesions, as reported by the Wojcinski et al. (16). Transabdominal sonoelastography has demonstrated its usefulness in diagnosis of diffuse liver diseases, al-

though this has to be confirmed in large multicentric studies (17). In the study of Botar-Jid et al. there has been found a positive correlation between the quantitative color parameters from the elastographic images and the laboratory studies (18). Preliminary results from the study of Hoyt et al. are encouraging and quantitative sonoelastography may prove clinically feasible for in vivo characterization of the dynamic viscoelastic properties of human skeletal muscle (19). In the musculoskeletal field, sonoelastography can help improve estimation of tendon stiffness. The usefulness of elastography can be expected to increase rapidly in the musculoskeletal field, as the medical professionals learn to interpret elastographic artifacts as well as to take advantage of the new information provided by sonoelastography (5). Sonoelastography may help in the differential diagnosis between rheumatoid nodules and tophi (20).

Instruments and Techniques of Elastography

Leader in sonoelastography technology is a Japanese company Hitachi whose ultrasound machine, HITACHI HI Vision with the probes EUB 8500 L 54 M, 6-13 MHz, EUB L 53S, 5-9 MHz and EUB L 52, 3-7 MHz, now makes high-quality real-time elastography view. On the market we can find appliances from other companies (Esaote, Toshiba, Siemens) with equal features. The first generation of these machines appeared in 1997 (Ophir et al.), and work on them was based on processing differential radio frequency signal before and after tissue compression with probe, so called static elastography. In period from 2003 to 2007 was developed 2nd generation machines, so called Supersonic shear wave elastography technology, rapid time options with new single crystal probe. Probe is the sender of strong pulse waves that ex-







Score	Classification Standard	Typical Image
1	Strain is seen in the entire hypoechoic area (the entire lesion is shown in green similar to the surrounding tissue)	
1*	BGR (blue-green-red) 3 layer pattern – typical artefact seen in a cystic lesion	
2	Strain is seen within most of the hypoechoic area but some areas show no strain (the lesion is a mixture of green and blue)	
3	Strain appears only in the periphery with no strain in the centre of the lesion (the centre of the lesion is shown as blue with the periphery in green)	
4	No strain is measured within the lesion (the entire lesion is shown in blue)	
5	No strain is measured within the lesion nor in the surrounding tissues (the lesion and the surrounding tissues are blue)	

FIGURE 2. Sonoelastographic classification by the Italian MultiCenter Team of study

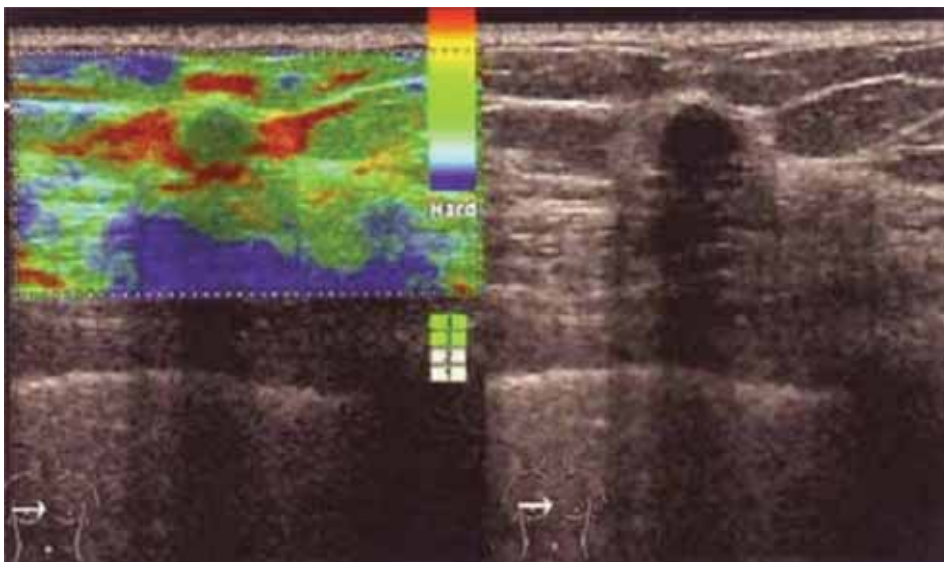


FIGURE 3. Fibroadenoma with elasticity score 2. On conventional B-mode image, the lesion was classified as BI-RADS 4

cluded the need to perform external compression (21, 22). The relative stiffness of the tissues within area of interest is described by colours superimposing on the B-mode image. Real-time elastography can be performed with linear scanners for transcutaneous use, rigid endocavitary probes and with flexible echoendoscopes. The probes can be used to compress the tissue. The elasticity modulus is calculated from the resulting deformation of the tissue (23). Examination technique starts an analysis of previous lesions or body parts in B-mode. After that, the simultaneous sonoelastography program starts and monitor screen is divided into two images – a dual mode. In the left image appears echo anatomical color display layer,

and on the right presented in gray scale. It is sufficient to hold the probe with the same continuous pressure on the skin with less movement. Region of interest (ROI) must be 1 cm wider than the lesions because of the possibility of comparing the difference in compression (elasticity) to changes and the surrounding healthy tissue. Prior training of medical professionals is required for performing proper SE investigation. Digital processing in SE is somewhat similar to the Doppler modalities. Elastography colour image, which displays the degree of hardness (compression) of tissue, occurs on the basis of the analysis and processing of the spectrum reflected echo signal before they are converted into 2D image (extended auto correlation combined method–ECAM).

Scores in Elastography
The degree of elasticity (deformation, compression) and pathological changes and/or parenchyma is determined in two ways: the numerical value expressed in kilopascals (kPa) and coloring with one of the three primary colors: red, green and blue. On the basis of Young module came a formula to measure the degree of tissue elasticity, which is as follows: $E = q / \epsilon$ $E =$ elasticity, $q =$ external pressure, $\epsilon =$ tissue deformation (compression). Previous studies have shown that the value of elasticity $> 20\text{kPa}$ (E score of I–III) is characterized by benign, and those above 20kPa malignant lesions. Great importance is associated to the values of E with which we assess the degree of the diffuse changes in the liver parenchyma (24). Thus, the values obtained $< 3\text{kPa}$ indicate fat infiltration of the liver, if they are 3 to 5kPa the minimal fibrosis, from 5 to 12 its intermediate intensity, up to 20kPa on a strong fibrosis, and from 20 to 75kPa the liver cirrhosis. Real-time sonoelastography has a diagnostic specificity of 93%, sensitivity of up to 90% which

is higher than B-mode (25). Another way of assessing elasticity (deformation) of the tissue is with color (encoding) view of scanned echo tomography layer presented by E scores from 1 to 3, or from 1 to 5 (Ueno et al. 2006 score system, Italian Team of the Multi Center Study). Changes with the greatest intensity of deformation (liquid, necrotic, hemorrhagic, edematous content) are colored in red-yellow color, and marked with score 1, with green on green-yellow color are colored structures with high intensity of deformation (elasticity) such as normal parenchyma, and are marked with score 2. In blue are colored is inelastic, rigid zones (fibrosis, infiltration) and marked with score 3. These colors in SE unit of I and II generation have reversed importance: red color corresponding on the first generation device correspond to blue from second generation.

At the scale with interval 1 to 5, score 1 denote the red colored changes, score 2 areas dominated by green, score 3 dominance of green with some blue spots (26). Changes with score 2 and 3 are medium compressible and usually are benign. Lesions with score 4 (domination of blue with green spots) and 5 (dark blue with pale blue ring) detect their rigid, inelastic structure (fibrosis, malignancies).

Indications for Elastography

Sonoelastography is useful in determining the structure and differentiation of focal lesions and parenchyma organs. It is performed after completing the review in B-mode, and because of reliable detection of occult lesions in apparently normal cases. Use is recommended for the ultrasound exam of brain in children, lymph nodes, thyroid, breast, scrotum and muscular-bone structures (27-29), liver, prostate gland, and esophagus, stomach and pancreas (endoscopic SE) (14, 20, 30-33). In review of muscle-bone system is easier to differentiate inflammatory (edema – lower score), traumatic

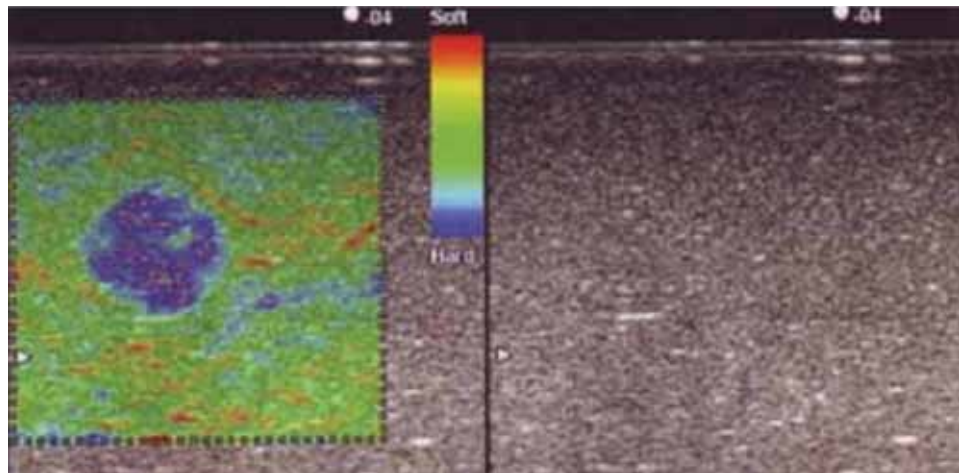


FIGURE 4. Displacement is encoded in different colors: “hard” tissue is blue and “soft tissue red. Conventional ultrasound image of phantom is homogenous, and shows only light shadowing dorsal to undefined structure. Rtse reveals well-defined, hard structure.

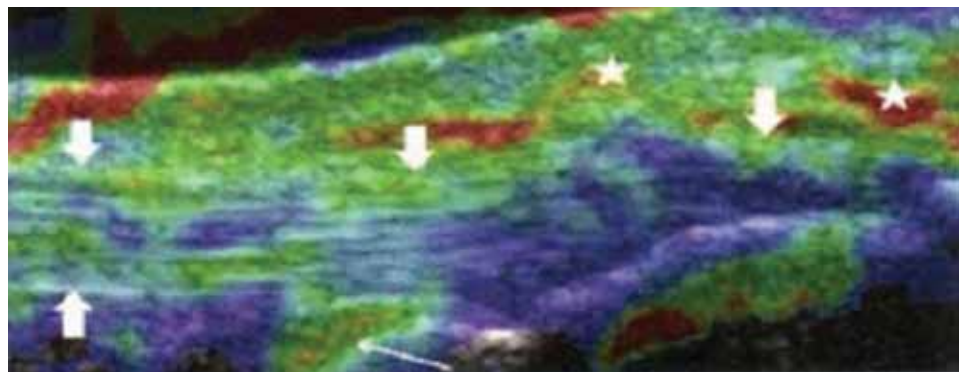


FIGURE 5. normal elasticity of insertional portion of Achilles tendon in a health volunteer. longitudinal rtse scan shows “hard” structured tendon (thick arrows, blue to green-coloured) and “soft” (yellow to red-colored) retrocalcaneal bursa (thin arrow) and and peritendinous tissue (stars)

(hemorrhage and fibrosis) from the tumor changes. This modality has proven to be useful also at echo mammography in review of breast with more density, with palpation undetectable tumefact and states which are by BI-RADS (Brest Reporting Imaging and Data System-USA) are graded of 3 and more (33). Normal tissues of the breasts have greenish blue colours from the fat and orange aspect of the duct structure. Ordinary cysts are colored in red-yellow, as opposed to those with denser content in which the layered coloring is in three colors (bull eyes). Fibro adenomas are characterized by mixed colors with possible minimal blue note, with blue dominating carcinomas, and in case hyper vascularisation, in addition to blue we found the zones of mixed colors. Great importance elastography demonstrated during TRUS examination of the prostate with early cancer detection and secure determination of the target suspicious lesion for biopsy (Feloppa, Eggert-Bochum) (34). This method will surely eventually prove even more quality and expand its indication area.

Conclusion

Sonoelastography is a complementary option to ultrasound B-mode with high diagnostic sensitivity in detecting and assessing the nature and structure of pathological changes in the body. It is proved to be reliable in determining the type of cyst content in the diagnosis of hematoma, edema, fibrosis, solid benign and malignant lesions and the precise staging. It is

already possible to detect early stage of prostate and many other cancers. Elastography contributes to obtaining representative samples from the suspicious lesions and directly reduces unnecessary organ trauma. Real-time elastography will be important for providing diagnostic information and tends to become an integral part of any quality ultrasound examination.

References

1. Watanabe H, Kanematsu M, Kitagawa T, Suzuki Y, Kondo H, Goshima S, et al. MR elastography of the liver at 3 T with cine-tagging and bending energy analysis: preliminary results. *Eur Radiol.* 2010;20(10):2381-9.
2. Wong VW, Chan HL. Transient elastography. *J Gastroenterol Hepatol.* 2010;25(11):1726-31.
3. Li Y, Snedeker JG. Elastography: modality-specific approaches, clinical applications, and research horizons. *Skeletal Radiol.* 2010 30.
4. Saftoiu A, Iordache SA, Gheonea DI, Popescu C, Malos A, Gorunescu F, et al. Combined contrast-enhanced power Doppler and real-time sonoelastography performed during EUS, used in the differential diagnosis of focal pancreatic masses (with videos). *Gastrointest Endosc.* 2010;72(4):739-47.
5. Klauser AS, Faschingbauer R, Jaschke WR. Is sonoelastography of value in assessing tendons? *Semin Musculoskelet Radiol.* 2010;14(3):323-33.
6. Bhatia KS, Rasalkar DD, Lee YP, Wong KT, King AD, Yuen HY, et al. Evaluation of real-time qualitative sonoelastography of focal lesions in the parotid and submandibular glands: applications and limitations. *Eur Radiol.* 2010;20(8):1958-64.
7. Ruchala M, Szczepanek E, Sowinski J. Sonoelastography in de quervain thyroiditis. *J Clin Endocrinol Metab.* 2011;96(2):289-90.
8. Konofagou EE. Quo vadis elasticity imaging? *Ultrasonics.* 2004 Apr;42(1-9):331-6.
9. Rouviere O, Yin M, Dresner MA, Rossman PJ, Burgart LJ, Fidler JL, et al. MR elastography of the liver: preliminary results. *Radiology.* 2006;240(2):440-8.
10. Ophir J, Cespedes I, Ponnekanti H, Yazdi Y, Li X. Elastography: a quantitative method for imaging the elasticity of biological tissues. *Ultrason Imaging.* 1991;13(2):111-34.
11. Frey H. [Realtime elastography. A new ultrasound procedure for the reconstruction of tissue elasticity]. *Radiologe.* 2003;43(10):850-5.
12. Schurich M, Aigner F, Frauscher F, Pallwein L. The role of ultrasound in assessment of male fertility. *Eur J Obstet Gynecol Reprod Biol.* 2009;144 Suppl 1:S192-8.
13. Salomon G, Graefen M, Heinzer H, Hurland H, Pallwein L, Aigner F, et al. [The value of real-time elastography in the diagnosis of prostate cancer]. *Urologe A.* 2009;48(6):628-36.
14. Pallwein L, Aigner F, Faschingbauer R, Pallwein E, Pinggera G, Bartsch G, et al. Prostate cancer diagnosis: value of real-time elastography. *Abdom Imaging.* 2008;33(6):729-35.
15. Isermann R, Grunwald S, Hatzung G, Kongseng-Mustea D, Behrndt PO, Geaid AA, et al. Breast lesion sizing by B-mode imaging and sonoelastography in comparison to histopathological sizing—a prospective study. *Ultraschall Med.* 2011;32 Suppl 1:S21-6.
16. Wojcinski S, Farrokh A, Weber S, Thomas A, Fischer T, Slowinski T, et al. Multicenter study of ultrasound real-time tissue elastography in 779 cases for the assessment of breast lesions: improved diagnostic performance by combining the BI-RADS(R)-US classification system with sonoelastography. *Ultraschall Med.* 2010;31(5):484-91.
17. Gheonea DI, Saftoiu A, Ciurea T, Gorunescu F, Iordache S, Popescu GL, et al. Real-time sono-elastography in the diagnosis of diffuse liver diseases. *World J Gastroenterol.* 2010 14;16(14):1720-6.
18. Botar-Jid C, Damian L, Ducea SM, Vasilescu D, Rednic S, Badea R. The contribution of ultrasonography and sonoelastography in assessment of myositis. *Med Ultrason.* 2010;12(2):120-6.
19. Hoyt K, Kneezel T, Castaneda B, Parker KJ. Quantitative sonoelastography for the in vivo assessment of skeletal muscle viscoelasticity. *Phys Med Biol.* 2008 7;53(15):4063-80.
20. Sconfienza LM, Silvestri E, Bartolini B, Garlaschi G, Cimmino MA. Sonoelastography may help in the differential diagnosis between rheumatoid nodules and tophi. *Clin Exp Rheumatol.* 2010 Jan-;28(1):144-5.
21. Bercoff J, Tanter M, Fink M. Supersonic shear imaging: a new technique for soft tissue elasticity mapping. *IEEE Trans Ultrason Ferroelectr Freq Control.* 2004;51(4):396-409.
22. Varghese T, Zagzebski JA, Rahko P, Breburda CS. Ultrasonic imaging of myocardial strain using cardiac elastography. *Ultrason Imaging.* 2003;25(1):1-16.
23. Janssen J. [(E)US elastography: current status and perspectives]. *Z Gastroenterol.* 2008;46(6):572-9.
24. Sandrin L, Fourquet B, Hasquenoph JM, Yon S, Fournier C, Mal F, et al. Transient elastography: a new noninvasive method for assessment of hepatic fibrosis. *Ultrason Med Biol.* 2003;29(12):1705-13.
25. Wang J, Guo L, Shi X, Pan W, Bai Y, Ai H. Real-time elastography with a novel quantitative technology for assessment of liver fibrosis in chronic hepatitis B. *Eur J Radiol.* 2011 6.
26. Abenavoli L, Corpechot C, Poupon R. Elastography in hepatology. *Can J Gastroenterol.* 2007;21(12):839-42.
27. Wilson WD, Valet AS, Andreotti RF, Green-Jarvis B, Lyschchik A, Fleischer AC. Sonographic quantification of ovarian tumor vascularity. *J Ultrasound Med.* 2006;25(12):1577-81.
28. Lyschchik A, Higashi T, Asato R, Tanaka S, Ito J, Hiraoka M, et al. Elastic moduli of thyroid tissues under compression. *Ultrason Imaging.* 2005;27(2):101-10.
29. Hwang M, Niermann KJ, Lyschchik A, Fleischer AC. Sonographic assessment of tumor response: from in vivo models to clinical applications. *Ultrasound Q.* 2009;25(4):175-83.
30. Sinkus R, Tanter M, Xydeas T, Catheline S, Bercoff J, Fink M. Viscoelastic shear properties of in vivo breast lesions measured by MR elastography. *Magn Reson Imaging.* 2005;23(2):159-65.
31. Itoh A, Ueno E, Tohno E, Kamma H, Takahashi H, Shiina T, et al. Breast disease: clinical application of US elastography for diagnosis. *Radiology.* 2006;239(2):341-50.
32. Chen L, Housden R, Treece G, Gee A, Prager R. A normalization method for axial-shear strain elastography. *IEEE Trans Ultrason Ferroelectr Freq Control.* 2010;57(12):2833-8.

33. Chiorean AR, Duma MM, Dudea SM, Bolboaca S, Dumitriu D, Eniu D, et al. Typical and Unusual Sonoelastographic Patterns of Breast Cystic Lesions: Impact on BI-RADS Classification. *Ultraschall Med.* 2010 22.
34. Adams L. Transient elastography in nonalcoholic fatty liver disease: making sense of echoes. *Hepatology.* 2010;51(2):370-2.