

ORIGINAL RESEARCH

Use of magnetic resonance imaging to guide direct repair of penile fractures---a change to the operative paradigm

Henry Wang^{1,*}, Ankur Dhar¹, Apisara Kulapvirat², Evangeline Woodford³, Sunny Nalavenkata¹, Lawrence Kim¹

¹Urology Department, Westmead Hospital, 2145, Westmead, Australia

²Westmead Clinical School, The University of Sydney, 2145, Sydney, Australia

³Acute Surgical Unit, Westmead Hospital, 2145, Sydney, Australia

***Correspondence**

henry.wang@health.nsw.gov.au

(Henry Wang)

Abstract

Penile fractures are an uncommon urological emergency, typically diagnosed on clinical grounds and require urgent operative intervention. Examination findings include penile swelling and bruising, commonly referred to as an “eggplant deformity”. Close palpation to identify the exact site of injury is often limited by pain. Subcoronal degloving, often with concurrent circumcision is the most utilised surgical approach, though risks include skin necrosis and decreased penile sensitivity. Magnetic Resonance Imaging (MRI) for penile fracture diagnosis is increasingly recognised, however, its ability to guide localised longitudinal incisions is currently undefined. A multi-centre retrospective observational study from February 2016 to February 2022 was performed. Electronic medical records were reviewed for patient demographics, presentation, injury characteristics, investigations and operative outcomes. MRI use and protocols were determined at the discretion of the treating urologist and on-duty radiologist respectively. Twenty-one patients were eligible for study inclusion. Ten patients underwent pre-operative MRI. Median time from MRI request to image acquisition was 2.5 hours (1.5–3.0). Time from presentation to surgical intervention did not significantly differ between the two groups. All patients without pre-operative MRI underwent subcoronal degloving. Six patients underwent MRI-guided localised incision successfully without requiring secondary incision or conversion to subcoronal degloving. The remaining four patients in the MRI cohort underwent degloving. Operative times were significantly shorter ($p = 0.44$) in the pre-operative MRI group, with a median duration of 1.11 hours (0.98–1.17), compared to 1.5 hours (1.20–1.75) in the non-MRI cohort. Median length of stay was 1 day in both groups. No Clavien Dindo 2 or greater complications were observed in any patient. In this study, MRI in the pre-operative setting for penile fractures is associated with reduced operative time and was successfully used to guide localised incisions for direct repair of penile fractures. Its use has the potential to change the paradigm of penile fracture management and operative repair.

Keywords

Magnetic resonance imaging; MRI; Penile fracture; Rupture of corpus cavernosum; Localised incision; Longitudinal incision

1. Introduction

Penile fractures represent an uncommon urological emergency. Occurrences are seen in the setting of sexual activities and intentional penile manipulation, where the tunica albuginea is predisposed to injury due to thinning when erect. Diagnosis is classically established on clinical grounds. Pathognomonic descriptions include a popping sound, followed by rapid detumescence and penile swelling. Examination commonly reveals an “eggplant deformity” with additional findings including penile curvature and palpable tunica defects [1]. Predominantly, these injuries occur in the

mid- and proximal penile shaft, a finding consistent across both Eastern and Western patient populations [2–4]. Emergent surgical repair is typically performed through a subcoronal degloving approach, often with concurrent circumcision.

However, clinical history and examination findings can be misleading, with misdiagnosis rates reported as high as 15% [5, 6]. There are several penile fracture mimics including penile contusions and dorsal vein or dartos bleeding. Unlike penile fractures, these can be managed conservatively with no significant complications or sequelae [1, 7]. Radiological investigations are classically only performed in equivocal cases. Among these, magnetic resonance imaging (MRI) has

demonstrated good specificity and sensitivity in diagnosing penile fractures due to excellent soft tissue contrast. There is limited evidence in the use of MRI to guide operative repair of penile fractures. In this article, we report a retrospective study on the use of MRI in diagnosing and guiding localised incisions for penile fracture repair.

2. Materials and method

This was a multi-centre retrospective observational study using data collected from patients referred to our urology service with suspected penile fractures between February 2016 and February 2022. A retrospective review of electronic medical records was performed by the authors to collect relevant data points. Inclusion criteria were age ≥ 16 years, MRI and surgical intervention performed through our urology service between 2016 and 2022, and confirmation of final diagnosis *via* surgical exploration. Clinical records of the study patients were screened to extract patient demographics such as age, the etiology of injury, estimated time from injury to presentation, time from MRI request to image acquisition, time from presentation to operative intervention, radiological findings, operative technique, post-operative progress, and complications.

2.1 MRI evaluation

MRI was performed following clinical review by the urology team in the emergency department. Images were obtained using both 1.5 and 3 Tesla MRI scanners, with the penis oriented in the anatomical position. MRI protocols were determined and reported by the on-duty radiologist, reflecting real-life clinical practice.

2.2 Surgical technique

Pre-operative MRI was used to guide localised incisions for direct repair of penile fractures. Anatomical information considered prior to incision included side of injury, distance from base of penis to defect, size of defect, and presence of hematoma (Fig. 1). A longitudinal incision was made directly over the site of the fracture. Dissection is performed through Dartos and Buck's fascia. Typically, a surgical plane deep to Buck's fascia is developed by the hematoma resulting from the corporal injury. The hematoma is evacuated to facilitate vision of the defect. Corporal repair is performed with the use of buried, interrupted, absorbable sutures.

2.3 Statistical analysis

SAS 9.4 (SAS Institute Inc., Cary, NC, USA) software was used for analysis of collected data; non-normally distributed continuous variables were reported as median and interquartile range (IQR). Significance of difference between the two groups was calculated using Mann-Whitney U testing for non-normally distributed continuous variables, with Pearson chi-squared testing for categorical variables, or Fisher testing where expected cell counts were less than five.

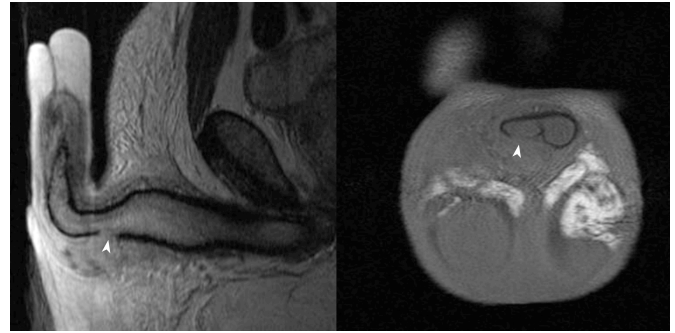


FIGURE 1. Defect in Tunica Albuginea (white arrow) on T2-weighted Sagittal and T1-weighted Coronal MRI.

3. Results

A total of twenty-one patients met the inclusion criteria within the study period (Table 1). Pre-operative MRI was obtained in ten patients (47.6%) as a confirmatory test and for operative planning.

3.1 Patient demographics and presentation

The median age of patients was 37 years in both MRI (24–42), and non-MRI group (32–47). No statistically significant difference in time from injury to presentation was noted, with a median time of 1 hour (0.75–4.75) for the MRI cohort, and 2 hours (1.0–4.0) for the non-MRI group ($p = 0.478$) (Table 1).

3.2 Injury characteristics

Mechanism of penile fracture was predominantly intercourse related (14 out of 21 injuries). The remaining fractures occurred in the setting of variations of penile manipulation. Most injuries involved solely the right corpora cavernosum (13 out of 21 injuries). Six of the remaining injuries occurred in the left corpora, and one case of bilateral corporal injury was observed. Most injuries were located proximally (15 of 21 injuries), followed by the mid-shaft (4 injuries) and distal corpora (1 injury). Side and location of injury was not available in one case (Table 1).

3.3 MRI acquisition, protocol and operative outcomes

The median time from MRI request to image acquisition was 2.50 hours (1.5–3 hours). All MRI studies were performed without contrast. Four studies used a 3-Tesla MRI scanner, with the remaining six performed by a 1.5-Tesla MRI. T2-weighted imaging was used in all MRIs performed. T1-weighted imaging, short tau inversion recovery (STIR) and additional fat suppression (FS) sequences were variably used (Table 2).

The MRI cohort had a higher median time of 25.8 hours (11.5–29.5) from presentation to surgical intervention, compared to 22 hours (10.5–29) for the non-MRI cohort. No statistically significant difference in time from presentation to operative intervention was seen ($p = 0.597$) (Table 3).

All eleven patients in the non-MRI group underwent surgical exploration *via* subcoronal degloving (9 with concomitant

TABLE 1. Patient demographics and injury characteristics.

Patient and Injury Characteristics	MRI (n = 10)	Non-MRI Group (n = 11)	p-value
Age, median years (IQR)	37 (24–42)	37 (32–47)	0.778
Time from Injury to Presentation, median h (IQR)	1.0 (0.75–4.75)	2 (1.0–4.0)	0.478
Etiology			
Intercourse	5	9	0.183
Manipulation	5	2	
Side			
Right	6	7	1.000
Left	3	3	
Bilateral	1	0	
Undocumented	0	1	
Location			
Proximal	8	7	0.587
Midshaft	1	3	
Distal	1	0	
Undocumented	0	1	

MRI: magnetic resonance imaging; IQR: interquartile range.

circumcision). In the ten patient MRI cohort, six patients underwent surgical repair by localised incision, rather than sub-coronal degloving. No secondary incision or conversion to degloving was required. On surgical correlation, eight MRI findings of penile fractures were confirmed. Of the remaining two cases, there was one false positive and one false negative finding (Table 2).

Median operation duration was 1.11 hours (0.98–1.17) for the MRI cohort. This was significantly shorter ($p = 0.044$) in duration than the non-MRI cohort, with a median operative time of 1.5 hours (1.20–1.75). Length of stay was similar between both cohorts, with a median of 1 day. A single patient in the non-MRI cohort who underwent degloving, remained an inpatient for 2 days due to pain concerns, representing a Clavien-Dindo 1 complication. No Clavien-Dindo 2 or greater complications were noted for any patients in this study (Table 3).

4. Discussion

Penile fractures are an uncommon urologic emergency requiring timely surgical intervention. Typically seen in the context of activities such as sexual intercourse, masturbation, blunt trauma and forced flexion, it is defined as the traumatic rupture of the tunica albuginea [3]. Complications of penile fractures include erectile dysfunction, plaques, curvature, chronic pain, and infected hematomas [8, 9]. American Urological Association guidelines recommend prompt surgical exploration and repair in patients with acute signs and symptoms of penile fracture. The recommended surgical approach is *via* circumferential degloving or ventral midline incisions [9]. This is however mired in classical teaching, where penile fractures are diagnosed by history and examination, requiring extended

exposure to accurately identify the defect for repair. In recent years, several studies have demonstrated the accuracy of MRI and its utility in the diagnosis and management of penile pathologies including fractures.

In cases equivocal for penile fractures, ultrasound (USS) and MRI may be performed [9]. The benefits of USS include being readily available in most institutions, low-cost and a favourable safety profile. However, they are associated with a number of shortfalls including decreased accuracy with small tunica tears, where an overlying thrombus or hematoma may obscure the underlying defect, and poor patient tolerance secondary to pain during image acquisition [10]. Additionally, due to the relative rarity of penile fractures, radiographer experience and operator-dependent quality of images may be lacking [11, 12].

MRI has come to be regarded as the superior imaging modality for penile fractures, with exceptional definition of soft tissue structures. It is associated with a positive and negative predictive value of 96.7% and 100% respectively [2]. The time taken for MRI acquisition in the literature is rarely reported. In this study, the median time from MRI request to image acquisition was 2.5 hours (1.5–3.0). Median time from presentation to intervention was 25.8 hours for the MRI group, compared to 22 hours for the non-MRI group. While a longer time to intervention for the MRI group is intuitively consistent, this study was likely underpowered to identify a significant difference. Within the literature, the mean time from presentation to surgical intervention in a large case series of 138 patients was 14.3 hours [13]. The comparatively longer delay observed in this study is likely attributed to the nature of our emergency department (ED) referral system and operating theatres. While our urology service covers two tertiary hospital EDs, there are an additional two referral hospitals in our network. The time required for inter-hospital transfer is included in the time from

TABLE 2. MRI and operative findings.

Patients in MRI Cohort	Clinical Findings	MRI Protocol	MRI Findings	Operative Approach	Operative Findings
1	Defect not palpable	1.5 Tesla T2—Triplanar T2 + FS—Triplanar STIR—Coronal No T1 imaging	Defect in Right Corpora—22 × 3 mm	Degloving	Corresponding Defect—3 cm
2	Defect not palpable	1.5 Tesla T2—Sagittal T2 + FS—Axial and Sagittal T1 FS—Axial and Sagittal	Defect in Right Corpora—17 mm	Degloving	Corresponding Defect—half circumferential
3	Defect not palpable	1.5 Tesla T2—Triplanar T1—Triplanar STIR—Coronal	1. Both Corpora Cavernosum appearing intact 2. Defect in Right Corpus Spongiosum	Degloving and Circumcision	1. Bilateral corpora cavernosal injury—40% circumferential on right, 20% on left 2. Urethral injury—60% circumferential
4	Defect not palpable	1.5 Tesla T2—Triplanar T1—Triplanar	Defect in Distal Left Corpora—(“small focal defect”—size not quantified)	Degloving	No penile fracture evident
5	Defect Right Base palpable	1.5 Tesla T2—Triplanar T1—Triplanar	Defect Right Base (8 × 7 mm)	Localised Incision	Corresponding defect—half circumferential
6	Defect not palpable	3 Tesla T2—Triplanar T1—Axial and Coronal STIR—Sagittal	Defect Right Proximal Corpora—8 mm	Localised Incision	Corresponding Defect—1 cm
7	Defect not palpable	3 Tesla T2—Axial and Sagittal T1—Axial and Coronal	Defect in Right Mid Corpora—11 × 5 mm	Localised Incision	Corresponding Defect—size not documented

TABLE 2. Continued.

Patients in MRI Cohort	Clinical Findings	MRI Protocol	MRI Findings	Operative Approach	Operative Findings
8	Defect not palpable	1.5 Tesla T2—Triplanar T1—Axial STIR—Coronal	Defect in Right Corpora— 3×10 mm	Localised Incision	Corresponding Defect—size not documented
9	Defect not palpable	3 Tesla T2 (+FS)—Triplanar No T1 imaging	Defect in Left Proximal Corpora— 9×7 mm	Localised Incision	Corresponding defect—1 cm
10	Defect not palpable	3 Tesla T2—Triplanar T2 + FS—Axial and Coronal T1—Axial and Coronal	Defect in Proximal Left Corpora— 6×12 mm	Localised Incision	Corresponding Defect—1 cm

MRI: magnetic resonance imaging.

TABLE 3. MRI acquisition and operative outcomes.

MRI Acquisition and Operative Outcomes	MRI (n = 10)	Non-MRI Group (n = 11)	p-value
Time required to obtain MRI imaging, median h (IQR)	2.5 (1.5–3.0)	NA	-
Time from presentation to intervention, median h (IQR)	25.8 (11.5–29.5)	22 (10.5–29.0)	0.597
Surgical Approach			
Degloving	4	11	0.004
Direct repair	6	0	
Operative time, median h (IQR)			
All	1.11 (0.98–1.17)	1.50 (1.20–1.75)	0.044
Degloving	1.10 (0.98–2.38)	1.50 (1.20–1.75)	
Direct repair	1.12 (0.98–1.13)	NA	
Length of stay, median days (IQR)	1 (1–1)	1 (1–2)	0.562
Post-operative Complications	No Clavien-Dindo 2 + complications		

MRI: magnetic resonance imaging; IQR: interquartile range.

presentation to intervention. Additionally, although all cases were booked to undergo emergency operative intervention within 8 hours, this was not always possible.

The clinical relevance of potential delays to intervention for penile fractures and long-term functional outcomes is debated. With early intervention defined as less than 24 hours from time of injury, a systematic review performed by Wong *et al.* [14] (2017) was unable to demonstrate significant improvements in erectile function or tunica scar formation. While penile curvature was improved in the early intervention group, the magnitude in improvement was mild, did not affect sexual functioning, and was deemed clinically insignificant. A meta-analysis by Amer *et al.* [8] (2016) also failed to demonstrate differences in erectile dysfunction when comparing early *vs.* delayed surgical intervention. Studies however do demonstrate reduced complications including decreased erectile dysfunction, lower rates of plaque formation, decreased penile curvature and less painful erections favouring immediate surgical intervention over non-operative management [8, 15].

Our study demonstrates the accuracy of MRI in diagnosing and localising the site of penile fractures. Of the nine patients with penile fractures in our MRI group, only one patient had a palpate tunica defect in the pre-operative setting. Surgical exploration for correlation of radiological findings identified eight true positive, one false positive, and one false negative result. In the single false negative MRI, a urethral injury was identified, which ultimately required surgical exploration with subsequent identification of the penile fracture. Isolated urethral injuries are an exceedingly rare pathology and should prompt consideration of missed corpora cavernosal injuries. The single false positive MRI was a case of a “small focal defect” without size quantification, potentially representing a subclinical injury on exploration. Our findings are consistent with the limited available literature, where the use of MRI to localise the site of penile fracture is promising. In a cohort of 28 patients, Mehrjardi *et al.* [16] (2017) found that MRI correctly mapped the quadrant of injury (determined by laterality and proximity) when compared to surgical degloving in almost all instances (73/75). The two incorrect instances were off by a single order of proximity.

Degloving currently remains the most common incision performed for penile fracture repair. Alternative surgical approaches include penoscrotal and infrapubic incisions [2, 8, 17]. Complications associated with degloving approaches include hematoma formation, decreased sensation, infection, post-operative oedema, and skin necrosis [1, 18]. Concurrent circumcisions are often performed to reduce the risks of post-operative phimosis, paraphimosis and avascular necrosis [18]. However, adult circumcisions have been associated with decreased sexual pleasure, lower orgasm intensity, discomfort or pain, and unusual sensations at the penile shaft [19]. The use of localised, longitudinal incisions as reported in our study may potentially reduce or negate the complications associated with degloving and circumcision. Additionally, longitudinal incisions may be associated with improved long-term functional outcomes. A lower mean time to sexual function recovery was reported in a longitudinal incision cohort (35.6 days) as compared to patients who underwent degloving (54 days). International Index of Erectile Function (IIEF-5) scores were

also similar on long-term follow-up to pre-operative function [20]. In this study, MRI-guided localised incisions directly over the site of penile fracture was successfully performed in all 6 cases attempted, without requiring secondary incisions or conversion to subcoronal degloving. Operation duration was also observed to be significantly reduced with use of pre-operative MRI (1.11 hours *vs.* 1.50 hours; $p = 0.044$). Median length of stay was one day, and no Clavien Dindo 2 or greater complication occurred in either cohort.

Limitations in this study include its retrospective nature and inherent small number of cases. Use of MRI was up to the discretion of the surgeon, and the MRI protocol was not standardised. A potential MRI protocol recommended by Esposito *et al.* [21] (2016) includes the use of T2 weighted imaging for all three orthogonal planes, and T1 weighted imaging for either the axial or sagittal plane. Image acquisition duration is approximately 20 minutes, and there are no routine contrast requirements. Long-term functional outcomes were unavailable in this study due to poor follow-up compliance in the setting of sexual trauma, as well as follow-up occurring in the setting of private consulting rooms.

The utility of MRI for penile imaging is increasingly recognised. It is an excellent imaging modality owing to multi-planar capabilities, lack of ionising radiation and exceptional soft tissue contrast [12]. The use of MRI-guided localised incisions is successfully reported in this study. In the future, as MRI availability increases and more studies are published, its use may potentially change the operative paradigm for penile fractures.

5. Conclusions

This study contributes to the limited literature available relating to MRI use in the diagnosis and management of penile fractures. MRI demonstrated high specificity in penile fracture diagnosis, and successfully facilitated penile fracture repair *via* localised incision. Additional incisions or conversion to degloving approaches were not required, and the operative time for localised incisions was shorter compared to a degloving group.

MRI has the potential to change the paradigm of penile fracture management and operative repair. Additional studies are required to determine long term functional outcomes from localised incisions, as well as the utility of MRI in diagnosing penile fracture mimics and preventing unnecessary explorations altogether.

AVAILABILITY OF DATA AND MATERIALS

The datasets used and analyzed during the current study are available from the corresponding author on reasonable request.

AUTHOR CONTRIBUTIONS

AD—Conceptualisation; AK and HW—Data Curation and Investigation; EW—Formal Analysis; AD and HW—Methodology; AD and LK—Project Administration; LK—Supervision; HW—Writing (original draft); AD, SN and

LK—Writing (review and editing).

ETHICS APPROVAL AND CONSENT TO PARTICIPATE

Ethics was obtained through Western Sydney Local Health District Human Research Ethics Committee (WSLHD HREC). Per my local health district ethics for this particular study, individual consent not required.

ACKNOWLEDGMENT

The authors would like to thank the Western Sydney Local Health District Radiology and Operating Theatre departments for their involvement in patient care.

FUNDING

This research received no external funding.

CONFLICT OF INTEREST

The authors declare no conflict of interest.

REFERENCES

- [1] Falcone M, Garaffa G, Castiglione F, Ralph DJ. Current management of penile fracture: an up-to-date systematic review. *Sexual Medicine Reviews*. 2018; 6: 253–260.
- [2] Saglam E, Tarhan F, Hamarat MB, Can U, Coskun A, Camur E, *et al*. Efficacy of magnetic resonance imaging for diagnosis of penile fracture: a controlled study. *Investigative and Clinical Urology*. 2017; 58: 255.
- [3] Zargooshi J. Sexual function and tunica albuginea wound healing following penile fracture: an 18-year follow-up study of 352 patients from Kermanshah, Iran. *The Journal of Sexual Medicine*. 2009; 6: 1141–1150.
- [4] De Luca F, Garaffa G, Falcone M, Raheem A, Zacharakis E, Shabbir M, *et al*. Functional outcomes following immediate repair of penile fracture: a tertiary referral centre experience with 76 consecutive patients. *Scandinavian Journal of Urology*. 2017; 51: 170–175.
- [5] Beysel M, Tekin A, Gürdal M, Yücebaş E, Şengör F. Evaluation and treatment of penile fractures: accuracy of clinical diagnosis and the value of corpus cavernosography. *Urology*. 2002; 60: 492–496.
- [6] Karadeniz T, Topsakal M, Arýman A, Erton H, Basak D. Penile fracture: differential diagnosis, management and outcome. *British Journal of Urology*. 1996; 77: 279–281.
- [7] Feki W, Derouiche A, Belhaj K, Ouni A, Ben Mouelhi S, Ben Slama MR, *et al*. False penile fracture: report of 16 cases. *International Journal of Impotence Research*. 2007; 19: 471–473.
- [8] Amer T, Wilson R, Chlosta P, AlBuheissi S, Qazi H, Fraser M, *et al*. Penile fracture: a meta-analysis. *Urologia Internationalis*. 2016; 96: 315–329.
- [9] Morey AF, Brandes S, Dugi DD, Armstrong JH, Breyer BN, Broghammer JA, *et al*. Urotrauma: AUA guideline. *Journal of Urology*. 2014; 192: 327–335.
- [10] Uder M, Gohl D, Takahashi M, Derouet H, Defreyne L, Kramann B, *et al*. MRI of penile fracture: diagnosis and therapeutic follow-up. *European Radiology*. 2002; 12: 113–120.
- [11] Kati B, Akin Y, Demir M, Boran OF, Gumus K, Ciftci H. Penile fracture and investigation of early surgical repair effects on erectile dysfunction. *Urologia Journal*. 2019; 86: 207–210.
- [12] Lindquist CM, Nikolaidis P, Mittal PK, Miller FH. MRI of the penis. *Abdominal Radiology*. 2020; 45: 2001–2017.
- [13] Ouanes Y, Saadi MH, Haj Alouene H, Bibi M, Sellami A, Rhouma SB, *et al*. Sexual function outcomes after surgical treatment of penile fracture. *Sexual Medicine*. 2021; 9: 100353–100353.
- [14] Wong NC, Dason S, Bansal RK, Davies TO, Braga LH. Can it wait? A systematic review of immediate vs. delayed surgical repair of penile fractures. *Canadian Urological Association Journal*. 2017; 11: 53–60.
- [15] Sarıkaya K, Senocak Ç, Sadioğlu FE, Bozkurt ÖF, Çiftçi M. Early surgical repair or conservative treatment? Comparing patients with penile fracture concerning long-term sexual functions. *Turkish Journal of Trauma and Emergency Surgery*. 2021; 27: 249–254.
- [16] Zare Mehrjardi M, Darabi M, Bagheri SM, Kamali K, Bijan B. The role of ultrasound (us) and magnetic resonance imaging (MRI) in penile fracture mapping for modified surgical repair. *International Urology and Nephrology*. 2017; 49: 937–945.
- [17] Kominsky H, Beebe S, Shah N, Jenkins LC. Surgical reconstruction for penile fracture: a systematic review. *International Journal of Impotence Research*. 2020; 32: 75–80.
- [18] Pandher M, Pedrosa GF, Alwaal A. Presentation, management, and outcomes of penile fractures. *Journal of Men's Health*. 2022; 18: 215.
- [19] Bronselaer GA, Schober JM, Meyer-Bahlburg HFL, T'Sjoen G, Vlietinck R, Hoebeke PB. Male circumcision decreases penile sensitivity as measured in a large cohort. *BJU International*. 2013; 111: 820–827.
- [20] Xu MX, Zhou Z, Yao HJ, Zhang K, Da J, Zhang M, *et al*. Comparison of different approaches to the surgical treatment of penile fractures: quicker return to sexual function with longitudinal incisions. *International Journal of Impotence Research*. 2016; 28: 155–159.
- [21] Esposito AA, Giannitto C, Muzzupappa C, Maccagnoni S, Gadda F, Albo G, *et al*. MRI of penile fracture: what should be a tailored protocol in emergency? *La Radiologia Medica*. 2016; 121: 711–718.

How to cite this article: Henry Wang, Ankur Dhar, Apisara Kulapvirat, Evangeline Woodford, Sunny Nalavenkata, Lawrence Kim. Use of magnetic resonance imaging to guide direct repair of penile fractures—a change to the operative paradigm. *Journal of Men's Health*. 2023; 19(6): 34-40. doi: 10.22514/jomh.2023.025.