

Research article

# Medical management and rehabilitation in a patient with avascular necrosis of the femoral head in the context of vitamin D deficiency and secondary hyperparathyroidism – case report

Cosmina Diaconu <sup>1,2</sup>, Remus Calin Cipăian <sup>2,3</sup>, Mădălina Gabriela Iliescu <sup>4,\*</sup>, Viorela-Mihaela Ciortea <sup>5</sup>, Laszlo Irsay <sup>5</sup>, Rodica Ana Ungur <sup>5</sup>, Cristinel Gabriel Diaconu <sup>6,7</sup>

**Citation:** Diaconu C., Cipăian R.C., Iliescu M.G., Ciortea V.M., Irsay L., Ungur R.A., Diaconu C.G. - Medical management and rehabilitation in a patient with avascular necrosis of the femoral head in the context of vitamin D deficiency and secondary hyperparathyroidism – case report. *Balneo and PRM Research Journal* 2023, 14(2): 547

Academic Editor(s):  
Constantin Munteanu

Reviewer Officer:  
Viorela Bembea

Production Officer:  
Camil Filimon

Received: 10.05.2023  
Accepted: 15.06.2023  
Published: 23.06.2023

**Reviewers:**  
Mariana Rotariu  
Mihail Hoteteu

**Publisher's Note:** Balneo and PRM Research Journal stays neutral with regard to jurisdictional claims in published maps and institutional affiliations.



**Copyright:** © 2023 by the authors. Submitted for possible open access publication under the terms and conditions of the Creative Commons Attribution (CC BY) license (<https://creativecommons.org/licenses/by/4.0/>).

1. Nursing- Dental Medicine and Nursing Department, Lucian Blaga University of Sibiu, Faculty of Medicine, Lucian Blaga Street, 2A, Romania
2. Academic Emergency Hospital Sibiu, Coposu Boulevard, 2-4, 550245, Romania
3. Department of Clinical Medicine, Lucian Blaga University of Sibiu, Faculty of Medicine, Romania
4. Department of Physical Medicine and Rehabilitation, „Ovidius” University of Constanta, Faculty of Medicine, 1 University Alley, Campus – Corp B, 900470, Constanta, Romania
5. Department of Rehabilitation Medicine, University of Medicine and Pharmacy “Iuliu Hatieganu”, 8 Victor Babes street, 400012, Cluj-Napoca, Romania
6. Physiology- Preclinic Department, Lucian Blaga University of Sibiu, Faculty of Medicine, Lucian Blaga Street, 2A, Romania
7. Pneumophysiology Hospital of Sibiu, Radiology Department, Romania

\* Correspondence: Iliescu Mădălina-Gabriela - [iliescumadalina@gmail.com](mailto:iliescumadalina@gmail.com)

**Abstract:** Vitamin D is essential in determining bone and muscle health. Vitamin D deficiency (VDD) produces secondary hyperparathyroidism, loss of bone quality and mass, mineralization effects and fractures, myopathy, and falls. The avascular necrosis (AVN) of the femoral head pathophysiology is still unclear and can be considered a vascular bone disease. Our paper aimed to evaluate the etiology of AVN in a young male with bilateral femoral neck damage who required bilateral arthroplasty. Method: We present the case of a 46-year-old male patient with VDD and bilateral total hip arthroplasty for osteoarthritis secondary to AVN of the femoral head. After complete hormonal, biological, and imaging evaluations, the diagnosis of primary hyperparathyroidism was not supported; the improvement of vitamin D deficiency after eight months of treatment clarified the diagnosis: hyperparathyroidism secondary to vitamin D deficiency. Results: Supplementation with 4000 IU of vitamin D improved the patient's response to specific rehabilitation methods. Conclusions: Severe vitamin D deficiency can secondarily affect the structure of the femoral head through secondary hyperparathyroidism, producing AVN, but only osteopenia was obtained on DXA evaluation. VDD can be an important etiological factor in the occurrence of AVN, and its correction can improve the evolution of the disease, improving the rehabilitation of these patients.

**Keywords:** avascular necrosis, secondary hyperparathyroidism, vitamin D deficiency, rehabilitation,

## 1. Introduction

In determining bone health, calcium, and vitamin D play an essential role. Vitamin D deficiency (VDD) in adults leads to low bone mass and increases the risk of falls; hence, it predisposes to fractures [1].

In severe cases of VDD can appear osteomalacia and muscle weakness and increase the risk of fragility fractures. VDD is also a significant risk factor for osteoporotic fractures in all age groups, especially among the elderly [2].

Osteoporosis is a significant public health problem worldwide, with substantial morbidity and mortality. Although spine fractures are usually more frequent, hip fractures should also be a considerable complication of osteoporosis. Mild mechanical forces produce fragility fractures. Decreased bone mineral density (BMD) or osteopenia is a significant risk factor, followed by a bone with a low tolerance for low-energy trauma and easily breaks [3].

Deficiency in vitamin D produces secondary hyperparathyroidism, a high bone turnover, loss of bone quality and mass, mineralization defects, and fractures. Other consequences of VDD are myopathy and falls. A low-calcium diet may increase the turnover of vitamin D metabolites and aggravate VDD [1].

AVN is a progressive, multifactorial, and challenging clinical problem of increasing severity, affecting mainly the middle-aged male population in the most productive age group of 25-50 years. Clinically, AVN of the femoral head is a pathological condition with multifactorial etiologies associated primarily with reduced vascular supply to the subchondral bone of the femoral head. As a result, it leads to osteocyte death and progressive collapse of the joint surface, followed by degenerative arthritis of the hip joint [4-7].

The exact pathomechanism of AVN is still unclear. Each case is probably determined by different factors, including underlying conditions or medication that increase the likelihood of vessel obstruction, alteration of the osteocyte's metabolism, and genetic factors [8].

AVN is an avascular necrosis or aseptic necrosis of the bone, characterized by the death of the bone cells due to an impairment of the blood flow in bone. The most frequent cause is traumatic but can be non-traumatic and often appears in the hip joint (femoral head), but can also occur in other anatomical locations such as the shoulder, knee, and ankle [9].

The AVN pathophysiology remains unclear but is considered a vascular and bone disease. The number of mesenchymal stem cells, like precursors of osteoblastic cells, is depressed in patients with osteonecrosis. The proliferation rate of the osteoblastic cells in the proximal femur is depressed, so some studies concluded that AVN might be a disease of bone cells or bone metabolism [9]. Non-traumatic systemic conditions involved in AVN include corticosteroid administration, fat emboli, hemoglobinopathies (sickle cell anemia), systemic lupus erythematosus and alcoholism [10]

Our paper aimed to evaluate the etiology of AVN in a young male with bilateral femoral neck damage who required bilateral arthroplasty on the background of osteopenia with the need to combine multiple medical rehabilitation methods.

## 2. Results

The results of the radiological examination and IRM performed pre and postoperatively at the first and second cementless total hip arthroplasty are presented below (figure 1, figure 2, figure 3, figure 4)

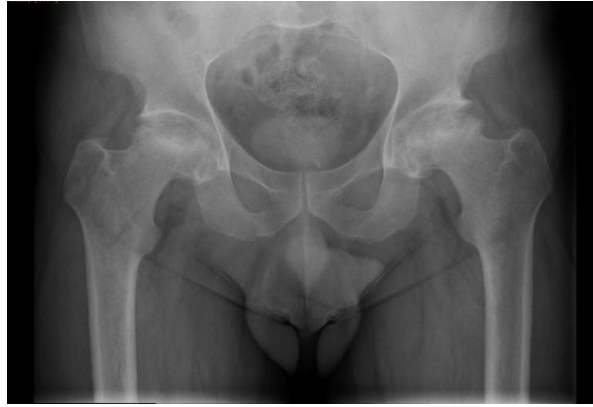

Figure 1. Anteroposterior radiographs of the hip joints: grade II/III bilateral osteoarthritis, secondary to avascular necrosis of the femoral head: joint space narrowing, subchondral sclerosis of acetabulum , osteophytes, flattening of the femoral head, with inhomogeneous bone structure - sclerosis and changes in bone density.

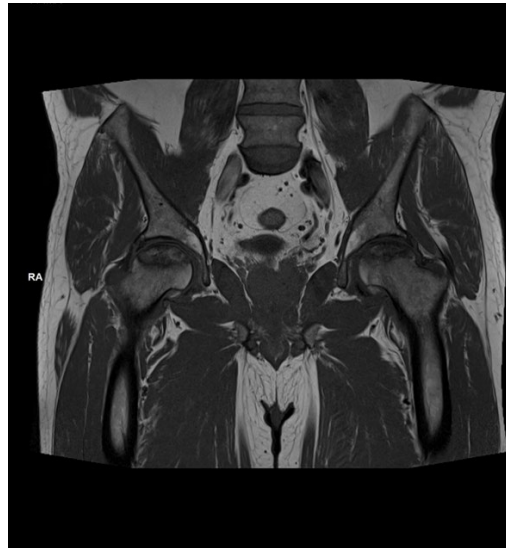

Figure 2 . MRI of the hip joints confirmed bilateral AVN

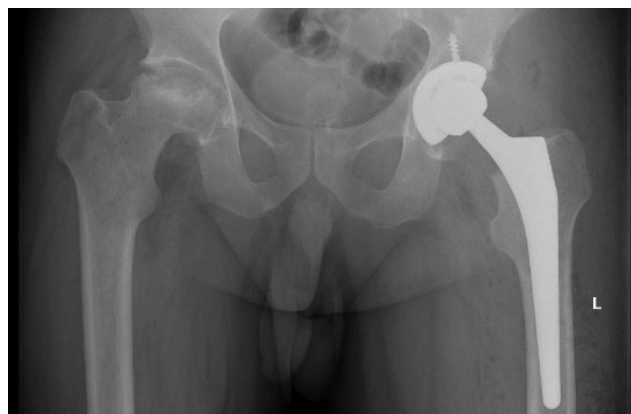

Figure 3. Anteroposterior radiographs of the hip joints: Left hip arthroplasty

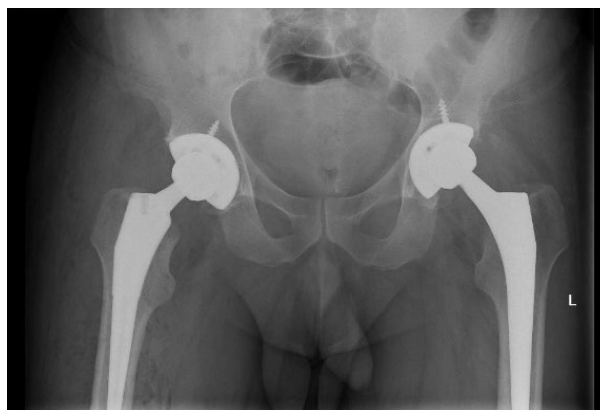


Figure 4. Bilateral cementless total hip arthroplasty

Table 1. Hormonal evaluation for osteopenia etiology

Hormonal parameters				
	First evaluation		Second evaluation	
	Values	Reference range	Values	Reference range
Free T4 (ng/dL)	0.99	0.58-1.16	1,09	0.58-1.16
Free T3 (ng/dL)	3.2	2.66-4.37	3,2	2.66-4.37
Thyroid-stimulating hormone (mIU/L)	3.1	0.38-5.33	3,8	0.38-5.33
PTH (pg/mL)	123,7	18,5-88	82,8	18,5-88
Follicle stimulating hormone (IU/L)	10.22	1.27-19.26	11,09	1.27-19.26
Luteinizing hormone (IU/L)	6.28	1.24-8.62	5,99	1.24-8.62
Total testosterone (ng/dL)	254	175-781	266	175-781
25-OH vitamina D (ng/ml)	12, 81	30-100	30,7	30-100
Calcium ionic (ng/mL)	4,87	3,8-4,8	4,76	3,8-4,8
Calcium total (mg/dL)	10,42	8,4-10,2	10,17	8,4-10,2
Cortisol (µg/dL)	10.6	6.7-22.6	12,1	6.7-22.6

Based on laboratory data (table 1): PTH was 123.7pg/mL (normal range 18.5-88), Total Calcium was 10.42mg/dL (normal range 8.4-10.2), Ionic Calcium 4.87mg/dL (normal range 3,8-4,8), thyroid and parathyroid ultrasound (fig 5) and abdominal ultrasound (renal microlithiasis association), the endocrinological evaluation initially interpreted (on the occasion of the first hospitalization in our rehabilitation department after the first left hip arthroplasty), that the bone changes have occurred in the context of primary hyperparathyroidism determined by the presence of a possible left parathyroid adenoma. The patient was treated with bisphosphonates (acidum risedronicum 35mg/week) just for one month because the patient stopped the treatment on his own initiative.

The dosage of the 25-OH vitamin D level revealed its deficiency (12, 81 ng/ml, average values = 30-100 ng/mL). The treatment was supplemented with six months of cholecalciferol 4000 UI/day.

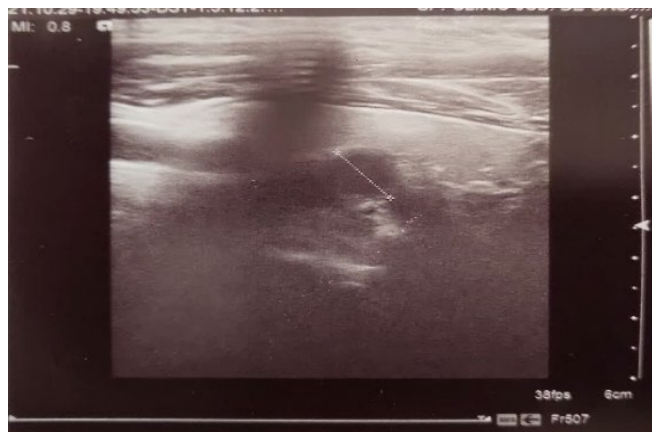

Figure 5. Cervical ultrasound (initial evaluation): intensely hypoechoic image in the posterior area of the left thyroid lobe, with 1 cm diameter, with a large posterior shadow (possibly the parathyroid gland with completely calcified periphery)

Later, after eight months, the patient was reevaluated in our rehabilitation clinic after the right hip arthroplasty. Repeated hormonal dosages demonstrated the improvement of the previously low vitamin D level by substitution with 4000 IU (30,7ng/ml). Also, the serum total calcium level was in normal range (10,17mg/dl) (table1).

Ultrasound of the cervical area described a mixed formation with a cystic component, with some calcifications included, non-vascularized, about 20/14.5/12mm, being interpreted by the radiologist as possible parathyroid cystic adenoma or thyroid cyst (fig 6).

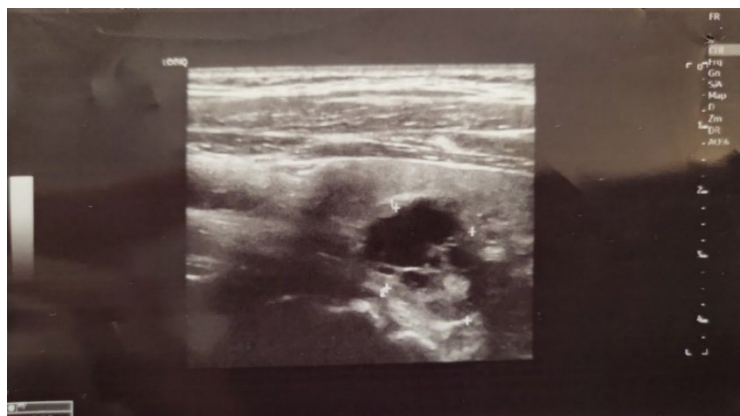
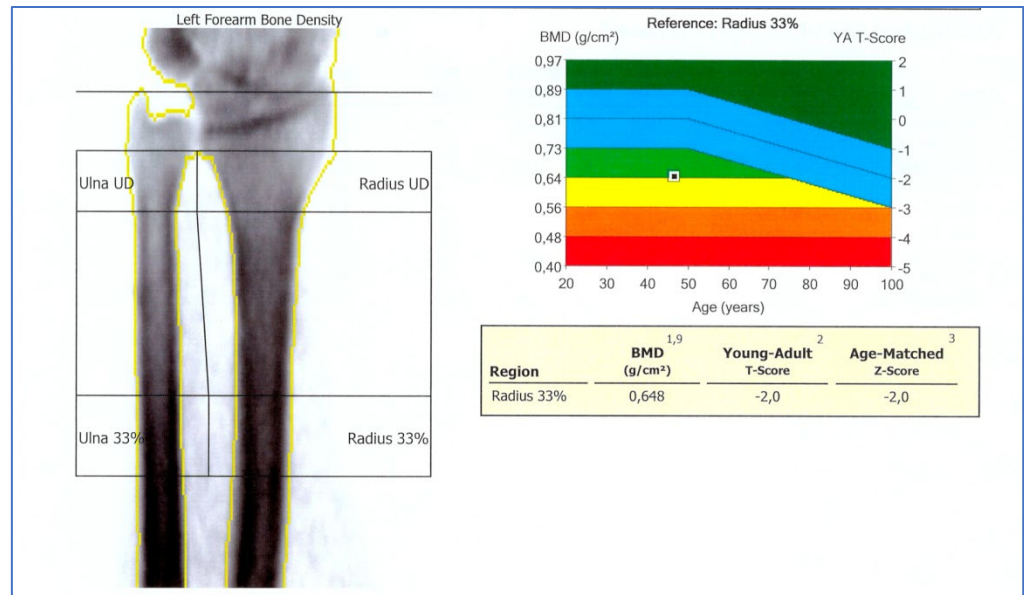


Figure 6. Cervical ultrasound (visit 2) - mixed formation with a cystic component, with some calcifications included, non-vascularized, with dimensions of 20/14.5/12mm, in the posterior area of the left thyroid lobe (a possible cystic adenoma parathyroid).

Scintigraphy with Tc-sestamibi showed no parathyroid fixation, so it was not a parathyroid adenoma, bringing the discussion to a possible adenopathy or thyroid cyst. This result also correlates with the normalized PTH level and total calcium values.

The final diagnosis was hyperparathyroidism secondary to vitamin D deficiency remitted under treatment and osteopenia. Bilateral total hip arthroplasty was performed for grade II/III bilateral hip osteoarthritis, secondary to avascular necrosis of the femoral head.

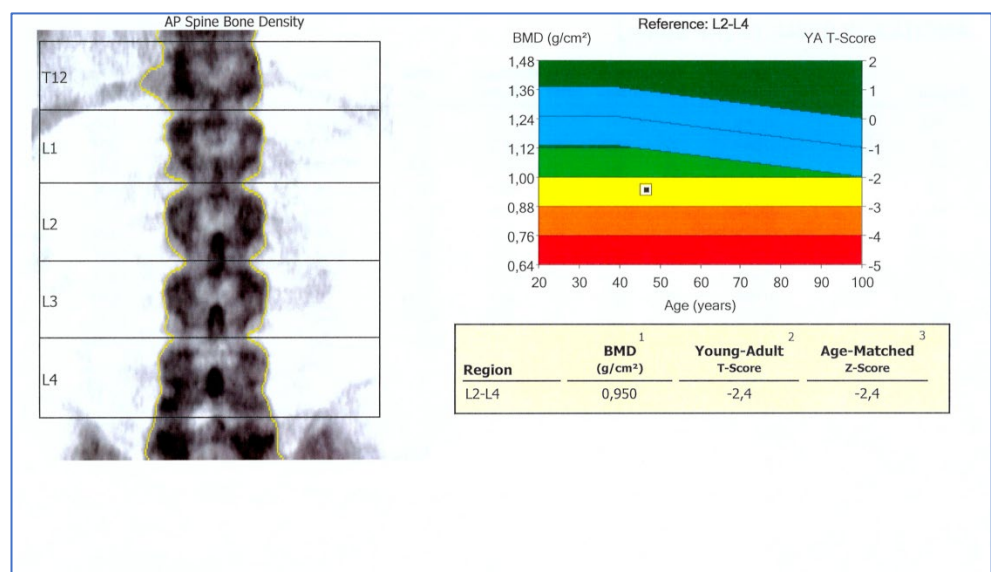
BMD values correspond to osteopenia correlated with low vitamin D levels (figures 7,8).



**ANCILLARY RESULTS [Left Forearm]**

Region	BMD (g/cm <sup>2</sup> ) <sup>1,9</sup>	Young-Adult (%) <sup>2</sup>	T-Score <sup>2</sup>	Age-Matched (%) <sup>3</sup>	Z-Score <sup>3</sup>	BMC (g) <sup>9</sup>	Area (cm <sup>2</sup> )
Radius UD	0,369	87	-1,3	87	-1,3	1,4	3,7
Ulna UD	0,325	-	-	-	-	0,6	1,9
Radius 33%	0,648	80	-2,0	80	-2,0	1,7	2,7
Ulna 33%	0,711	-	-	-	-	1,5	2,1
Both UD	0,354	-	-	-	-	2,0	5,5
Both 33%	0,676	-	-	-	-	3,2	4,7
Radius Total	0,539	88	-1,3	88	-1,3	7,0	13,0
Ulna Total	0,526	-	-	-	-	4,5	8,6
Both Total	0,534	-	-	-	-	11,6	21,7

Figure 7. DXA osteodensitometry at the level of the distal left forearm



ANCILLARY RESULTS [AP Spine]										
Region	1		2		3		BMC (g)	Area (cm <sup>2</sup> )	Width (cm)	Height (cm)
	BMD (g/cm <sup>2</sup> )	Young-Adult (%)	T-Score	Age-Matched (%)	Z-Score					
T12	0,858	-	-	-	-	-	11,9	13,8	4,5	3,05
L1	0,894	77	-2,2	78	-2,2		11,7	13,1	4,0	3,26
L2	0,974	79	-2,2	79	-2,2		13,4	13,7	4,0	3,47
L3	0,954	77	-2,4	77	-2,3		13,7	14,4	4,1	3,47
L4	0,928	75	-2,6	75	-2,5		15,4	16,6	4,6	3,57
L1-L2	0,935	78	-2,2	78	-2,2		25,1	26,8	4,0	6,72
L1-L3	0,942	78	-2,2	78	-2,2		38,7	41,2	4,0	10,19
L1-L4	0,938	77	-2,4	77	-2,3		54,1	57,7	4,2	13,76
L2-L3	0,964	78	-2,3	78	-2,3		27,1	28,1	4,1	6,93
L2-L4	0,950	77	-2,4	77	-2,4		42,4	44,7	4,3	10,50
L3-L4	0,940	76	-2,5	76	-2,4		29,1	31,0	4,4	7,04

Figure. 8. DXA osteodensitometry at the lumbar spine (L1-L4)

### 3. Discussion

Avascular necrosis is defined as the death of bone cells due to vascular impairment (11). Avascular bone necrosis commonly occurs following corticosteroid use, trauma, SLE, pancreatitis, alcoholism, gout, radiation, sickle cell disease, infiltrative diseases (e.g. Gaucher disease) and Caisson's disease (11,12).

The femoral head is most commonly affected, and patients usually present with hip and knee pain (11,12). Our patient presented with avascular necrosis of the right hip with referred right knee pain. The possible causes, in this case, were vitamin D deficiency correlated with secondary hyperparathyroidism.

Avascular necrosis or osteonecrosis is a condition in which the death of osteocytes and the loss of associated hematopoietic elements occurs, characterized by the appearance of focal lesions in weight-bearing joints (the hip). The pathophysiology of the disease still needs to be clarified. It is studied and treated as a vascular but also a bone disease. In patients with osteonecrosis, the number of mesenchymal stem cells (precursors of osteoblastic cells) is reduced, as is the proliferation rate of osteoblastic cells in the proximal femur (13). Our patient had no such risk factors for avascular necrosis of the femoral head, so we tried to identify another cause of bone changes in this case.

In a recent study, Dadra A. et al.(3) demonstrated widespread vitamin D deficiency in patients with hip fragility fractures. Also, the prevalence of secondary hyperparathyroidism was correlated with low vitamin D levels. The inverse correlation between PTH and vitamin D is well known, but this paper demonstrated that this correlation is more substantial in young Indian adults. Our young patient present also had a low level of vitamin D (12, 81ng/dl) at first evaluation, after the first arthroplasty, and it can be the single etiological factor in AVN apparition in both femoral heads. A high prevalence of osteoporosis was demonstrated in persons with fragility fractures (3).

In a study published by Gurion R. et al.(14) on Atherosclerosis Prevention in Pediatric Lupus Erythematosus (APPLE) trial, they asses the associations between AVN and Lupus Erythematosus disease activity and vitamin D deficiency in children (defined as serum 25-hydroxyvitamin D [25(OH)D] <20 ng/m). In this first report of vitamin D deficiency associated with AVN in pediatric lupus, there were lower levels of vitamin D in children who developed AVN during the three years of the study, but not statistically significant, probably because of the small number of patients enrolled (14).

In a recent study, Liang D. et al.(15) demonstrated that fenestration of the neck of the femoral head by the OCM ( Orthopedische Chirurgie München) approach mixed autologous tricalcium  $\beta$ -phosphate with porous bioceramic bone graft can effectively treat non-traumatic ON. In patients with 25(OH)D deficiency or ARCO (International Association Research Circulation Osseous) stage IIIA, the clinical failure rate was higher compared to

those without vitamin D deficiency, emphasizing the role of this vitamin not only in etiology but also in the treatment of AVN (15).

Our patient presented an advanced degree of osteonecrosis that required bilateral hip arthroplasty and then complex medical recovery, correlated with a deficient vitamin D level, unable to identify other causes of AVN.

Our case supports the physiopathological mechanism of hyperparathyroidism secondary to severe vitamin D deficiency with an impact on bone structure and function.

Gangji V. et al.(13) demonstrated that patients with AVN have a high prevalence of VDD but without secondary hyperparathyroidism, with a low bone turnover (by low osteocalcin levels and normal levels of C-telopeptide). Osteonecrosis was also associated with severe osteopenia (13). Our patient presented an essential deficiency of vitamin D with secondary hyperparathyroidism, not being confirmed by scintigraphy with Tc sestamibi. This parathyroid adenoma would have been responsible for primary hyperparathyroidism (16). Although the lesions at the femoral head level were severe, we performed the DXA only at the lumbar spine (score T=-2.4) and left forearm (score T=-2) with values corresponding to osteopenia.

Several studies have reported that vitamin D deficiency is associated with impaired muscle function and strength, increased risk of sarcopenia, and reduced physical performance (17,18, 19, 20). Thus, vitamin D deficiency negatively influences the musculoskeletal health and the rehabilitation process of patients.

In a paper published by Karim R. et al. (21), they presented an interesting case of a 41-years old man, with avascular necrosis of the right hip due to chronic use of corticotherapy, pain killers and anti-inflammatories drugs. Nonsteroidal antiinflammatories accumulate in the environment acting as chemical pollutants, while some forms of electrotherapy (ultrasound) have favorable biological effects without negative impact of the environment. In addition, physical agents used in medical rehabilitation can be a therapeutic alternative (22).

Early identification of AVN offers physicians possibility to prevent the evolution of necrosis, because the untreated AVN leads to secondary hip arthritis requiring hip arthroplasty (23,24).

Lai et al. (25) evaluated, in a randomized study the efficacy of alendronate, a bisphosphonate (70 mg orally daily for 25 weeks) in preventing femoral head collapse in patients with Steinberg Stage II or III atraumatic AVN osteonecrosis of the femoral head. They demonstrated that alendronate, by inhibiting osteoclast activity followed by influences of bone turnover and remodeling, and can delay or prevent collapse of the femoral head in osteonecrosis of the hip. (25,26) Based on this findings we recommended treatment with acidum risedronicum 35mg/week, another bisphosphonate for our patient before and after the second arthroplasty.

#### 4. Materials and Methods

We present the case of a 46-year-old male patient known with bilateral total hip arthroplasty for osteoarthritis secondary to avascular necrosis of the femoral head. The surgeries were performed two years ago at the left hip and one year ago at the right hip.

The patient was hospitalized in our Physical Medicine and Rehabilitation Department of Sibiu after the first and second intervention for mechanical pain and functional deficit of the hips and gait disorders.

It should be noted that the diagnosis of avascular necrosis of the both femoral heads was established four years ago. Revascularization drills were performed before arthroplasty to reestablish the disruption of blood supply to the proximal femur.

Clinical examination at the last admission revealed: supple postoperative scars on the outer side of the hips and lateral upper third of both thighs; pain on hips mobilization and decreased mobility for flexion = 110°, external rotation, and abduction = 30° and internal rotation = 20°; evaluation of the muscle strength using the Medical Research Council scale (MRC) highlighted mild functional deficit in following hips muscles: gluteus medius



and iliopsoas (value +3/5 MRC); without pathological changes on examination of deep tendon reflexes or plantar reflexes.

Functional evaluation reveals at admission: the visual analog scale (VAS) for pain intensity index = 6 in the right hip, = 4 in the left hip, the activities of daily living scale (ADL) index = 9 (quasi-independent), instrumental activities of daily living scale (IADL) index = 6/8 (aided), Functional Ambulation Categories scale (FAC) index = 4 (requires supervision on walking on stairs), quantified quality of life scale (after Flanagan) 76/112 (aided). According to these results, we found a slight deficit in self-care and locomotion.

Upon first admission to our physical medicine and rehabilitation department after the left hip arthroplasty, the current disability at the right hip and the critical deficiency of vitamin D due to the impairment of muscle metabolism adversely influenced the rehabilitation process.

In the case of both hospitalizations, the rehabilitation treatment had as objectives the increase of stability and mobility of the hips and the reeducation of walking. The means used were: short pulsating waves (Diapulse), laser therapy, massage therapy, kinesiotherapy, and occupational therapy. The evolution of the case was favorable with the improvement of disability, especially after right hip arthroplasty.

## 5. Conclusions

It is essential to evaluate the vitamin D deficiency in patients with osteonecrosis because it can be correlated with secondary hyperparathyroidism and osteoporosis. The presented case demonstrates that severe vitamin D deficiency can secondarily affect the structure of the femoral head through secondary hyperparathyroidism, producing AVN. Additional studies on large groups of patients are needed to establish the degree of correlation between vitamin D deficiency and AVN. Other studies are also required to demonstrate the impact of vitamin D deficiency on the rehabilitation of patients with various associated musculoskeletal or cardiovascular conditions.

**Author Contributions:** Conceptualization, C.D. and C.G.D.; methodology, R.C.C. and M.G.I.; validation, R.C.C., V.M.C., C.D., R.A.U. and L.I.; formal analysis, C.D.; investigation, C.G.D., C.D.; resources, M.S., C.D.; data curation, R.C.C., L.I., R.A.U.; writing—original draft preparation, C.D., C.G.D.; writing—review and editing, M.G.I.; visualization, V.M.C.; supervision, M.G.I. All authors have read and agreed to the published version of the manuscript.

*\*All authors had equal contribution in this paper.*

**Funding:** This research received no external funding.

**Institutional Review Board Statement:** The study was conducted in accordance with the Declaration of Helsinki and approved by the Institutional Review Board (no.2995/09.02.2023).

**Informed Consent Statement:** Informed consent was obtained from the subject involved in the study.

**Data Availability Statement:** Not applicable.

**Acknowledgments:** This article represent a teamwork of a multicenter university research group.

**Conflicts of Interest:** The authors declare no conflict of interest.

## References

1. Lips P. Vitamin D deficiency and secondary hyperparathyroidism in the elderly: consequences for bone loss and fractures and therapeutic implications. *Endocrine reviews*, 2001, 22.4: 477-501. <https://doi.org/10.1210/edrv.22.4.0437>.
2. Wang Q, Yu D, Wang J, Lin S. Association between vitamin D deficiency and fragility fractures in Chinese elderly patients: a cross-sectional study. *Ann Palliat Med* 2020;9(4):1660-1665. doi: 10.21037/apm-19-610.
3. Dadra A, Aggarwal S, Kumar P, Kumar V, Dibar DP, Bhadada SK. High prevalence of vitamin D deficiency and osteoporosis in patients with fragility fractures of hip: A pilot study. *J Clin Orthop Trauma*. 2019 Nov-Dec;10(6):1097-1100. doi: 10.1016/j.jcot.2019.03.012. Epub 2019 Mar 21. PMID: 31708635; PMCID: PMC6834936.
4. Kamal, D., Traistaru, R., Alexandru, D., Grecu, D. & Mogoanta, L. Epidemiologic study of avascular necrosis of the femoral head. *Curr. Health Sci. J.* 39 (2013).

5. Mont MA, Hungerford DS. Non-traumatic avascular necrosis of the femoral head. *J Bone Joint Surg Am.* 1995;77:459–474. doi: 10.2106/00004623-199503000-00018.
6. Chao Y-C, Wang S-J, Chu H-C, Chang W-K, Hsieh T-Y. Investigation of alcohol metabolizing enzyme genes in Chinese alcoholics with avascular necrosis of hip joint, pancreatitis and cirrhosis of the liver. *Alcohol and Alcoholism.* 2003;38:431–436. doi: 10.1093/alcalc/agg106.
7. Narayanan A, Khanchandani P, Borkar RM, Ambati CR, Roy A, Han X, Bhoskar RN, Ragampeta S, Gannon F, Mysorekar V, Karanam B, V SM, Sivaramakrishnan V. Avascular Necrosis of Femoral Head: A Metabolomic, Biophysical, Biochemical, Electron Microscopic and Histopathological Characterization. *Sci Rep.* 2017 Sep 6;7(1):10721. doi: 10.1038/s41598-017-10817-w. PMID: 28878383; PMCID: PMC5587540.
8. Guggenbuhl, P.; Robin, F.; Cadiou, S.; Albert, J.D. Etiology of avascular osteonecrosis of the femoral head. *Morphologie* 2021, 105, 80–84.
9. Petek D, Hannouche D, & Suva D. Osteonecrosis of the femoral head: pathophysiology and current concept of treatment. *EFORT Open Reviews* 4(3), 85-97. Retrieved Dec10, 2022.
10. Jones J.P., Jr. Intravascular coagulation and osteonecrosis. *Clin Orthop.* 1992;277:41–53. [PubMed] [Google Scholar] [Ref list]
11. Yochum T, Rowe L. *Essentials of skeletal radiology.* 2nd ed. Baltimore: Williams & Wilkins 1996; 1260–1263.
12. Tierney Jr. LM, McPhee SJ, Papadakis MA. *Current Medical diagnosis and treatment.* 36th ed. Stamford: Appleton & Lange 1997; 798–799.
13. Gangji V. Vitamin D deficiency and low bone turnover in patients with osteonecrosis. *Orthopaedic Proceedings.* Vol 94-B, Suppl VIII. Feb 2018.
14. Gurion, R., Tangpricha, V., Yow, E., Schanberg, L.E., McComsey, G., Robinson, A. and (2014), A32: Low Vitamin D Status is Associated with Avascular Necrosis: An Atherosclerosis Prevention in Pediatric Lupus Erythematosus Substudy. *Arthritis & Rheumatology*, 66: S49-S50. <https://doi.org/10.1002/art.38448>.
15. Liang, D., Pei, J., Zhang, L. et al. Treatment of pre-collapse non-traumatic osteonecrosis of the femoral head through Orthopdische Chirurgie München approach combined with autologous bone mixed with  $\beta$ -tricalcium phosphate porous bioceramic bone graft: a retrospective study of mid-term results. *J Orthop Surg Res* 16, 492 (2021). <https://doi.org/10.1186/s13018-021-02632-x>.
16. M. Stanciu, LC. Boicean, FL. Popa. The rol of combined techniques of scintigraphy and SPECT/CT in diagnosis of primary hyperparathyroidism – clinical case report. *Medicine* 2019, 98:4(e14154), <http://dx.doi.org/10.1097/MD.00000000000014154>.
17. Popa FL, Stanciu M, Bighea A, Berteanu M, Totoianu I Gh, Rotaru M. Decreased serum levels of sex steroids associated with osteoporosis in a group of Romanian male patients. *Romanian Journal of Laboratory Medicine.* 2016. 24(1):75-82. DOI:10.1515/rrml-2016-0014
18. SE. Bollen, JJ. Bass, S Fujita, D Wilkinson, M Hewison, PJ Atherton. The Vitamin D/Vitamin D receptor (VDR) axis in muscle atrophy and sarcopenia. *Cellular Signalling*, Vol 96, August 2022, 110355; <https://doi.org/10.1016/j.cellsig.2022.110355>.
19. J. Yoo, H.J. Chung, B.G. Kim, Y. Jung, K. Baek, M. Song, M. Cho. Comparative analysis of the association between various serum vitamin D biomarkers and sarcopenia. *J. Clin. Lab. Anal.*, 35 (2021), 10.1002/jcla.23946.
20. Grimaldi AS, Parker BA, Capizzi JA, Clarkson PM, Pescatello LS, White MC, Thompson PD. 25(OH) Vitamin D Is Associated with Greater Muscle Strength in Healthy Men and Women. *Medicine & Science in Sports & Exercise* 45(1):p 157-162, January 2013. | DOI: 10.1249/MSS.0b013e31826c9a78.
21. Karim R, Goel KD. Avascular necrosis of the hip in a 41-year-old male: a case study. *J Can Chiropr Assoc.* 2004 Jun;48(2):137-41. PMID: 17549225; PMCID: PMC1840046.
22. Ungur RA, Ciortea VM, Irsay L, Ciubean AD, Năsui BA, Codea RA, Singurean VE, Groza OB, Căinap S, Martiș Petruț GS, et al. Can Ultrasound Therapy Be an Environmental-Friendly Alternative to Non-Steroidal Anti-Inflammatory Drugs in Knee Osteoarthritis Treatment? *Materials* 2021, 14, 2715. <https://doi.org/10.3390/ma14112715>.
23. Tripathy, S.K.; Goyal, T.; Sen, R.K. Management of femoral head osteonecrosis: Current concepts. *Indian J. Orthop.* 2015, 49, 28–45.
24. Petrigliano, Frank A MD<sup>\*</sup>; Lieberman, Jay R MD<sup>†</sup>. Osteonecrosis of the Hip: Novel Approaches to Evaluation and Treatment. *Clinical Orthopaedics and Related Research* 465():p 53-62, December 2007. | DOI: 10.1097/BLO.0b013e3181591c92
25. Lai KA, Shen WJ, Yang CY, Shao CJ, Hsu JT, Lin RM. The use of alendronate to prevent early collapse of the femoral head in patients with nontraumatic osteonecrosis. A randomized clinical study. *J Bone Joint Surg Am.* 2005;87:2155-2159.
26. Çalapkulu M, Kızılgül M, Sencar ME, Düğger H, Uçan B, Çakal E, Özbek M. Avascular necrosis of the femoral head due to low-dose corticosteroid used in a patient with panhypopituitarism: A case report and literature review. *Jt Dis Relat Surg.* 2020;31(2):390-394. doi: 10.5606/ehc.2020.72773. Epub 2020 Jun 18. PMID: 32584743; PMCID: PMC7489177.