

VirtualArm.

MCFADYEN, M.C.E.

2012

This is a series of images from the presentation-style demo of the above educational resource. This demo is hosted on Prezi: <https://prezi.com/p/embed/zipoj1tqucqi/>.



ARTICULATE: 3D ANATOMY

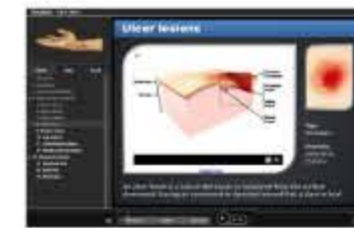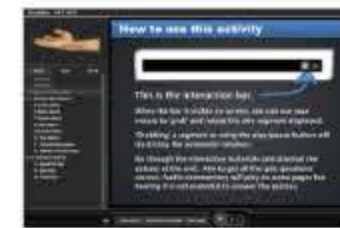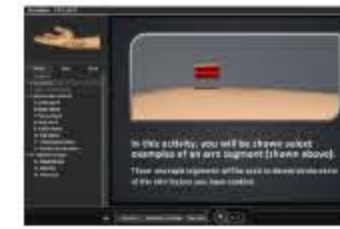USING ARTICULATE TO TEACH ABOUT ANATOMY



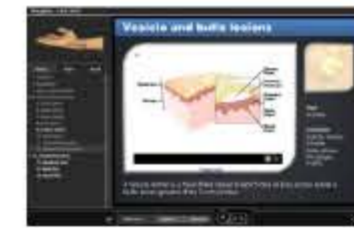First page
3D model of Arm
• Produced using opensource "MakeHuman" Software
• Edited using Google Sketchup



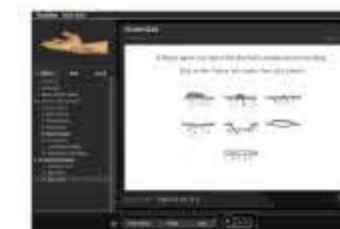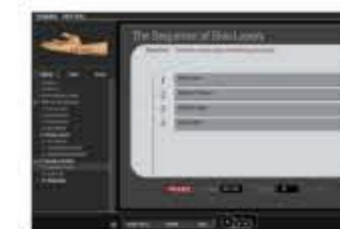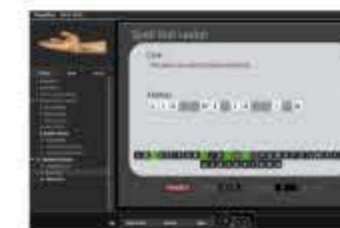Intro page
Informs about the format used
• Animation of skin block
• Used to indicate the notion of the 'Arm segment'
• Interactive bar intro



Example Lesions
Ulcer and Bulla
• Sketchup Models
• Animated into mock 3D using flash image sequence
• Allows user to grab and spin segment



Quizzes
Used to check understanding
• Spell and Sequence: Simple quizzes built right into Articulate presenter (no need to quizmaker)
• Image map quizmaker added



Why?

More 'dimensional' support materials needed for course

- Existing materials useful but lack depth
- Needed to address the different ways that students appeared to learn
- Interested in reusable content that is able to be developed at later date

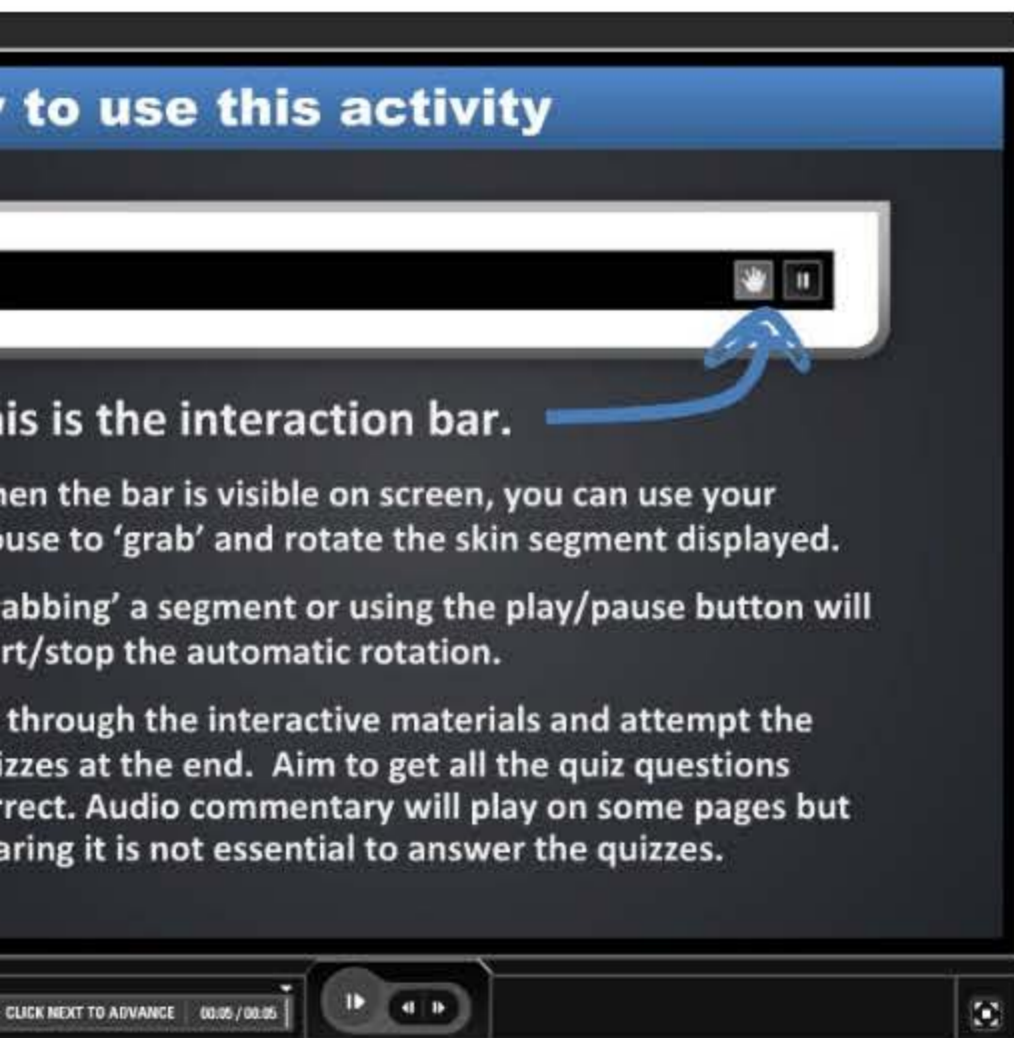
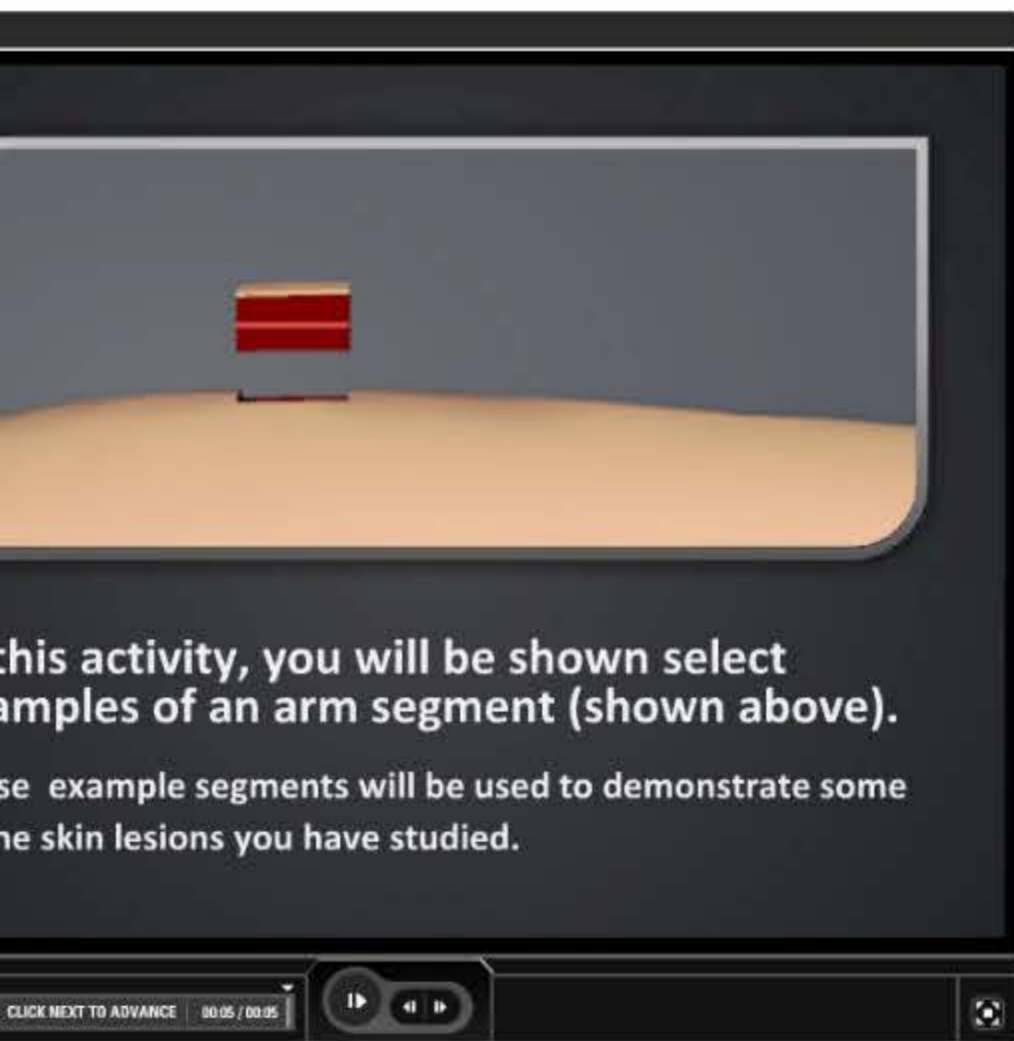
How?

Identified support personnel, communicated idea using existing materials and outlined project

- Lecturer arranged for meeting with a support partner (PALS elearning support)
- Arranged meeting and brought in existing materials to view with written notes
- Projected required-by date, then worked backwards to identify milestones

Where to next?

- Obtain feedback, collaborate with fellow lecturers, develop with added details
- Engage with students and collect feedback from multiple sources (positive to-date)
- Discuss with colleagues about areas of use in other modules
- Add more details i.e. Immune system skin layers, burns and bedsores



Why?

More 'dimensional' support materials needed for course

- Existing materials useful but lack depth
- Needed to address the different ways that students appeared to learn
- Interested in reusable content that is able to be developed at later date

How?

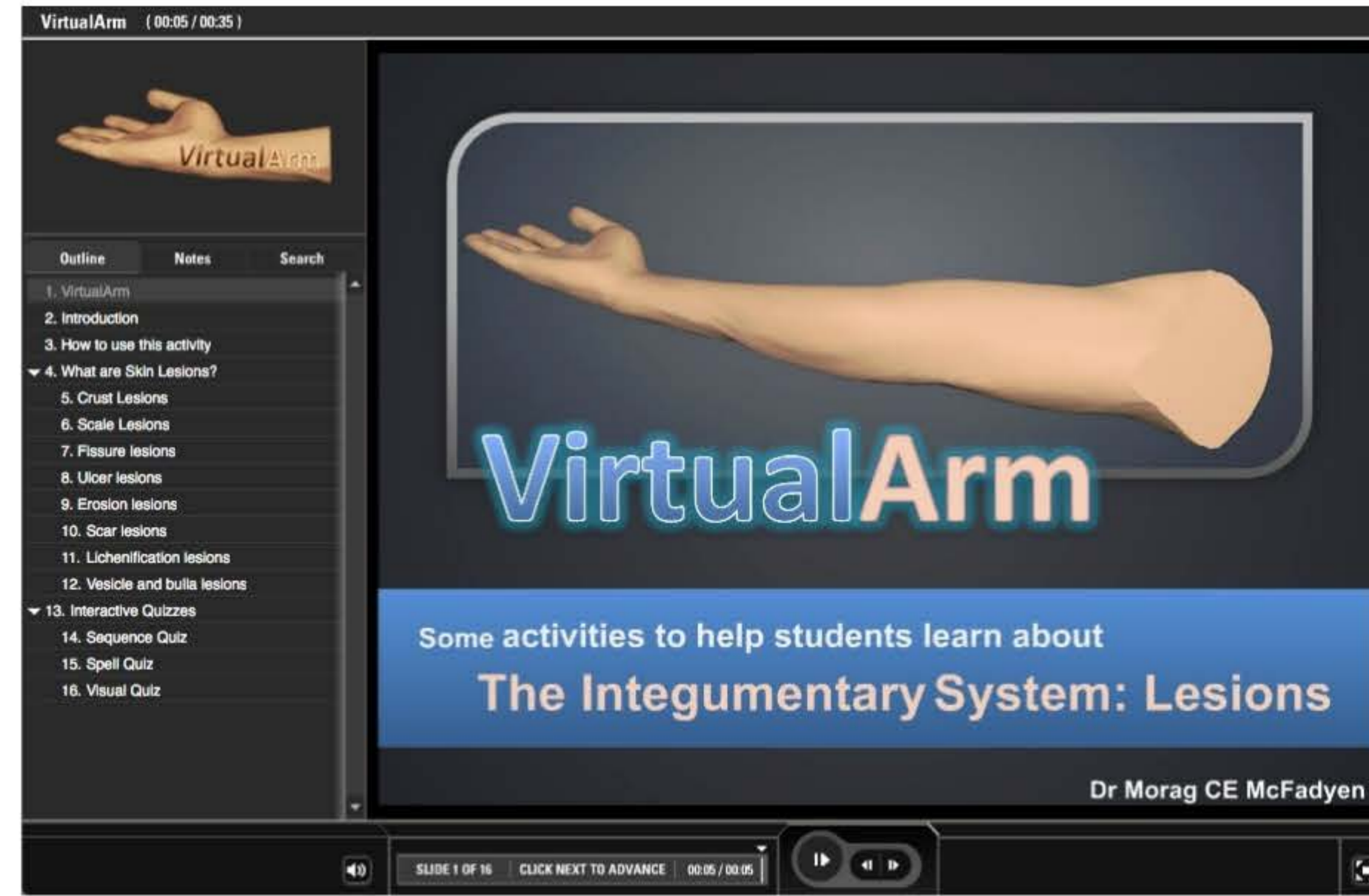
Identified support personnel,
communicated idea using existing
materials and outlined project

- Lecturer arranged for meeting with a support partner (PALS elearning support)
- Arranged meeting and brought in existing materials to view with written notes
- Projected required-by date, then worked backwards to identify milestones

Spell that Lesion

Clue:

This lesion is a result of atopic dermatitis



Intro page

Informs about the used

- Animation of skin
- Used to indicate the notion of the 'Arm segment'
- Interactive bar

First page

3D model of Arm

- Produced using open source "MakeHuman" Software
- Edited using Google Sketchup

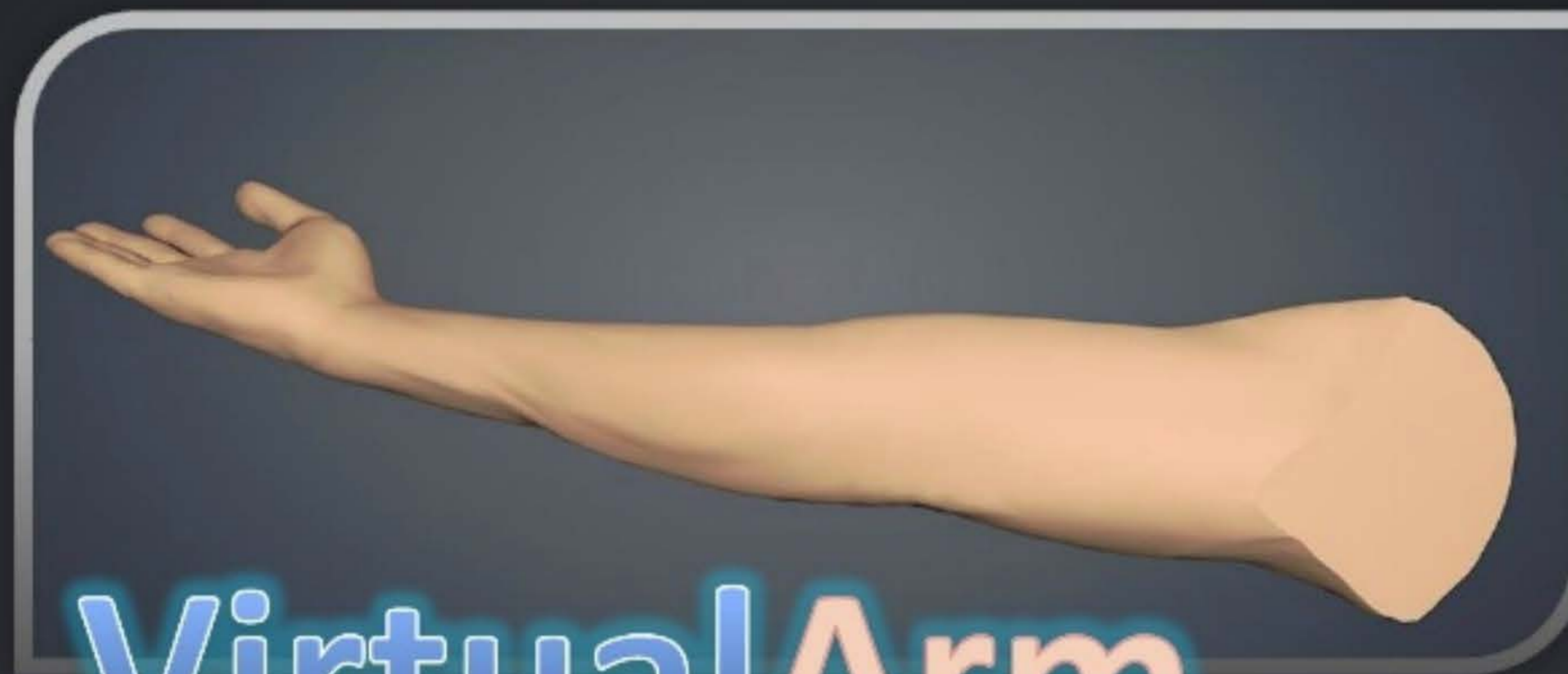

Outline

Notes

Search

- 1. VirtualArm
- 2. Introduction
- 3. How to use this activity
- ▼ 4. What are Skin Lesions?
 - 5. Crust Lesions
 - 6. Scale Lesions
 - 7. Fissure lesions
 - 8. Ulcer lesions
 - 9. Erosion lesions
 - 10. Scar lesions
 - 11. Lichenification lesions
 - 12. Vesicle and bulla lesions
- ▼ 13. Interactive Quizzes
 - 14. Sequence Quiz
 - 15. Spell Quiz
 - 16. Visual Quiz



VirtualArm

Some activities to help students learn about

The Integumentary System: Lesions

Dr Morag CE McFadyen



SLIDE 1 OF 16 CLICK NEXT TO ADVANCE 00:05 / 00:05

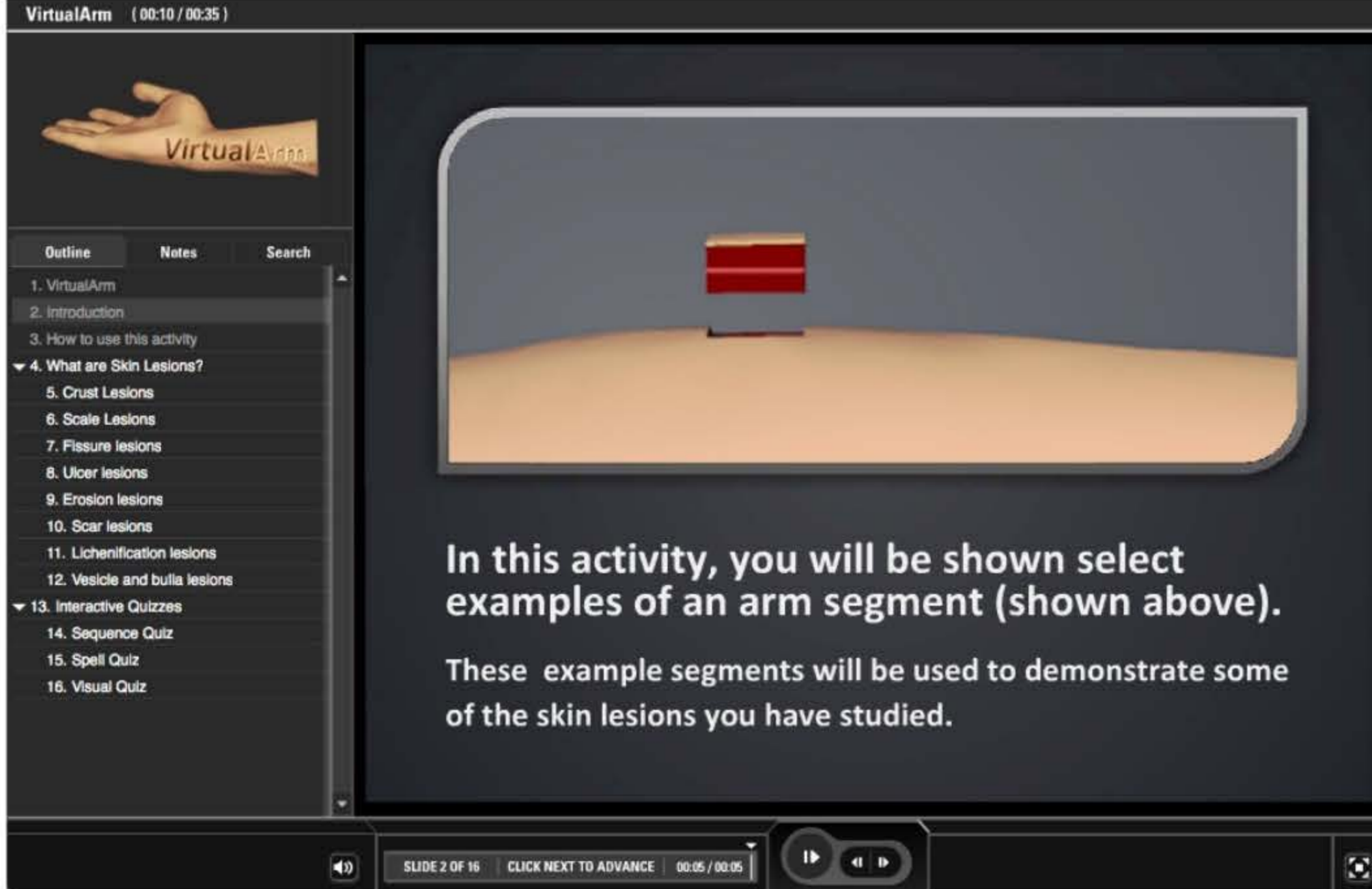




Intro page

Informs about the format used

- Animation of skin block
- Used to indicate the notion of the 'Arm segment'
- Interactive bar intro



VirtualArm (00:10 / 00:35)

VirtualArm

Outline Notes Search

1. VirtualArm
2. Introduction
3. How to use this activity
- ▼ 4. What are Skin Lesions?
5. Crust Lesions
6. Scale Lesions
7. Fissure lesions
8. Ulcer lesions
9. Erosion lesions
10. Scar lesions
11. Lichenification lesions
12. Vesicle and bulla lesions
- ▼ 13. Interactive Quizzes
14. Sequence Quiz
15. Spell Quiz
16. Visual Quiz

In this activity, you will be shown select examples of an arm segment (shown above).
These example segments will be used to demonstrate some of the skin lesions you have studied.

SLIDE 2 OF 16 | CLICK NEXT TO ADVANCE | 00:05 / 00:05



VirtualArm (00:15 / 00:35)

VirtualArm

Outline Notes Search

1. VirtualArm
2. Introduction
3. How to use this activity
- ▼ 4. What are Skin Lesions?
5. Crust Lesions
6. Scale Lesions
7. Fissure lesions
8. Ulcer lesions
9. Erosion lesions
10. Scar lesions
11. Lichenification lesions

How to use this activity

This is the interaction bar.

When the bar is visible on screen, you can use your mouse to 'grab' and rotate the skin segment displayed.

'Grabbing' a segment or using the play/pause button will start/stop the automatic rotation.

SLIDE 2 OF 16 | CLICK NEXT TO ADVANCE | 00:05 / 00:05




Outline

Notes


Search

1. VirtualArm
2. Introduction
3. How to use this activity
- ▼ 4. What are Skin Lesions?
 5. Crust Lesions
 6. Scale Lesions
 7. Fissure lesions
 8. Ulcer lesions
 9. Erosion lesions
 10. Scar lesions
 11. Lichenification lesions
 12. Vesicle and bulla lesions
- ▼ 13. Interactive Quizzes
 14. Sequence Quiz
 15. Spell Quiz
 16. Visual Quiz



In this activity, you will be shown select examples of an arm segment (shown above).

These example segments will be used to demonstrate some of the skin lesions you have studied.





Outline

Notes

Search

1. VirtualArm

2. Introduction

3. How to use this activity

▼ 4. What are Skin Lesions?

5. Crust Lesions

6. Scale Lesions

7. Fissure lesions

8. Ulcer lesions

9. Erosion lesions

10. Scar lesions

11. Lichenification lesions

12. Vesicle and bulla lesions


▼ 13. Interactive Quizzes

14. Sequence Quiz

15. Spell Quiz

16. Visual Quiz

How to use this activity



This is the interaction bar.

When the bar is visible on screen, you can use your mouse to 'grab' and rotate the skin segment displayed.

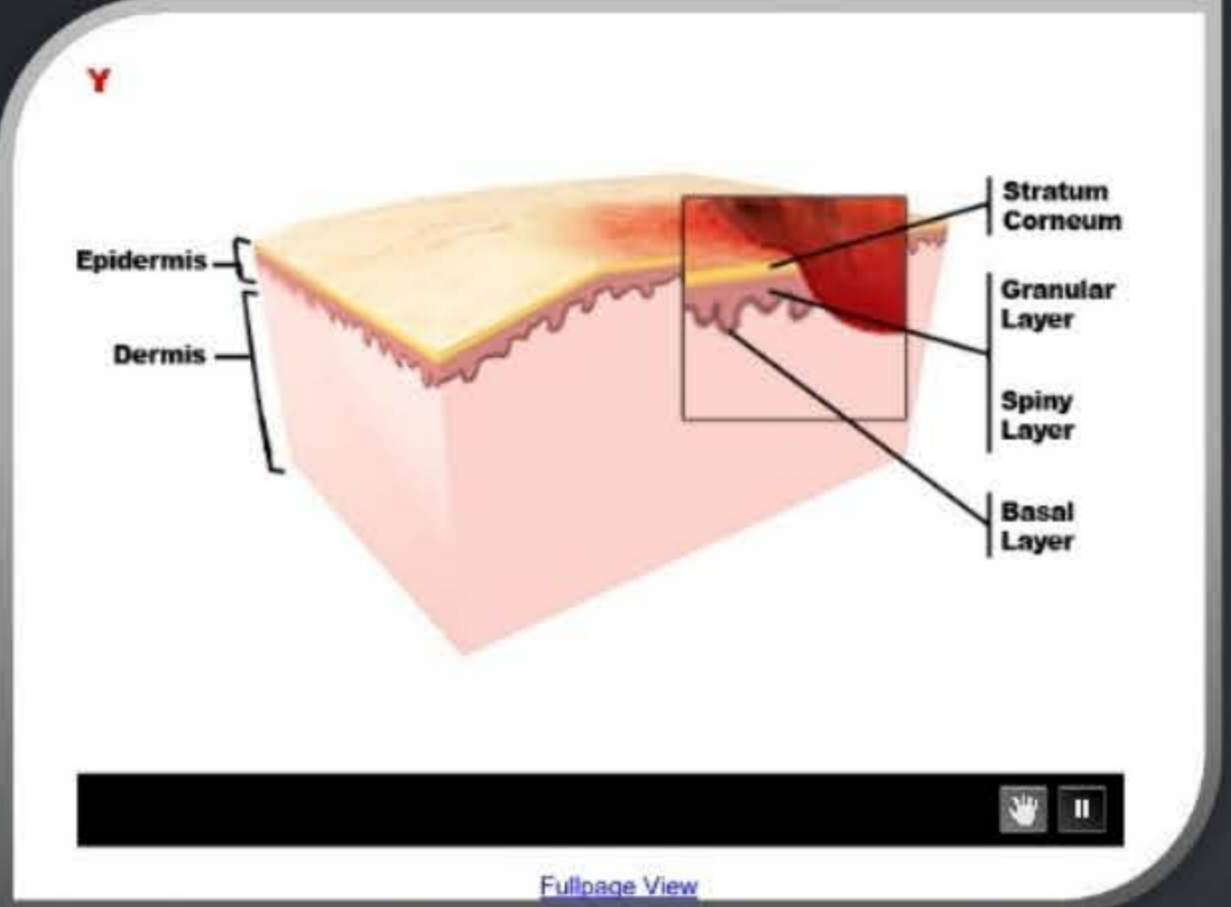
'Grabbing' a segment or using the play/pause button will start/stop the automatic rotation.

Go through the interactive materials and attempt the quizzes at the end. Aim to get all the quiz questions correct. Audio commentary will play on some pages but hearing it is not essential to answer the quizzes.



VirtualArm (00:18 / 00:35)

Ulcer lesions




Type
Secondary

Examples
Stasis Ulcer,
Chancere

An ulcer lesion is a loss of skin tissue or substance from the surface downward, leaving an uncovered or denuded wound that is slow to heal.

SLIDE 8 OF 16 PAUSED 00:03 / 00:33



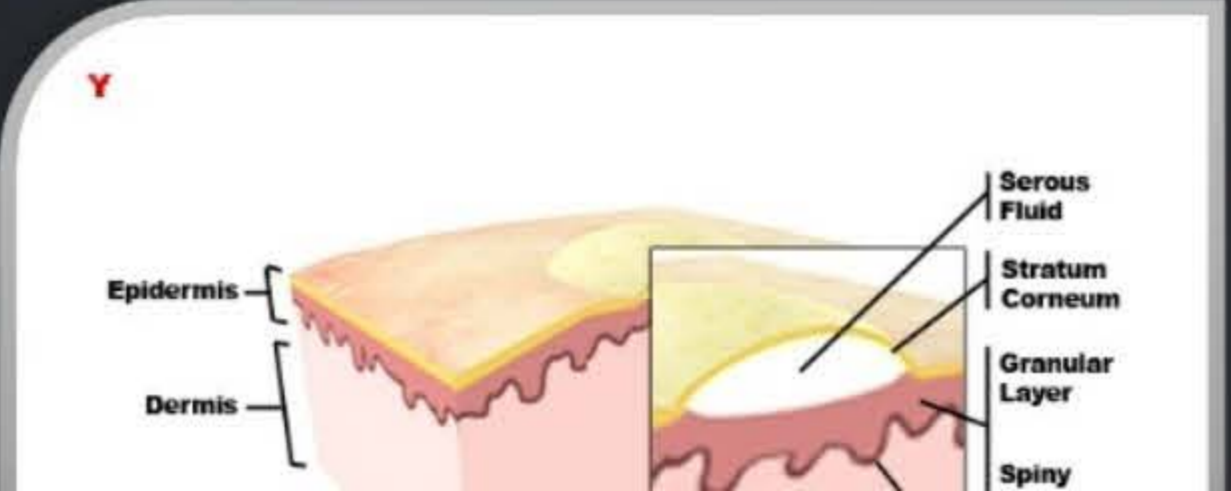
Example Lesions

Ulcer and Bulla

- Sketchup Models
- Animated into mock 3D using flash image sequence
- Allows user to grab and spin segment

VirtualArm (00:41 / 00:35)

Vesicle and bulla lesions



Type

SLIDE 8 OF 16 PAUSED 00:03 / 00:33



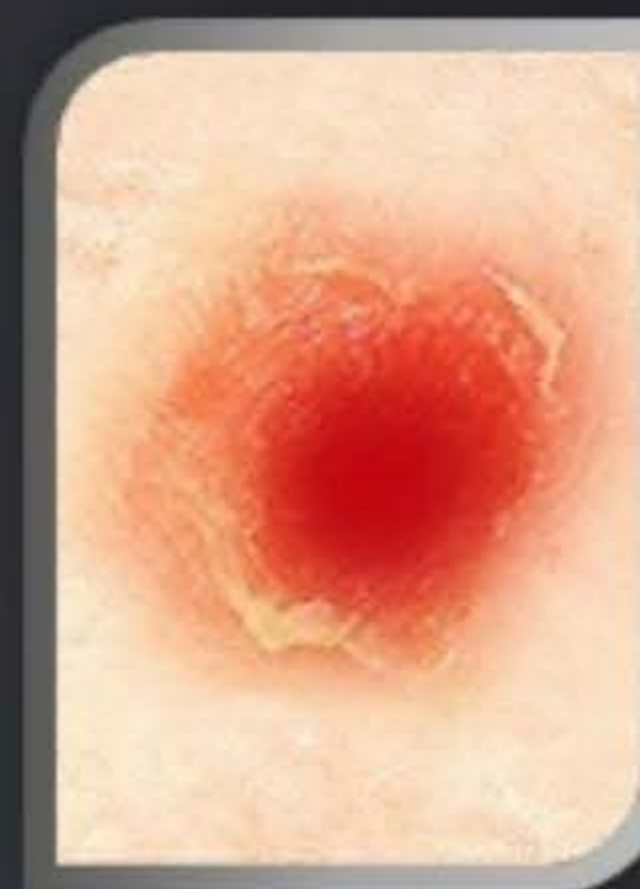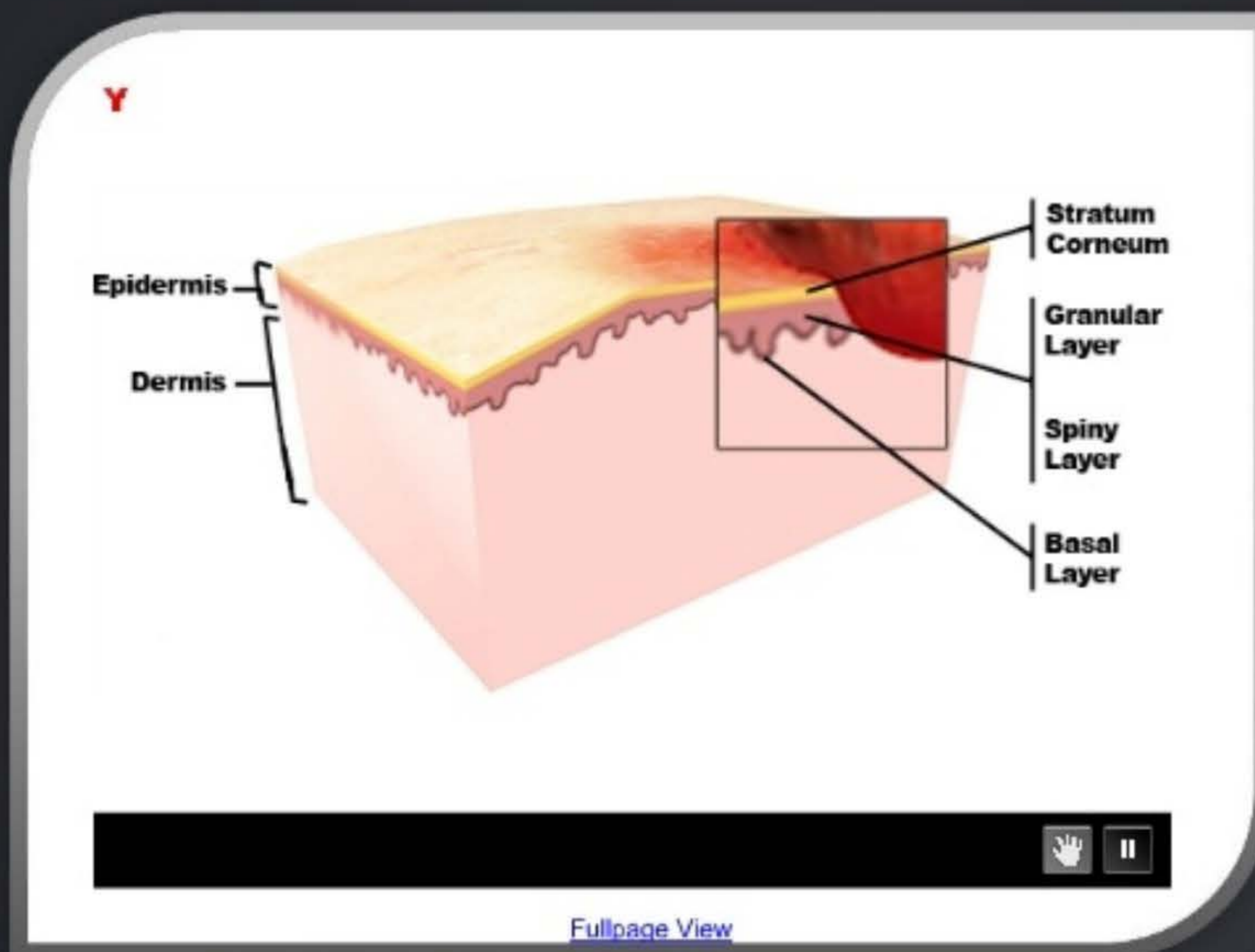
Outline

Notes

Search

1. VirtualArm
2. Introduction
3. How to use this activity
- ▼ 4. What are Skin Lesions?
 5. Crust Lesions
 6. Scale Lesions
 7. Fissure lesions
 8. Ulcer lesions
 9. Erosion lesions
 10. Scar lesions
 11. Lichenification lesions
 12. Vesicle and bulla lesions
- ▼ 13. Interactive Quizzes
 14. Sequence Quiz
 15. Spell Quiz
 16. Visual Quiz

Ulcer lesions



Type
Secondary

Examples
Stasis Ulcer,
Chancre

An ulcer lesion is a loss of skin tissue or substance from the surface downward, leaving an uncovered or denuded wound that is slow to heal.





Outline

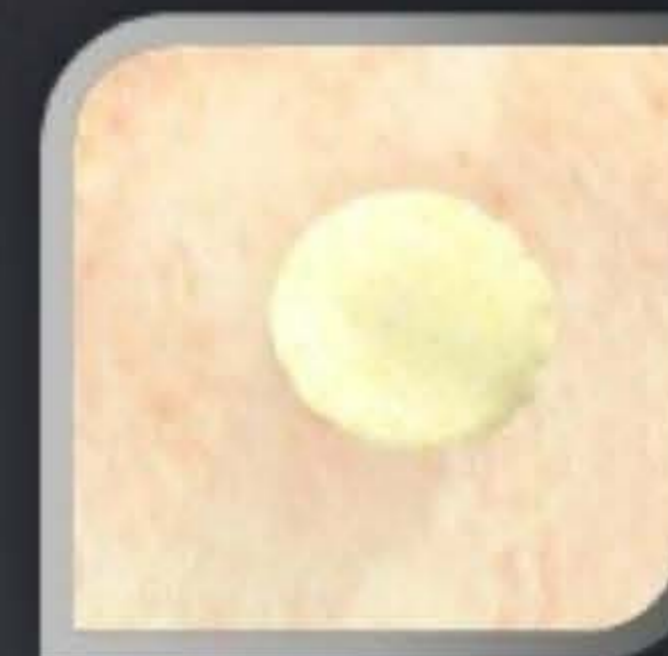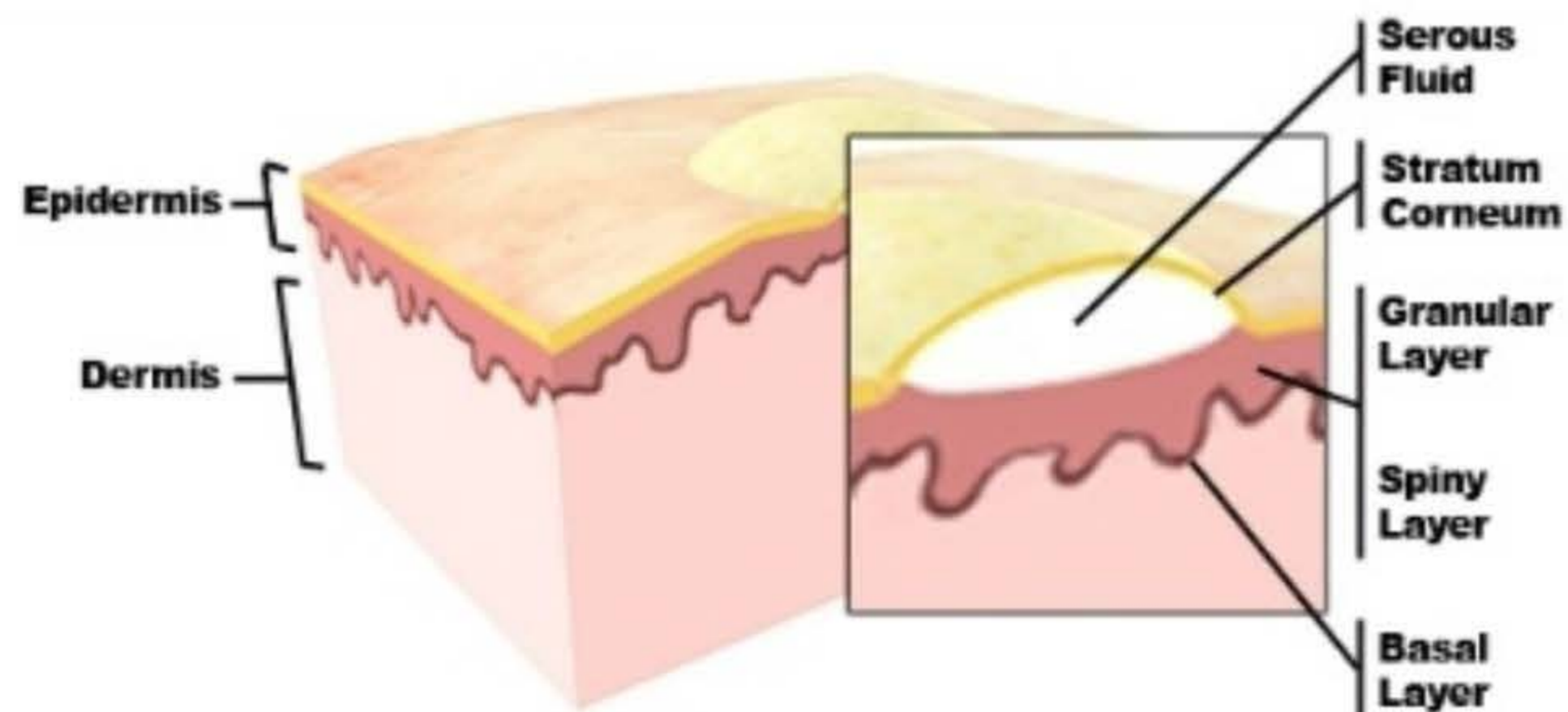
Notes

Search

1. VirtualArm
2. Introduction
3. How to use this activity
- ▼ 4. What are Skin Lesions?
 5. Crust Lesions
 6. Scale Lesions
 7. Fissure lesions
 8. Ulcer lesions
 9. Erosion lesions
 10. Scar lesions
 11. Lichenification lesions
 12. Vesicle and bulla lesions
- ▼ 13. Interactive Quizzes
 14. Sequence Quiz
 15. Spell Quiz
 16. Visual Quiz

Vesicle and bulla lesions

Y



Type
Primary

Examples
Vesicle: Herpes Simplex
Bulla: Blister, Pemphigus Vulgaris

[Fullpage View](#)

A vesicle lesion is a fluid-filled raised lesion 5 mm or less across while a bulla lesion greater than 5 mm across.



SLIDE 12 OF 16

PLAYING

00:26 / 01:01



Quizzes

Used to check understanding

- Spell and Sequence: Simple quizzes built right into Articulate presenter (no need to quizmaker)
- Image-map quizmaker added

The screenshot shows the VirtualArm interface with a quiz titled "Spell that Lesion". The clue is "This lesion is a result of atopic dermatitis". The answer is displayed as "L I C H E N I T I C I N" with some letters in boxes. Below the answer is a keyboard layout with letters A-Z and numbers 1-0. The interface includes a sidebar with a table of contents, a "PAUSE II" button, a timer at 00:43, a score of 0, and a progress indicator "1 of 4".

| Outline | Notes | Search |
|-------------------------------|-------|--------|
| 1. VirtualArm | | |
| 2. Introduction | | |
| 3. How to use this activity | | |
| 4. What are Skin Lesions? | | |
| 5. Crust Lesions | | |
| 6. Scale Lesions | | |
| 7. Fissure lesions | | |
| 8. Ulcer lesions | | |
| 9. Erosion lesions | | |
| 10. Scar lesions | | |
| 11. Lichenification lesions | | |
| 12. Vesicle and bulla lesions | | |
| 13. Interactive Quizzes | | |
| 14. Sequence Quiz | | |
| 15. Spell Quiz | | |
| 16. Visual Quiz | | |

The screenshot shows the VirtualArm interface with a quiz titled "The Sequence of Skin Layers". The question is "Enter the correct order of following skin layers:". There are four numbered input fields with the following text: 1. Basal Layer, 2. Stratum Corneum, 3. Granular Layer, 4. Spiny Layer. The interface includes a sidebar with a table of contents, a "PAUSE II" button, a timer at 00:16, a score of 0, and a progress indicator "1 of 3".

| Outline | Notes | Search |
|-------------------------------|-------|--------|
| 1. VirtualArm | | |
| 2. Introduction | | |
| 3. How to use this activity | | |
| 4. What are Skin Lesions? | | |
| 5. Crust Lesions | | |
| 6. Scale Lesions | | |
| 7. Fissure lesions | | |
| 8. Ulcer lesions | | |
| 9. Erosion lesions | | |
| 10. Scar lesions | | |
| 11. Lichenification lesions | | |
| 12. Vesicle and bulla lesions | | |
| 13. Interactive Quizzes | | |
| 14. Sequence Quiz | | |
| 15. Spell Quiz | | |
| 16. Visual Quiz | | |



Outline Notes Search

- 1. VirtualArm
- 2. Introduction
- 3. How to use this activity
- ▼ 4. What are Skin Lesions?
 - 5. Crust Lesions
 - 6. Scale Lesions
 - 7. Fissure lesions
 - 8. Ulcer lesions
 - 9. Erosion lesions**
 - 10. Scar lesions
 - 11. Lichenification lesions
 - 12. Vesicle and bulla lesions
- ▼ 13. Interactive Quizzes
 - 14. Sequence Quiz
 - 15. Spell Quiz
 - 16. Visual Quiz

Spell that Lesion

Clue:

This lesion is a result of atopic dermatitis

Answer:

L I C [] [] N I [] I C [] [] I [] N

| | | | | | | | | | | | | | | | | | | | | | | | | | |
|---|---|---|---|---|---|---|---|---|---|---|---|---|---|---|---|---|---|---|---|---|---|---|---|---|---|
| A | B | C | D | E | F | G | H | I | J | K | L | M | N | O | P | Q | R | S | T | U | V | W | X | Y | Z |
| | | | | | | | | 1 | 2 | 3 | 4 | 5 | 6 | 7 | 8 | 9 | 0 | | | | | | | | |

PAUSE II

TIME 00:43

SCORE 0

1 of 4



SLIDE 15 OF 16

PLAYING

00:00 /





Outline

Notes

Search

1. VirtualArm
2. Introduction
3. How to use this activity
- ▼ 4. What are Skin Lesions?
 5. Crust Lesions
 6. Scale Lesions
 7. Fissure lesions
 8. Ulcer lesions
 - 9. Erosion lesions**
 10. Scar lesions
 11. Lichenification lesions
 12. Vesicle and bulla lesions
- ▼ 13. Interactive Quizzes
 14. Sequence Quiz
 15. Spell Quiz
 - 16. Visual Quiz**

The Sequence of Skin Layers

Question: Enter the correct order of following skin layers:

- 1 Basal Layer
- 2 Stratum Corneum
- 3 Granular Layer
- 4 Spiny Layer

PAUSE II

TIME 00:16

SCORE 0

1 of 3



SLIDE 14 OF 16

PLAYING

00:00 /





Outline

Notes

Search

1. VirtualArm
2. Introduction
3. How to use this activity
- ▼ 4. What are Skin Lesions?
 5. Crust Lesions
 6. Scale Lesions
 7. Fissure lesions
 8. Ulcer lesions
 - 9. Erosion lesions**
 10. Scar lesions
 11. Lichenification lesions
 12. Vesicle and bulla lesions
- ▼ 13. Interactive Quizzes
 14. Sequence Quiz
 15. Spell Quiz
 16. Visual Quiz

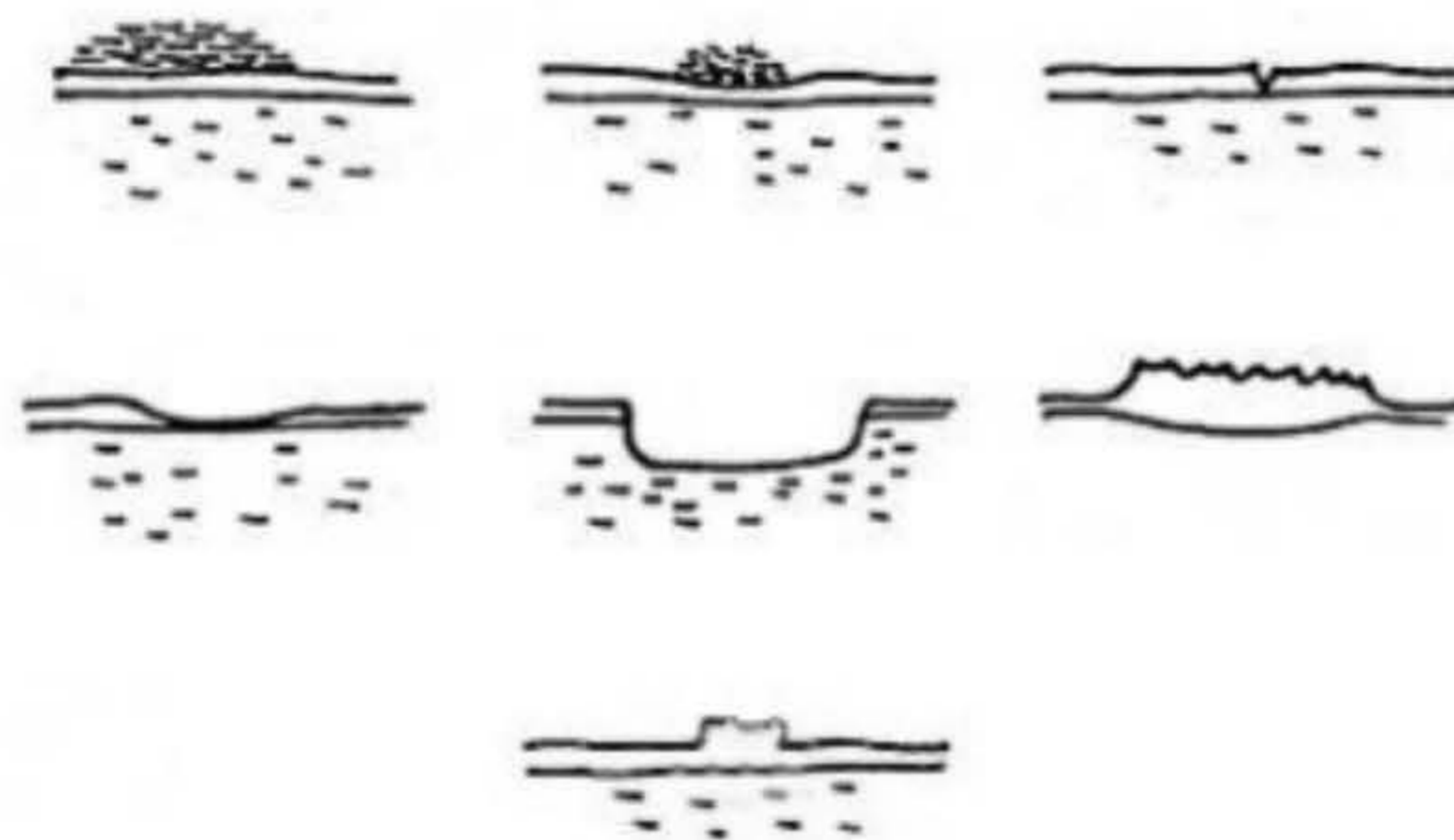
Visual Quiz

Question 1 of 7

Point Value: 10

A fissure lesion is a crack in the skin that is usually narrow but deep.

Click on the 'Fissure' skin lesion, then click submit.



Score so far: 0 points out of 0


SUBMIT



SLIDE 16 OF 16

PLAYING

00:00 /



PAUSE II | TIME 00:43 | SCORE 0 | 1 of 4

The Sequence of Skin Layers

Question: Enter the correct order of following skin layers:

- 1 Basal Layer
- 2 Stratum Corneum
- 3 Granular Layer
- 4 Spiny Layer

PAUSE II | TIME 00:16 | SCORE 0 | 1 of 3

Visual Quiz

Question 1 of 7 | Point Value: 10

A fissure lesion is a crack in the skin that is usually narrow but deep.

Click on the 'Fissure' skin lesion, then click submit.

Score so far: 0 points out of 0 | SUBMIT

Where to next?

Obtain feedback, collaborate with fellow lecturers, develop with added details

- Engage with students and collect feedback from multiple sources (positive to-date)
- Discuss with colleagues about areas of use in other modules
- Add more details i.e. Immune system skin layers, burns and bedsores