

Journal section: *Special patients*

Publication Types: *Review*

Fragile X-syndrome: Literature review and report of two cases

Lourdes Ridaura-Ruiz ¹, Milva Quinteros-Borgarello ², Leonardo Berini-Aytés ³, Cosme Gay-Escoda ⁴

¹ DDS and Resident of the Master of Oral Surgery and Implantology. University of Barcelona Dental School

² DDS and Associate Professor of Oral Surgery. Professor of the Master of Oral Surgery and Implantology. University of Barcelona Dental School

³ DDS, MD. Assistant Professor of Oral and Maxillofacial Surgery. Professor of the Master of Oral Surgery and Implantology. University of Barcelona Dental School

⁴ DDS, MD, PhD. Chairman of Oral and Maxillofacial Surgery. Director of the Master of Oral Surgery and Implantology. University of Barcelona Dental School. Oral and maxillofacial surgeon of the Teknon Medical Center, Barcelona (Spain)

Correspondence:

Centro Médico Teknon

C/ Vilana 12

08022-Barcelona (Spain)

cgay@ub.edu

Ridaura-Ruiz L, Quinteros-Borgarello M, Berini-Aytés L, Gay-Escoda C. Fragile X-syndrome: Literature review and report of two cases. *Med Oral Patol Oral Cir Bucal*. 2009 Sep 1;14 (9):e434-9.
<http://www.medicinaoral.com/medoralfree01/v14i9/medoralv14i9p434.pdf>

Received: 30/09/2008
 Accepted: 20/05/2009

Article Number: 5123658847 <http://www.medicinaoral.com/>
 © Medicina Oral S. L. C.I.F. B 96689336 - pISSN 1698-4447 - eISSN: 1698-6946
 eMail: medicina@medicinaoral.com

Indexed in:

- SCI EXPANDED
- JOURNAL CITATION REPORTS
- Index Medicus / MEDLINE / PubMed
- EMBASE, Excerpta Medica
- SCOPUS
- Indice Médico Español

Abstract

Fragile X-syndrome is caused by a mutation in chromosome X. It is one of the most frequent causes of learning disability. The most frequent manifestations of fragile X-syndrome are learning disability, different orofacial morphological alterations and an increase in testicle size. The disease is associated with cardiac malformations, joint hyperextension and behavioural alterations. We present two male patients aged 17 and 10 years, treated in our Service due to severe gingivitis. Both showed the typical facial and dental characteristics of the syndrome. In addition, we detected the presence of root anomalies such as taurodontism and root bifurcation, which had not been associated with fragile X-syndrome in the literature. In some cases these root malformations have been associated with other sex-linked congenital syndromes, though in none of the studies published in the literature have they been related with fragile X-syndrome.

This syndrome is relevant due to its high prevalence, the presentation of certain oral and facial characteristics that can facilitate the diagnosis, and the few cases published to date.

Key words: *Fragile X-syndrome, Martin-Bell syndrome, mental retardation, taurodontism.*

Introduction

Fragile X-syndrome (FXS), also known as Martin-Bell syndrome, is one of the most common diseases of genetic origin. This syndrome is responsible for 30% of all cases of hereditary mental retardation, and is associated to certain cognitive, behavioral and physical alterations (1,2).

FXS is a chromosome X-linked monogenic disease resulting from a dynamic mutation of exon 1 in the FMR-1

(Fragile X-linked Mental Retardation type 1) gene located in band q27.3 of the long arm of chromosome X. This alteration originates from an increase in the number of repetitions of the cytosine – guanine – guanine (CGG) trinucleotide. Healthy individuals have 6 to 54 repetitions of the CGG triplet. The genetic sequence related with FXS manifests in two forms or states depending on the number of CGG triplets it contains: premutation (PM) and complete mutation (CM). Individuals with

PM have between 55 and 200 repetitions, and are generally considered to be unaffected, while patients with CM have expansions in excess of 200 CGG (normally between 1000 and 2000) (3). Crawford et al. in turn described an intermediate form involving between 41 and 60 repetitions (2).

Mutation of the FMR1 gene induces hypermethylation of the corresponding genomic region, preventing the production of messenger RNA (mRNA), and thus interrupting production of the FMRP (Fragile X Mental Retardation Protein)-which is essential for neuronal development and the production of connective tissue in the fetus. A deficiency or absence of FMRP is the cause of FXS (4).

Since the causal mutation is linked to chromosome X, FXS is 30% more frequent in males than in females (1,2,5). The incidence of FXS varies according to the source consulted in the literature. Hessler et al. (6) reported an incidence of one out of every 2000-5000 individuals (without specifying gender differences or distinguishing between CM and PM). Nunn et al. (5) in turn reported an incidence of one out of every 750 females and one out of every 1500 males (though likewise without differentiating between CM and PM) (5). The prevalence of PM as reported by most authors is one out of every 100-200 females and one out of every 800 males, while the prevalence of CM is one out of every 6000-8000 females and one out of every 4000 males (4,7).

The clinical manifestations of this syndrome in adult males include four main features: an elongated and narrow face with a large forehead and prominent chin, large and anteverted ears, joint hyperlaxity (with increased mobility), and uni- or bilaterally large testes (macroorchidism). Between 25-30% of all patients with FXS do not present the typical fascies of the syndrome (1). The secondary characteristics of FXS in turn include tallness (1), a soft and silky skin, widened fingertips and flat feet. The physical features of females with CM are less evident and more variable than in males with CM, though exceptionally there have been reports of females with the classical phenotype of the syndrome. In contrast to males, girls with FXS are shorter than normal. In comparison, females with PM usually have a normal physical appearance (8).

The connective tissue anomalies are practically constant in patients with FXS, and include the presence of joint hyper-extensibility that decreases with age and is more accentuated in the case of the small joints (9) such as the temporomandibular joint (TMJ). These connective tissue disorders lead to cardiac anomalies such as heart valve alterations, particularly mitral valve prolapse—which gives rise to heart murmurs (7,8,9).

The typical facial characteristics of FXS include macrocephalia, a prominent frontal bone, hypotelorism,

strabismus, hypoplasia of the middle third of the face, mandibular protrusion, and the possible coexistence of Pierre-Robin syndrome (micrognathia, glossoptosis and cleft palate) (7,11). The most frequent intraoral anomalies are an ogival palate, cleft palate, the presence of mesiodens (9), dental hypomineralization and abrasion of the occlusal surfaces and incisal edges (5,8,10), as well as an increase in the dimensions of the dental crowns in the mesiodistal and vestibulolingual orientation, which produces severe bone-dental discrepancies (8,11).

During the prepubertal stage the behavioral features of the syndrome are more apparent than the physical characteristics. In boys and adult males with CM, cognitive performance is usually affected, and 80-90% present intellectual deficiencies—with an IQ score in the range corresponding to moderate-severe mental retardation. In addition, most of these patients suffer important attentional problems. The most common behavioral disturbances are hyperactivity, which tends to improve with age, anxiety in the face of new situations or circumstances with unknown elements, and perseveration behavior (repetition of actions and phrases) (8). These patients are also extremely shy, and tend to avoid anxiety-generating eye contact. In situations characterized by excitement, stereotypes are common (flapping movements and nibbling of hands). Approximately 15-30% are autistic; in fact, it is estimated that 6% of all autistic males have FXS (1,4,5). These patients usually show poor tolerance of frustration, and have scant patience when having to wait for something. Their behavior can be impulsive and/or aggressive under certain circumstances. Approximately 30-50% of all girls with CM have a normal IQ score, though with learning difficulties, deficient executive function, attentional disorders, emotional lability, difficulties with mathematics, and language deficiencies. Shyness and social anxiety may pose serious problems requiring specific treatment.

Approximately 15% of all patients with FXS suffer a form of epilepsy characterized by a benign course with disappearance of the seizures before 20 years of age. Anomalies have been documented in brain morphology, related with the low intellectual performance of children with FXS, and with methylation of the FMR1 gene (8,12).

The present study describes our experience with two male patients aged 17 and 10 years, diagnosed with FXS.

Clinical Cases

Case 1

A 17-year-old male presented with FXS (offspring of a woman with FXS carrier status). The molecular genetic study showed the patient to carry an allele with 53 repetitions of the CGG triplet in region 5 of the FMR1 gene, with increased levels of mRNA and decreased levels of FMRP. The patient presented discrete hypoa-

cusia, an ocular refraction defect, upper dorsal scoliosis and epilepsy (currently undergoing remission). He suffered two seizure episodes at 10 years of age, for which carbamazepine (Tegretol®, Novartis, Barcelona, Spain) was prescribed during 5 years (until 15 years of age). He was receiving no drug treatment at the time of presentation to our Service. The patient presented a septum pellucidum cyst as sole anomaly in the study of the brain (electroencephalogram and computed tomography). There were no cardiological alterations. The patient had been subjected to tonsillectomy at four years of age, resection of a plantar nevus at 6 years of age, and bilateral otoplasty at 8 years due to anteversion of the ears. He presented no infectious disorders of interest, known drug allergies or toxic habits.

The general physical examination (fig.1) revealed some dysmorphic features such as a dolichocephalic skull, muscle hypotonus and lax ligament structures. The patient presented cognitive deficiency, affecting language in particular.

This patient was referred to our Service for the correction of deficient buccodental hygiene that had produced severe gingivitis. He had undergone root canal treatment at the level of 2.1 at 10 years of age, and had been operated upon on two occasions under general anesthesia for the removal of mesiodens at 10 years of age and of fully impacted 1.3 at 16 years of age. The patient had received fixed and removable orthodontic treatment for two years, and presently wore a removable space maintainer in the upper maxilla.

Physical examination showed facial asymmetry at left mandibular body level, while intraoral examination of the mandible revealed secondary retention and infraocclusion of 3.6. Radiographically, root elongation of this molar was seen, together with the presence of root anomalies in all the lower premolars, such as taurodontism and root bifurcation (fig.2).

The management plan included periodontal treatment, surgical extraction of 3.6 under local anesthesia, and the fitting of a removable partial prosthesis for maintaining the space. Once the growth phase of the patient has been completed, rehabilitation of the edentulous zones will be carried out by placing unit implants at the levels of 3.6 and 1.3.

Case 2

A 10-year-old male presented with FXS, offspring of a woman with FXS carrier status. He had no history of systemic diseases or infectious processes. There were no known drug allergies or toxic habits.

The general physical examination revealed some typical features of FXS, such as an elongated face, a prominent frontal bone, large ears and strabismus. In the same way as in case 1, the patient had a low muscle tone, hyperlaxity of the ligaments, and cognitive deficiency, affecting language in particular.

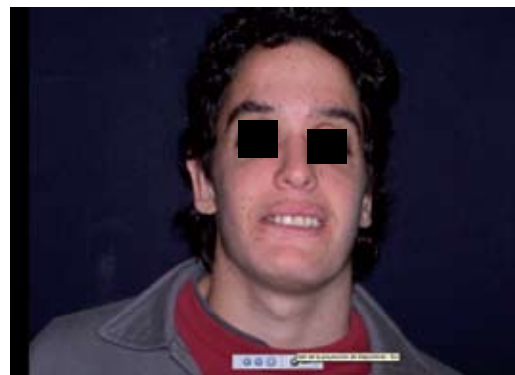

Fig. 1. Clinical frontal view of case 1. Note the typical facial features of fragile X-syndrome, such as the elongated face, the prominent mandible and large ears.

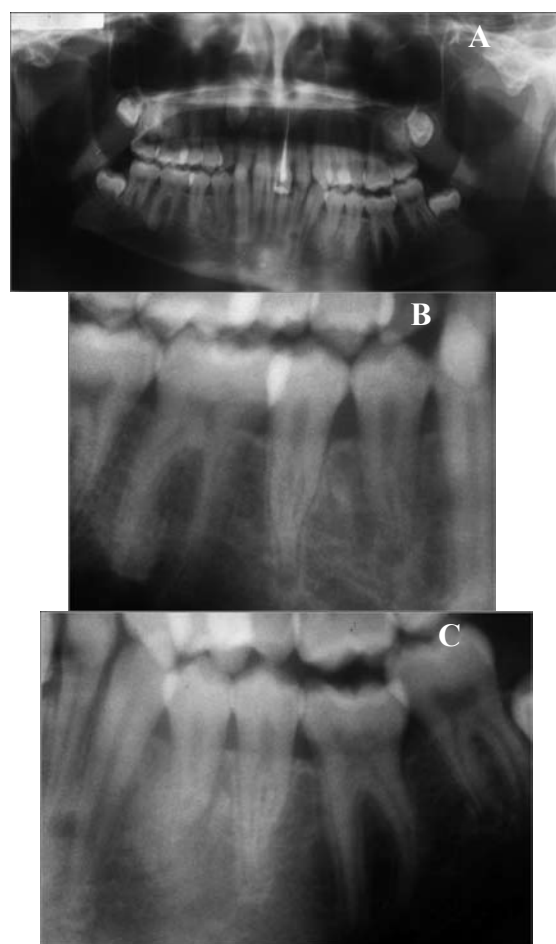


Fig. 2. Case 1

A. Panoramic X-ray view of 2002. Showing total in-bone retention of 1.3.

B. Panoramic X-ray detail (year 2002). Showing root anomalies, taurodontism and bifurcation, in premolars of the fourth quadrant.

C. The third quadrant shows these same root malformations in 3.4 and 3.5, in addition to root elongation of 3.6.

This patient was referred to our Service for the correction of deficient buccodental hygiene that had produced mild gingivitis, aggravated by a mouth breathing habit. However, this patient had not undergone previous dental treatment.

Exploration of the maxillas showed no facial asymmetry, and the patient presented bilateral class II division 1 malocclusion. As intraoral characteristics typical of FXS, he presented an ogival palate, with increased dimensions of the molar crowns (mesiodistal as well as vestibulolingual). The upper arch was V-shaped due to narrowing in the region of the premolars and canine, together with protrusion or labioversion of the upper incisors that produced an anterior open bite. Muscle abnormalities were also noted, with a hypotonic upper lip. The panoramic X-ray study (Fig.3) showed the germs of the permanent teeth and the absence of supernumerary teeth. The X-ray view revealed taurodontism affecting 2.6 and 1.6, and anomalous root morphology of unerupted 4.3. The germs of the upper and lower second molars were still partially within the bone.

Periodontal treatment was provided, and the need for orthodontic management was evaluated but rejected by the parents.

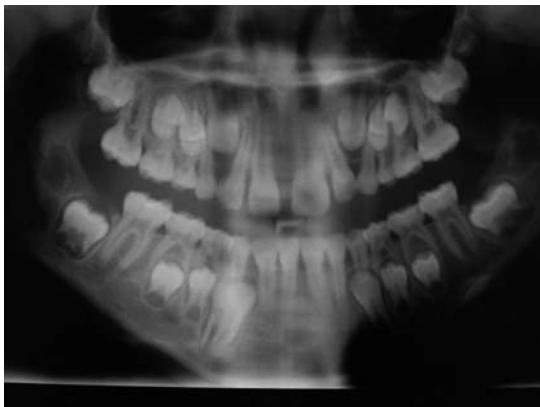

Fig. 3. Case 2. Panoramic X-ray view showing taurodontism affecting 2.6 and 1.6, with root anomalies of unerupted 4.3. This patient presents no supernumerary teeth.

Discussion

Fragile X-syndrome (FXS) was first described in 1943 by J. Purdon Martin and Julia Bell. Its genetic origin was not established until 1969, when individuals with certain mental and physical characteristics were associated with an alteration of chromosome X. In 1991, Verkerk described the FMR1 gene, which stimulated the medical and psychopedagogic study of the syndrome. The most important contributions in this sense have been improvements in the prenatal diagnosis of the disorder,

and genetic counseling of individuals with antecedents of fragile X-syndrome (1,2, 13-15).

The name of this syndrome refers to the form of chromosome X when cultured under special conditions (in folic acid-deficient medium). Due to the expansion of the nucleotide triplet, the extremity of the long arm of chromosome X appears decondensed and elongated, and ruptures easily. The phenomenon of chromosome X rupture only appears *in vitro*, on examining the sample under the microscope. The diagnosis of FXS is confirmed by molecular genetic studies of the FMR1 gene. Newborn infants with FXS tend to have an increased body weight, and the clinical examination reveals macrocephaly and large fontanelles. However, delayed mental development is usually the first diagnostic sign. Children with FXS begin to walk and speak after 20 months of age on average. The syndrome is usually not diagnosed until 8-9 years of age, since the clinical manifestations of the syndrome are greatly attenuated in childhood. On reaching puberty, the facial and body features of FXS become more evident (9), and testicular enlargement is observed (although 10-15% of all affected boys present macroorchidism before puberty) (8). The prepubertal patient corresponding to case 2 showed more attenuated physical features than in case 1.

The existence of connective tissue dysplasia associated to this syndrome leads to a high incidence of cardiac anomalies. These alterations include heart valve disease, with mitral valve prolapse in over 80% of all patients with FXS. In these cases antibiotic prophylaxis has been advised to prevent bacterial endocarditis before dental treatment or oral surgery. General anesthesia entails important risks because of these cardiac malformations. As a result, dental treatment preferably should be carried out under local anesthesia (5,9). However, neither of our patients presented heart problems.

Individuals with premutation (PM) of the FMR1 gene have no cognitive impairments, though our patients presented cognitive problems affecting language in particular, associated to physical features specific of FXS. The PM phenotype is attributable to the increase in mRNA of the FMR1 gene, and to the slight decrease in FMRP levels, which leads to intracellular precipitations and neuron degeneration (1).

These patients present two late-onset subphenotypes. The first is premature ovarian failure (POF), observed in over 20% of all females with PM. This prevalence is 30 times greater than in the general population. The FMR1 gene intervenes in ovarian development and maturation (16). Non-fertile women who prematurely present elevations in follicle stimulating hormone (FSH) may be candidates for the study of FMR1 gene premutation (4).

The second subphenotype is referred to as FXTAS (Fragile X Associated Tremor / Ataxia Syndrome), and its prevalence is 30% among adults with PM. FXTAS is

a multisystemic neurological disorder mainly characterized by progressive intentional tremor, ataxia, parkinsonism and autonomous dysfunction (8,17). Other associated characteristics are peripheral neuropathy with a reduction in vibration sensation in the distal portions of the lower extremities, sexual impotency, cognitive defects (memory loss, difficulty forming words, etc.), and executive functional deficiencies. However, this clinical picture usually manifests after 50 years of age (1,4). Females with PM do not develop FXTAS. This difference is explained by the protection afforded by inactivation of the allele carrying the permutation. Very high levels of mRNA (up to 4-fold the normal levels) corresponding to the FMR1 gene have been documented (8).

Family antecedents of FXTAS or POF associated to cognitive defects, as well as mental retardation of unknown origin without family antecedents, are indications for genetic studies and the exclusion of FXS (4). An early diagnosis is very important for correct family planning, with specific and individualized intervention by a multidiscipline team (developmental therapies, educational or early stimulation protocols, etc.).

The most typical orofacial characteristics of this syndrome are mandibular prominence, an ogival palate and a cleft palate (5,9). Both of our patients presented an ogival palate, which in case 1 added to mandibular protrusion, though neither had a cleft palate. Another feature described by Nunn et al. (5), as well as by Shellhart et al. (10), is abrasion of the occlusal surfaces and incisal edges of the teeth. In our patients we observed no enamel hypoplasia or abrasions or wear facets—possibly because of their young age. In a case reported by Kulkarni et al. (9), a supernumerary tooth was identified in the premaxillary zone, in the same way as in our first patients, that was surgically removed at 10 years of age.

In our patients we observed localized taurodontism: in case 1 affecting the roots of all the lower premolars, and in case 2 the upper left first molar. This type of anomaly is seen in 0.5-5% of the general population, and only can be established radiographically. Taurodontism is characterized by less manifest cervical constriction of the tooth, shortening of the roots, and apical displacement of the furcation. In addition, the pulp chamber is very large in the apico-occlusal direction in relation to the external configuration of the tooth (as in our first patient), and in the permanent molars (as in case 2). The literature reports cases of such root malformations associated to other sex-linked congenital syndromes (18,19), though no publication to date has related them to FXS.

It has been reported that chromosome X dental size and shape, in addition to root morphology (20). Our two patients presented anomalies in root morphology. We identified bifurcated roots bilaterally in both lower premolars of case 1, and in the lower right canine in

case 2 (this tooth being fully retained in bone). In the general population the prevalence of alterations in premolar root morphology is low –2.3% according to Vertucci (21) –and is more common in the first premolars (20,21). In addition, an increased frequency of premolars with two roots has been observed in patients with chromosomal alterations (19,22).

In studies of tooth morphology in patients with FXS, an increase has been reported in crown diameter in the mesiodistal and vestibulolingual direction, compared with the normal population. Asymmetry in crown size may be used as dental evidence for the diagnosis of patients with FXS (13). In our two patients, the coronal diameters were greater than in the general population, with slight macrodontia at molar and premolar level.

Due to the ligament hyperlaxity of these patients, recurrent temporomandibular joint luxation is common. In case 1 we diagnosed bilateral anterior disc displacement with reduction and subluxation of the condyle, associated to joint sounds but without pain.

Secondary retention is defined as the arrest of tooth eruption once the latter has appeared in the mouth, in the absence of any anomalous positioning or physical barrier against further eruption (23). The incidence of this alteration in the case of the permanent molars is very low, and causes severe alterations in dentition development and normal orofacial growth. Clinically, the presentation tends to be unilateral, and retention can be associated to cystic or inflammatory disorders and to alterations in occlusion. Treatment depends on the age of the patient, the affected tooth, and the degree of infraocclusion and malocclusion caused (24). According to most authors, the main cause of secondary retention is an alteration in the alveolar ligament, which can lead to ankylosis of the tooth (25). In the radiological study of case 1, we observed an increase in root length with secondary retention of 3.6. In patients with dental retention, periodic clinical and radiological controls are advised, particularly in age intervals between mixed dentition and 20 years of age—in view of the possible appearance of new retentions.

Transcriptional gene therapy appears as a future solution for genetic diseases, including FXS. With postnatal treatment, the neurological alterations of this syndrome could be modified, though it is unlikely that the facial malformations and the ligament hyperlaxity can be avoided (1).

Conclusions

Fragile X-syndrome is of interest in dental practice because of its high incidence and the presence of orofacial alterations that are key elements for diagnosing the disease in males with mental retardation of unknown origin. In our two patients we observed root malformations such as taurodontism, bifurcation and root elonga-

tion root, which have not been previously reported in association to FXS.

In the relationship between dentist and patient it is necessary to take the behavioral disorders of subjects with FXS into account. The stress of dental treatment should be avoided through anxiolytic premedication, and the patients should become familiarized with the environment of the dental clinic, since they become afraid in the presence of numerous external stimuli (noise, lights, etc.). If these patients have heart valve problems, preoperative antibiotic coverage should be provided, and as far as possible, dental treatment should be carried out under local anesthesia.

References

- Terracciano A, Chiurazzi P, Neri G. Fragile X syndrome. *Am J Med Genet C Semin Med Genet.* 2005;137C:32-7.
- Crawford DC, Acuña JM, Sherman SL. FMR1 and the fragile X syndrome: human genome epidemiology review. *Genet Med.* 2001;3:359-71.
- Pieretti M, Zhang FP, Fu YH, Warren ST, Oostra BA, Caskey CT, et al. Absence of expression of the FMR-1 gene in fragile X syndrome. *Cell.* 1991;66:817-22.
- Wattendorf DJ, Muenke M. Diagnosis and management of fragile X syndrome. *Am Fam Physician.* 2005;72:111-3.
- Nunn JH, Durning P. Fragile X (Martin Bell) syndrome and dental care. *Br Dent J.* 1990;168:160-2.
- Hessl D, Glaser B, Dyer-Friedman J, Blasey C, Hastie T, Gunnar M, et al. Cortisol and behavior in fragile X syndrome. *Psychoneuroendocrinology.* 2002;27:855-72.
- Murray J, Cuckle H, Taylor G, Hewison J. Screening for fragile X syndrome. *Health Technol Assess.* 1997;1:1-71.
- Tejada-Minguez MI. Síndrome X frágil. Libro de consulta para familiares y profesionales. Madrid: Artegraf; 2006.
- Kulkarni GV, Levine N. Fragile X (Martin-Bell) syndrome. *Spec Care Dentist.* 1994;14:21-5.
- Shellhart WC, Casamassimo PS, Hagerman RJ, Belanger GK. Oral findings in fragile X syndrome. *Am J Med Genet.* 1986;23:179-87.
- Peretz B, Ever-Hadani P, Casamassimo P, Eidelman E, Shellhart C, Hagerman R. Crown size asymmetry in males with fra (X) or Martin-Bell syndrome. *Am J Med Genet.* 1988;30:185-90.
- Mostofsky SH, Mazzocco MM, Aakalu G, Warsofsky IS, Denckla MB, Reiss AL. Decreased cerebellar posterior vermis size in fragile X syndrome: correlation with neurocognitive performance. *Neurology.* 1998;50:121-30.
- Verkerk AJ, Pieretti M, Sutcliffe JS, Fu YH, Kuhl DP, Pizzuti A, et al. Identification of a gene (FMR-1) containing a CGG repeat coincident with a breakpoint cluster region exhibiting length variation in fragile X syndrome. *Cell.* 1991;65:905-14.
- Nualart Grollmus ZC, Morales Chávez MC, Silvestre Donat FJ. Periodontal disease associated to systemic genetic disorders. *Med Oral Patol Oral Cir Bucal.* 2007;12:E211-5.
- Linossier AG, Valenzuela CY, Toledo H. Differences of the oral colonization by *Streptococcus* of the mutans group in children and adolescents with Down syndrome, mental retardation and normal controls. *Med Oral Patol Oral Cir Bucal.* 2008;13:E536-9.
- Bretherick KL, Fluker MR, Robinson WP. FMR1 repeat sizes in the gray zone and high end of the normal range are associated with premature ovarian failure. *Hum Genet.* 2005;117:376-82.
- Hagerman RJ, Leehey M, Heinrichs W, Tassone F, Wilson R, Hills J, et al. Intention tremor, parkinsonism, and generalized brain atrophy in male carriers of fragile X. *Neurology.* 2001;57:127-30.
- López ME, Bazán C, Lorca IA, Chervonagura A. Oral and clinical characteristics of a group of patients with Turner syndrome. *Oral Surg Oral Med Oral Pathol Oral Radiol Endod.* 2002;94:196-204.
- Varrela J. Effect of 45,X/46,XX mosaicism on root morphology of mandibular premolars. *J Dent Res.* 1992;71:1604-6.
- Kusiak A, Sadlak-Nowicka J, Limon J, Kochańska B. Root morphology of mandibular premolars in 40 patients with Turner syndrome. *Int Endod J.* 2005;38:822-6.
- Vertucci FJ. Root canal morphology of mandibular premolars. *J Am Dent Assoc.* 1978;97:47-50.
- Varrela J. Root morphology of mandibular premolars in human 45,X females. *Arch Oral Biol.* 1990;35:109-12.
- Valmaseda-Castellón E, De-la-Rosa-Gay C, Gay-Escoda C. Eruption disturbances of the first and second permanent molars: results of treatment in 43 cases. *Am J Orthod Dentofacial Orthop.* 1999;116:651-8.
- Valmaseda-Castellón E, De-la-Rosa-Gay C, Ustrell-Torrent JM, Gay-Escoda C. La infraoclusión de molares temporales. *Arch Odontostomatol.* 1996;12:578-89.
- Raghoobar GM, Boering G, Jansen HW, Vissink A. Secondary retention of permanent molars: a histologic study. *J Oral Pathol Med.* 1989;18:427-31.