

Journal section: Oral Surgery

Publication Types: Review

## Treatment of oral mucocele - scalpel versus CO<sub>2</sub> laser

Jose Yagüe-García <sup>1</sup>, Antonio-Jesus España-Tost <sup>2</sup>, Leonardo Berini-Aytés <sup>3</sup>, Cosme Gay-Escoda <sup>4</sup>

<sup>1</sup> DDS. Resident of the Master of Oral Surgery and Implantology. University of Barcelona Dental School

<sup>2</sup> DDS, MD, PhD. Associate Professor of Oral Surgery. Professor of the Master of Oral Surgery and Implantology. University of Barcelona Dental School

<sup>3</sup> DDS, MD, PhD. Assistant Professor of Oral Surgery. Professor of the Master of Oral Surgery and Implantology. Dean of the University of Barcelona Dental School

<sup>4</sup> MD, DDS, PhD. Chairman of Oral and Maxillofacial Surgery. Director of the Master of Oral Surgery and Implantology. University of Barcelona Dental School. Oral and maxillofacial surgeon of the Teknon Medical Center, Barcelona (Spain)

### Correspondence:

Centro Médico Teknon  
C/ Vilana 12  
08022 - Barcelona. Spain  
cgay@ub.edu

Yagüe-García J, España-Tost AJ, Berini-Aytés L, Gay-Escoda C. Treatment of oral mucocele - scalpel versus CO<sub>2</sub> laser. Med Oral Patol Oral Cir Bucal. 2009 Sep 1;14 (9):e469-74.  
<http://www.medicinaoral.com/medoralfree01/v14i9/medoralv14i9p469.pdf>

Received: 20/10/2008  
Accepted: 16/03/2009

Article Number: 2496 <http://www.medicinaoral.com/>  
© Medicina Oral S. L. C.I.F. B 96689336 - pISSN 1698-4447 - eISSN: 1698-6946  
eMail: [medicina@medicinaoral.com](mailto:medicina@medicinaoral.com)  
**Indexed in:**  
-SCI EXPANDED  
-JOURNAL CITATION REPORTS  
-Index Medicus / MEDLINE / PubMed  
-EMBASE, Excerpta Medica  
-SCOPUS  
-Indice Médico Español

### Abstract

**Objective:** To compare the results obtained after oral mucocele resection with the scalpel versus the CO<sub>2</sub> laser, based on the complications and recurrences after surgery

**Patients and Methods:** Of the 68 patients we studied who have mucocele, 38 were resected with a scalpel and the remaining 30 with the CO<sub>2</sub> laser (5-7 W). Patient sex and age were documented, along with location of the lesion as well as size, symptoms, duration, etiological factors, type of treatment, complications and recurrences after surgical removal.

**Results:** The sample comprised 40 males and 28 females, aged between 6-65 years. The histological diagnosis was extravasation mucocele in 95% of the cases. The most frequent location was the lower lip (73.5%). The mean lesion diameter was 9 mm, and in most cases no evident etiological factor was recorded. The mean duration of the lesion was 4 months. Among the cases of conventional surgical removal of mucocele, recurrence was recorded in 8.8% of the cases, and 13.2% of the patients suffered postoperative complications - the most frequent being the presence of fibrous scars. There were no complications or relapses after a minimum follow-up of 12 months in the cases subjected to CO<sub>2</sub> laser treatment.

**Conclusions:** Oral mucocele ablation with the CO<sub>2</sub> laser offers more predictable results and fewer complications and recurrences than conventional resection with the scalpel.

**Key words:** Mucocele, the CO<sub>2</sub> laser, treatment of mucoceles.

## Introduction

Mucoceles (from the Latin terms *mucus*, or mucus, and *coele*, or cavity) are defined as mucus-filled cavities that can appear in the oral cavity, appendix, gallbladder, paranasal sinuses or lacrimal sac (1,2). They are characterized by the accumulation of liquid or mucoid material, giving rise to a rounded, well circumscribed transparent and bluish-colored lesion of variable size. The consistency is typically soft and fluctuant in response to palpation. Mucoceles are painless and tend to relapse (3,4).

The incidence is high, in the order of 2.5 lesions per 1000 individuals. Indeed, mucoceles are the most common minor salivary gland disorder, and represent the second most frequent benign soft tissue tumors of the oral cavity, following irritative fibromas (1,5,6).

Mucoceles normally appear in the glands that secrete predominantly mucous saliva. It is therefore more frequent to find these lesions in the minor salivary glands, which are distributed throughout the oral submucosa, except in the attached gingival regions and in the anterior portion of the back of the tongue (7). However, such lesions can also be found with less frequency in the major salivary glands. Mucoceles located in the floor of the mouth in turn are referred to as “ranulas” (from the Latin terms *rana*, or frog, and *ula*, or small), due to the great similarity between these mucosal lesions and the swollen mouth of a frog (1,8). In these cases the sublingual glands are affected, and the saliva is mainly composed of mucus. There also have been exceptional reports of mucoceles of the submaxillary glands (2,9).

Etiologically, most mucoceles are considered to be secondary to traumatic or obstructive disorders of the mainly minor salivary glands—the preferential location being the humid mucosa of the lower lip (3,8).

Based on the underlying etiopathogenesis, these lesions classically have been divided into retention mucoceles and extravasation mucoceles (1,8,10). The former are less frequent and are seen particularly in elderly patients. Retention mucoceles consist of a well defined cystic cavity presenting an epithelial wall lined with cuboid or squamous cells. In contrast, extravasation mucoceles account for over 80% of all mucoceles, and are more common in individuals under 30 years of age. They are in fact pseudocysts lacking a well defined wall, and are composed of compressed elements of the surrounding connective tissue, and inflammatory components (1,8,11). These two types of mucocele also show some differences in anatomical location: retention mucoceles are uniformly distributed throughout all the territories that contain minor salivary glands, while extravasation mucoceles are fundamentally located in the lower lip (80%) (7,10).

Mucoceles are usually asymptomatic, though in some patients they can cause discomfort by interfering with

speech, chewing or swallowing (1). However, in most cases these lesions rupture spontaneously or traumatically a few hours after being formed, with the release of a characteristic viscous, mucoid fluid (4). This may give the mistaken impression of healing, since the lesion decreases in size or disappears. However, once the small perforation allowing release of the mucocele contents has healed, the secretions accumulate again, and the lesion relapses (1,5,8). On the other hand, in the case of repeated trauma, the lesion may become nodular and firmer in response to palpation—rupture in this situation being more difficult (7,12).

Mucoceles do not cause direct obstruction of salivary flow, and the amount of secretion that can be extravasated is limited by the elasticity of the surround tissues. As a result, although these lesions can become quite large, they are usually of small size (8).

As regards treatment, resection is carried out when the lesions that are multiple, recurrent or cause patient discomfort. It must be taken into account that typical minor salivary gland mucoceles rarely resolve on their own, i.e., surgical removal is required in most cases (5,12,13).

The main objective of this study was to compare the results obtained after oral mucocele resection with scalpel versus the CO<sub>2</sub> laser, based on the recorded complications and relapses after surgery. Likewise, an analysis was made of patient sex and age, the main etiological factors, lesion location and size, the duration of the lesions, and the symptoms.

## Patients and Methods

A retrospective study was made of 68 patients with clinically and histologically diagnosed minor salivary gland mucoceles, seen in the Service of Oral Surgery (Dental Clinic of the University of Barcelona, Spain) in the period 1990-2005. Of these patients, 38 were subjected to conventional treatment (resection with scalpel), while the remaining 30 were treated using a CO<sub>2</sub> laser (Lasersat 20W, Sharplan 1020, Tel Aviv, Israel) with a straight handpiece.

All the mucoceles were removed under infiltrating perilesional local anesthesia (4% articaine with 1:100,000 adrenalin). In those cases where the CO<sub>2</sub> laser was used, the power was set to 5-7 W, focalizing for sectioning of the mucosa and defocalizing for vaporizing remaining pathological tissue and/or for controlling bleeding. The teeth and adjacent tissues were protected with a wooden spatula. In those cases where the mucocele membrane was ruptured, the operation was continued, defocalizing the laser over the entire surface until the most superficial fibers of the lip muscle layer were seen to be vaporized. The resulting surgical wounds were allowed to heal by second intention, regardless of their depth (fig.1). The specimens obtained were fixed in 10%

formalin solution for posterior histological study to establish the definitive diagnosis. In general, no antibiotics or antiinflammatory analgesics were prescribed. Chlorhexidine (Lácer®, Cerdanyola del Vallés, Spain) was applied both as a gel (0.2%) to the surgical zone, and as a rinse (0.12%) twice daily—stressing the need to maintain good postoperative oral hygiene.

In those cases where resection was carried out with the scalpel, we always used a number 15 blade mounted in a number 3 handle. An elliptic incision was made to fully enucleate the lesion along with the overlying mucosa and the affected glands. The operation proved more complicated when the lesion ruptured, since the loss of references made it more difficult to ensure complete elimination of the lesion. The wound was finally sutured. The postoperative patient instructions were the same as in the CO<sub>2</sub> laser treated group.

Controls were made after one week and 30 days to check healing and the evolution of the wound, with an evaluation of possible relapse after 12 months.

In order to compare the incidence of postoperative complications and recurrences between the two types of treatment, we selected 25 lower lip mucocoeles removed with the scalpel, and the same number of mucocoeles corresponding to the same location, treated with the CO<sub>2</sub> laser.

## Results

The study sample comprised 68 mucocoeles diagnosed in 40 males (58.8%) and 28 females (41.2%), aged between 6-65 years (mean 26 years). Most of the lesions (34 cases) presented between 10-20 years of age, with 22 mucocoeles between 20-30 years of age, 4 in patients under 10 years of age, and 8 in patients over 40 years of age (fig.2).

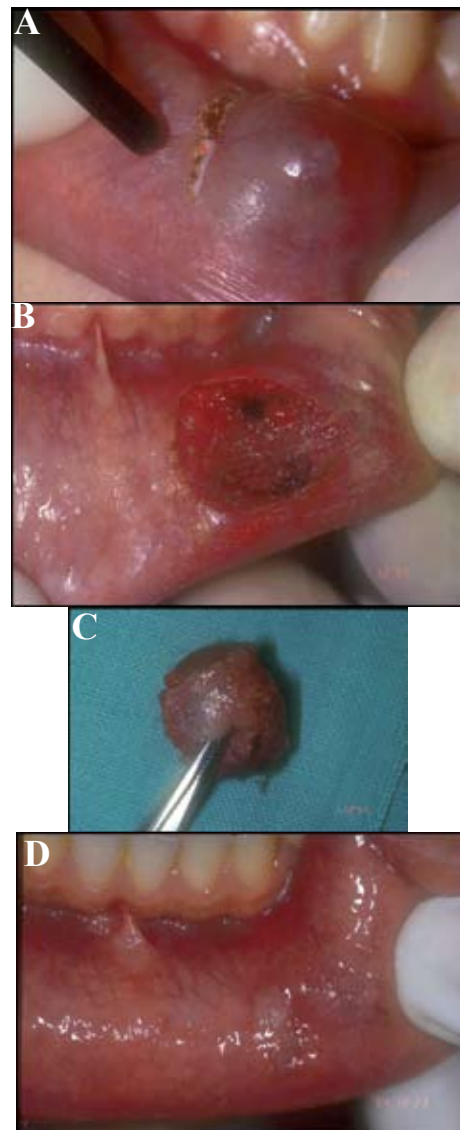
Although about one-third of the patients reported previous trauma in the region of the mucocoele, in most of the cases there was no evident etiological factor. As regards location, the lower lip was affected in 73.5% of the cases (50 mucocoeles), with few lesions in other parts of the oral cavity (fig.3).

While the mucocoeles ranged from 0.4-3 cm in diameter (mean 0.9 cm.), the lesions most often measured between 1-1.5 cm in size. The mean evolution was 4 months (range 1 month - 3 years).

Sixty-seven percent of the lesions were casually identified by a dentist, without the patient being aware of their presence. The rest of the lesions were identified by the patients despite the absence of symptoms. Only 22% of the patients reported discomfort associated with nibbling of the lesion, though in no case was pain reported.

The histological diagnosis was extravasation mucocoele in 91.2% of the cases. Only 6 retention mucocoeles were recorded.

Among the mucocoeles located in the lower lip, 5 that had been eliminated with the cold scalpel were seen to relapse, versus only 1 of those treated with the CO<sub>2</sub> laser. All the recurrences occurred within 30 days after the operation, and were again treated with the CO<sub>2</sub> laser. No additional relapses were documented after a minimum follow-up of 12 months. No relapses were observed after exeresis of the rest of mucocoeles.



**Fig. 1.** A) Start of lesion ablation with the focalized CO<sub>2</sub> laser. B) Surgical wound after defocused CO<sub>2</sub> laser irradiation. Hemostasia is effective, and no suturing is required. C) Surgical specimen before immersion in 10% formalin solution for subsequent histological processing. D) Appearance of the wound four weeks after surgery. Epithelization is correct, and no esthetic defect or fibrous scar is seen.

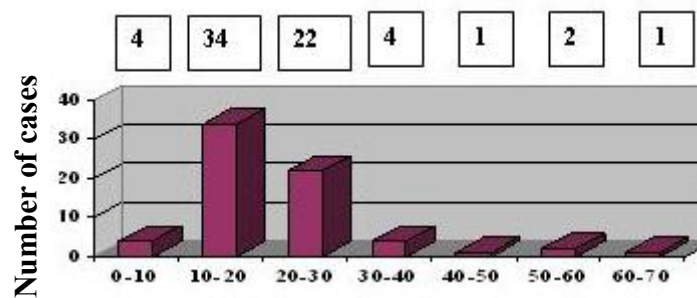


Fig. 2. Distribution of the mucoceles according to age groups.

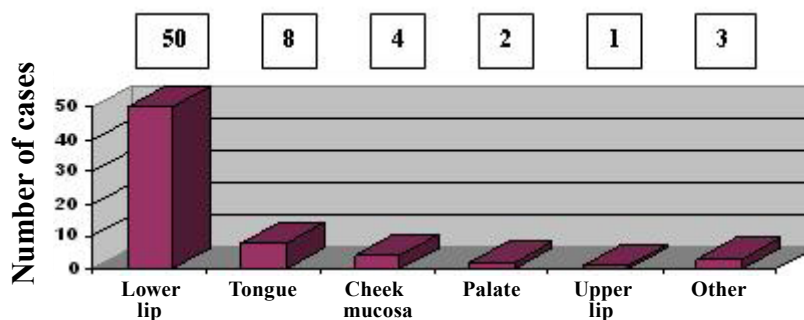


Fig. 3. Distribution of the mucoceles according to location.

Lastly, postoperative complications were recorded in 9 of the 25 cases of lower lip mucocele removed with the cold scalpel. This global 13.2% complications rate included 1 case of transient lip paresthesia, 3 cases of postoperative bleeding and 5 fibrous scars after the normal healing period. In contrast, no postoperative complications were seen in any of the lower lip mucoceles treated with the CO<sub>2</sub> laser.

**Discussion**

The incidence of mucoceles in the general population is 0.4-0.8% (6), with scant differences between males and females. Our own series coincides with this, since 55% of the lesions were found in males (1,4,14). As regards patient age, different authors report the peak incidence to be in the second or third decades of life (8,11,14). An interesting and controversial aspect of mucoceles is their origin. Bhaskar et al. (10) suggested obstruction of the salivary gland ducts as the cause of mucoceles, though this hypothesis has lost support in favor of a traumatic origin of the lesions (15). The literature contains a number of studies that confirm the traumatic etiology of these lesions (8,11,14). In our series we identified an antecedent of trauma or of nibbling in 34% of the patients – this figure being low in comparison to

the percentages reported in other studies (1,5,14). In any case, the typical location of these lesions in the lower lip (more susceptible to accidental traumatism or nibbling and suction habits), their presence in young patients, and the exceptional presence of calculi in the minor salivary glands (16), all support this etiopathogenic theory. As regards mucocele location in the oral cavity, most investigators consider the lower lip to be the most frequently affected location (40-80% of all cases) (7,8,14), followed by the cheek mucosa and floor of the mouth. The tongue, palate and upper lip are infrequent locations. The present study coincides with these observations, since 73.5% of the lesions were in the lower lip, with very little involvement of other locations. In addition, the lower lip mucoceles were predominantly located on one side—with very few medial lower lip locations (14). These data would be directly related to the greater capacity of certain teeth to exert trauma upon the lip, as a result of their spatial distribution. In this sense, there also have been reports of mucoceles produced as a result of the action of dental braces. In the present study mucocele growth was generally seen to be slow. According to Harrison (8), the lesions develop over a period of one week to five years, though the most common duration is three weeks to three months (somewhat shorter than the 4 months on average do-

cumented in our study). In turn, lesion size reportedly varies between 0.2 mm and 2 cm in diameter (1,4,14), in coincidence with our own observations, where the mean size was 0.9 cm. As a result, mucoceles usually produce no symptoms, since the patients seek medical treatment in the early stages of development, i.e., when the mucoceles are still small (1,8).

Histologically, two types of mucoceles are distinguished: retention mucoceles and extravasation mucoceles. In our series, and in coincidence with other studies (8,10,14,15), the great majority of lesions (91.2%) were extravasation mucoceles. As an example of the great difference in frequency between the two types of mucoceles, Cataldo et al. (11) identified only 24 retention mucoceles in a large series of 594 cases.

The literature describes different treatment options, including cryosurgery (17), intralesional corticosteroid injection (13), micro-marsupialization (18), marsupialization of the mucocele (1,11), conventional surgical removal of the lesión (1,8,11), and laser ablation (19-22).

Some authors recommend an initial cryosurgical approach (17) or the intralesional injection of corticosteroids (13). However, the number of relapses associated with these techniques is very high, and most cases therefore require reintervention in the form of conventional surgery to ensure complete resolution of the lesions.

On the other hand, Botazzo et al. (18) propose micro-marsupialization as an ideal treatment alternative for mucoceles in pediatric patients, since the technique is rapid, simple, and offers good results. This is the least traumatic of all the described management options, and involves traversing the lesion along its maximum diameter with suture thread that is left in place for at least 7 days.

Another option is the marsupialization of large mucoceles, with the purpose of making surgery less invasive, and thus preventing damage to neighboring anatomical structures such as the labial branch of the mental nerve (1,11).

Using the scalpel, Baurmash (1) proposes complete resection of the mucocele through careful dissection, and ensuring that both the affected and neighboring glands are removed, along with the pathological tissue, before primary closure of the wound. This minimizes the risk of relapse. In addition, special care is required to avoid damaging other glands or ducts with the suture needle, since this may become a cause of recurrence. In order to apply this technique, the lesion must have a relatively thick connective tissue wall. In effect, too thin a wall would imply a risk of rupturing the mucocele, and leakage of its contents would cause soft tissue collapse—with loss of the anatomical references needed for resection. This would make the procedure more complicated, and it would be difficult to ascertain whether the entire lesion has been removed (including the causal minor sa-

linary gland tissue). As a result, lesion relapse would be the norm.

Lastly, the CO<sub>2</sub> laser often has been used in oral soft tissue surgery. However, it has been little used to date for treating oral mucoceles (20).

This laser is strongly absorbed by water, as a result of which its effect is scantily penetrating, and action is essentially confined to the surface of the soft tissues. Moreover, the device is very potent, and can offer power settings of between 1-100W (23). According to España et al. (23), the recommended power setting for the treatment of oral soft tissues is 5-10W in most cases, since higher settings produce fibrous scars or destruction of the adjacent tissues. For this reason we used the Lasersat 20W, at a power setting of 5-7W.

Of the 50 mucoceles of the lower lip, 25 were removed with the scalpel, and the rest with the CO<sub>2</sub> laser. This allowed direct comparison between the results obtained with the two surgical instruments.

The CO<sub>2</sub> laser was seen to offer a range of advantages with respect to the scalpel (23). Firstly, the CO<sub>2</sub> laser allowed rapid and simple mucocele ablation. In coincidence with the observations of Huang et al. (22) we found the total treatment time with the laser to be 3-5 minutes. This was less than with the scalpel, which requires a meticulous technique and also suturing of the lesion at the end of the operation. For this reason, resection using the CO<sub>2</sub> laser also would be indicated in pediatric and geriatric patients, who are less able to tolerate long procedures.

Another advantage of the CO<sub>2</sub> laser is the minimization of complications and relapses. However, few studies have been published on this subject. A review of the literature yielded only two studies involving a small number of mucoceles treated with the CO<sub>2</sub> laser (19,20), and a publication by Huang et al. (22), in which 82 lower lip mucoceles were treated with this type of laser. These latter authors recorded no postoperative bleeding or healing problems. One case of lower lip paresthesia was observed that lasted two weeks. On the other hand, only two relapses were recorded among the 82 lower lip mucoceles treated with the CO<sub>2</sub> laser. Our own findings coincide with those of Huang et al. (22) where postoperative complications and relapses were minimal following ablation of the lower lip mucoceles with the CO<sub>2</sub> laser. Moreover, we recorded no bleeding or lip paresthesias, and only one recurrence was documented.

On comparing these results with those of the lower lip mucoceles treated with the scalpel, we observed a greater incidence of complications and relapses with the latter technique. We recorded a case of lower lip paresthesia after scalpel removal of a large mucocele measuring 2.4 cm in diameter—this indicating damage to some terminal branch of the mental nerve as a consequence of the aggressiveness of the procedure. In addition, we

registered five relapses. This comparatively greater relapse rate could be attributable to damage to the neighboring minor salivary glands, caused by the scalpel during removal of the mucocele, or by the needle upon suturing. Failure to eliminate the glands giving rise to the mucocele would also be a cause of relapse.

According to Basu et al. (24), healing of the wounds caused by the CO<sub>2</sub> laser involves the appearance of a fibrous membrane after 72 hours that replaces the superficial necrotic layer of the irradiated tissue. Epithelial covering of the wound begins from the periphery after two weeks, and is thinner and parakeratotic in comparison with the epithelium that appears after scalpel resection. Probably for this reason, the esthetic outcome of all the CO<sub>2</sub> laser interventions was excellent, with no fibrosis or scarring, while the scalpel left small residual esthetic defects after the usual healing period, in 5 of the 25 lower lip mucoceles treated with this surgical instrument.

Other advantages of the CO<sub>2</sub> laser versus the cold scalpel are minimal damage to the neighboring tissues, a bloodless and highly decontaminated surgical bed, lessened swelling and pain during the postoperative period, and the appearance of fewer myofibroblasts—resulting in comparatively lesser wound contraction (19,20,23,25,26). Our observation of only minimal postoperative pain and swelling coincides with the findings of other authors (14,21,22)—no medication being needed in any of the patients subjected to CO<sub>2</sub> laser treatment, compared with the need for analgesia in over half of all scalpel-treated patients.

Finally, we must stress the importance of subjecting the resected specimen to histological study, regardless of the technique used to remove the lesion. This serves to confirm the diagnosis and ensure that elimination of the gland tissue implicated in the process has been complete—thereby preventing possible recurrence.

## Conclusions

Mucoceles of the oral cavity are more common in young males. Traumatism is the usual cause, and the most frequent location is the mucosa of the lower lip.

The CO<sub>2</sub> laser is rapid (operating time 3-5 minutes) and simple for resecting oral mucoceles. Its advantages include a reduction in the number of relapses in comparison with the scalpel. On the other hand, the treatment of these lesions with the CO<sub>2</sub> laser offers a better esthetic outcome, with less postoperative bleeding and paresthesias than conventional surgical removal of the lesion.

Lastly, ablation with the CO<sub>2</sub> laser offers a more comfortable postoperative course for the patient.

## References

1. Baumash HD. Mucoceles and ranulas. *J Oral Maxillofac Surg.* 2003;61:369-78.

2. Ozturk K, Yaman H, Arbag H, Koroglu D, Toy H. Submandibular gland mucocele: report of two cases. *Oral Surg Oral Med Oral Pathol Oral Radiol Endod.* 2005;100:732-5.
3. Eveson JW. Superficial mucoceles: pitfall in clinical and microscopic diagnosis. *Oral Surg Oral Med Oral Pathol.* 1988;66:318-22.
4. Bermejo A, Aguirre JM, López P, Saez MR. Superficial mucocele: report of 4 cases. *Oral Surg Oral Med Oral Pathol Oral Radiol Endod.* 1999;88:469-72.
5. Baumash H. The etiology of superficial oral mucoceles. *J Oral Maxillofac Surg.* 2002;60:237-8.
6. Knapp MJ. Oral disease in 181,338 consecutive oral examinations. *J Am Dent Assoc.* 1971;83:1288-93.
7. Jinbu Y, Kusama M, Itoh H, Matsumoto K, Wang J, Noguchi T. Mucocele of the glands of Blandin-Nuhn: clinical and histopathologic analysis of 26 cases. *Oral Surg Oral Med Oral Pathol Oral Radiol Endod.* 2003;95:467-70.
8. Harrison JD. Salivary mucoceles. *Oral Surg Oral Med Oral Pathol.* 1975;39:268-78.
9. Anastassov GE, Haiavy J, Solodnik P, Lee H, Lumerman H. Submandibular gland mucocele: diagnosis and management. *Oral Surg Oral Med Oral Pathol Oral Radiol Endod.* 2000;89:159-63.
10. Bhaskar SN, Bolden TE, Weinmann JP. Pathogenesis of mucoceles. *J Dent Res.* 1956;35:863-74.
11. Cataldo E, Mosadomi A. Mucoceles of the oral mucous membrane. *Arch Otolaryngol.* 1970;91:360-5.
12. Jinbu Y, Tsukinoki K, Kusama M, Watanabe Y. Recurrent multiple superficial mucocele on the palate: Histopathology and laser vaporization. *Oral Surg Oral Med Oral Pathol Oral Radiol Endod.* 2003;95:193-7.
13. Wilcox JW, History JE. Nonsurgical resolution of mucoceles. *J Oral Surg.* 1978;36:478.
14. Silva A Jr, Nikitakis NG, Balciunas BA, Meiller TF. Superficial mucocele of the labial mucosa: a case report and review of the literature. *Gen Dent.* 2004;52:424-7.
15. Arendorf TM, Van Wyk CW. The association between perioral injury and mucoceles. *Int J Oral Surg.* 1981;10:328-32.
16. Eversole LR, Sabes WR. Minor salivary gland duct changes due to obstruction. *Arch Otolaryngol.* 1971;94:19-24.
17. Twetman S, Isaksson S. Cryosurgical treatment of mucocele in children. *Am J Dent.* 1990;3:175-6.
18. Delbem AC, Cunha RF, Vieira AE, Ribeiro LL. Treatment of mucocele retention phenomena in children by the micro-marsupialization technique: case reports. *Pediatr Dent.* 2000;22:155-8.
19. Kopp WK, St-Hilaire H. Mucosal preservation in the treatment of mucocele with CO<sub>2</sub> laser. *J Oral Maxillofac Surg.* 2004;62:1559-61.
20. Frame JW. Removal of oral soft tissue pathology with the CO<sub>2</sub> laser. *J Oral Maxillofac Surg.* 1985;43:850-5.
21. Pogrel MA, Yen CK, Hansen LS. A comparison of carbon dioxide laser, liquid nitrogen cryosurgery, and scalpel wounds in healing. *Oral Surg Oral Med Oral Pathol.* 1990;69:269-73.
22. Huang IY, Chen CM, Kao YH, Worthington P. Treatment of mucocele of the lower lip with carbon dioxide laser. *J Oral Maxillofac Surg.* 2007;65:855-8.
23. España AJ, Velasco V, Gay Escoda C, Berini L, Arnabat J. Aplicaciones del láser de CO<sub>2</sub> en Odontología. Madrid: Ergon; 1995.
24. Basu MK, Frame JW, Rhys Evans PH. Wound healing following partial glossectomy using the CO<sub>2</sub> laser, diathermy and scalpel: a histological study in rats. *J Laryngol Otol.* 1988;102:322-7.
25. Bornstein MM, Winzap-Kälin C, Cochran DL, Buser D. The CO<sub>2</sub> laser for excisional biopsies of oral lesions: a case series study. *Int J Periodontics Restorative Dent.* 2005;25:221-9.
26. Fisher SE, Frame JW. The effects of the carbon dioxide surgical laser on oral tissues. *Br J Oral Maxillofac Surg.* 1984;22:414-25.