

Journal section: *Oral Medicine and Pathology*

Publication Types: *Case Report*

Lemierre's Syndrome: A serious complication of an odontogenic infection

Pablo Rosado ¹, Lorena Gallego ¹, Luis Junquera ², Juan C. de Vicente ³

¹ Attending, Department of Oral and Maxillofacial Surgery. Central University Hospital, Oviedo, Spain

² Professor of Oral and Maxillofacial Surgery, University of Oviedo Dental School and Central University Hospital, Oviedo, Spain

³ Professor and chief of Department of Oral and Maxillofacial Surgery. University of Oviedo Dental School and Central University Hospital, Oviedo, Spain

Correspondence:

Oviedo University. Dental School

Catedrático José Serrano

33009. Oviedo. Spain

Junquera@uniovi.es

Rosado P, Gallego L, Junquera L, de Vicente JC. Lemierre's Syndrome: A serious complication of an odontogenic infection. *Med Oral Patol Oral Cir Bucal*. 2009 Aug 1;14 (8):e398-401.

<http://www.medicinaoral.com/medoralfree01/v14i8/medoralv14i8p398.pdf>

Received: 15/11/2008
Accepted: 26/01/2009

Article Number: 5123658909 <http://www.medicinaoral.com/>
© Medicina Oral S. L. C.I.F. B 96689336 - pISSN 1698-4447 - eISSN: 1698-6946
eMail: medicina@medicinaoral.com

Indexed in:

- SCI EXPANDED
- JOURNAL CITATION REPORTS
- Index Medicus / MEDLINE / PubMed
- EMBASE, Excerpta Medica
- SCOPUS
- Indice Médico Español

Abstract

Necrobacillosis, postanginal septicaemia or Lemierre's Syndrome is characterised by suppurative thrombophlebitis of the internal jugular vein with embolization to several sites, including the lungs. We report the case of a 38-year-old man who was initially hospitalized because of odontogenic cellulitis. Given the deterioration of his clinical state (septic shock and multiple organ failure), neck computed tomography was performed, revealing both cervical and parotid abscesses, and thrombosis of the right internal jugular vein. *Streptococcus salivarius* was isolated. The patient was treated with intravenous antibiotics, and surgical drainage and after 6 weeks of treatment, recovered completely. Lemierre's Syndrome is an uncommon, but potentially lethal complication of an odontogenic infection. The case reported here is interesting since the pathogen and the site of primary infection are unusual. *Fusobacterium necrophorum* is the most common pathogen in Lemierre's Syndrome, and to the best of our knowledge there are no similar case reports with *Streptococcus salivarius* as the causative bacteria. Early recognition and high-dose antibiotics are critical elements in reducing mortality.

Key words: *Lemierre Syndrome, thrombosis jugular vein, odontogenic infection.*

Introduction

Necrobacillosis, postanginal septicaemia or Lemierre's syndrome is characterised by suppurative thrombophlebitis of the internal jugular vein and therefore a metastatic infection. In most cases, primary infection is located in oropharynx (1). Alternative sources are middle ear or an odontogenic infection. This fact precedes the onset of a septicemia status.

Fusobacterium necrophorum is the most common etiologic agent (70-80%) (2), although other pathogens or mixed infections have been reported (*Bacteroides fragilis*, *Staphylococcus epidermidis* and *Enterococcus* sp). This was a severe life-threatening syndrome until the antimicrobial agents were available. With the introduction of antibiotics, the incidence and the mortality decreased, that is why it is known as the "forgotten disease".

We report an unusual case of Lemierre's syndrome with a primary odontogenic infection and review the published literature, emphasizing those with an odontogenic origin.

Case Report

A 38 year old male patient, allergic to penicillin and sulfonamides, presented upon admission at the hospital with a right mandibular swelling for three days duration and fever up to 39°C. Physical exploration revealed an important right submandibular cellulitis and sublingual swelling. The orthopantomography (Fig. 1) showed caries affecting to his third right mandibular molar with a periapical radiolucent image. The abscess was drained through an extraoral approach and stained cultures were obtained under local anaesthesia. The patient was hospitalized and received intravenous clindamicin (600 mgrs every 6 hours) and gentamicin (240 mgrs every 24 hours). Third right mandibular molar extraction was made 24 hours later. After 2 days of treatment, fever, pain and swelling had almost completely disappeared.

The third day after hospitalization, the patient presented symptoms of respiratory distress and delirium. He was intubated because of an acute hypoxemic respiratory failure and moved to intensive care unit. The arterial blood gas analysis showed a pH of 7.41, a PaCO₂ of 31 mm Hg, and a PaO₂ of 64 mm Hg while breathing 100% oxygen. Laboratory values revealed platelet count 65000 cells/μL, glucose 157 mg/dL, urea concentration was 211 mg/dL, and creatinine concentration was 2.06 mg/dL. The total bilirubin concentration was 7.4 mg/dL and prothrombin rate was 71%, revealing both a kidney and liver failure. Chest radiographs demonstrated bibasillar infiltrates.

Contrast-enhanced Computed Tomography (CT) of the neck and chest was performed (Fig. 2 and 3), showing submandibular, parotideal and parapharyngeal abscesses, right internal jugular vein thrombosis and right cavitary pulmonary nodules.

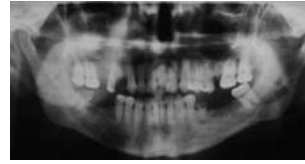


Fig. 1. Orthopantomography showing a dental caries in the third right molar with a periapical radiolucent image.

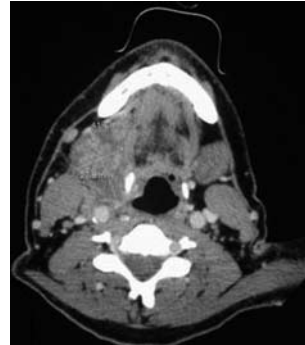


Fig. 2. Contrast enhanced CT of the neck, showing a submandibular abscess.

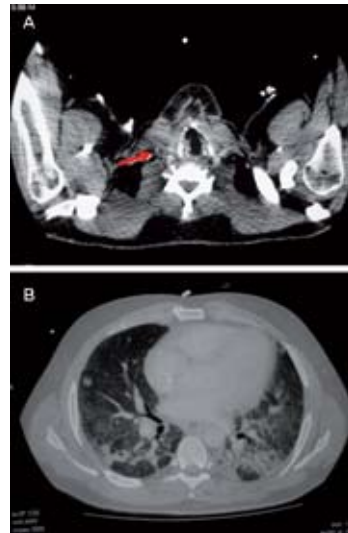


Fig. 3. A. Contrast enhanced CT showing thrombus at right internal jugular vein (arrow). B. Contrast enhanced CT showing septic pulmonary emboli with cavitations and pleural effusion.

Therefore, the patient underwent cervical abscesses drainage and tracheotomy under general anaesthesia. The following days, kidney and liver failures improved, but respiratory distress worsened. Control CT was performed revealing partial thrombosis of the internal jugular vein, septic emboli in right lung and right obstructive atelectasis.

Local bacterial samplings drawn Streptococcus salivarius. After receiving the result of the antibiogram, the antibiotic therapy was changed to clindamicin (600 mg every 6 hours), vancomycin (2 g/day) and levofloxacin (500 mg/day) and was continued for a total of 6 weeks. The patient made rapid improvement and was discharged by day 60. In a control CT, resolution of the right internal jugular vein thrombosis was observed.

Discussion

Lemierre syndrome is an uncommon but potentially lethal complication of an odontogenic infection. Early recognition and high-dose antibiotics are critical elements in reducing mortality. Dentists and oral surgeons must be alert to detect few cases with an odontogenic origin.

An extensive search of English literature between 2001 to 2008 was undertaken to identify published cases, using multiple search criteria: Lemierre's syndrome, F. necrophorum, postanginal sepsis, and septic jugular thrombophlebitis. Ninety-nine cases of this uncommon disease were found and reviewed.

In our review, primary site of infection was oropharynx in 59.5% of cases, followed by mastoiditis (15%). We have found only 7 cases with a primary odontogenic infection (7,07%) (2-7) (Table1). Most of them have been developed from gingivitis and periodontitis, but also dental caries. Only two cases presented thrombophlebitis of internal jugular vein. Five blood cultures were

positive to Fusobacterium necrophorum. Most studies show a minimal role of Fusobacterium necrophorum in oral diseases. 45% of patients, despite the initial treatment, continued with fever and rigors that precede septicemia. Mononucleosis was associated in 11.9% of cases, something that has been considered as a predisposing factor to invasive infections.

Although magnetic resonance (MR) has been used, recent literature suggests that color Doppler ultrasonography and high-resolution CT, respectively (8), play the most important roles in identifying jugular venous thrombosis and pulmonary metastases. Chest X-ray may not be effective in the early diagnosis of septic emboli. Chirinos et al. (1) described a 19.9% of negative X-ray films.

In the pre-antibiotic era, Lemierre's syndrome carried a mortality rate of 83% (9). Then, the only accepted treatment was internal jugular vein ligation in order to prevent septic emboli. Initial treatment involves high-dose IV penicillin/β-lactamase inhibitor and metronidazole, or IV clindamycin monotherapy (9-11). The antibiotic treatment will then be adapted based on the results of the testing. Conversion to 2–6 weeks of oral therapy after the patient's clinical condition has been stabilized is required. In case of antibiotic resistance, ligation of the jugular vein is indicated. The use of anticoagulation agents such as heparin and anti-vitamin K remains controversial. Standard supportive care for respiratory and hemodynamic compromise is important.

Table 1. Lemierre's syndrome: cases with odontogenic source.

	CASE NO.	SOURCE	PATHOGENS	IYVT*	SEPTIC EMBOLI	CHEST TC	TREATMENT
Le Moal et al. ³	1	Periodontal disease	Fusobacterium necrophorum	No	spine	Normal	clindamycin
	2	Periodontal disease	Fusobacterium necrophorum	No	spine	Normal	penicillin + clindamycin
Sonsale et al. ⁴	3	Dental abscess	Fusobacterium necrophorum	No	knee	Normal	metronidazol
Shibasaki Warabi et al. ⁵	4	Caries	Unknown	left	lungs, brain	diffuse nodes	penicillin + metronidazole
Duquesne et al. ⁶	5	Gingivitis	Fusobacterium necrophorum, Staphylococcus aureus and Stenotrophomonas xanthomonas	No	meningitis	Normal	cefotaxime, vancomycine, amikacine
Tan et al. ⁷	6	Caries and periodontitis	Fusobacterium necrophorum	left and right	lungs, meningitis	two small nodes	penicillin + metronidazole
Juárez Escalona et al. ²	7	Dental abscess	Streptococcus intermedius, bacteroides fragilis	No	lungs	difusse abscesses	levofloxacin + vancomicine

* Internal jugular vein thrombosis.

The case reported here is interesting since both, the pathogen and the location of primary infection, are unusual. *Fusobacterium necrophorum* has remained the most common pathogen in Lemierre syndrome and to the best of our knowledge there are no similar case reports with *Streptococcus salivarius* as causative bacteria.

References

1. Chirinos JA, Lichtstein DM, Garcia J, Tamariz LJ. The evolution of Lemierre syndrome: report of 2 cases and review of the literature. *Medicine (Baltimore)*. 2002;81:458-65.
2. Juárez Escalona I, Diaz Carandell A, Aboul-Hons Centenero S, Monner Diéguez A, Mari Roig A, Arranz Obispo C, et al. Lemierre Syndrome associated with dental infections. Report of one case and review of the literature. *Med Oral Patol Oral Cir Bucal*. 2007;12:E394-6.
3. Le Moal G, Juhel L, Grollier G, Godet C, Azais I, Roblot F. Vertebral osteomyelitis due to *Fusobacterium* species: report of three cases and review of the literature. *J Infect*. 2005;51:E5-9.
4. Sonsale PD, Philipson MR, Bowskill J. Septic arthritis of the knee due to *Fusobacterium necrophorum*. *J Clin Microbiol*. 2004;42:3369-70.
5. Shibasaki Warabi Y, Yoshikawa H, Idezuka J, Yamazaki M, Onishi Y. Cerebral infarctions and brain abscess due to Lemierre syndrome. *Intern Med*. 2005;44:653-6.
6. Duquesne F, Milesi C, Guyon G, Saguintaah M, Chautemps N, Sabatier E, et al. *Fusobacterium necrophorum* meningitis: forgotten complication of a gingivitis. *Arch Pediatr*. 2007;14:1000-2.
7. Tan NC, Tan DY, Tan LC. An Unusual Headache: Lemierre's Syndrome. *J Neurol*. 2003;250:245-6.
8. Screatton NJ, Ravenel JG, Lehner PJ, Heitzman ER, Flower CD. Lemierre syndrome: forgotten but not extinct--report of four cases. *Radiology*. 1999;213:369-74.
9. Gunn AA. *Bacteroides septicaemia*. *J R Coll Surg Edinb*. 1956;2:41-50.
10. Moore-Gillon J, Lee TH, Eykyn SJ, Phillips I. Necrobacillosis: a forgotten disease. *Br Med J (Clin Res Ed)*. 1984;288:1526-7.
11. Freeman CD, Klutman NE, Lamp KC. Metronidazole. A therapeutic review and update. *Drugs*. 1997;54:679-708.