

Journal section: Oral Medicine and Pathology

Publication Types: Case Report

## Bilateral mental nerve neuropathy as the sole presenting symptom of Burkitt's Lymphoma

Pedro Martos-Díaz <sup>1</sup>, Raquel Bances-del Castillo <sup>2</sup>, Rosa Vidal-Laso <sup>3</sup>, María Mancha-de la Plata <sup>4</sup>, Gui-Youn Cho-Lee <sup>5</sup>, Luis Naval-Gías <sup>4</sup>

- <sup>1</sup> Consultant in Oral and Maxillofacial Surgery. Nuestra Señora de la Candelaria University Hospital. Santa Cruz de Tenerife  
<sup>2</sup> Consultant in Physical Medicine and Rehabilitation). Nuestra Señora de la Candelaria University Hospital. Santa Cruz de Tenerife  
<sup>3</sup> Resident in Haematology. University Hospital La Princesa. Madrid  
<sup>4</sup> Consultant in Oral and Maxillofacial Surgery. University Hospital La Princesa. Madrid  
<sup>5</sup> Resident in Oral and Maxillofacial Surgery. University Hospital La Princesa. Madrid

Correspondence:

Ifara 75

Santa Cruz de Tenerife. Spain

plmartos9@hotmail.com

Martos-Díaz P, Bances-del Castillo R, Vidal-Laso R, Mancha-de la Plata M, Cho-Lee GY, Naval-Gías L. Bilateral mental nerve neuropathy as the sole presenting symptom of Burkitt's Lymphoma. Med Oral Patol Oral Cir Bucal. 2009 Aug 1;14 (8):e408-10.  
<http://www.medicinaoral.com/medoralfree01/v14i8/medoralv14i8p408.pdf>

Received: 29/07/2008

Accepted: 16/03/2009

Article Number: 2373 <http://www.medicinaoral.com/>  
© Medicina Oral S. L. C.I.F. B 96689336 - pISSN 1698-4447 - eISSN: 1698-6946  
eMail: [medicina@medicinaoral.com](mailto:medicina@medicinaoral.com)

Indexed in:

- SCI EXPANDED
- JOURNAL CITATION REPORTS
- Index Medicus / MEDLINE / PubMed
- EMBASE, Excerpta Medica
- SCOPUS
- Indice Médico Español

### Abstract

There are several pathologies that may cause alteration of the lower lip sensation, therefore a differential diagnosis is needed. Among these pathologies, we have focused on intrabone growing tumours such as Burkitt's Lymphoma. Burkitt's Lymphoma is a malignant tumour of B-Cell lymphocyte origin, classified as a Non-Hodgkin's Lymphoma. Three clinical subtypes are described: endemic, sporadic and HIV associated. It is characterized by very fast growing, undifferentiated lymphocytes and bone marrow infiltration. A high incidence of Burkitt's Lymphoma has been reported in African children. It is known to have a good response to radiotherapy and chemotherapy treatment. This report describes the case of a 29 year-old Spanish man diagnosed with Burkitt's Lymphoma, in which his first and only symptom was bilateral anaesthesia of the lower lip. We have also described the clinical evolution, steps for diagnosis and treatment.

**Key words:** Burkitt's lymphoma, inferior alveolar nerve anaesthesia, mental nerve neuropathy, numb chin syndrome.

## Introduction

Lymphomas are malignant tumours involving cells of the lymphoreticular or immune system. Burkitt's Lymphoma belong to the group of Non-Hodgking Lymphomas and it's characterized by a very high and diffuse proliferation of undifferentiated cells of B lymphoid origin (1).

Metastatic alteration by tumours in the mandible is uncommon. Metastasis from breast, lung and prostate are the most frequent. Burkitt's Lymphoma, especially the endemic variant can also spread into the mandible (2,3). If the mandible marrow is affected, alteration of the inferior alveolar nerve could be the first symptom alerting the presence of this tumour.

## Case Report

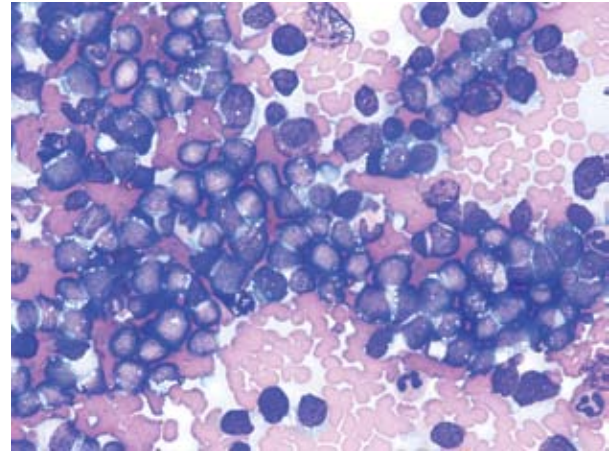
A 29 years old Spanish man with a month history of sensitive alteration of the lower lip is described. Physical examination revealed a complete anaesthesia involving both left and right lower lip. No other alterations were found, even through neurological examination. Panoramic X-Ray didn't show any abnormal signs.

Fifteen days later, the patient came back referring functional alteration of the lower right limb, sensitive alteration in the inner side of the left thigh and sphincter alteration within a Cauda Equina Syndrome. He also presented bilateral submaxillary and cervical lymph nodes.

Blood chemistry analysis showed the existence of leucocytosis standed out :10% of blast cells, 20000 platelets, GOT 114 Ui/l. and 4154 b-microglobulin.

Facial MRI (Fig.1) showed hypointense signal on T1 and hyperintense on T2 at marrow level of the left mandibular angle and joint. These findings are compatible with an infiltration of mandibular bone marrow.

Medullar Histological examination (Fig.2) showed a



**Fig. 2.** Starry Sky appearance. Neoplastic lymphoid cells with basophilic cytoplasm and nucleus with immature chromatin.

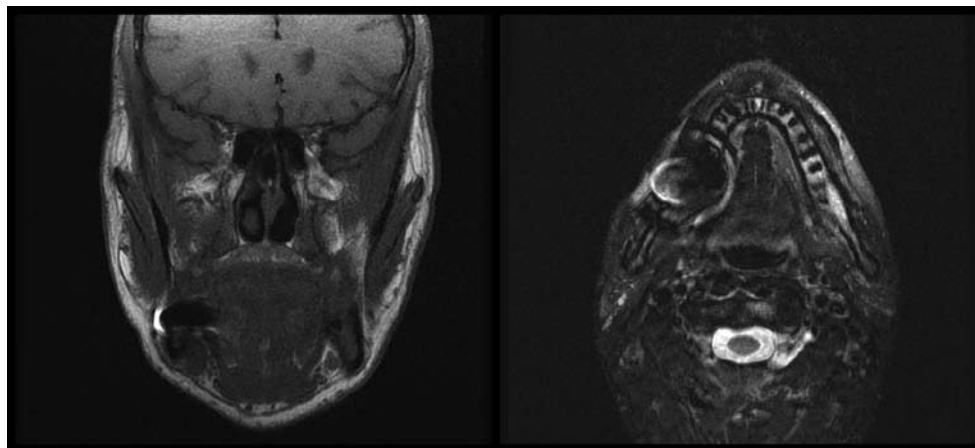
typical "Starry Sky" appearance. An infiltrate of neoplastic lymphoid cells characterized by basophilic cytoplasm and nucleus with immature chromatin.

Immunohistochemical staining was positive for CD 20, CD 19, CD 22, CD 10, and showed high labelling indices (more than 85%) of nuclear staining for Ki-67.

Three years after the beginning of the symptoms, the patient is free of disease after treatment with radiotherapy and chemotherapy.

## Discussion

Burkitt's lymphoma was described in 1958. It is characterized by a monoclonal proliferation of non cleaved cells of B cell-origin (1). Its potential growth fraction of nearly 100 % makes it perhaps the most rapidly dividing tumour known (4).



**Fig. 1.** Hypointense T1 and hyperintense T2 signal at marrow level of the left mandibular angle and joint. Ferromagnetic artefact in right mandibular angle.

**Table 1.** Causes of Mental Nerve Neuropathy.

Metastatic Neoplasms	Syphilis	Mandible Tumors and Cyst
Multiple Mieloma	Mandibular Osteomyelitis	Radiotherapy
Burkitt's Lymphoma	Diabetes Mellitus	Temporal Arteritis
Non Hogking Lymphoma	Sarcoidosis	Trauma
Multiple Sclerosis	AIDS	Mandibular atrophy
Peripheral Neuropathies	Amyloidosis	Exposure to chemical agents
Vertebro-basilar insufficiency	Vasculitis	Yatrogenic
Lyme disease	Sickle cell anemy	

Three clinical variants of Burkitt's Lymphoma have been described: Endemic, non endemic, and human immunodeficiency virus associated (5).

The differences between the endemic and the non endemic variants lie on their clinical manifestations. The endemic variant affects younger African children, presents higher involvement of the mandible and expression of the Epstein-Barr virus genome in more than 90% of cases. As for the sporadic variant, the expression of this virus is less than 10%, is more frequent among older children and involvement of the mandible is very rare.

Histological examination is characterized in all these variants by scattered macrophages throughout the field of malignant lymphocytes, creating the classic "starry-sky appearance" (6).

In the head and neck, the most usual is the involvement of the lymph nodes but the extranodal variant is also possible. Involvement of other structures, such as the tongue, nasopharynx, orbit, maxilla, mandible and mastoid, as well as involvement of different cranial pairs has been described (7, 8).

Despite the fact that our patient did not present any alteration in the mouth, several signs associated to Burkitt's lymphoma with oral involvement were described: Hyperplastic gingivae, swelling of the jaw, mobile teeth and premature eruption of permanent molars (8, 9).

Mental nerve neuropathy or "Numb Chin Syndrome" consists in an alteration of the inferior lip and mental sensibility in relation with different pathologies. (Table 1) Unilateral side of the inferior lip is affected in the majority of cases. However, bilateral alteration is very rare and there are only a few cases described in the English literature (10).

It is not unusual that a Burkitt's lymphoma affects the sensation of the perilabial area, specially when the mandible is also involved. Actually, several cases of unilateral paresthesia of the lower lip caused by involvement of the mental nerve as the initial manifestation have already been described (11). However, this is the first case of a Burkitt's Lymphoma presenting with bilateral anaesthesia of lower lip as sole symptom described in medical literature.

The fast clinical evolution of the illness is remarkable: in the described case, in just fifteen days, it evolved from local involvement of the lip to general neurological involvement.

The treatment plan consist in chemotherapy and radiotherapy (12) and the early diagnosis and treatment are imperative for a favorable prognosis.

**References**

1. Burkitt D. A sarcoma involving the jaws in African children. *Br J Surg.* 1958;46:218-23.
2. Durmuş E, Oz G, Güler N, Avunduk M, Calışkan U, Blanchaert RH Jr. Intraosseous mandibular lesion. *J Oral Maxillofac Surg.* 2003;61:246-9.
3. Naval L, Fraga J, López Elzaudia C, Monje F, Díaz GF, Alamillos F, et al. Perineural dissemination in labial carcinoma. *Rev Stomatol Chir Maxillofac.* 1990;91:65-9.
4. Iversen OH, Iversen U, Ziegler JL, Bluming AZ. Cell kinetics in Burkitt lymphoma. *Eur J Cancer.* 1974;10:155-63.
5. Tao Q, Robertson KD, Manns A, Hildesheim A, Ambinder RF. Epstein-Barr virus (EBV) in endemic Burkitt's lymphoma: molecular analysis of primary tumor tissue. *Blood.* 1998;91:1373-81.
6. Carbone A. Emerging pathways in the development of AIDS-related lymphomas. *Lancet Oncol.* 2003;4:22-9.
7. Wang MB, Strasnick B, Zimmerman MC. Extranodal American Burkitt's lymphoma of the head and neck. *Arch Otolaryngol Head Neck Surg.* 1992;118:193-9.
8. Sisk JD, Wein RO. Sporadic Burkitt's lymphoma presenting with multiple cranial neuropathies. *Otolaryngol Head Neck Surg.* 2006;135:640-2.
9. Lund DI, Rodd H, Craig GT. Burkitt's lymphoma presenting with jaw lesions in a young white girl. *Br J Oral Maxillofac Surg.* 1997;35:438-41.
10. Mohammed N, Cowie F, Junor EJ. Bilateral mental nerve neuropathy. *Clin Oncol (R Coll Radiol).* 2002;14:260.
11. Landesberg R, Yee H, Datikashvili M, Ahmed AN. Unilateral mandibular lip anesthesia as the sole presenting symptom of Burkitt's lymphoma: case report and review of literature. *J Oral Maxillofac Surg.* 2001;59:322-6.
12. Van Sickels JE, Anderegg C Jr, Aufdemorte TB, Bouquot JE. Nonendemic American Burkitt's lymphoma. *J Oral Maxillofac Surg.* 1985;43:453-6.