

Journal section: Oral Surgery
Publication Types: Case Reports

Bilateral bifid mandibular canal: A case report

Ozkan Miloglu ¹, Ahmet Berhan Yilmaz ², Fatma Caglayan ¹

¹ Research Assistant, Department of Oral Diagnosis and Oral Radiology

² Professor, Department of Oral Diagnosis and Oral Radiology
 Faculty of Dentistry, Ataturk University, Erzurum, Turkey

Correspondence:
 Department of Oral Diagnosis and Radiology,
 Faculty of Dentistry,
 Ataturk University,
 Erzurum, TURKEY
 omiloglu@hotmail.com

Miloglu O, Yilmaz AB, Caglayan F. Bilateral bifid mandibular canal: A case report. Med Oral Patol Oral Cir Bucal. 2009 May 1;14 (5):E244-6. <http://www.medicinaoral.com/medoralfree01/v14i5/medoralv14i5p244.pdf>

Received: 01/10/2008
 Accepted: 21/12/2008

Article Number: 5123658852 <http://www.medicinaoral.com/>
 © Medicina Oral S. L. C.I.F. B 96689336 - pISSN 1698-4447 - eISSN: 1698-6946
 eMail: medicina@medicinaoral.com

Indexed in:

- SCI EXPANDED
- JOURNAL CITATION REPORTS
- Index Medicus / MEDLINE / PubMed
- EMBASE, Excerpta Medica
- SCOPUS
- Indice Médico Español

Abstract

The objective of this case report is to help clinicians identify bifid mandibular canals on panoramic radiographs and subsequently use the information in the modification of dental treatment planning. A 45-year old man was referred to the service of Oral Diagnosis and Radiology. Routine panoramic radiography, suggested the presence of bilateral bifid mandibular canals (BMC). Mandibular computed tomography revealed a clear view of bilateral mandibular canals. BMC can be detected on a panoramic radiograph.

Key words: *Bifid mandibular canal, panoramic radiography, cone beam computed tomography.*

Introduction

The mandibular canal, or the inferior alveolar canal, transmits the inferior alveolar nerve, a branch of the third division of the trigeminal nerve, and the associated vessels. The canal typically extends from the mandibular foramen to the mental foramen. The terminal dental and incisive branches leave the inferior alveolar nerve within the canal to supply the teeth and adjacent structures. A terminal branch leaves the canal at the mental foramen to become the mental nerve (1). The location and configuration of mandibular canal variations are important in surgical procedures involving the mandible, such as extraction of an impacted third molar, dental implant treatment, and sagittal split ramus osteotomy (2).

When we reviewed the literature regarding BMC; we encountered only two case reports that had two mental foramina (3,4). The following case report describes a patient with bilateral bifid mandibular canals with two mental foramina by using cone beam computed tomography (CBCT).

Case Report

A 45-year-old man was referred to Department of Oral Diagnosis and Radiology for the prosthetic restoration. The patient stated in his anamnesis that he wanted an implant treatment since he had problems with accepting a removable lower denture. On the routine panoramic radiograph, bilateral, duplicated mandibular canals were suspected. CT scans with axial, sagittal and coro-

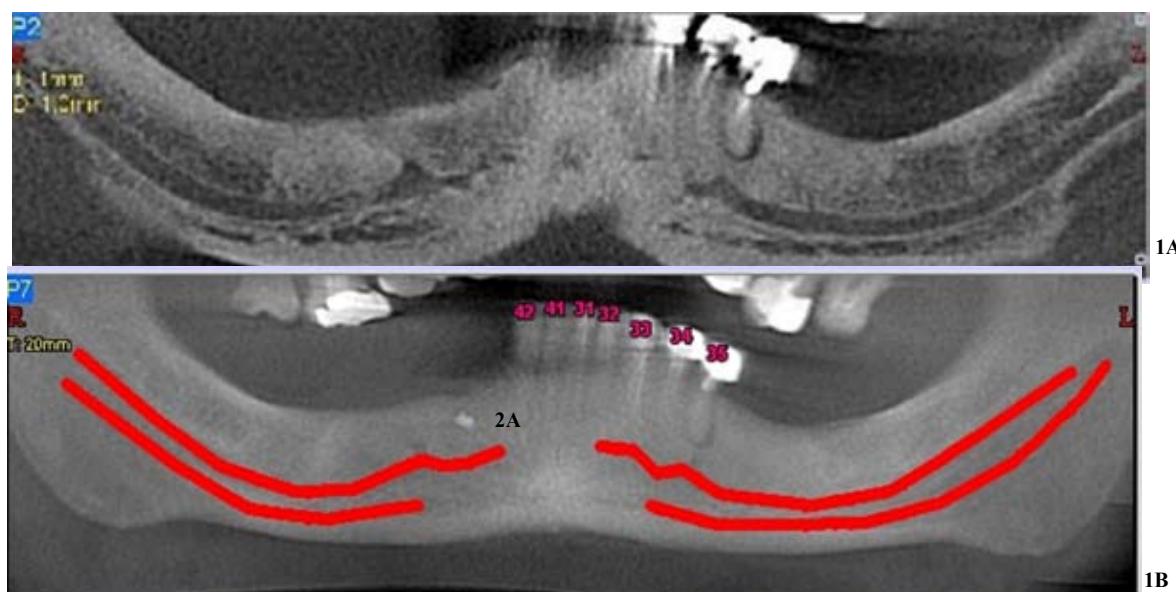


Fig. 1A and 1B. The panoramic view of the patient formed on a selected axial section.




Fig. 2A and 2B. The sagittal image of patient's right and left mandible.

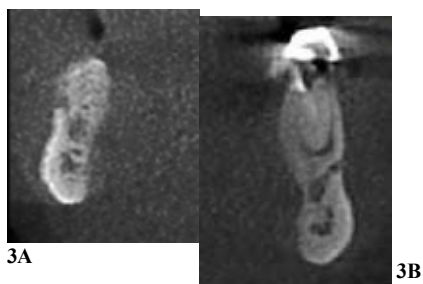

Fig. 3A and 3B. The cross-section images of patient's right and left mandible.

nal cross-sectional cuts perpendicular to the alveolar ridge were performed with cone beam computed tomography (trademark: Newtom Flat Panel) and confirmed this suspicion.

First, the panoramic image formed on a selected axial section more clearly revealed the presence of bilateral mandibular canals (Fig.1A and 1B). The mandibular canal in both sides was raised from two separated mandibular foramen. The upper mandibular canals on both sides ended at the apices of the lower lateral incisors, while the lower duplicate canals, which are relatively shorter and narrower than the upper canals, ended approximately at the level of mental foramen. The presence of the bifid canals was shown on the sagittal (Fig.2A and 2B) and cross-sections (Fig.3A and 3B) as well.

Discussion

Nortjé et al. (5,6) found an occurrence of bifid inferior mandibular canals of 0.9%. Grover et al. (7) were only able to find 0.08% of radiographs suggestive of bifurcation of the inferior alveolar nerve. Langlais et al. (8) found 0.95% cases of bifid inferior mandibular canals. Klinge et al. (9) reported that mandibular canal of specimen cadavers was not visible in 36.1% of panoramic radiographs. Also, Lindh et al. (10) reported that the mandibular canal of specimen cadavers was clearly visible in approximately 25% of panoramic radiographs. Thus, it was considered that there was a limitation in the observation of the mandibular canal using panoramic radiography. Detailed 2-D and 3-D images could be recon-

structured using CBCT. When further studies regarding the BMC will be conducted using CBCT, a frequency of BMC will increase compared with previous studies using panoramic radiography.

Nortjé et al. (5,6) reported that there were three main variants of mandibular canal division or duplication. Another radiographic study by Langlais et al. (8) also revealed similar variations, with four different patterns of bifid mandibular canals being described. The bilateral bifid canals in our cases originated from two separated foramen on both sides. In this respect, our cases might be considered as appropriate for the Type III classification by Nortjé and Type IV classification by Langlais. Nevertheless, the fact that, as opposed to the upper canals, the duplicate canals on both sides extended into different mental foramen allows us to consider our cases as a new division.

The clinical relevance of this issue is to remind clinicians of the variable anatomy of the mandibular canal. Bifid mandibular canals may have some important clinical implications. Inadequate anesthesia may be possible with any bifurcation type, but especially when there are two mandibular foramina such as our case. Conventionally, the presence of profound soft tissue anaesthesia of the ipsilateral lip, chin and teeth is indicative of an effective inferior alveolar nerve block. If a patient experiences only soft tissue anaesthesia around the injection site, but not of the ipsilateral lip or chin, then a problem with local anaesthesia technique is likely to be the cause of the failure. However, if there is soft tissue anaesthesia of the lips and chin but not the teeth, one should consider anatomical variation.

If the problem is considered to be due to a problem with local anaesthesia, a repeat inferior alveolar nerve block should prove effective provided the operator is able to correct his or her technique. If the problem is thought to involve anatomical variation, other types of local anaesthesia technique are indicated, as repeating the same procedure is likely to be ineffective and may result in increased postoperative pain and even trismus (11).

Conclusion

The location and configuration of the mandibular canal should be carefully observed using cross-sectional images of the mandibular canal and images perpendicular to them, reconstructed by CBCT, when conducting surgical procedures such as implant treatment involving the mandible.

References

1. Sanchis JM, Peñarrocha M, Soler F. Bifid mandibular canal. *J Oral Maxillofac Surg.* 2003;61:422-4.
2. Naitoh M, Hiraiwa Y, Aimiya H, Gotoh M, Arijii Y, Izumi M, et al. Bifid mandibular canal in Japanese. *Implant Dent.* 2007;16:24-32.
3. Claeyss V, Wackens G. Bifid mandibular canal: literature review and case report. *Dentomaxillofac Radiol.* 2005;34:55-8.
4. Lew K, Townsen G. Failure to obtain adequate anaesthesia associated with a bifid mandibular canal: a case report. *Aust Dent J.* 2006;51:86-90.
5. Nortjé CJ, Farman AG, De V Joubert JJ. The radiographic appearance of the inferior dental canal: an additional variation. *Br J Oral Surg.* 1977;15:171-2.
6. Nortjé CJ, Farman AG, Grotepass FW. Variations in the normal anatomy of the inferior dental (mandibular) canal: a retrospective study of panoramic radiographs from 3612 routine dental patients. *Br J Oral Surg.* 1977;15:55-63.
7. Grover PS, Lorton L. Bifid mandibular nerve as a possible cause of inadequate anesthesia in the mandible. *J Oral Maxillofac Surg.* 1983;41:177-9.
8. Langlais RP, Broadus R, Glass BJ. Bifid mandibular canals in panoramic radiographs. *J Am Dent Assoc.* 1985;110:923-6.
9. Klinge B, Petersson A, Maly P. Location of the mandibular canal: comparison of macroscopic findings, conventional radiography, and computed tomography. *Int J Oral Maxillofac Implants.* 1989;4:327-32.
10. Lindh C, Petersson A, Klinge B. Visualisation of the mandibular canal by different radiographic techniques. *Clin Oral Implants Res.* 1992;3:90-7.
11. Malamed SF. *Handbook of Local Anaesthesia.* 5th ed. St Louis: Mosby; 2004.