

Journal section: Oral Medicine and Pathology

Publication Types: Case Reports

Multiple hyperodontia: Report of a case with 17 supernumerary teeth with non syndromic association

Antonio Diaz ¹, Jose Orozco ², Maria Fonseca ³

¹ Dentist University of Cartagena. Specialist in Periodontics University Javeriana, Magister in Education University of the Norte. Candidate to Doctorate in Biomedical Sciences University of Cartagena. Professor School of Dentistry University of Cartagena

² Dentist University of Cartagena. Specialist in Stomatology and Oral Surgery University of Cartagena. Professor of Oral Surgery School of Dentistry University of Cartagena

³ Dentist University of Cartagena

Correspondence:

Facultad de Odontología Universidad de Cartagena
Campus de la Salud Barrio Zaragocilla
Cartagena, Colombia,
antoniodiazc@yahoo.com

Diaz A, Orozco J, Fonseca M. Multiple hyperodontia: Report of a case with 17 supernumerary teeth with non syndromic association. Med Oral Patol Oral Cir Bucal. 2009 May 1;14 (5):E229-31.
<http://www.medicinaoral.com/medoralfree01/v14i5/medoralv14i5p229.pdf>

Received: 20/07/2008
Accepted: 21/12/2008

Article Number: 5123658846 <http://www.medicinaoral.com/>
© Medicina Oral S. L. C.I.F. B 96689336 - pISSN 1698-4447 - eISSN: 1698-6946
eMail: medicina@medicinaoral.com
Indexed in:
-SCI EXPANDED
-JOURNAL CITATION REPORTS
-Index Medicus / MEDLINE / PubMed
-EMBASE, Excerpta Medica
-SCOPUS
-Indice Médico Español

Abstract

Supernumerary teeth or hyperodontia is an infrequent developmental alteration that appears in any area of the dental arches and can affect any dental organ. Multiple hyperodontia can be associated with several syndromes such as Gardner's, cleidocranial dysplasia, tricho-rhino phalangeic syndrome or in patients with cleft lip and palate. However, it can be present in patients without any systemic pathology. The presence of supernumerary teeth is associated with different alterations in neighboring teeth, being the most common: over retained teeth or delayed eruption, ectopic eruption, dental malposition, occlusal problems, diastemas and rotated neighboring teeth, among a series of associated pathologies.

The routine use of radiographic images during examination is a valuable tool that helps make the early diagnosis of these types of abnormalities. Keeping in mind that there are different treatment options, the therapeutic modalities increase. A case of a 20 year old female patient with multiple supernumerary teeth with non syndromic association is presented. The teeth were located in the maxilla and the mandible causing a severe malocclusion.

Key words: *Supernumerary teeth, hyperodontia, supplementary tooth, malocclusion.*

Introduction

Supernumerary teeth or hyperodontia are defined as the existence of an excessive number of teeth in relation to the normal dental formula (20 in the deciduous dentitions and 32 in the permanent dentition) (1). They can be present in the maxilla or in the mandible and can be only one, multiple, uni or bilateral (2). The reported prevalence of this abnormality varies between 1,5% and 3,5% in the permanent dentition in comparison with 0,3 to 0,6% in the deciduous dentition. Supernumerary teeth are more frequent in males than in females in a proportion of 2:1 (3).

The most frequent locations for supernumerary teeth are: the midline of the maxilla, palatal area of upper incisors, lower premolar area and distal of the upper and lower third molars (4). Regarding their morphology, supernumerary teeth are classified as supplementary (they duplicate the anatomy of anterior or posterior teeth) or rudimentary (dysmorphic, tubercular or conoid) (5, 6). Multiple hyperodontia can be associated with Gardner's syndrome, Fabry-Anderson syndrome, Ehlers-Danlos syndrome, labial palatal cleft or cleidocranial dysostosis. Multiple supernumerary teeth not associated with syndromes are rare, and the premolar area of the mandible is the most frequent location (7).

The exact etiology of supernumerary teeth is unknown, however, several theories have been postulated to try to explain their presence: the phylogenetic theory as a regression to the anthropoids whose dental formula had more teeth, the autonomic recessive inheritance or linked to the X chromosome, an abnormal reaction to a local traumatic episode, environmental factors, dichotomy of the tooth germ and the theory of hyperactivity of the dental lamina, are the most accepted (8).

The presence of supernumerary teeth is associated with numerous abnormalities in neighboring teeth: over retained or delayed eruption of teeth, ectopic eruption, tooth malposition, occlusal problems, diastemas, tooth displacement, cosmetic problems, cysts derived from the follicle of the supernumerary tooth, dental caries in neighboring teeth due to an increased plaque retention, root resorption, periodontal lesions due to compression of adjacent roots and pulp necrosis (9).

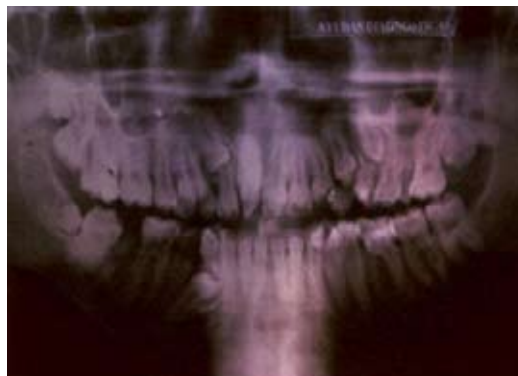
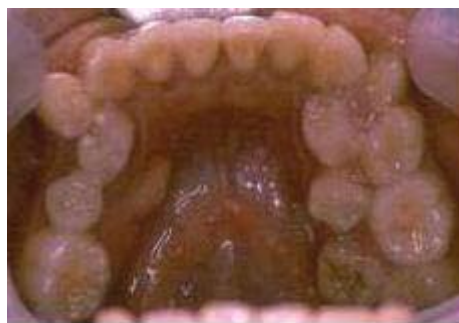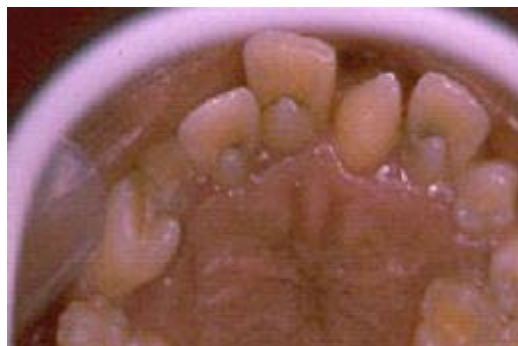Radiographs are the most reliable and definitive method for the diagnosis of supernumerary teeth. The most commonly used radiographs are: panoramic radiograph (orthopantomogram), periapical and occlusal radiographs (10).

Case Report

Female patient of twenty years of age who presents herself to the clinic of the school of dentistry of the University of Cartagena with a chief complaint of dental malposition. During anamnesis she reported that there was no family history of hyperodontia or systemic dis-

ease, the extra oral physical exam revealed the presence of four supernumerary breasts located in the upper and middle abdominal region.

The intra oral exam revealed thirteen erupted supernumerary teeth, nine in the maxilla and four in the mandible, which created a malocclusion (Figure 1 and 2). The panoramic radiograph showed three retained supernumerary teeth in the maxilla located distally to the right third molar, the right canine and left premolar areas, also there was a retained supernumerary tooth in the mandible next to the left premolar area (Figure 3). Several clinical exams were then performed to discard the presence of systemic pathology, and they all showed normal results.



The proposed treatment plan consisted of extraction of the retained and erupted supernumerary teeth in order to initiate orthodontic treatment. At present the patient is undergoing orthodontic treatment and has regular clinical and radiographic controls.

Discussion

Multiple supernumerary teeth not associated with syndromes are a rare anomaly. Yusof in 1990 (7) reported that the premolar region in the lower arch is the most common place for supernumerary teeth. This case had a higher prevalence of supernumerary teeth in the premolar area of both arches, followed by the molar region. Supernumerary teeth can be classified according to their morphology and location in the dental arch; eumorphic and dysmorphic forms were found in this case. Maintaining a supernumerary tooth in the mouth could result in the appearance of different abnormalities. Hegde and Munshi (11), Mason et al (12) reported displacements, rotations, ectopic eruption, and malocclusion in their studies, similar alterations were noted in this clinical case.

It is difficult to establish an ideal treatment for cases of multiple supernumeraries. The clinical and radiographic exam is of vital importance to carry out a good treatment plan which can vary from simple extractions or extractions followed by orthodontic treatment to obtain a correct occlusion.

In this case it was decided to extract the erupted and retained supernumerary teeth followed by orthodontic treatment in order to establish a correct occlusion.

We emphasize the importance of a good clinical history when a patient with multiple supernumerary teeth comes for consultation, since most of them are associated with other syndromes and their presence must be discarded.

This case report presents a patient with 17 supernumerary teeth and 4 supernumerary breasts of smaller size. There have not been any similar cases reported before in which there are other associated abnormalities such as supernumerary breasts.

References

1. Leco Berrocal MI, Martín Morales JF, Martínez González JM. An observational study of the frequency of supernumerary teeth in a population of 2000 patients. *Med Oral Patol Oral Cir Bucal*. 2007;12:E134-8.
2. Garvey MT, Barry HJ, Blake M. Supernumerary teeth--an overview of classification, diagnosis and management. *J Can Dent Assoc*. 1999;65:612-6.
3. Giancotti A, Grazzini F, De Dominicis F, Romanini G, Arcuri C. Multidisciplinary evaluation and clinical management of mesiodens. *J Clin Pediatr Dent*. 2002;26:233-7.
4. Hyun HK, Lee SJ, Ahn BD, Lee ZH, Heo MS, Seo BM, et al. Non-syndromic multiple mandibular supernumerary premolars. *J Oral Maxillofac Surg*. 2008;66:1366-9.
5. Patchett CL, Crawford PJ, Cameron AC, Stephens CD. The man-

agement of supernumerary teeth in childhood--a retrospective study of practice in Bristol Dental Hospital, England and Westmead Dental Hospital, Sydney, Australia. *Int J Paediatr Dent*. 2001;11:259-65.

6. Fernández Montenegro P, Valmaseda Castellón E, Berini Aytés L, Gay Escoda C. Retrospective study of 145 supernumerary teeth. *Med Oral Patol Oral Cir Bucal*. 2006;11:E339-44.

7. Yusof WZ. Non-syndromic multiple supernumerary teeth: literature review. *J Can Dent Assoc*. 1990;56:147-9.

8. Rao PV, Chidzonga MM. Supernumerary teeth: literature review. *Cent Afr J Med*. 2001;47:22-6.

9. Hurlen B, Humerfelt D. Characteristics of premaxillary hyperodontia. A radiographic study. *Acta Odontol Scand*. 1985;43:75-81.

10. Bäckman B, Wahlin YB. Variations in number and morphology of permanent teeth in 7-year-old Swedish children. *Int J Paediatr Dent*. 2001;11:11-7.

11. Hegde SV, Munshi AK. Late development of supernumerary teeth in the premolar region: a case report. *Quintessence Int*. 1996;27:479-81.

12. Mason C, Rule DC, Hopper C. Multiple supernumeraries: the importance of clinical and radiographic follow-up. *Dentomaxillofac Radiol*. 1996;25:109-13.