

## Ameloblastomas mimicking apical periodontitis: a case series

Giuliana Soimu<sup>1</sup>, Juliana de Noronha Santos Netto<sup>2</sup>, Águida Maria Menezes Aguiar Miranda<sup>3</sup>, Danyel Elias da Cruz Perez<sup>4</sup>, Luciana Armada<sup>5</sup>, Fábio Ramoa Pires<sup>6</sup>

<sup>1</sup> DDS, MSc, Post-graduation Program in Dentistry, Estácio de Sá University, Rio de Janeiro/RJ, Brazil

<sup>2</sup> DDS, PhD, Professor, Stomatology, Universidade Federal do Rio de Janeiro, Rio de Janeiro/RJ, Brazil

<sup>3</sup> DDS, MSc, Staff, Stomatology, Brazilian Dental Association, Rio de Janeiro/RJ, Brazil

<sup>4</sup> DDS, PhD, Professor, Oral Pathology, School of Dentistry, Universidade Federal de Pernambuco, Recife/PE, Brazil

<sup>5</sup> DDS, PhD, Professor, Post-graduation Program in Dentistry, Estácio de Sá University, Rio de Janeiro/RJ, Brazil

<sup>6</sup> DDS, PhD, Professor, Oral Pathology, Dental School, Rio de Janeiro State University and Professor, Post-graduation Program in Dentistry, Estácio de Sá University; Rio de Janeiro/RJ, Brazil

### Correspondence:

Post graduation Program in Dentistry, Estácio de Sá University  
Av. das Américas, 700 bloco 8, 2o andar, sala 218, Shopping Città  
CEP 22640-100, Barra da Tijuca, Rio de Janeiro/RJ, Brazil  
ramoafop@yahoo.com

Received: 31/01/2022

Accepted: 04/04/2022

Please cite this article in press as: Soimu G, Netto JNS, Miranda AMMA, Perez DEC, Armada L, Pires FR. Ameloblastomas mimicking apical periodontitis: a case series. Med Oral Patol Oral Cir Bucal. 2022. doi:10.4317/medoral.25338

### Abstract

**Background:** Ameloblastomas are benign odontogenic tumors that can eventually mimic the clinical and radiological features of apical periodontitis. The aim of the present study was to evaluate the clinical, radiological and histological characteristics from a series of ameloblastomas mimicking apical periodontitis diagnosed in a 14-year period.

**Material and Methods:** all cases histologically diagnosed as ameloblastomas from 2005 to 2018 presenting a clinical diagnosis of periapical lesion of endodontic origin were selected for the study. Clinical, radiological and histological characteristics from all cases were tabulated and descriptively and comparatively analyzed.

**Results:** Twenty cases composed the final sample, including 18 solid and 2 unicystic ameloblastomas. Mean age of the affected patients was in the fifth decade with predilection for males (72%). The most common anatomical location was the posterior mandible (55%) and most cases presented a radiolucent unilocular (80%) well-defined (95%) image. Most cases were asymptomatic, but the presence of local swelling and bone cortical rupture were common.

**Conclusions:** Ameloblastomas mimicking periapical lesions of endodontic origin are mostly diagnosed in adult males as well-defined radiolucent unilocular lesions producing local swelling and bone cortical rupture.

**Key words:** Ameloblastoma, apical periodontitis, cyst, diferencial diagnosis, granuloma, periapical lesion.

## Introduction

Most lesions observed in the periapical region are associated with inflammatory processes derived from the dental pulp and its consequent necrosis, as a result of caries or dental trauma. However, there is a wide variety of conditions located in the apical region that can simulate inflammatory periapical diseases. These conditions, known collectively as non endodontic periapical lesions (NEPL), can represent 2 to 27% of the injuries associated with the periapical area submitted to histological analysis (1-7).

Ameloblastomas are locally aggressive epithelial odontogenic tumors characterized by uni or multilocular radiolucent images with predilection for the posterior mandible and can be located in close relationship to the adjacent teeth roots (8-10). Due to their local aggressive behavior early and prompt diagnosis is essential, avoiding misinterpretation as inflammatory conditions leading to unnecessary treatments and delay in establishing correct diagnosis and appropriate surgical treatment (11,12). Although this is an essential subject for the endodontist background, only few case reports and very few small case series have been published focusing on ameloblastomas mimicking apical periodontitis (AMAP) (12-19). Thus, the aim of the present study is to report a series of AMAP with a detailed clinical, radiological and histological analysis.

## Material and Methods

This is a cross-sectional, retrospective and descriptive study that was conducted in accordance with the Declaration of Helsinki and was approved by the Ethics in Research Committee (protocol 2.223.941). All specimens diagnosed as ameloblastomas in the Oral Pathology laboratory, Dental School, Rio de Janeiro State University, from 2005 to 2018 were reviewed. All cases including a clinical diagnosis compatible with apical periodontitis (such as inflammatory periapical lesion, periapical granuloma, periapical or radicular cyst, and dentoalveolar abscess), provided by the responsible clinician and/or oral and maxillofacial surgeon based on panoramic radiographs, were selected for further analysis.

Laboratory records, including data derived from biopsy submission forms, were reviewed and information on age (in years), gender, location of the tumor (maxilla or mandible; anterior or posterior region), symptoms, local swelling, and radiological features (pattern and size of the image, and relationship with the roots of the adjacent teeth by using panoramic radiographs) were retrieved. Hematoxylin and eosin stained histological sections from all cases were reviewed for diagnosis confirmation and for further histological analysis. Cases presenting few or no clinical and radiological informations, and cases in which the histological findings were insufficient for the conclusive diagnosis of ameloblas-

toma were excluded from the final sample.

Data obtained from the clinical, radiological and histological analysis were tabulated and descriptively and comparatively analyzed through the use of the Statistical Program for Social Sciences software (SPSS, IBM, version 20). Statistical significance was established at 5% ( $p < 0.05$ ).

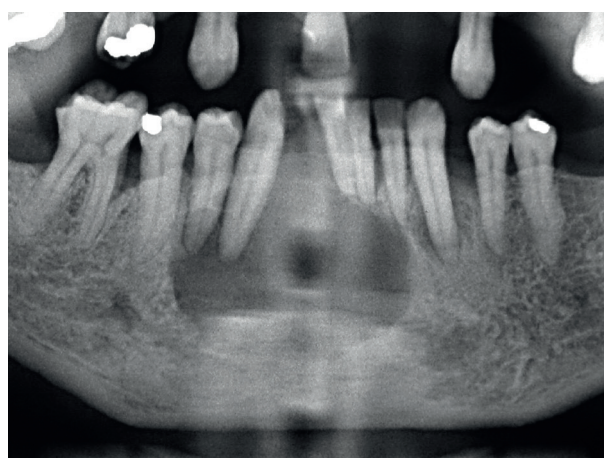
## Results

In the 14-year period (from 2005 to 2018), 20 AMAP were retrieved from the laboratory files, including 18 solid ameloblastomas and two unicystic ameloblastomas. Solid ameloblastomas affected 13 males (72%) and 5 females (28%). The two unicystic ameloblastomas affected males. Mean age of patients with solid ameloblastomas was 41.4 years (standard deviation - SD - 12.77, ranging from 17 to 59 years), and both unicystic ameloblastomas were diagnosed in adults (Table 1). Mean age of the affected males (43.8 years) was higher than affected females (35.4 years) ( $p = 0.223$ ).

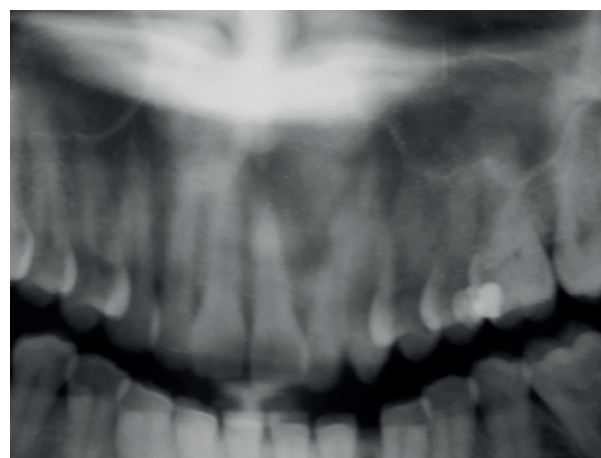
Fourteen solid ameloblastomas (82%) and the two unicystic ameloblastomas were associated with local swelling. The mean radiological size for solid and unicystic ameloblastomas was 37.1 mm and 40 mm, respectively. Mean radiological size of the tumors was larger in females (53.8 mm) than in males (32 mm) ( $p = 0.107$ ). Symptoms were reported in 3 (20%) solid ameloblastomas, and included pain, suppuration and paresthesia. Mobility and/or displacement of the associated adjacent teeth were identified in 7 (47%) solid ameloblastomas and in both unicystic ameloblastomas. Solid ameloblastomas were located in the posterior mandible (10 cases, 55%), anterior mandible (3 cases, 17%), posterior maxilla (3 cases, 17%), and anterior maxilla (2 cases, 11%); each unicystic ameloblastoma affected the posterior and anterior mandible (Table 1). Mean time of onset in solid ameloblastomas was 24 months (SD - 23.63, ranging from 5 to 60 months); both patients affected by unicystic ameloblastomas were not aware about the precise time of onset. Solid and unicystic ameloblastomas presented as unilocular radiolucencies in 78% and 100% of the cases, respectively (Fig. 1, Fig. 2 and Fig. 3). Cortical bone rupture was observed in 14 solid (82%) and in one (50%) unicystic ameloblastoma. The radiological limits were considered well-defined in 16 solid (94%) and in both unicystic ameloblastomas. Endodontic status of the associated teeth was evaluated in 14 solid ameloblastomas and showed that the teeth had endodontic treatment in only two cases (14%). Clinical differential diagnosis included periapical cyst/granuloma (20 cases), odontogenic keratocyst (7), unicystic ameloblastoma (6), residual cyst (5), and nasolabial cyst, dentigerous cyst, lateral periodontal cyst, aneurismal bone cyst, adenomatoid odontogenic tumor, central giant cell lesion and hemangioma (1 case each).

**Table 1:** Distribution of the clinical and radiological information according with the type of ameloblastoma.

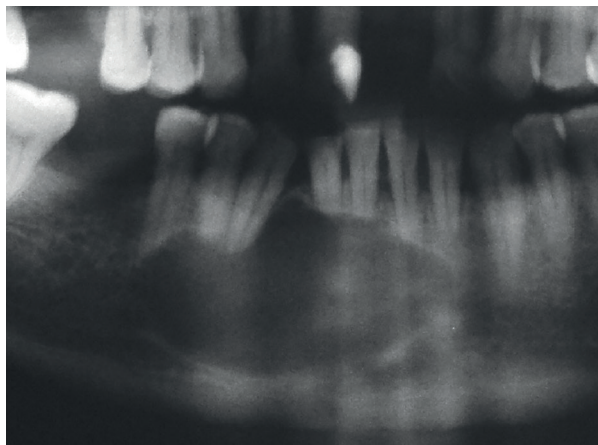
Parameter		Ameloblastoma		Total
		Solid	Unicystic	
<b>Mean age (range; years)</b>		41.4 (17-59)	48.5 (46-51)	20
<b>Gender</b>	Male	13 (72%)	2 (100%)	15
	Female	5 (28%)	0	5
<b>Symptoms</b>	No	12 (80%)	2 (100%)	14
	Yes	3 (20%)	0	3
<b>Local swelling</b>	No	3 (18%)	0	3
	Yes	14 (82%)	2 (100%)	16
<b>Teeth Mobility/ Displacement</b>	No	8 (53%)	0	8
	Yes	7 (47%)	2 (100%)	9
<b>Anatomical location</b>	Posterior mandible	10 (55%)	1 (50%)	11
	Anterior mandible	3 (17%)	1 (50%)	4
	Posterior maxilla	3 (17%)	0	3
	Anterior maxilla	2 (11%)	0	2
<b>Radiological image</b>	Unilocular	14 (78%)	2 (100%)	16
	Multilocular	4 (22%)	0	4
<b>Radiological limits</b>	Well-defined	16 (94%)	2 (100%)	18
	Ill-defined	1 (6%)	0	1
<b>Mean radiological size (range; mm)</b>		37.1 (15-120)	40	19
<b>Root resorption of associated teeth</b>	No	2 (14%)	0	2
	Yes	12 (86%)	2 (100%)	14



**Fig. 1:** Solid ameloblastoma mimicking apical periodontitis. Well-defined unilocular radiolucency in the anterior mandible extending from the left lateral incisor to the right first premolar, causing displacement of lower incisors and right canine!



**Fig. 2:** Solid ameloblastoma mimicking apical periodontitis. Well-defined unilocular radiolucency in the anterior maxilla extending from the right central incisor to the left first premolar, causing displacement of the upper left central and lateral incisors (Courtesy: Drs. Marília Heffer Cantisano, Geraldo Oliveira Silva-Júnior, and Thays Teixeira - Stomatology section, Policlínica Piquet Carneiro, Rio de Janeiro State University, Rio de Janeiro, Brazil).



**Fig. 3:** Solid ameloblastoma mimicking apical periodontitis. Well-defined unilocular radiolucency in the anterior mandible extending from the left lateral incisor to the right second premolar, causing teeth displacement and root resorption (Courtesy: Drs. Roberto Bastos and Henrique Martins da Silveira - Oral and Maxillofacial Surgery, Hospital Pedro Ernesto, Rio de Janeiro State University, Rio de Janeiro, Brazil).

The predominant histological pattern for solid ameloblastomas was the follicular subtype (12 cases, 67%), followed by plexiform (3 cases, 17%), acanthomatous (2 cases, 11%), and adenoid subtypes (1 case, 5%). Both unicystic ameloblastomas were classified as luminal. No statistically significant differences were found when comparing the location of the tumors and their histological pattern with gender of the affected patients.

## Discussion

NEPL represent up to 27% of the conditions located in the periapical region submitted to histological analysis (Table 2). In this group, odontogenic keratocysts, ameloblastomas, nasopalatine cysts, dentigerous cysts, glandular odontogenic cysts, fibro-osseous lesions and giant cell lesions are the most common reported diseases. Ameloblastomas represent 1.2% to 11.5% of all NEPL according with the most recently published literature (1-7).

The present study focused on a descriptive and comparative analysis of the clinical, radiological, and histological characteristics of AMAP comparing the results with those described for ameloblastomas in general (8-10,20). Few studies have been directed to the analysis of periapical and periradicular ameloblastomas and their similarities with apical periodontitis (15,21). Most papers included isolated AMAP case reports (12,22), and there was only one previously published short series (17). The present study seems to be the largest series of AMAP including both solid and unicystic ameloblastomas published up to now.

Solid AMAP included in the present study affected mostly adult males, similarly to solid ameloblastomas in general (8,10,15,20). Mean age of unicystic AMAP in the present study, however, was higher than the mean age of usual unicystic ameloblastomas (8,10). Solid ameloblastomas were the predominant type and the follicular was the most common histological pattern, followed by the plexiform subtype, in agreement with most studies (10,15,20). In contrast, Fregnani *et al.* (9) reported that the plexiform subtype represented 53% of their sample. AMAP were preferentially located in the posterior mandible, as it has been shown for ameloblastomas in general (8-10,15,20). It is worth mentioning, however, that 5 cases (25%) affected the maxilla, reinforcing that ameloblastomas should be considered in the differential diagnosis of endodontic lesions also in this anatomical location. Most ameloblastomas were associated with local swelling but few were symptomatic, similarly to usual ameloblastomas (8-10,21).

The mean radiological size of the AMAP included in the present study was lower than the mean average size of ameloblastomas (8,9). Most cases showed a unilocular radiolucent image, contrarily to most ameloblastomas (9,10,20). This difference could be attributable to the applied sample selection, focusing on ameloblastomas that had a presumptive clinical diagnosis of apical periodontitis. Most radiological limits were considered well-defined, similarly to what has been demonstrated for ameloblastomas in general (8,10). Even being characterized

**Table 2:** Frequency of non endodontic periapical lesions (NEPL) reported in the literature, with emphasis on ameloblastomas.

Authors	Year	Country	N	NEPL	Ameloblastomas *
Koivisto <i>et al.</i> (1)	2012	United States	9723	2587 (26.6%)	114 (4.4%)
Pontes <i>et al.</i> (2)	2014	Brazil	56	66%	4 (7.1%)
Kontogiannis <i>et al.</i> (3)	2015	Greece	1521	52 (3.4%)	1 (1.9%)
Sullivan <i>et al.</i> (4)	2016	United States	5993	166 (2.8%)	2 (1.2%)
Vieira <i>et al.</i> (5)	2020	Brazil	7246	306 (4.2%)	27 (8.8%)
Guimarães <i>et al.</i> (6)	2021	Brazil	1125	208 (18.5%)	24 (11.5%)
Kosanwat <i>et al.</i> (7)	2021	Thailand	1566	157 (10%)	15 (9.6%)

\* Frequency of ameloblastomas on non endodontic periapical lesions (NEPL).

by relatively small well-defined unilocular images, most AMAP included in the present study showed cortical bone disruption, reinforcing the local aggressiveness of these tumors. In the present study, tooth displacement and/or mobility and root resorption were frequently found in both solid and unicystic ameloblastomas. Ide *et al.* (15) reported the presence of root resorption in 5 of the 14 ameloblastomas included in their study. The present study highlights the importance of the correct diagnosis of incipient periapical lesions, whether endodontic or not, correlating the clinical and radiological findings, and when indicated, with the histological features of the surgical specimen (2). In addition to ameloblastomas, the other presumptive clinical diagnosis suggested for the cases included in the present sample were similar to those reported in the literature (16,19). Curiously, solid ameloblastoma was not provided as a clinical differential diagnosis in none of the present reported cases. It is essential for clinicians, particularly endodontists, to be aware of the possible differential diagnosis of periapical radiolucent lesions, considering their clinical and radiological characteristics. Although intraosseous lesions that are not related to pulpal conditions represent a small percentage of periapical lesions, an accurate diagnosis is essential for the correct treatment protocol, taking into account their individual biological behavior, as in the case of ameloblastomas (4). Clinicians should be aware of the main clinical and radiological features that would suggest the possibility of AMAP and alert for its inclusion in the differential diagnosis of periapical radiolucencies. The present results have shown that AMAP were more common in males in their fifties, with most cases located in the posterior mandible, although 25% of the cases affected the maxilla. They were mostly solid ameloblastomas presenting as an asymptomatic swelling associated with teeth mobility. Most cases were characterized by well-defined unilocular radiolucencies, presenting a mean size of 40 mm, and associated with tooth displacement, root resorption, and cortical bone rupture.

## References

1. Koivisto T, Bowles WR, Rohrer M. Frequency and distribution of radiolucent jaw lesions: a retrospective analysis of 9.723 cases. *J Endod.* 2012;38:729-32.
2. Pontes FSC, Fonseca FP, de Jesus AS, Alves ACG, Araújo LM, do Nascimento LS, *et al.* Nonendodontic lesions misdiagnosed as apical periodontitis lesions: series of case reports and review of literature. *J Endod.* 2014;40:16-27.
3. Kontogiannis TG, Tosios KI, Kerezoudis NP, Krithinakis S, Christopoulos P, Sklavounou A. Periapical lesions are not always a sequela pulpal necrosis: a retrospective study of 1521 biopsies. *Int Endod J.* 2015;48:68-73.
4. Sullivan M, Gallagher G, Noonan V. The root of the problem: occurrence of typical and atypical periapical pathoses. *J Am Dent Assoc.* 2016;147:646-9.
5. Vieira CC, Pappen FG, Kirschnick LB, Cademartori MG, Nóbrega KHS, do Couto AM, *et al.* A retrospective Brazilian multicenter study of biopsies at the periapical area: identification of cases of non-

6. endodontic periapical lesions. *J Endod.* 2020;46:490-5.
6. Guimarães GG, Perez DEC, Netto JNS, da Costa ACO, Leonel ACLS, de Castro JFL, *et al.* Nonendodontic periapical lesions: a retrospective descriptive study in a Brazilian population. *Med Oral Patol Oral Cir Bucal.* 2021;26:e502-9.
7. Kosanwat T, Poomsawat S, Kitisubkanchana J. Non-endodontic periapical lesions clinically diagnosed as endodontic periapical lesions: a retrospective study over 15 years. *J Clin Exp Dent.* 2021;13:e586-93.
8. Ledesma-Montes C, Mosqueda Taylor A, Carlos Bregni R, Romero de León E, Palma-Guzmán JM, Páez-Valencia C, *et al.* Ameloblastomas: a regional Latin-American multicentric study. *Oral Dis.* 2007;13:303-7.
9. Fregnani ER, da Cruz Perez DE, de Almeida OP, Kowalski LP, Soares FA, de Abreu Alves F. Clinicopathological study and treatment outcomes of 121 cases of ameloblastomas. *Int J Oral Maxillofac Surg.* 2010;39:145-9.
10. Filizzola AI, Dos Santos TCRB, Pires FR. Ameloblastomas: clinicopathological features from 70 cases diagnosed in a single oral pathology service in an 8-year period. *Med Oral Patol Oral Cir Bucal.* 2014;19:e556-61.
11. Motamedi MHK. Periapical ameloblastoma: a case report. *Br Dent J.* 2002;193:443-5.
12. Faitaroni LA, Bueno MR, De Carvalhosa AA, Ale KAB, Estrela C. Ameloblastoma suggesting large apical periodontitis. *J Endod.* 2008;34:216-9.
13. Hollows P, Fasanmade A, Hayter JP. Ameloblastoma: a diagnostic problem. *Br Dent J.* 2000;188:243-4.
14. Cunha EM, Fernandes AV, Versiani MA, Loyola AM. Unicystic ameloblastoma: a possible pitfall in periapical diagnosis. *Int Endod J.* 2005;38:334-40.
15. Ide F, Mishima K, Yamada H, Horie N, Saito I, Shimoyama T, *et al.* Unsuspected small ameloblastoma in the alveolar bone: a collaborative study of 14 cases with discussion of their cellular sources. *J Oral Pathol Med.* 2008;37:221-7.
16. Kashyap B, Sridhar Reddy P, Desai RS. Plexiform ameloblastoma mimicking a periapical lesion: a diagnostic dilemma. *J Conserv Dent.* 2012;15:84-6.
17. Gondak RO, Rocha AC, Neves Campos JG, Vargas PA, de Almeida OP, Lopes MA, *et al.* Unicystic ameloblastoma mimicking apical periodontitis: a case series. *J Endod.* 2013;39:145-8.
18. Satyabhusan NVV, Routray S, Bendi L, Suresh BV, Majumdar S, Mohanty N. Unicystic ameloblastoma masquerading as huge periapical lesion, both clinically and histopathologically: two case reports with review of literature. *J Clin Imaging Sci.* 2013;3:9.
19. Sinha D, Dormaar T, Salvo N, Politis C, Bornstein MM, Jacobs R. Solid ameloblastoma mimicking a periodontal defect: a diagnostic dilemma. *Eur J Oral Implantol.* 2016;9:189-93.
20. Dhanuthai K, Chantarangsu S, Rojanawatsirivei S, Phattaratatip E, Darling M, Jackson-Boeters L, *et al.* Ameloblastoma: a multicentric study. *Oral Surg Oral Med Oral Pathol Oral Radiol.* 2012;113:782-8.
21. Siar CH, Nakano K, Chelyanayagam PI, Ng KH, Nagatsuka H, Kawakami T. An unsuspected ameloblastoma in the subpontic region of the mandible with consideration of pathogenesis from the radiographic course. *Eur J Med Res.* 2010;15:135-8.
22. Panneerselvam K, Kavitha B, Panneerselvam E, Parameswaran A. Mural unicystic ameloblastoma mimicking odontogenic cyst. *J Family Med Prim Care.* 2020;9:2524-7.

## Acknowledgements

Authors wish to thank Drs. Marília Heffer Cantisano, Geraldo Oliveira Silva-Júnior and Thays Teixeira for kindly providing figure 2 (Source: Stomatology section, Policlínica Piquet Carneiro, Rio de Janeiro State University, Brazil). Authors wish to thank Drs. Roberto Bastos and Henrique Martins da Silveira for kindly providing figure 3 (Source: Oral and Maxillofacial Surgery, Hospital Pedro Ernesto, Rio de Janeiro State University, Brazil).

**Funding**

This study was supported by Fundação Carlos Chagas Filho de Amparo à Pesquisa do Estado do Rio de Janeiro (FAPERJ), Rio de Janeiro, Brazil.

**Conflict of interest**

Authors state that there are no conflicts of interest related to this study.

**Ethics**

This study was conducted in accordance with the Declaration of Helsinki and was approved by the Ethics in Research Committee (protocol 2.223.941).

**Authors contributions**

Giuliana Soimu - Data curation; Formal analysis; Investigation; Methodology; Project administration; Software; Roles/Writing - original draft; Juliana de Noronha Santos Netto - Data curation; Investigation; Methodology; Resources; Validation; Roles/Writing - original draft; Águida Maria Menezes Aguiar Miranda - Data curation; Investigation; Methodology; Resources; Roles/Writing - original draft; Danyel Elias da Cruz Perez - Conceptualization; Formal analysis; Resources; Visualization; Writing - review and editing; Luciana Armada - Formal analysis; Resources; Visualization; Writing - review and editing; Fábio Ramoa Pires - Conceptualization; Data curation; Formal analysis; Funding acquisition; Project administration; Software; Supervision; Writing - review and editing.