

Case Report

Case report of congenital rubella syndrome with sub aortic membrane non-coronary cusp perforation and patent ductus arteriosus

Amith Kiran^{1*}, Harshika S. Shetty², Chetan Gotur², Nishith¹

¹Department of Cardiac Surgery, Srinivas Institute of Medical Sciences, Mangalore, Karnataka, India

²Department of General Surgery, Srinivas Institute of Medical Sciences, Mangalore, Karnataka, India

Received: 31 January 2023

Accepted: 03 March 2023

*Correspondence:

Dr. Amith Kiran,

E-mail: naik.amithkiran@email.com

Copyright: © the author(s), publisher and licensee Medip Academy. This is an open-access article distributed under the terms of the Creative Commons Attribution Non-Commercial License, which permits unrestricted non-commercial use, distribution, and reproduction in any medium, provided the original work is properly cited.

ABSTRACT

Rubella, a common viral infection caused primarily by the rubella virus, is still a global public health concern. Every year, about 30000 instances of congenital rubella syndrome are reported in India, according to health ministry surveillance. A case study of a 6-year-old boy with congenital rubella syndrome was presented here. The child presented with classic abnormalities of congenital rubella syndrome like hearing loss, vision problems, heart defects and intellectual disabilities. Among its many manifestations, congenital heart defects are life threatening, this child was planned for surgical correction of above cardiac lesions. Treatment modalities differ in each type of congenital heart defects and its early detection and surgical intervention can reduce childhood mortality and morbidity.

Keywords: Cardiac lesions, Congenital rubella syndrome, Intellectual disabilities, Rubella virus

INTRODUCTION

Congenital rubella syndrome (CRS) is a set of birth defects that can occur in a new-born baby when the mother contracts rubella, commonly known as German measles, during the first trimester of pregnancy. This condition is quite serious, as the baby can suffer from hearing loss (sensorineural deafness), vision problems (cataracts, chorioretinitis, glaucoma, microphthalmia, pigmentary retinopathy,) heart defects (patent ductus arteriosus or ventricular septal defects, peripheral pulmonary artery stenosis,) and intellectual disabilities (microcephaly), or the pregnancy can end in a miscarriage or stillbirth.¹

Infection with rubella is contracted by inhaling microorganisms that are exhaled, sneezed, or coughed by another infected person. The virus first infects cells in the upper respiratory tract, then spreads throughout the vascular system and replicates in lymphoid tissue of the nasopharynx, infecting numerous organ systems,

including the placenta in early-pregnancy infections. Viremia develops 5-7 days after exposure, following viral replication in the nasopharynx and regional lymph nodes, and spreads throughout the body and transplacentally, causing foetal damage through cell destruction and mitotic arrest.²

The clinical pattern of congenital rubella syndrome can take many different forms, and each type of presentation requires a different approach to therapy. Therefore, it is essential for pediatricians to recognize congenital rubella syndrome early and to accurately identify structural and functional abnormalities.³

CASE REPORT

The 6-year-old male child weighing 17 kg came with chief complaints of exertional breathlessness. The child had a surgical history for non-perforated anus at birth. Clinical examination revealed the child had pallor, cardiovascular system examination (CVS) revealed there

was bilateral mild subcostal retractions, and there were no added breath sounds. S1 was heard and S2 muffled with ejection systolic murmur. Grade 4/5 heard at left upper sternal border conducting to both carotids, there was continuous murmur heard in left second intercostal space conducting to interscapular area (PDA) and apex beat was present in the fifth intercostal space, medial to the midclavicular line. An ophthalmic examination revealed bilateral cataracts in the eyes. Ear, nose and throat (ENT) evaluation revealed bilateral conductive deafness. Chest X-ray revealed cardiomegaly and pectus excavatum. Hemoglobin was 9 g/dl and other blood investigations were normal. Echocardiography revealed significant 4 mm PDA and moderate pulmonary hypertension (PAH) and circumferential subaortic membrane of peak gradient 40 mmHg. Left ventricular function was normal with mild left ventricular hypertrophy. There was moderate AR (aortic regurgitation)-probably from perforation of non-coronary cusp (NCC). PDA gradient was also high.

The child was diagnosed with congenital rubella syndrome with heart defects; he was detected to have left-sided obstructive lesions, severe subaortic membrane, patent ductus arteriosus, non-coronary cusp perforation and mild microcephaly. Hence considering all the above findings and diagnosis, the child was planned for surgical correction of above cardiac lesions.

Procedure

The entire procedure was conducted under general anaesthesia. Median sternotomy was performed followed by cardiopulmonary bypass. Then superior vena cava was sutured using size 4-0 trulene polypropylene suture, followed by inferior vena cava was sutured using size 4-0 trulene polypropylene suture. The aorta was cannulated using two size 2-0 Trubond polyester sutures. Then antegrade cardioplegia (delnido-single shot) was performed and cardia was arrested. Oblique aortotomy was made and subaortic membrane was excised. Then the NCC perforation was repaired with pericardial patch using size 5-0 Trulene polypropylene suture (Figure 1). PDA double ligation was performed using size 2-0 Trubond polyester suture. Haemostasis was achieved by using Trutite-100 ligating clips. Aortotomy was closed using size 5-0 Trulene polypropylene suture in 2 layers and sternum was closed using no. 2 size Trusteel stainless steel sutures.

Post-operative period

Post-operative period was uneventful and postoperative ECHO showed no patent ductus arteriosus flow, no aortic regurgitation, no residual subaortic membrane, intact ventricular septum and interatrial septum intact, no gradient in left ventricular outlet tract, ejection fraction: 61%, fractional shortening: 32% and end-diastolic volume: 62 ml.

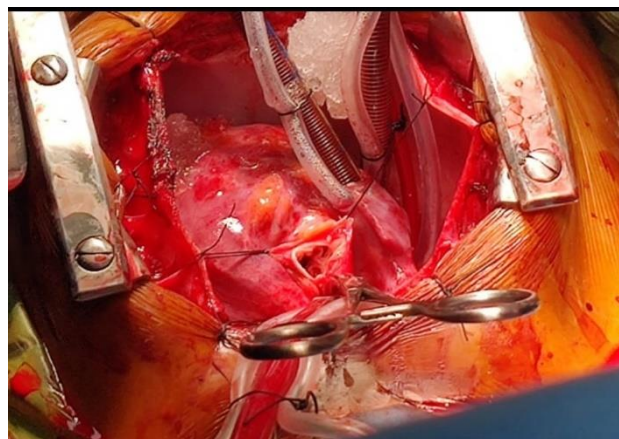


Figure 1: Sub aortic membrane and non-coronary cusp repaired with pericardial patch.

DISCUSSION

Rubella is a common viral infection that primarily affects children and adolescents. According to WHO estimates from 2008, 110000 infants are born with congenital rubella syndrome, making rubella a prominent cause of congenital abnormalities. Every year, about 30000 instances of congenital rubella syndrome are reported in India, according to health ministry surveillance.⁴⁻⁶

Congenital rubella syndrome (CRS) contributes to 8.5% of congenital heart defects. CRS is associated with a wide spectrum of congenital heart defects. The etiology of a large number of congenital heart defects remains elusive.⁷ Detailed studies on the cause and mechanism of development of congenital heart defects need to be undertaken. Commonly the congenital heart defects in congenital rubella syndrome is atrial septal defect, patent ductus arteriosus, pulmonary artery stenosis, tetralogy of fallot, and ventricular septal defect.⁸ In our case it was left-sided obstructive lesions, severe subaortic membrane, patent ductus arteriosus, non-coronary cusp perforation and mild microcephaly. Several studies have documented patent ductus arteriosus (47.5%) as the most common among congenital heart defects followed by atrial septal defect (17.5%) and ventricular septal defect (17%) which is more consistent with this study.^{9,10,12} Pattern of congenital heart defects were also diverse in this study. Hence our study was a variant in the congenital heart defects of congenital rubella syndrome. Hence, we reported this as a case report.

Incidence of congenital heart defects varies in different studies, according to surveillance study conducted by Indian Council of Medical Research and the Ministry of Health and Family Welfare for 2 years (2016-2018), 645 CRS were enrolled and among them 78.8% patients reported congenital heart defects, 59% patients reported vision defects and 38.6% patients reported hearing impairment which is more consistent with this study.¹¹ Another surveillance study conducted in Myanmar also

had congenital heart defects as most common sign of CRS (72%).¹²

The chest X-ray of congenital heart disease cases showed cardiomegaly in 71% cases, and patchy opacity in 65% of the cases.¹² The chest X-ray of the study revealed cardiomegaly and pectus excavatum. It was consistent with this study. Congenital heart disease was found to be an important cause of cardiomegaly.

CONCLUSION

The presence of congenital heart defects is significant in CRS. Congenital heart defects manifest itself in a variety of patterns, and treatment modalities and surgical interventions vary depending on the congenital heart defects. As a result, any infant suspected of having CRS should undergo cardiac evaluation and treated accordingly.

Funding: No funding sources

Conflict of interest: None declared

Ethical approval: Not required

REFERENCES

1. CDC. Congenital Rubella Syndrome. Chapter 15. Manual for the Surveillance of Vaccine-Preventable Diseases. Centers for Disease Control and Prevention. Available at: <https://www.cdc.gov/vaccines/pubs/surv-manual/chpt15-crs.html>. Accessed on 10 January 2023.
2. Mawson AR, Croft AM. Rubella virus infection, the congenital rubella syndrome, and the link to autism. *Int J Environ Res Public Health*. 2019;16(19):3543.
3. Nazme NI, Hoque MM, Hussain M. Congenital rubella syndrome: an overview of clinical presentations in Bangladeshi children. *Delta Med Col J*. 2014;2(2):42-7.
4. Kaushik A, Verma S, Kumar P. Congenital rubella syndrome: a brief review of public health perspectives. *Ind J Pub Health*. 2018;62(1):52.
5. Athira PS, Simon H, Sivakumar T. Congenital rubella syndrome- a case report. *Int J Res Rev*. 2019;6(11).
6. WHO. Fact sheet: Rubella. Available at: <https://www.who.int/news-room/fact-sheets/detail/rubella>. Accessed on 10 January 2023.
7. Priyanka P, Vyas V, Deora S, Nag VL, Singh K. Epidemiology, etiology and clinical associations of congenital heart disease identified during congenital rubella syndrome surveillance. *J Trop Pediatr*. 2022;68(6):089.
8. Mekonnen D. Clinically confirmed congenital rubella syndrome: the role of echocardiography. *Ethiop J Health Sci*. 2017;27(2):197-202.
9. Begum NNF. Device closure of patent ductus arteriosus in complicated patient. *JAFMC Bangladesh*. 2011;7:43-5.
10. Oster ME, Riehle-Colarusso T, Correa A. An update on cardiovascular malformations in congenital rubella syndrome. *Birth Defects Res A Clin Mol Teratol*. 2010;88:1.
11. Murhekar M, Verma S, Singh K, Bavdekar A, Benakappa N, Santhanam S, et al. Epidemiology of congenital rubella syndrome (CRS) in India, 2016-18, based on data from sentinel surveillance. *PLoS Negl Trop Dis*. 2020;14(2):0007982.
12. Nazme NI, Hussain M, Hoque M, Dey AC, Das AC. Study of cardiovascular malformation in congenital rubella syndrome in two tertiary level hospitals of Bangladesh. *Bangladesh J Child Health*. 2014;38(3):137-41.

Cite this article as: Kiran A, Shetty HS, Gotur C, Nishith. Case report of congenital rubella syndrome with sub aortic membrane non-coronary cusp perforation and patent ductus arteriosus. *Int J Res Med Sci* 2023;11:1821-3.