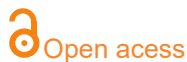

ORIGINAL ARTICLE

New insights about myofibrillar myopathies: the role of metalloproteinases 2 and 9 in the pathogenesis

Alzira Alves de Siqueira Carvalho^{a,b,c}, Vinicius Gomes Silva^a, Alan Patricio da Silva^b, Roseli Corazzini^a, Emmanuelle Lacene^c



^aDepartamento de Neurociências- Laboratório de doenças neuromusculares da FMABC, Centro Universitário FMABC, Santo André, SP, Brasil

^bLaboratório de Delineamento de Estudos e Escrita Científica – Centro Universitário FMABC, Santo André, Brasil

^cLaboratoire de Pathologie musculaire –Risler, GH Pitié-Salpêtrière, 75013 Paris, France.

Corresponding author

alanpatricio.fmabc@gmail.com

Manuscript received: december 2021

Manuscript accepted: december 2021

Version of record online: january 2022

Abstract

Background: There are few reports suggesting that gene expression and activation of various matrix metalloproteinases (MMPs) are deregulated. MMP-2 and MMP-9 represent the two MMPs, which degrade type IV collagen, the component of basement membrane.

Methods: We analysed the involvement of gelatinases, MMP-2 and MMP-9, in the pathogenesis of myofibrillar myopathy (MFM). Muscle specimens from 23 patients well diagnosed with MFM, were immunostained by MMP-2 and MMP-9. We analysed qualitatively the immunoeexpression in three compartments: subsarcolemmal (SSC), intracytoplasmic (ICC) and perinuclear (PNC).

Results: 95,7% and 100% samples showed MMP-2 and MMP-9 upregulation ICC, respectively. PNC showed MMP-2 (82,6%) and MMP-9 (8,7%) regulation ($p < 0.001$). SSC and ICC did not present statistical significance. There was no correlation between mutated gene and immunohistochemical pattern distribution.

Conclusion: Our results suggest that MMP-2 and/or MMP-9 could participate in the pathomechanism of MFM, causing damage of sarcomere and deposition of protein aggregates.

Keywords: MMP-2, MMP-9, Myofibrillar myopathy, muscle biopsy, metalloproteinase

Suggested citation: Carvalho AAS, Silva VG, Silva AP, Corazzini R, Lacene E. New insights about myofibrillar myopathies: the role of metalloproteinases 2 and 9 in the pathogenesis. *J Hum Growth Dev.* 2022; 32(1):101-107. DOI: 10.36311/jhgd.v32.12913

Authors summary

Why was this study done?

There are few reports suggesting that gene expression and activation of various matrix metalloproteinases (MMPs) are deregulated. MMP-2 and MMP-9 represent the two MMPs, which degrade type IV collagen, the component of basement membrane.

What did the researchers do and find?

Our results suggest that MMP-2 and/or MMP-9 could participate in the pathomechanism of MFM, causing damage of sarcomere and deposition of protein aggregates.

What do these findings mean?

The mutations of known genes responsible for MFM will lead to an absence or dysfunction of coded proteins, causing mechanical instability of the sarcomere and, consequently, injury to the subcellular fiber compartments (ECM, sarcolemma, sarcoplasm, nucleus, and endoplasmic reticulum).

BACKGROUND

Since the discovery of metalloproteinases and its functions in 1962, they have been identified as extracellular matrix (ECM) proteinases responsible for transforming the matrix and degrading its components¹. However, the discovery of an intracellular function of MMP-2 challenged this idea corroborating that MMP-2 not only repairs the ECM but also acts intracellularly in ischemia-reperfusion in myocardium by degrading troponin I, contributing therefore, to cardiac dysfunction¹⁻⁴.

Regarding the role of MMPs in some myopathies, there are few reports suggesting that stimulation of various MMPs and also gene expression is deregulated. Whilst MMP-2 and MMP-9 are likely involved in the pathology of dystrophin-deficient skeletal muscle^{5,6}, MMP-9 is implicated in the inflammatory myopathies during the process of elimination of necrotic fibers and muscle degeneration and MMP-2 may be associated with the process of reconstruction of ECM during muscle regeneration and fiber growth^{7,8}.

Myofibrillar myopathies (MFM), a heterogeneous group of hereditary or sporadic skeletal and cardiac muscle disorders of sarcomere, are still a challenge in terms of our understanding about the pathogenesis⁹. Many different components are involved in the cascade of events occurring in muscle fibers in these disorders, as mutant proteins, a defective ubiquitin – proteasome system and oxidative stress¹⁰. Nevertheless, there are no previous studies correlating the activation of MMPs and MFM.

In order to determine other components engaged in this pathogenic process we decided to examine the involvement of the gelatinases MMP-2 and MMP-9 in in muscle fibers in MFM.

METHODS

Muscle biopsies from 23 well-characterized patients with a previous diagnosis of MFM were studied. The diagnosis was obtained by clinical findings, morphological and ultrastructural aspects of muscle biopsies, and genetic studies. Control muscles specimens from 4 patients showing minimal and no specific findings in muscle biopsy were concurrently examined. We collected demographic data (gender, age of onset and age of diagnosis), gene mutated and specific mutations in order to correlate them with immunocytochemistry results.

Single immunocytochemistry: Five-micrometer serial sections from muscle specimens, stored in a freezer at -80°, were incubated in acetone at 4°C for 10 minutes,

washed in 0.05 mol/L Tris-buffered saline (pH 7.5) for 15 minutes, and fixed for 30 minutes with a blocking reagent containing 2% bovine serum albumin and 5% normal goat serum or 5% horse serum. Sections were then incubated overnight at 4°C with one of the following antibodies: goat polyclonal IgG against human MMP-9 (dilution 1:50; Santa Cruz, Santa Cruz, CA, USA) or rabbit polyclonal IgG against human MMP-2 (dilution 1:400; Chemicon, Temecula, CA, USA). These affinity-purified antibodies are well characterized and do not cross-react with each other. After being washed for 30 minutes in Tris-buffered saline, the sections were incubated with biotinylated goat anti-rabbit IgG for MMP-2 or biotinylated horse anti-goat IgG for MMP-9, followed by fluorescent isothiocyanate avidin D.

We analyzed qualitatively the MMP-2 and MMP-9 muscle immunorexpression from all patients, including controls by optic microscopy fluorescence in three different compartments - subsarcolemmal (SS), intracytoplasmic (IC), and perinuclear (PN) - classifying them as expressed (+) or no expressed (-). In order to correlate the histopathological and immunocytochemical findings, five-micrometer serial sections were also stained with hematoxylin and eosin simultaneously.

Statistical analysis

To compare the immunostaining pattern and its correlation with demographic and genetic data, we performed the McNemar non-parametric test. For the tests, we used the SPSS 17.0 softwares for Windows. The significance level used for the tests was 5% [11]. Qualitative variables were presented using absolute frequency and relative frequency. In order to compare MMP-2 and MMP-9 regulation among the genetic groups, the Chi-square test was used. The level of significance adopted in this analysis was $p < 0.05$. The statistical program used was Stata version 11.0.

RESULTS

Demographic features and molecular diagnosis from these patients are shown in Table 1. Among the patients, gender distribution was 11 (47.8%) females and 12 (52.2%) males. In our sample, 21 out 23 patients (91.3%) were genetically identified — DES=9 (39.1%), ZASP=5 (21.7%), FLNC=3 (13%), MYOT=2 (8.7%) and CRYAB=2(8.7%) — and in two we did not find a pathogenic variant (NMF) (8.7%).

Table 1: Demographic, molecular and immunohistochemical findings.

Patient	Sex	Δ t Diag	Mutation	MMP-2 PN	MMP-2 SS	MMP-2 IC	MMP-9 PN	MMP-9 SS	MMP-9 IC
1	F	0	FLNC	-	+	+	-	-	+
2	F	10	DES	-	+	+	-	-	+
3	F	19	DES	-	+	+	-	+	+
4	M	21	DES	-	+	+	-	+	+
5	M	14	NMF	+	-	-	-	+	+
6	M	4	NMF	+	-	+	-	-	+
7	M	20	NMF	+	-	+	-	-	+
8	M	9	ZASP	+	-	+	-	-	+
9	F	5	MYOT	+	-	+	-	+	+
10	F	14	FLNC	+	-	+	-	+	+
11	M	25	ZASP	+	-	+	-	+	+
12	F	6	NMF	+	-	+	-	+	+
13	M	32	NMF	+	-	+	-	+	+
14	M	7	DES	+	-	+	+	+	+
15	M	10	DES	+	+	+	-	+	+
16	F	18	DES	+	+	+	-	+	+
17	M	14	NMF	+	+	+	-	+	+
18	F	8	ZASP	+	+	+	-	+	+
19	F	0	DES	+	+	+	-	+	+
20	M	7	ZASP	+	+	+	-	+	+
21	F	34	NMF	+	+	+	-	+	+
22	F	8	DES	+	+	+	+	+	+
23	M	20	FLNC	+	+	+	-	+	+
Total (%)				82.6	56.5	95.7	8.7	78.3	100.0

Legend: MMP: metalloproteinase; Δ t Diag: interval between age onset and diagnosis; NMF: no mutation found; PN: perinuclear; SS: subsarcolemmal; IC: Intracytoplasmic; -: downregulated; +: upregulated; NS: no symptoms.

The age of diagnosis varied from 22 to 72 years (mean: 53.3 years; median: 56 years). The age of onset of symptoms ranged from 0 to 66 years (mean: 40.1 years; median: 41 years). The interval between the beginning of symptoms and the diagnosis varied from 0 to 34 years (mean: 13.3; median: 10).

The MMP-2 and MMP-9 muscle immunoeexpression pattern distributions are presented in Table 1 and Graphic

1. It should be noted that both MMPs have a constitutive expression in endomysial blood vessels including control samples. There was no correlation between the immunoeexpression pattern distribution and the duration of symptoms ($p > 0.05$). Most patients showed MMP-2 and MMP-9 expression (+) in the IC compartment (95.7% and 100%, respectively). The control group showed no expressed (-) in all 4 samples. (Figure 1).

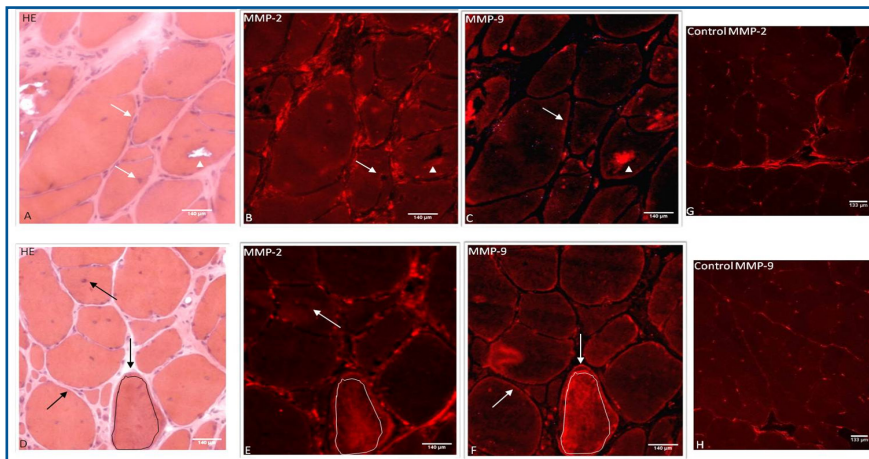
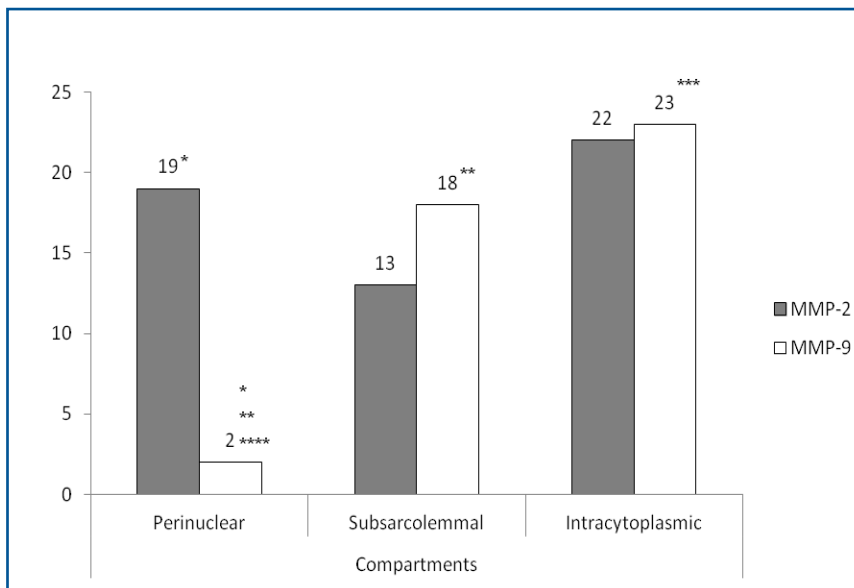


Figure 1: Immunocalization of MMP-2 and 9.



Graphic 1: Comparative between different comartments of metalloproteinases MMP-2 and MMP-9.

*
** non-parametric. MCNemans teste - significant difference $p < 0.001$.

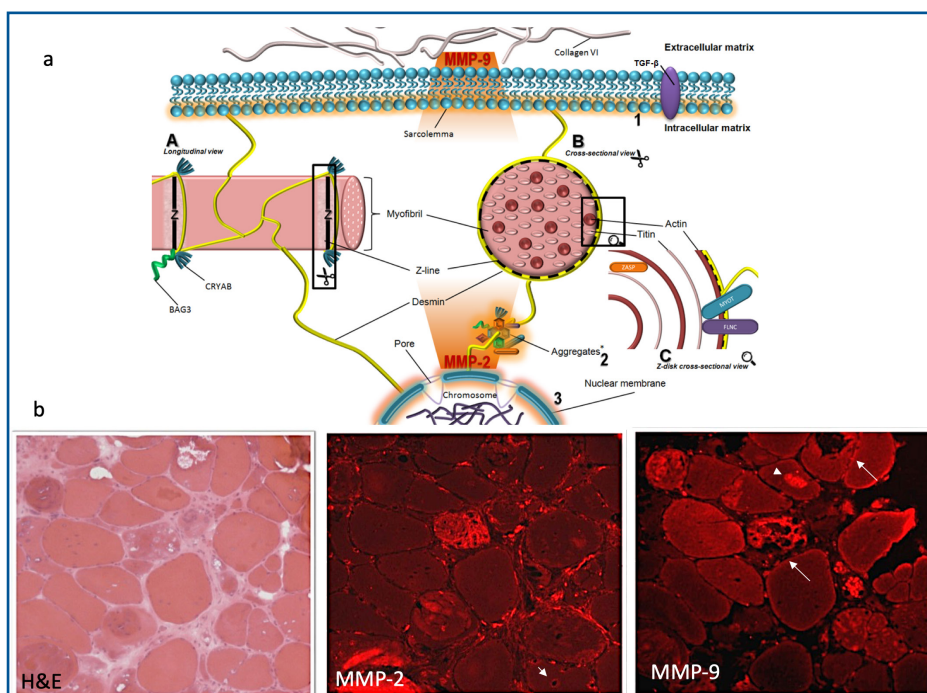


Figure 2: Schematic view of the sarcomere structure and role of MMP-2 and 9.

In terms of MMP-2 and MMP-9 expression, PN compartment showed a significant difference between MMP-2 expressed (82.6%) and MMP-9 expressed (8.7%) ($p < 0.001$). In contrast, SS and IC compartments did not present statistical significance between MMP-2 and 9 expression (graphic 2, Table 1) however, the protein aggregates showing expression (+) varied from one patient to another. In addition, the same protein aggregate was expressed by MMP-9 but not by MMP-2, and vice-versa in the same section (Figure 2b). Also, the immunodistribution of MMPs were similar in most patients in relation to different genetic groups (FLNC, DES, MYOT, ZASP, CRYAB and NMF) ($p > 0.05$).

DISCUSSION

The pathogenesis and etiology of myofibrillar myopathy is not yet completely elucidated. Destruction of the myofibrillar network starting at the z-disk is supposed to be the first stage in the possible mechanism participating in the sarcomere's damage process.

Our study was a descriptive analysis about the behavior of MMP-2 and 9 in different compartments of the skeletal muscle fiber (Figure 1). Particularly, MMP-2 presented significant expression (+) in the PN compartment ($p < 0.001$) in relation to MMP-9. By contrast, MMP-9 expression (+) was predominantly in the SS compartment demonstrating a possible influence of this gelatinase in ECM. In relation to IC compartment, our results were intriguing: both MMPs were expressed (+) in different regions of sarcoplasm. The same protein aggregate was expressed (+) by MMP-9 but not by MMP-2, and vice-versa in the same section (Figure 2b).

MMP-9 is normally expressed during early embryonic developmental while in normal adult tissues, it is not present suggesting that MMP-9 are increased upon tissue injury in order to repair damage, release growth factors and modulation of ECM. By contrast, the continuous expression of MMP-9 will contribute to inflammation and tissue destruction in different diseases⁵. Choi and Dalakas demonstrated that upregulation of MMP-2 and 9 in the muscle membrane of patients with s-IBM and PM may cause an active role in disarrangement of the integrity of the muscle fibers by the autoinvasive cytotoxic T cells⁷. In addition, increased proinflammatory cytokines in mdx mice, appear to be some of the potential stimuli for up-regulation in MMP-9 levels in skeletal and cardiac muscle in muscular dystrophy¹².

In relation to MMP-2, it is constitutively expressed by many cell types including skeletal muscle and has a minimal regulation at the transcriptional level therefore, the regulation process takes place at the post-transcriptional level.

Ogura

According to previous reports, MMP-2 is demonstrated in several subcellular compartments, including the thin and thick myofilaments, close to the Z disks of the cardiac sarcomere, the cytoskeleton, nuclei, mitochondria, and caveolae observed in cardiac sarcomere after injury induced by ischemia^{4,13}.

In view of the aforementioned aspects of MMPs there would be another component of cell signaling that could be part of the protein aggregate deposit and MMPs expressed would be just an epiphenomenon? Or why not, those MMPs expressed (PN, IC and SS) could not be protection factor to muscle fiber?

We believe that both MMPs may participate actively in the pathological cascade leading to muscle membrane injury. MMP-9 comes from extracellular space into intracellular space and MMP-2 comes from intracellular space into extracellular space (Figures 1, 2a). Several intracellular processes are related to MMP-2 as cleaving specific proteins inside of myocytes thereafter reducing contractile function⁴.

The mutations of known genes responsible for MFM will lead to an absence or dysfunction of coded proteins, causing mechanical instability of the sarcomere and, consequently, injury to the subcellular fiber compartments (ECM, sarcolemma, sarcoplasm, nucleus, and endoplasmic reticulum). The mechanical stress due to this instability would lead to MMP-2 upregulation with consequent destruction of the sarcomere, causing accumulation of proteins in the sarcoplasm (aggregates).

CONCLUSION

This study was the first one to analyze the role of MMPs in the pathogenesis of MFM. Our results showed that MMP-2 and 9 are expressed in different compartments of skeletal muscle while in control muscles they were not demonstrated. Therefore, they could participate in the pathomechanism of MFM, causing damage of sarcomere and deposition of protein aggregates.

More studies are necessary to clarify this new concept. Our study provides only preliminary qualitatively data about the role of MMPs in order to better understand the pathogenesis of this set of disorders.

Ethics approval and consent to participate

Written informed consent for DNA and RNA analysis was obtained from all the recruited patients when primary diagnostic procedures were performed, with explicit consent for future use for research purposes, according to the Declaration of Helsinki and the study was approved by our local Ethics Committee."

Consent for publication

Not applicable.

Availability of data and material

The datasets used and / or analyzed during the current study will be available from Professor Alves de Siqueira Carvalho on a reasonable request

Competing interests

None of the authors has any conflict of interest to disclose

Funding

Not applicable

Authors' contributions

All authors have contributed to the work, agree with the presented findings. The article has not been published before nor is being considered for publication in another journal.

Abbreviations

- 1.DES: desmin
- 2.DMD: Duchene muscular dystrophy
- 3.ECM: extracellular matrix

- 4.FLNC: filamin C
- 5.IC: intracytoplasmic
- 6.MMP: matrix metalloproteinase
- 7.MFM: myofibrillar myopathy
- 8.MYOT: myotilin
- 9.NMF: no mutation found
10. PM: polymyositis
11. PN: perinuclear
12. sIBM: sporadic inclusion body myositis
13. SS: subsarcolemmal
14. Zasp (LDB3): LIM DOMAIN-BINDING 3

REFERENCES

1. Wang W, Schulze CJ, Suarez-Pinzon WL, Dyck JR, Sawicki G, Schulz R. Intracellular action of matrix metalloproteinase-2 accounts for acute myocardial ischemia and reperfusion injury. *Circulation*. 2002;106: 1543–1549.
2. Sung MM, Schulz CG, Wang W, Sawicki G, Bautista-Lopez NL, Schulz R. Matrix metalloproteinase-2 degrades the cytoskeletal protein alpha-actinin in peroxynitrite mediated myocardial injury. *J Mol Cell Cardiol*. 2007; 43:429-36
3. DeCoux A, Lindsey ML, Villarreal F, Garcia RA, Schulz R. Myocardial matrix metalloproteinase-2: inside out and upside down. *J Mol Cell Cardiol*. 2014; 77:64-72
4. Schulz R. Intracellular Target of Matrix Metalloproteinase-2 in Cardiac Disease: Rationale and Therapeutic Approaches. *Annu Rev Pharmacol Toxicol*. 2007;47: 211-42
5. Ogura Y, Tajrishi MM, Sato S, Hindi SM, Kumar A. Therapeutic potential of matrix metalloproteinase in Duchenne muscular dystrophy. *Front Cell Dev Biol*. 2014; 2: 1-11.
6. Fukushima K, Nakamura A, Ueda H, Yuasa K, Yoshida K, Takeda S et al. Activation and localization of matrix metalloproteinase-2 and -9 in the skeletal muscle of the muscular dystrophy dog (CXMDJ). *BMC Musculoskelet Disord*. 2007 Jun 28; 8:54.
7. Choi YC, Dalakas MC. Expression of matrix metalloproteinases in the muscle of patients with inflammatory myopathies. *Neurology* 2000 Jan 11; 54(1): 65-71
8. Schoser BGH, Blottner D, Stuerenburg HJ. Matrix metalloproteinases in inflammatory myopathies: enhanced immunoreactivity near atrophic myofibers. *Acta Neurol Scand* 2002: 105: 309-13
9. Béhin A, Salort-Campana E, Wahbi K, Richard P, Carlier RY, Carlier P et al. Myofibrillar myopathies: State of the art, present and future challenges. *Rev Neurol (Paris)*. 2015 Oct; 171(10): 715-29
10. Ferrer I, Olivé M. Molecular pathology of myofibrillar myopathies. *Expert Rev Mol Med*. 2008; 10 Sep 3;10: e25. doi: 10.1017/S1462399408000793.
11. Rosner B. *Fundamentals of Biostatistics*. Boston. PWS Publishers. Second edition. 1986. 584pp.
12. Acharyya S, Villalta SA, Bakkar N, Bupha-Intr T, Janssen PM, Carathers M et al. Interplay of IKK/NF-kappaB signaling in macrophages and myofibers promotes muscle degeneration in Duchenne muscular dystrophy. *J. Clin. Invest*. 2007; 117, 889–901
13. Carlson BM, Faulkner JA. The regeneration of skeletal muscle fibers following injury: a review. *Med Sci Sports Exerc*. 1983; 15(3): 187-98.

Resumo

Introdução: Existem poucos relatos sugerindo que a expressão gênica e a ativação de várias metaloproteinases de matriz (MMPs) estão desreguladas. MMP-2 e MMP-9 representam as duas MMPs, que degradam o colágeno tipo IV, o componente da membrana basal.

Método: Analisamos o envolvimento das gelatinases, MMP-2 e MMP-9, na patogênese da miopatia miofibrilar (MFM). Amostras de músculos de 23 pacientes bem diagnosticados com MFM foram imunocoradas por MMP-2 e MMP-9. Analisamos qualitativamente a imunexpressão em três compartimentos: subsarcolemal (SSC), intracitoplasmático (ICC) e perinuclear (PNC).

Resultados: 95,7% e 100% das amostras apresentaram ICC de regulação positiva de MMP-2 e MMP-9, respectivamente. PNC mostrou regulação MMP-2 (82,6%) e MMP-9 (8,7%) ($p < 0,001$). SSC e ICC não apresentaram significância estatística. Não houve correlação entre o gene mutado e a distribuição do padrão imunohistoquímico.

Conclusão: Nossos resultados sugerem que MMP-2 e / ou MMP-9 podem participar do patomecanismo da MFM, causando dano ao sarcômero e deposição de agregados proteicos.

Palavras-chave: MMP-2, MMP-9, Miopatia miofibrilar, biópsia muscular, metaloproteinase.

©The authors (2022), this article is distributed under the terms of the Creative Commons Attribution 4.0 International License (<http://creativecommons.org/licenses/by/4.0/>), which permits unrestricted use, distribution, and reproduction in any medium, provided you give appropriate credit to the original author(s) and the source, provide a link to the Creative Commons license, and indicate if changes were made. The Creative Commons Public Domain Dedication waiver (<http://creativecommons.org/publicdomain/zero/1.0/>) applies to the data made available in this article, unless otherwise stated.