



# Postoperative Segmental Motion up to 1 Year Following Single-Level Anterior Cervical Discectomy and Fusion: Plate versus Non-plate

Kwang-Sup Song<sup>1</sup>, Jeongik Lee<sup>1</sup>, Dae Woong Ham<sup>1</sup>, Chan-Woo Jung<sup>1</sup>, Hyun Kang<sup>2</sup>, Seung Won Park<sup>3</sup>, Dong-Gune Chang<sup>4</sup>, Youngbae B. Kim<sup>5</sup>

<sup>1</sup>Department of Orthopaedic Surgery, Chung-Ang University Hospital, Chung-Ang University College of Medicine, Seoul, Korea

<sup>2</sup>Department of Anesthesiology and Pain Medicine, Chung-Ang University Hospital, Chung-Ang University College of Medicine, Seoul, Korea

<sup>3</sup>Department of Neurosurgery, Chung-Ang University Hospital, Chung-Ang University College of Medicine, Seoul, Korea

<sup>4</sup>Department of Orthopaedic Surgery, Inje University Sanggye Paik Hospital, College of Medicine, Inje University, Seoul, Korea

<sup>5</sup>Department of Orthopaedic Surgery, VHS Medical Center, Seoul, Korea

**Study Design:** Retrospective observational study.

**Purpose:** This study aimed to investigate the impact of plating on postoperative serial segmental motion and its correlation with clinical outcomes in single-level anterior cervical discectomy and fusion (ACDF) for up to 1 year.

**Overview of Literature:** The advantages and disadvantages of using cervical plating in ACDF have been well discussed; however, few studies compared the early serial segmental motions at the postoperative level between plating and non-plating.

**Methods:** In retrospectively collected data, 149 patients who underwent single-level ACDF for degenerative disease were enrolled and divided into non-plating (n=66) and plating (n=83). Interspinous motion (ISM) at the arthrodesis segment, Numeric Rating Scale (NRS) for neck pain, and Neck Disability Index (NDI) were serially evaluated at 3, 6, and 12 months postoperatively. Predictable factors for fusion, including age, sex, plating, diabetes, smoking, and type of grafts, were investigated, and fusion was defined as ISM <1 mm.

**Results:** In both groups, ISM was the highest at 3 months and gradually decreased thereafter, and the plating group showed significantly lower serial ISM than the non-plating group at 12 months. The plating group had lower NRS and NDI scores than the non-plating group at 12 months, and the difference in the NRS scores was statistically significant, particularly at 3 and 6 months, although that of the NDI scores was not. In a multivariate analysis, plating was the most powerful predictor for fusion.

**Conclusions:** Plating significantly decreases the serial ISM compared with non-plating in single-level ACDF, and such decreased motion is correlated with decreased neck pain until 12 months postoperatively, particularly at 3 and 6 months. Given that plating was the most predictive factor for fusion, we recommend plating even in single-level ACDF for better early clinical outcomes.

**Keywords:** Cervical vertebrae; Plate; Anterior cervical discectomy fusion; Interspinous motion; Patient reported outcomes

## Introduction

Stability support is a significant index of surgical out-

comes in anterior cervical fusion surgeries. Anterior cervical plating, as well as well-fitted interbody grafts, has been a common augmentation procedure for ensuring

Received May 9, 2022; Revised Aug 5, 2022; Accepted Aug 30, 2022

Corresponding author: Kwang-Sup Song

Department of Orthopaedic Surgery, Chung-Ang University Hospital, Chung-Ang University College of Medicine, 102 Heukseok-ro, Dongjak-gu, Seoul 06973, Korea

Tel: +82-2-6299-1589, Fax: +82-2-822-2017, E-mail: [ksong70@cau.ac.kr](mailto:ksong70@cau.ac.kr)

stability at the operated segment [1]. Several studies have reported that plating has the advantages of decreased rates of pseudarthrosis, subsidence, and segmental kyphosis [1-4]; nevertheless, its drawbacks include higher incidences of dysphagia and adjacent segment disease (ASD) than those observed with cage and graft-alone procedures [5-7].

Some studies have reported that stand-alone anterior cervical discectomy and fusion (ACDF) was sufficiently effective for inducing fusion and have demonstrated similar fusion rates, even in multi-level cervical segments [5-16]. Moreover, reports of postoperative disadvantages associated with the presence of an anterior plate suggest that its routine use is not beneficial [17].

In terms of defining the fusion status, various fusion criteria and time points have been used, and the evaluation methods frequently differ as well [6,10]. Such inconsistencies make the comparison of published results regarding fusion status challenging and determining differences in various surgical options impossible. One of the anterior cervical fusion criteria, measuring differences in interspinous motion (ISM) on flexion and extension dynamic radiographs, is affordable in terms of cost and accuracy and is a reasonable screening tool to detect pseudarthrosis [18]. Furthermore, the ISM method has an advantage in that it can demonstrate serial changes in the degree of motion in the operated segment for some period before the time point of determining fusion. To the best of our knowledge, few studies have compared the postoperative segmental motion in the arthrodesis level from early postoperative periods to investigate the role of plating.

This study aimed to investigate the differences in post-

operative serial segmental motion using ISM and clinical outcomes between plating and non-plating groups until 1 year postoperatively in patients who underwent single-level ACDF.

## Materials and Methods

### 1. Participants

This retrospective cohort study was approved by the institutional review board of Chung-Ang University Hospital (No., C2014197). The requirement for informed consent from individual patients was omitted because of the retrospective design of this study. Consecutive 221 patients who underwent single-level ACDF from C3-4 to C6-7 at a single institute were evaluated by three spine surgeons from January 2008 to January 2018. All patients were instructed to wear a rigid neck collar for 6 weeks postoperatively. Among them, patients who underwent surgery for fractures (n=4) and infections (n=5) were excluded. Moreover, patients with unavailable serial postoperative dynamic radiographs at 3 and 6 months or 12 months postoperatively (n=37), those with ineffective dynamic radiographs (n=9), those with translation cervical plates (n=8), and those with locked cages (n=9) were excluded (Fig. 1). An ineffective dynamic radiograph was defined as one with <4 mm of ISM at the superjacent level, which means just above the operative level [18]. Finally, a total of 149 patients were enrolled and divided into the following two groups: group I patients, who underwent single-level ACDF without plating, polyetheretherketone (PEEK)

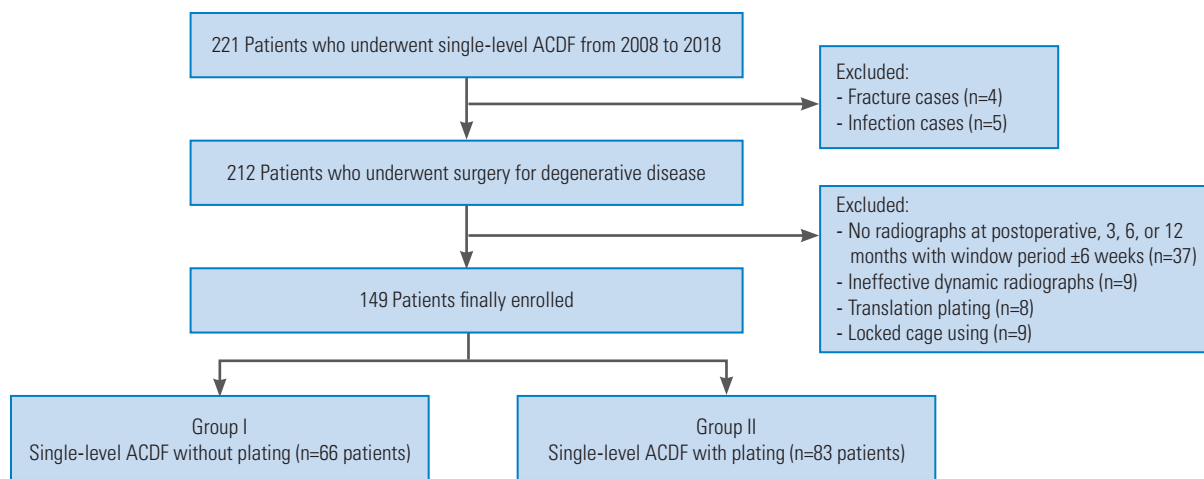


Fig. 1. Flowchart of patient enrollment. ACDF, anterior cervical discectomy and fusion.

cage, or graft-alone, and group II patients, who underwent single-level ACDF with plating.

## 2. Evaluation methods

Age, sex, diabetes, smoking, diagnoses, clinical scores, and types of grafts and implants for arthrodesis were reviewed from the medical records. Diagnoses included disc disease, stenosis, and ossification of the posterior longitudinal ligament. The interbody spacers used were divided into three categories, including PEEK cage, allo-cortical graft, and auto-cortical graft. Based on the type of bone graft used in the PEEK cage void, participants with PEEK cages were further divided into the following two subgroups: allograft (demineralized bone matrix) or autograft (harvested iliac bone). The Numeric Rating Scale (NRS) for neck pain and neck disability index (NDI) were recorded at 3-, 6-, and 12-month follow-up visits.

Differences in ISM between flexion and extension lateral cervical radiographs were measured on one monitor, displaying the two radiographs simultaneously. The most identifiable landmark around the spinous process tips on flexion and extension views at the arthrodesis segment was chosen at 150% magnification, and <1 mm of ISM at postoperative 12 months was defined as fusion [18]. Radiographic measurements were independently performed by two spine surgeons (14 and 2 years of experience) at two different time points over 4-week intervals. The data used were the average of all measured values.

## 3. Statistics

The Kolmogorov-Smirnov test and Q-Q plots were used to test for the normality of variables. NRS and NDI did not pass the Kolmogorov-Smirnov test; however, they did not show marked deviation from linearity on the Q-Q plot. Therefore, normality assumptions were applied to the linear mixed-effects model (LMEM). Natural log transformations of the ISM were performed because the ISM did not pass the Kolmogorov-Smirnov test and showed deviation from linearity on the Q-Q plot, and these values passed the Kolmogorov-Smirnov test. Differences in NRS, NDI, and natural log-transformed ISM were analyzed using LMEM, which were made using times (preoperatively and 3, 6, and 12 months postoperatively) and groups (I and II) as independent fixed factors and individual patients as random effects.

To compare ISM at each time point, t-test using Bonferroni correction ( $\alpha=0.05/4=0.0125$  or  $\alpha=0.05/3=0.0167$ ) was used. Multiple logistic regression was used to identify predictive factors for cervical fusion. The multi-collinearity diagnostic indicated no multi-collinearity issues (condition indices <30; variance inflation factor values <10) between the chosen independent variables. Age, sex, and factors that had univariate p-values of <0.1 were included for multivariate analysis. Data were expressed as median (P25–P75), odds ratio (OR, 95% confidence interval [95% CI]), or absolute number (%). Data in the figures were presented as mean±standard error. The inter-observer reliability of the measurements was evaluated using interclass correlation coefficients and 95% CI. All p-values <0.05 were considered statistically significant. All statistical analyses were performed using IBM SPSS ver. 23.0 (IBM Corp., Armonk, NY, USA).

## Results

Demographic data are shown in Table 1. No significant differences between the groups regarding age, sex, history of diabetes, current smoking, diagnoses, or operative levels were noted. Regarding ISM measurement, intra-rater reliability were 0.836 (95% CI, 0.739–0.912) and 0.833 (95%

**Table 1.** Demographic data

Variable	Group I (non-plating)	Group II (plating)
Age (yr)	53.3 (26–77)	51.3 (29–59)
Sex		
Male	32	53
Female	34	30
Smoking	16	29
Diabetes	11	18
Diagnosis		
Herniation of intervertebral disc	42	56
Stenosis	24	22
Ossification of posterior longitudinal ligament	0	5
Operative levels		
C3–4	2	7
C4–5	8	17
C5–6	42	40
C6–7	14	19

Values are presented as mean (range) or number.

CI, 0.737–0.898) and inter-rater value was 0.795 (95% CI, 0.635–0.879). Reliability values were in the excellent range.

**1. Serial changes in segmental motion at 12 months**

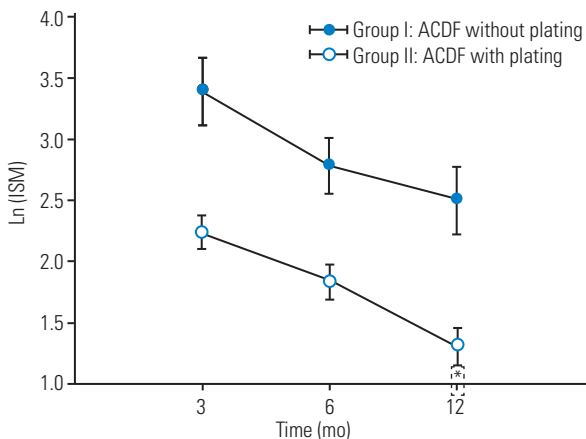
In both groups, Ln (ISM) was the highest at 3 months postoperatively and gradually decreased until 12 months postoperatively. Group II had significantly lower Ln (ISM) values than group I (estimated difference in means [MD], -0.63 [-1.08 to -0.17];  $p=0.007$ ) at 12 months.

In comparison at each follow-up period, group II had significantly lower Ln (ISM) values than group I in all time points (3, 6, and 12 months postoperatively) (Fig. 2). The fusion rates of the non-plating and plating groups, defined as <1 mm of ISM at 12 months postoperatively, were 35% and 64%, respectively.

**2. Serial changes in clinical outcomes at 12 months**

In both groups, the NRS and NDI scores gradually decreased until 12 months postoperatively. The NRS scores in group II were significantly lower than those in group I (MD, -0.34 [-0.64 to -0.04];  $p=0.028$ ); however, no evidence of a difference in the NDI scores between groups I and II (MD, -1.02 [-2.78 to -0.75];  $p=0.258$ ) at 12 months was noted (Figs. 3, 4).

In comparison at each follow-up period, group II had significantly lower NRS scores than group I at 3 and 6 months postoperatively; however, no significant difference in the NRS scores at 12 months postoperatively was noted. No evidence of difference in the NDI scores between

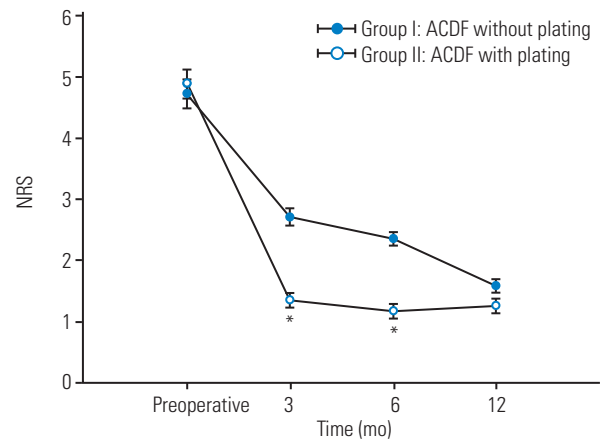


**Fig. 2.** Serial change of Ln (interspinous motion [ISM]) between the groups during 12 months postoperatively. \* $p<0.05$  compared with group I. ACDF, anterior cervical discectomy and fusion.

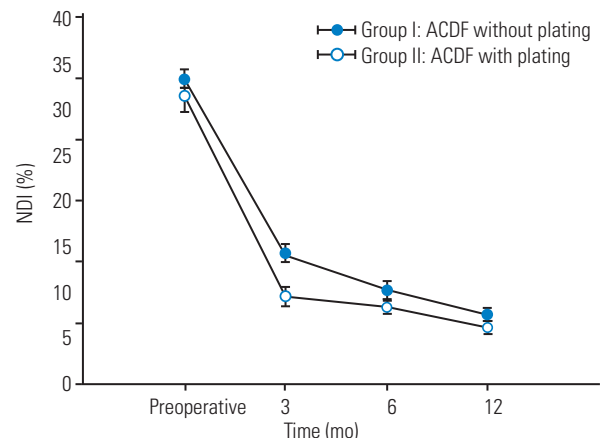
groups I and II at each time point was noted (Figs. 3, 4).

**3. Predictive factors for the fusion**

Uni- and multivariate analyses of predictive factors for fusion at 12 months postoperatively are presented in Table 2. In univariate analysis, age, sex, diabetes, and smoking were insignificant; however, anterior plating and graft type showed powerful predictive values. Anterior plating showed a significant OR of 4.16 for fusion ( $p<0.001$ ). Both allo-cortical (OR, 2.53;  $p=0.022$ ) and auto-cortical grafts (OR, 2.23;  $p=0.046$ ) showed statistical superiority compared with PEEK cage. In multivariate analysis, only anterior plating was a significant predictive factor for fusion (OR, 3.543;  $p=0.001$ ). In 97 participants using PEEK cage, anterior plating was also a powerful predictive factor for fusion (univariate: OR, 3.305;  $p=0.002$ ; multivariate:



**Fig. 3.** Serial change of the Numeric Rating Scale (NRS) between the groups at 12 months postoperatively. \* $p<0.05$  compared with group I. ACDF, anterior cervical discectomy and fusion.



**Fig. 4.** Serial change of the Neck Disability Index (NDI) between the groups at 12 months postoperatively. ACDF, anterior cervical discectomy and fusion.

OR, 2.795;  $p=0.070$ ). Based on bone material type used in the void of PEEK cages, autograft was a more influential factor for fusion than allograft (univariate: OR, 2.540;  $p=0.010$ ; multivariate: OR, 1.164;  $p=0.662$ ) (Table 3).

## Discussion

Our results revealed that the plating group in single-level ACDF demonstrated not only significantly lower serial ISM but also lower NRS scores for neck pain than the non-plating group at 12 months postoperatively; however, no significant differences for NDI scores were noted. Regarding each follow-up time point, the differences in clinical outcomes were observed only at 3 and 6 months for NRS. These results suggest that such larger postopera-

tive sustained motion at the operated segment adversely affects postoperative neck pain, particularly until postoperative 6 months.

If surgical outcomes between the two groups were compared at only 12 months postoperatively, as in most other studies, our results demonstrated no differences as well. Although the different result is due to different evaluation time points, we believe that comparing these sequential effects for 12 months postoperatively using LMEM may be more meaningful to demonstrate the actual differences between the groups (Fig. 5).

ACDF is a successful surgical procedure with good clinical results and a high fusion rate [19]. Stand-alone ACDF causes less damage to adjacent structures and is associated with shorter operating times and blood loss than plating

**Table 2.** Uni- and multivariate analysis for fusion at postoperative 12 months

Variable	Univariate		Multivariate	
	OR (95% CI)	<i>p</i> -value	OR (95% CI)	<i>p</i> -value
Age	0.977 (0.944–1.001)	0.282	0.963 (0.938–0.998)	0.214
Gender	1.160 (0.613–2.157)	0.380	1.024 (0.533–1.967)	0.938
Plating	4.164 (2.108–8.889)	<0.001*	3.543 (1.607–7.484)	0.001*
Diabetes	0.858 (0.427–1.731)	0.675		
Smoking	1.002 (0.553–1.818)	0.994		
Graft				
Cage (n=97)	1		1	
Allo-cortical graft (n=31)	2.532 (1.002–6.425)	0.022*	1.784 (0.679–4.892)	0.178
Auto-cortical graft (n=19)	2.226 (0.984–4.314)	0.046*	1.542 (0.627–3.271)	0.450

OR, odds ratio; CI, confidence interval.

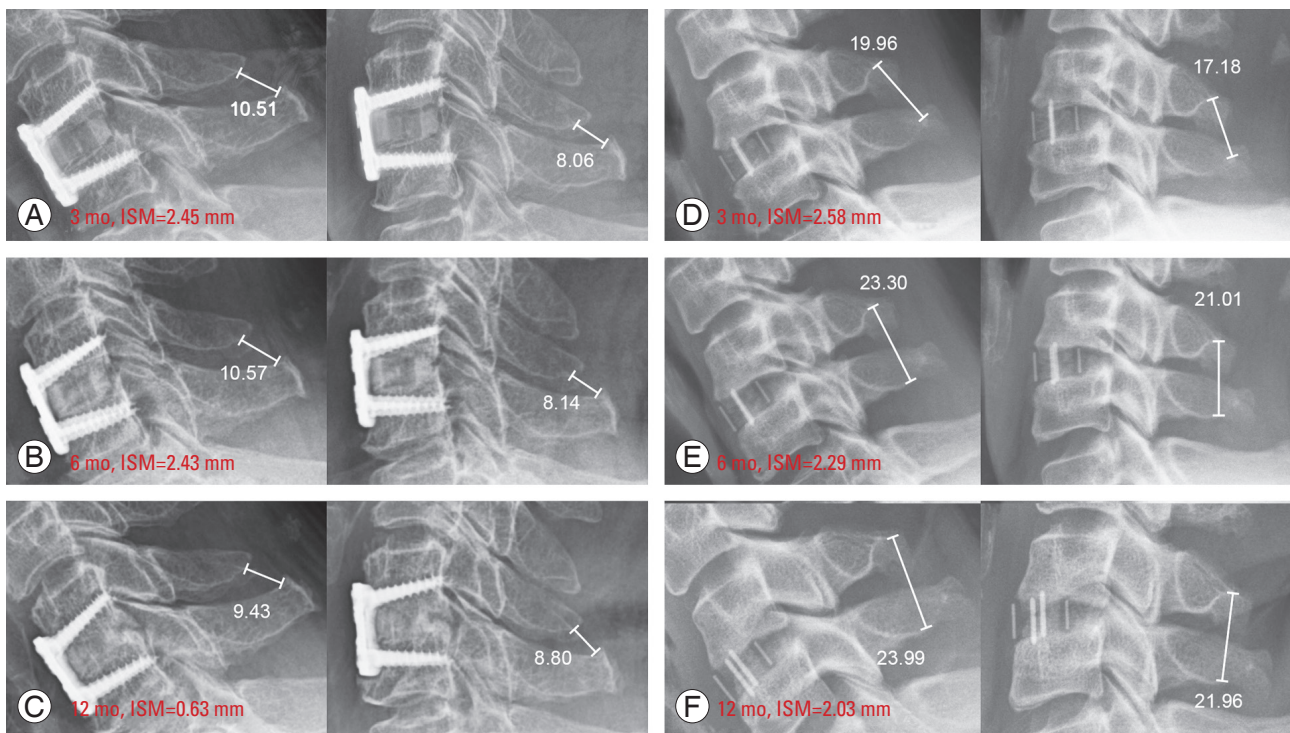
\* $p<0.05$ .

**Table 3.** Uni- and multivariate analysis for fusion at postoperative 12 months in 97 subjects with cage

Variable	Univariate		Multivariate	
	OR (95% CI)	<i>p</i> -value	OR (95% CI)	<i>p</i> -value
Age	1.005 (0.988–1.120)	0.820	0.998 (0.966–1.032)	0.752
Gender	1.172 (0.498–2.535)	0.370	1.032 (0.437–2.376)	0.891
Plating	3.305 (1.554–6.962)	0.002*	2.795 (0.902–8.324)	0.070
Diabetes	0.724 (0.328–1.846)	0.408		
Smoking	0.920 (0.434–1.932)	0.846		
Graft in void of cage				
Cage+allograft (n=67)	1		1	
Cage+autograft (n=30)	2.540 (1.149–5.426)	0.010*	1.164 (0.364–3.894)	0.662

OR, odds ratio; CI, confidence interval.

\* $p<0.05$ .



**Fig. 5.** Representative postoperative serial radiographs for both groups. (A–C) A 66-year-old female patient who underwent C5–6 single-level anterior cervical discectomy and fusion (ACDF) with plating. The interspinous motion (ISM) gradually decreased from postoperative 3-month to 12 months. The ISM gradually decreased from 3 to 12 months after surgery and showed less than 1 mm in the last follow-up. (D–F) A 42-year-old male patient who underwent C5–6 single-level ACDF without plating. The postoperative 12-month ISM was 2.03 mm and considered a failure to achieve fusion.

[1,10]. Several studies have reported comparative fusion rates between plating and non-plating [6–14]; however, the debate is currently ongoing. In this study, the impact of plating on suppressing segmental motion from the early postoperative period was not only correlated with better neck pain score but also resulted in a higher fusion rate (plating: 64% versus non-plating: 35%). Remarkably, in this study, the fusion rates in both groups were relatively 20%–30% lower than those reported in previous studies [1,10]. Our suggested fusion criterion, ISM <1 mm, may be considered stringent versus an ISM of 2 mm. However, careful determination of landmarks on radiographs at 150% magnification could overcome the measurement concerns and may be a tool to distinguish the overlooked difference [18].

Contrary to our findings, previous studies have reported similar fusion rates between plating and non-plating. Some studies did not provide details regarding how to define fusion; moreover, the time points of determining fusion varied from 3 months to several years postoperatively. It is debatable whether determination of radiographic fusion within 6 months is reasonable [17,20] using only bridging bone patterns on plain radiographs

[8,11,13,14,16].

When evaluating graft materials as predictive factors for fusion, the PEEK cage was inferior to allo-cortical allografts (OR, 1.784) and auto-cortical grafts (OR, 1.542). Both strut grafts have better biocompatibility than PEEK cage [21]. Although auto-cortical grafts have better osteogenic potential, allo-cortical grafts provide initial strength for supporting the anterior column [22]. On analyzing the effects of different materials in the PEEK cage void, we found that the autograft showed higher OR than the allograft (Table 3).

Dysphagia and ASD are the major concerns of anterior plating over stand-alone ACDF [10]. Although higher incidences of dysphagia related to the presence of plating have been reported, several reports have also demonstrated no significant differences in the incidence of dysphagia; the mechanism of dysphagia itself is also unclear [4,23]. Furthermore, ASD is influenced by the surgical technique, graft materials, amount of fusion level, alignment, and individual lifestyle [9]. The main reason for higher ASD related to the presence of plating could be the proximity or surgical insult to an adjacent segment, both of which

are related to the surgical technique and appear to be preventable. Furthermore, stand-alone ACDF is associated with more subsidence and loss of cervical lordosis than anterior plating ACDF [1,24]. These adverse effects could affect the progression of ASD.

This study had some limitations, particularly in terms of its retrospective design. First, a large proportion of participants was excluded due to mainly unavailable serial follow-up radiographs (37/186); however, a similar lost proportion of plating (15/81, 18%) and non-plating (22/105, 20%) in single-level ACDF patients may reduce some selection bias. Second, postoperative 12 months was relatively short to evaluate the long-term effects of plating, including ASD and the revision rate, and it could be early to determine the fusion status. Further fusion progression after 1 year can occur, and the possibility that our fusion rate increase cannot be excluded. Third, ISM fusion criteria demonstrated functional stability and not anatomic radiographic bony fusion. It may be difficult to directly compare the fusion rate with that of other studies due to the absence of data on the evaluation of anatomic bridging bone in this study. However, our study aimed to evaluate the differences in the changes of serial segmental motions and clinical outcomes from early postoperative periods between plating and non-plating in single-level ACDF, and there is a consensus that 1-year follow-up period is sufficient to determine fusion [25]. Fourth, the result of postoperative dysphagia comparing plate and cage-alone groups could not be presented due to a lack of dysphagia evaluation data.

## Conclusions

Considerable sustained motion at arthrodesis segments was observed at early postoperative periods, which gradually decreased in both the plating and non-plating single-level ACDF groups. However, compared with non-plating in single-level ACDF, plating significantly decreased the serial segmental motion, and such decreased motion was closely correlated with decreased neck pain at 12 months postoperatively, particularly at 3 and 6 months. Given that plating was the most predictive factor for fusion, we recommend anterior plating even in single-level ACDF for better early clinical outcomes.

## Conflict of Interest

No potential conflict of interest relevant to this article was reported.

## ORCID

Kwang-Sup Song: <https://orcid.org/0000-0002-9238-8908>

Jeongik Lee: <https://orcid.org/0000-0002-3071-259X>

Dae Woong Ham: <https://orcid.org/0000-0003-4278-2701>

Chan-Woo Jung: <https://orcid.org/0000-0003-0570-160X>

Hyun Kang: <https://orcid.org/0000-0003-2844-5880>

Seung Won Park: <https://orcid.org/0000-0001-8305-7501>

Dong-Gune Chang: <https://orcid.org/0000-0001-6731-1063>

Youngbae B. Kim: <https://orcid.org/0000-0003-3966-0949>

## Author Contributions

Conceptualization: KSS; data curation: CWJ, JL, SWP; formal analysis: HK, YBK, KSS; visualization: YBK, DG C, DWH; writing—original draft: KSS; writing—review & editing: KSS.

## References

1. Oliver JD, Goncalves S, Kerezoudis P, et al. Comparison of outcomes for anterior cervical discectomy and fusion with and without anterior plate fixation: a systematic review and meta-analysis. *Spine (Phila Pa 1976)* 2018;43:E413-22.
2. Yu J, Ha Y, Shin JJ, et al. Influence of plate fixation on cervical height and alignment after one- or two-level anterior cervical discectomy and fusion. *Br J Neurosurg* 2018;32:188-95.
3. Kim CH, Chung CK, Hahn S. Autologous iliac bone graft with anterior plating is advantageous over the stand-alone cage for segmental lordosis in single-level cervical disc disease. *Neurosurgery* 2013;72:257-66.
4. Song KJ, Taghavi CE, Lee KB, Song JH, Eun JP. The efficacy of plate construct augmentation versus cage alone in anterior cervical fusion. *Spine (Phila Pa 1976)* 2009;34:2886-92.
5. Wang YP, Zhang W, An JL, Lian LC, Zhang J, Sun YP. A comparative study for the usage of Fidji cervical cages after multilevel anterior cervical discectomy and fusion. *Injury* 2019;50:908-12.
6. Panchal RR, Kim KD, Eastlack R, et al. A clinical

- comparison of anterior cervical plates versus stand-alone intervertebral fusion devices for single-level anterior cervical discectomy and fusion procedures. *World Neurosurg* 2017;99:630-7.
7. Overley SC, Merrill RK, Leven DM, Meaike JJ, Kumar A, Qureshi SA. A matched cohort analysis comparing stand-alone cages and anterior cervical plates used for anterior cervical discectomy and fusion. *Global Spine J* 2017;7:394-9.
  8. Ng EP, Yip AS, Wan KH, et al. Stand-alone cervical cages in 2-level anterior interbody fusion in cervical spondylotic myelopathy: results from a minimum 2-year follow-up. *Asian Spine J* 2019;13:225-32.
  9. Burkhardt BW, Brielmaier M, Schwerdtfeger K, Oertel JM. Clinical outcome following anterior cervical discectomy and fusion with and without anterior cervical plating for the treatment of cervical disc herniation-a 25-year follow-up study. *Neurosurg Rev* 2018;41:473-82.
  10. Cheung ZB, Gidumal S, White S, et al. Comparison of anterior cervical discectomy and fusion with a stand-alone interbody cage versus a conventional cage-plate technique: a systematic review and meta-analysis. *Global Spine J* 2019;9:446-55.
  11. Kim SY, Yoon SH, Kim D, Oh CH, Oh S. A prospective study with cage-only or cage-with-plate fixation in anterior cervical discectomy and interbody fusion of one and two levels. *J Korean Neurosurg Soc* 2017;60:691-700.
  12. Baker JF, Gomez J, Shenoy K, Kim S, Razi A, Kim Y. A radiographic follow-up study of stand-alone-cage and graft-plate constructs for single-level anterior cervical discectomy and fusion. *J Spine Surg* 2017;3:596-600.
  13. Ji GY, Oh CH, Shin DA, et al. Stand-alone cervical cages versus anterior cervical plates in 2-level cervical anterior interbody fusion patients: analysis of adjacent segment degeneration. *J Spinal Disord Tech* 2015;28:E433-8.
  14. Hwang SL, Lin CL, Lieu AS, et al. Three-level and four-level anterior cervical discectomies and titanium cage-augmented fusion with and without plate fixation. *J Neurosurg Spine* 2004;1:160-7.
  15. Alhashash M, Allouch H, Boehm H, Shousha M. Results of four-level anterior cervical discectomy and fusion using stand-alone interbody titanium cages. *Asian Spine J* 2022;16:82-91.
  16. Fujibayashi S, Takemoto M, Nakamura T, et al. Stand-alone anterior cervical discectomy and fusion using an additive manufactured individualized bioactive porous titanium implant without bone graft: results of a prospective clinical trial. *Asian Spine J* 2021;15:373-80.
  17. Joo YH, Lee JW, Kwon KY, Rhee JJ, Lee HK. Comparison of fusion with cage alone and plate instrumentation in two-level cervical degenerative disease. *J Korean Neurosurg Soc* 2010;48:342-6.
  18. Song KS, Piyaskulkaew C, Chuntarapas T, et al. Dynamic radiographic criteria for detecting pseudarthrosis following anterior cervical arthrodesis. *J Bone Joint Surg Am* 2014;96:557-63.
  19. Karikari IO, Jain D, Owens TR, et al. Impact of subsidence on clinical outcomes and radiographic fusion rates in anterior cervical discectomy and fusion: a systematic review. *J Spinal Disord Tech* 2014;27:1-10.
  20. Yang S, Yu Y, Liu X, et al. Clinical and radiological results comparison of allograft and polyetheretherketone cage for one to two-level anterior cervical discectomy and fusion: a CONSORT-compliant article. *Medicine (Baltimore)* 2019;98:e17935.
  21. Song KS, Chaiwat P, Kim HJ, Mesfin A, Park SM, Riew KD. Anterior cervical fusion assessment using reconstructed computed tomographic scans: surgical confirmation of 254 segments. *Spine (Phila Pa 1976)* 2013;38:2171-7.
  22. Lee JC, Jang HD, Ahn J, Choi SW, Kang D, Shin BJ. Comparison of cortical ring allograft and plate fixation with autologous iliac bone graft for anterior cervical discectomy and fusion. *Asian Spine J* 2019;13:258-64.
  23. Shi S, Liu ZD, Li XF, Qian L, Zhong GB, Chen FJ. Comparison of plate-cage construct and stand-alone anchored spacer in the surgical treatment of three-level cervical spondylotic myelopathy: a preliminary clinical study. *Spine J* 2015;15:1973-80.
  24. Yang JJ, Yu CH, Chang BS, Yeom JS, Lee JH, Lee CK. Subsidence and nonunion after anterior cervical interbody fusion using a stand-alone polyetheretherketone (PEEK) cage. *Clin Orthop Surg* 2011;3:16-23.
  25. Buchowski JM, Liu G, Bunmaprasert T, Rose PS, Riew KD. Anterior cervical fusion assessment: surgical exploration versus radiographic evaluation. *Spine (Phila Pa 1976)* 2008;33:1185-91.