



COVID-19 associated mucormycosis at territory care hospital in South India - A retrospective study

Sambit Sahu^{1*}, Pratik Patil¹, Seema M Gafurjiwala², Manas Panigrahi¹, Yashaswini Kumar² and Nirupama AY²

¹Krishna Institute of Medical Sciences, Minister Road, Secunderabad-500003, Telangana, India

²Indian Institute of Public Health Hyderabad, Sy. No. 384, Premavathipet Village, Rajendranagar Mandal, RR. District, Hyderabad, Telangana-500030, India

Abstract

Background: Globally, several cases of mucormycosis have been diagnosed in patients with COVID-19, and the entity is described as COVID-19-associated mucormycosis (CAM). CAM is an emerging problem necessitating increased vigilance in COVID-19 patients, even those who have recovered. The objective was to study this cluster of cases admitted to KIMS Hospital to study the characteristics of the patients, co-morbidities, and intervention for the care.

Methods: Retrospectively reviewed EMR (Electronic Medical record) at KIMS Hospitals Secunderabad from March 2021 to October 2021. Case identification was based on the global guideline for the diagnosis and management of mucormycosis. For all cases, reverse transcription PCR (RT-PCR) result for severe acute respiratory syndrome coronavirus 2 (SARS-CoV-2), which was routinely obtained on admission, the history, the clinical presentation and course, and the radiological findings were recorded. We examined clinical features, surgical treatment approaches, medical management and type of drug used and outcomes of each case.

Results: In total 80% of case were male and all patients had an average duration of hospitalization for a week. The outcome of the Intervention at KIMS Hospital was 90.8% survival with sequelae followed by regular visit to hospital for antifungal treatment.

Conclusion: In our study we found that there was a strong association between the treatment outcome and co-morbidities (χ^2 value=14.8, p-value<0.05). Improved outcome was possible because of early aggressive approach and involvement of multidisciplinary team.

Keywords: COVID-19; India; mucormycosis; CAM; severe acute respiratory syndrome coronavirus 2; SARS-CoV-2

Introduction

COVID-19-associated rhino-orbital-cerebral mucormycosis (CAROCM) is the most common type observed during the COVID-19 pandemic, followed by the pulmonary form [1]. Rhinocerebral mucormycosis, also called zygomycosis is caused by filamentous fungi, involving the nose, paranasal sinuses, and brain. It is an opportunistic infection found commonly in immunocompromised individuals as the fungus grows rapidly and aggressively causing a well-defined fulminant and life-threatening disease. Early diagnosis and appropriate treatment are very crucial to save lives and prevent permanent neurological complications. Most of the cases have acute onset but chronic presentations are indolent and slowly progressive, occurring over several weeks [2].

The common risk factors include uncontrolled diabetic ketoacidosis, severe burns, solid organ transplantation, corticosteroid therapy, hemochromatosis, patients with HIV, neutropenia, malnutrition, and hematologic

***Corresponding author:** Dr. Sambit Sahu, Department of Critical and Intensive Care, Krishna Institute of Medical Sciences, Minister Road, Secunderabad-500003, Telangana, India. Email: drsambit@kimshospitals.com

Received 1 December 2022; Revised 2 March 2023; Accepted 9 March 2023;
Published 17 March 2023

Citation: Sahu S, Patil P, Gafurjiwala SM, Panigrahi M, Kumar Y, Nirupama AY. COVID-19 associated mucormycosis at territory care hospital in South India - A retrospective study. J Med Sci Res. 2023; 11(2):154-157. DOI: <http://dx.doi.org/10.17727/JMSR.2023/11-29>

Copyright: © 2023 Sahu S et al. Published by KIMS Foundation and Research Center. This is an open-access article distributed under the terms of the Creative Commons Attribution License, which permits unrestricted use, distribution, and reproduction in any medium, provided the original author and source are credited.

malignancies [3]. Evidence also showed that nine percentage of Rhinocerebral mucormycosis was found in patients without any predisposing factors [4].

Globally, the prevalence of mucormycosis varied from 0.005 to 1.7 per million populations. It was almost 80 times higher (0.14 per 1000) in India compared to that in the developed countries as per the data for the year 2019-2020. India alone has contributed to 71% of the total global cases. The disease emerged as a new imminent threat even as the COVID-19 pandemic continued to be a reality. Mucormycosis has a global mortality rate of 46% [5].

Globally, several cases of mucormycosis have been diagnosed in patients with COVID-19, and the entity is described as COVID-19-associated mucormycosis (CAM). Although a causal link between COVID-19 and mucormycosis remains unearthed, multiple factors including glucocorticoids, worsening of blood glucose control, and viral-induced lymphopenia have been implicated in the development of mucormycosis in patients with COVID-19. CAM is an emerging problem necessitating increased vigilance in COVID-19 patients, even those who have recovered [6].

We therefore studied this cluster of cases admitted to KIMS Hospital to study the characteristics of the patients, co-morbidities, and intervention for the care. The objective was to describe the characteristics of the COVID-19 associated mucormycosis cases in a tertiary care center during the year 2021.

Methods

We retrospectively reviewed EMR (Electronic Medical record) with ICD-code B46.1 which is rhinocerebral mucormycosis to identify cases that reported to KIMS Hospitals Secunderabad from March 2021 to October 2021. Case identification was based on the global guidelines for the diagnosis and management of mucormycosis [7], which includes patients presenting with symptoms of periorbital oedema, nasal crusting, diplopia, decreased vision, headache and facial abnormality; radiological evidence of bone destruction and orbit/brain infiltration and tissue biopsy with pathological evidence of tissue invasion, vessel occlusion, and non-pigmented non-/pauci-septate hyphae with variable width (6–16µm) or the same typical fungal growth in microbiological culture.

For all cases, the reverse transcription - polymerase chain (RT-PCR) result for severe acute respiratory syndrome coronavirus 2 (SARS-CoV-2), which was routinely obtained on admission, history, the clinical presentation and course, and the radiological findings

were recorded. We examined clinical features, surgical plan, and medical management and outcomes of each case.

All the secondary data from the hospital records entered into a database and then transferred to STATA version 14 for analysis. Descriptive statistics presented in frequency and percentage for categorical data and for continuous data mean with standard deviation. Bivariate analysis was performed using chi-square test with 5% level of significance and p value was reported. The work was approved by the ethical committee of KIMS Hospital, with written informed consents obtained from patients.

Results

A total of one hundred twenty (120) cases were diagnosed with rhino cerebral mucormycosis at KIMS Hospital, Secunderabad from March 2021 to October 2021. Out of 120 cases, 97 were males and 23 female patients. The average hospital stay at KIMS Hospital was 7 days.

Table 1: Characteristics of the Patients diagnosed with rhinocerebral mucormycosis.

Cases	Category	Total (N=120) f (%)
Age* (Years)		51.8(11.9)
Gender	Male	97(80.1)
	Female	23(19.9)
Hospital stay (Days)**		7(4,12)

Note: * Mean with SD; ** Median (Interquartile range).

Table 2: Age wise gender distribution of the patients.

Age group	Gender	
	Male, n(%)	Female, n(%)
21-30	6(6.2)	0(0)
31-40	15(15.5)	1(4.4)
41-50	28(28.9)	5(21.7)
51-60	26(26.8)	9(39.1)
61-70	19(19.6)	6(26.1)
71-80	3(3.1)	2(8.7)

As shown in figure-1, patients who presented with signs and symptoms of rhinocerebral mucormycosis, 58(48%) patients had diabetes mellitus on regular medication while in 42(35%) cases, there was no history of any co-morbidities.

The most common clinical presentations of the cases of mucormycosis were periorbital oedema, nasal

blockage/crusting, diplopia and nasal bleeding had shown in Table 3.

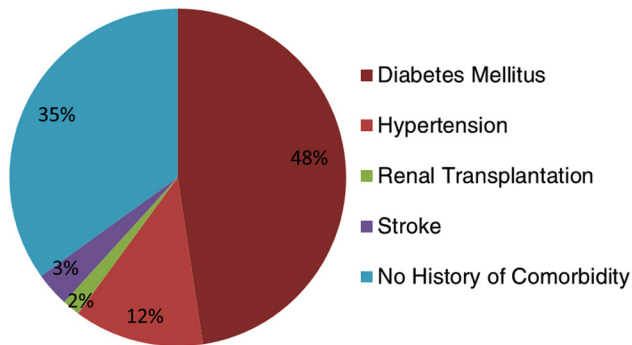


Figure 1: Types of co-morbidities.

Table 3: Clinical sign and symptoms at the time of presentation.

Sign and symptom	n	%
Periorbital oedema	71	59
Nasal blockage/crusting	55	46
Diplopia	36	30
Nasal bleeding	33	27
Facial abnormality	24	20
Headache	18	15
Decreased vision	12	10
Blood stained discharge	6	5

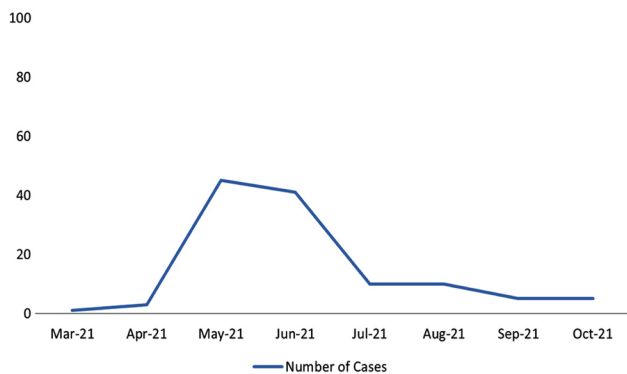


Figure 2: Month-wise distribution of cases. *As shown figure-II more than half of the total cases came in May and June 2021 (The second wave of COVID-19), and peaked in the month of May 2021.

Table 4: Treatment for post COVID-19 mucormycosis.

Types of medicine for treatment	n	%
Amphotericin (conventional)	24	20
Amphotericin (liposomal)	70	58.3
Both forms of amphotericin	12	10.0
Parenteral posaconazole	1	0.8
Oral posaconazole	11	9.2
Both forms of posaconazole	2	1.7

101(84.2%) cases underwent surgical intervention with medication whereas 19(15.2%) cases underwent only medical treatment and did not give consent for surgical intervention. The outcomes of intervention at KIMS Hospital were 109(90.8%) survival with sequelae with follow up visits to the hospital for antifungal treatment.

Discussion

In the current study, a total of 120 cases were diagnosed with CAM and it was found that 80% of the patients were male, indicating that males are at higher risk than females. 28.9% of the male patients of age group 41–50 years followed by 26.8% were of age group 51–60 years. Mucormycosis was predominantly seen in males, both in people who were recovering from COVID-19 or were still active [8]. Patients involved in our study, the clinical signs and symptoms of mucormycosis varied with the involved organ. During the presentation, 59% of the patients had periorbital oedema, 46% patient had nasal crusting, 30% had diplopia and 27% had nasal bleeding. In these patients, MRI had the advantage of detecting early vascular and intracranial invasion. We found that patients with comorbidities especially diabetes mellitus, i.e., 48% were more prone for COVID-19 mucormycosis compared to any other comorbidity, which is in congruence with the study conducted by Singh et al, stating that diabetes mellitus type 2 is the most common predisposing factor accounting for 80% of case [9].

Three principles for successful treatment are early diagnosis, aggressive debridement and appropriate antifungal therapy: (1) Early diagnosis is greatly imperative and can enormously reduce the patient’s mortality, (2) Necrotic tissues debridement should be aggressively debrided or infected tissues should be resected and (3) Medical treatment with appropriate antifungal agents should be carried out at the earliest [1].

One of the previous study found that, systemic antifungal therapy includes the use of high-dose amphotericin B 5-10 mg/kg/day and is associated with an overall survival rate of 72% [9]. In the present study, 58.3% of cases were given liposomal amphotericin, and the other 20% of patients were given conventional amphotericin B.

Surgical interventions included functional endoscopic sinus surgery (FESS) with debridement, maxillectomy, cranioplasty, and debridement of the intracranial extent of disease, anterior cranial fossa carpeting, and orbital exenteration. Post-surgery the specimens were sent for histo-pathological and microbiological investigation.

Our study found that there was no statistically significant difference between gender and outcome of the treatment given at the hospital (χ^2 value=0.007, p value=0.9). We found that multiorgan failure was the most common complication for fatality. But in extensive disease, if required, repeated surgeries were necessary to treat. Because the fungus thrives in devitalized and necrotic tissue, and because ischaemic tissue is difficult for therapeutic agents to penetrate, debridement has been recommended, and in this setting 10% of cases had a revision of debridement. Drainage and debridement of paranasal sinuses, exenteration of necrotic orbital contents, palatectomy, and craniotomy have all been associated with a cure [10]. 36(33%) post-surgical cases visited hospital regularly for antifungal therapy for 6 months. Prognosis is mostly dependent on multiple factors like early diagnosis, age, history of comorbidity, and early initiation of treatment. A multidisciplinary approach consisting of dental specialists, ENT surgeons, ophthalmologists, infectious disease specialists, neurosurgeon, and neurologist is critical in the successful management of a patient with mucormycosis. Therefore the approach is to treat early, aggressively, and with all modalities available.

Conclusion

CAM is fungal infection that continues to carry significant morbidity and mortality. The primary drug of choice in managing patients with CAM is amphotericin B, preferably liposomal, followed by posaconazole. Management of mucormycosis is not complete without an effective debridement strategy which depends on the region involved. Follow up surgeries directed towards rehabilitation and reconstruction is major step to improve long-term outcome.

Improved outcome was possible because of early aggressive approach and involvement of multidisciplinary team.

Conflicts of interest

Authors declare no conflicts of interest.

References

- [1] Aranjanı JM, Manuel A, Razack HIA, Mathew ST. Covid-19-associated mucormycosis: Evidence-based critical review of an emerging infection burden during the pandemic's second wave in India. *PLoS Negl Trop Dis.* 2021; 15:1–21.
- [2] Harrill WC, Stewart MG, Lee AG, Cernoch P. Chronic rhinocerebral mucormycosis. *Laryngoscope.* 1996; 106:1292–1297.
- [3] Gonzalez CE, Couriel DR, Walsh TJ. Disseminated zygomycosis in a neutropenic patient: Successful treatment with amphotericin B lipid complex and granulocyte colony-stimulating factor. *Clin Infect Dis.* 1997; 24:192–196.
- [4] Elinav H, Zimhony O, Cohen MJ, Marcovich AL, Benenson S. Rhinocerebral mucormycosis in patients without predisposing medical conditions: A review of the literature. *Clin Microbiol Infect.* 2009; 15:693–697.

- [5] Chander J, Kaur M, Singla N, Punia RPS, Singhal SK, et al. Mucormycosis: Battle with the deadly enemy over a five-year period in India. *J Fungi.* 2018; 4:46.
- [6] Pal R, Singh B, Bhadada SK, Banerjee M, Bhogal RS et al. Mycoses - 2021 - Pal - COVID-19-associated mucormycosis An updated systematic review of literature. *Mycoses.* 2021; 64:1452–1459.
- [7] HHS Public Access. 2021; 19:1–34.
- [8] Kamath S, Kumar M, Sarkar N, Ahmed T, Sunder A. Study of profile of mucormycosis during the second wave of COVID-19 in a tertiary care hospital. *Cureus.* 2022; 14:1–22.
- [9] Singh AK, Singh R, Joshi SR, Misra A. Mucormycosis in COVID-19: A systematic review of cases reported worldwide and in India. *Diabetes Metab Syndr.* 2021; 15:102146.
- [10] Jiang N, Zhao G, Yang S, Lin J, Hu L, et al. A retrospective analysis of eleven cases of invasive rhino-orbito-cerebral mucormycosis presented with orbital apex syndrome initially. *BMC Ophthalmol.* 2016; 16:1–7.