



GUIDELINES

ISUOG Practice Guidelines (updated): fetal cardiac screening

Clinical Standards Committee

The International Society of Ultrasound in Obstetrics and Gynecology (ISUOG) is a scientific organization that encourages sound clinical practice and high-quality teaching and research related to diagnostic imaging in women's healthcare. The ISUOG Clinical Standards Committee (CSC) has a remit to develop Practice Guidelines and Consensus Statements as educational recommendations that provide healthcare practitioners with a consensus-based approach, from experts, for diagnostic imaging. They are intended to reflect what is considered by ISUOG to be the best practice at the time at which they are issued. Although ISUOG has made every effort to ensure that Guidelines are accurate when issued, neither the Society nor any of its employees or members accepts liability for the consequences of any inaccurate or misleading data, opinions or statements issued by the CSC. The ISUOG CSC documents are not intended to establish a legal standard of care, because interpretation of the evidence that underpins the Guidelines may be influenced by individual circumstances, local protocol and available resources. Approved Guidelines can be distributed freely with the permission of ISUOG (info@isuog.org).

INTRODUCTION

Effective fetal cardiac screening should maximize detection of structural anomalies and (according to available expertise and resources) abnormalities of function and rhythm, as part of routine prenatal care. This document provides recommendations for low-risk fetal cardiac ultrasound screening during the second trimester, updated from previously published Guidelines¹. The practical implementation of late first-trimester and early second-trimester cardiac screening, when technically feasible, is also considered. These Guidelines encourage the use of color flow Doppler ultrasound and introduce new sections on quality assurance and the use of a checklist (Appendix 1). Healthcare workers can also use these Guidelines to identify pregnancies at risk for genetic anomalies² and to provide timely guidance for patient counseling, obstetric management and multidisciplinary care. Cases with suspected heart anomalies and/or those at increased risk require fetal echocardiography^{3–6}.

Congenital heart disease (CHD) has a prevalence of 8.2 per 1000 live births and is a leading cause of infant morbidity and mortality⁷. Prenatal diagnosis can improve birth outcome prior to intervention⁸, particularly for certain types of cardiac lesion^{9–15}. Prenatal awareness of CHD and parental education allow preparation for the birth of a neonate that will require specialized care and services. The impact of prenatal diagnosis may also be relevant to long-term neurodevelopmental outcome^{16,17} and it maximizes options for the family. However, prenatal detection rates vary widely in different geographic regions and for various types of CHD, with fewer than one half of cardiac anomalies being identified before birth^{7,18,19}. Some variation can be attributed to differences in examiner ability, transducer frequency, patient body habitus, abdominal scars, gestational age, amniotic fluid volume and fetal position^{20–23}. Continuous feedback-based training of healthcare professionals, a low threshold for echocardiography referrals, use of standardized ultrasound protocols and easy access to fetal-heart specialists can improve the performance of a screening program^{14,24–26}.

Details of the grades of recommendation and levels of evidence used in ISUOG Guidelines are given in Appendix 2.

GENERAL CONSIDERATIONS

Despite the well-documented utility of the four-chamber and outflow-tract views, one should be aware of the potential diagnostic pitfalls that can prevent timely detection of CHD^{27–29}. Detection rates can be optimized by performing a thorough screening examination of the heart, recognizing that the four-chamber and three-vessel views require much more than a simple count of cardiac structures, understanding that some lesions are not discovered until later in pregnancy, and being aware that certain types of abnormality (e.g. transposition of the great arteries, aortic coarctation) may not be evident in the four-chamber plane alone. Complementing the four-chamber view with outflow-tract and great-vessel views in the cardiac screening examination has played an important role in improving detection of CHD^{24,30,31}.

Gestational age

The cardiac screening examination is performed optimally between 18 and 22 weeks' gestation (**GOOD PRACTICE POINT**). Screening at 20–22 weeks is less likely to require an additional scan for completion of this evaluation when compared with screening at 18–20 weeks, although many patients would prefer to know about major defects as early as possible in the pregnancy³². Many anatomical structures can be visualized satisfactorily beyond 22 weeks and some major cardiac defects may be identified during the late first and early second trimesters, especially when increased nuchal translucency thickness raises suspicion or if attempts are made to visualize the fetal heart during earlier scans^{33–39}.

Technical factors

Ultrasound transducer

Higher-frequency probes will improve the likelihood of detecting subtle defects, at the expense of reduced acoustic penetration. The highest possible transducer frequency should be used for all examinations, recognizing the trade-off between penetration and resolution. Tissue harmonic imaging provides improved images, especially for patients with increased abdominal wall thickness and during the third trimester of pregnancy⁴⁰ (**GOOD PRACTICE POINT**).

Imaging parameters

Cross-sectional grayscale imaging is the basis of a reliable fetal cardiac scan. System settings should emphasize a high frame rate, with increased contrast and high resolution. Low persistence, a single acoustic focal zone and a relatively narrow image field should also be used and are usually incorporated in cardiac presets. Advanced postprocessing of images has also been added to current ultrasound systems and contributes further to improved image display (**GOOD PRACTICE POINT**).

Zoom, cine-loop and image storage

Images should be magnified until the heart fills at least one-third to one-half of the screen. The cine-loop feature should be used to assist the real-time evaluation of normal cardiac structures, for example, to confirm movement of heart valve leaflets throughout the cardiac cycle. Image magnification and use of cine-loop may also help in identifying abnormalities (**GOOD PRACTICE POINT**).

For the structures and views noted in this Guideline, we recommend archiving of still frames and videoclips, while also considering local/national standards. The examination should be recorded in a manner that will allow subsequent review to verify its diagnostic adequacy, with appropriate patient identification and labeling of image laterality and orientation, when appropriate (**GOOD PRACTICE POINT**).

CARDIAC EXAMINATION

The cardiac screening examination should include the fetal *situs* and the four-chamber, outflow-tract and great-vessel views^{30,31,41–49}. This evaluation increases the detection rates for major cardiac malformations above those achievable using the four-chamber view alone^{24,30,31,50,51}. The inclusion of outflow-tract and great-vessel views enables detection of anomalies such as tetralogy of Fallot, transposition of the great arteries, double-outlet right ventricle and truncus arteriosus^{44–47,52–57}. This standardized workflow (Appendix 1) can also identify abnormalities of the semilunar valves, such as aortic and pulmonary stenosis, which may progress in severity as the pregnancy advances^{58,59} (**GRADE OF RECOMMENDATION: C**).

Situs and the four-chamber view

Sonographic technique

To assess cardiac *situs*, it is necessary first to determine fetal laterality, i.e. to identify fetal right and left sides, based on the position of the fetus *in utero*, prior to ascertaining that both stomach and heart are on the left side of the fetus^{48,60–62}. In the second trimester, the heart is positioned in a horizontal plane within the chest, held in place by the fetal liver, which extends to the left side of the fetal abdominal wall^{63,64}. A transverse sweep with cephalad movement of the transducer, from the fetal abdomen towards the fetal chest, allows visualization of the abdominal *situs* and the four-chamber view (Figures 1 and 2).

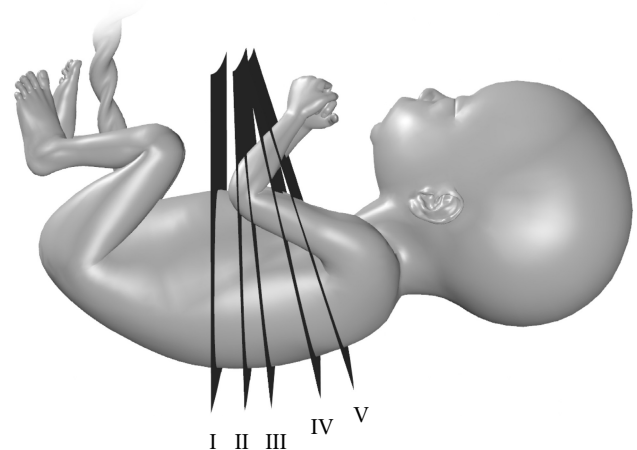


Figure 1 Technique for scanning fetal heart through sequential planes. (I) Axial view of upper abdomen is visualized first. (II) By moving and tilting the transducer in a cephalad direction, the four-chamber view is obtained through an axial scanning plane across the fetal chest. Further cephalad movement of the transducer from the four-chamber view towards the fetal head gives the outflow-tract and great-vessel views sequentially: (III) left ventricular outflow-tract view; (IV) right ventricular outflow-tract view and the three-vessel view variants; and (V) three-vessel-and-trachea view.

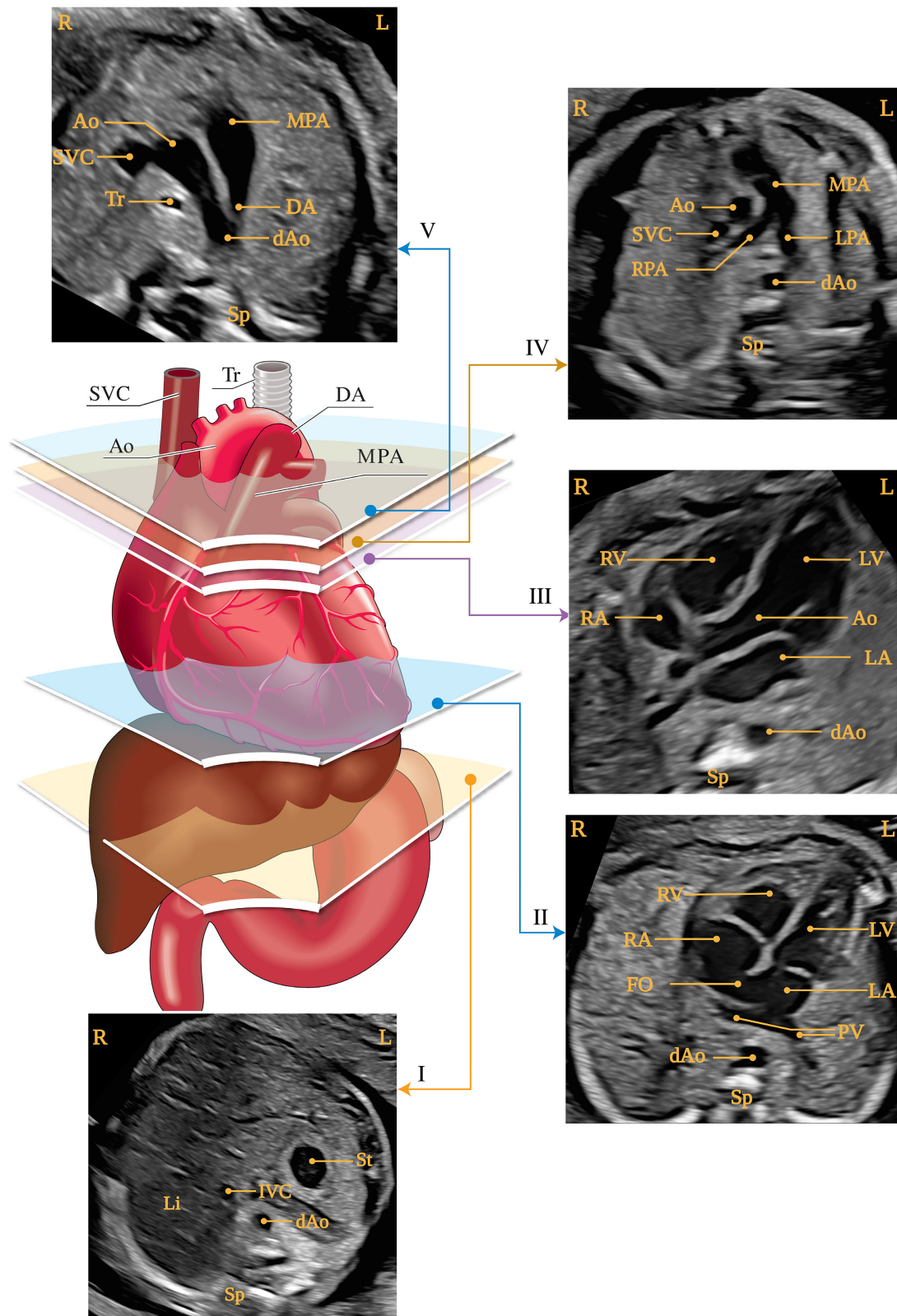


Figure 2 Five axial views for optimal fetal heart screening, corresponding to planes shown in Figure 1. Diagram shows trachea, heart and great vessels, liver and stomach, with five planes of insonation indicated by polygons, corresponding to grayscale images, as indicated. (I) Most caudal plane, showing fetal stomach (St), cross-section of descending aorta (dAo) and inferior vena cava (IVC), spine (Sp) and liver (Li). (II) Four-chamber view of fetal heart, showing right and left ventricles (RV, LV) and atria (RA, LA), foramen ovale (FO) and pulmonary veins (PV) to right and left of dAo. (III) Left ventricular outflow-tract view, showing proximal ascending aorta (Ao), LV, RV, LA and RA and cross-section of dAo. (IV) Slightly more cephalad view (right ventricular outflow-tract view) showing main pulmonary artery (MPA) and bifurcation into right (RPA) and left (LPA) pulmonary arteries and cross-sections of Ao and dAo. (V) Three-vessel-and-trachea view, showing superior vena cava (SVC), MPA, ductus arteriosus (DA), transverse aortic arch (from proximal Ao to dAo) and trachea (Tr). L, left, R, right. Modified from Yagel *et al.*⁹⁹ with permission.

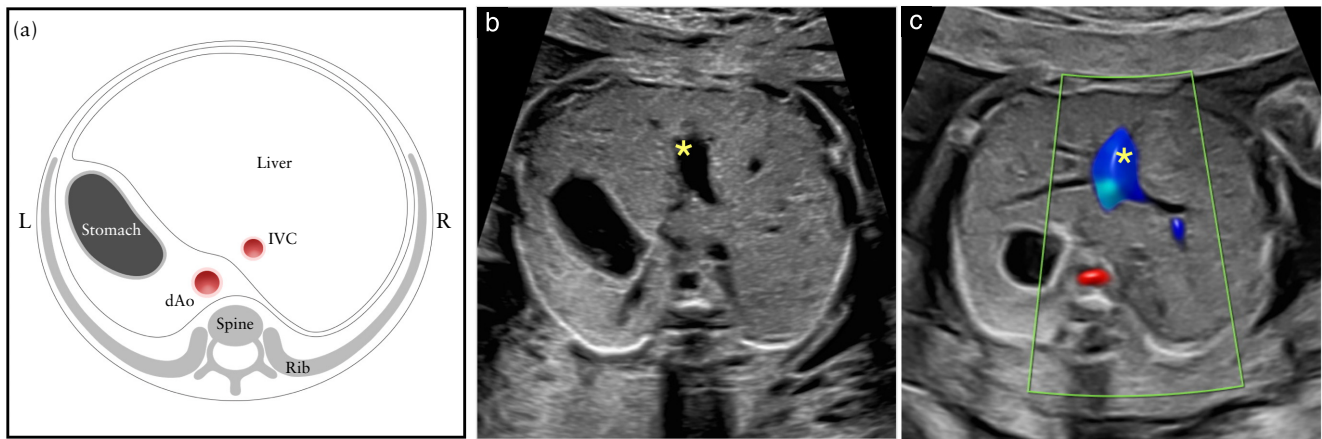


Figure 3 Schematic diagram (a) and corresponding grayscale (b) and color Doppler (c) ultrasound images of axial view of fetal upper abdomen. (a) Abdominal *situs* is ascertained in transverse view of fetal abdomen. After determination of fetal laterality from fetal position *in utero*, stomach should be identified on fetal left side, with descending aorta (dAo) and inferior vena cava (IVC) on left and right sides of spine, respectively. (b,c) Short segment of umbilical vein (★) is seen in center of liver. L, left, R, right.

Situs

The abdominal *situs* is obtained at the level of the standard abdominal circumference measurement, with the stomach visible on the left side. Additionally, cross-sectional views of the descending aorta and inferior vena cava are seen on the left and right sides of the spine, respectively (Figure 3). Identification of normal abdominal *situs* is a surrogate for normal atrial *situs* (*situs solitus*, i.e. right atrium to the right and left atrium to the left).

Four-chamber view

Assessment of the four-chamber view involves careful evaluation of specific criteria. The main elements for examination of the four chambers are shown in Table 1 and Figures 4 and 5. A normal heart is usually no larger than one-third of the area of the chest. A small amount of pericardial fluid is commonly seen during the second and third trimesters (≤ 2 mm in thickness, at end-systole) and is a normal finding⁶⁵. Some views may also reveal a small hypoechoic rim around the fetal heart, and care should be taken not to mistake this for pericardial effusion⁶⁶.

The heart is situated mainly on the left side of the chest and its long axis normally points to the left by about $45 \pm 20^\circ$ (2SD)⁶⁷ relative to the anteroposterior axis of the chest (Figure 4). Careful attention should be paid to cardiac axis and position, which can be evaluated easily even if the four-chamber view is not visualized satisfactorily⁶⁸. *Situs* abnormalities should be suspected when the fetal heart and/or stomach are not found on the left side. An abnormal cardiac axis increases the risk of a cardiac malformation, especially involving the outflow tracts⁶⁹. This finding may also be associated with a chromosomal anomaly. Abnormal displacement of the heart from its normal anterior left position can be caused by a diaphragmatic hernia or space-occupying lesion, such as congenital pulmonary airway malformation.

Table 1 Assessment of fetal laterality/*situs* and the four-chamber view

<i>Situs</i> and general appearance	
Fetal laterality (identify right and left sides of fetus)	
Stomach* and heart on left	
Descending aorta on left and inferior vena cava on right side of spine*	
Heart occupies one-third of thoracic area	
Majority of heart in left chest	
Cardiac axis (apex) points to left by $45 \pm 20^\circ$	
Four chambers present	
Regular cardiac rhythm	
No pericardial effusion	
Atrial chambers	
Two atria, approximately equal in size	
Foramen ovale flap in left atrium	
Atrial septum primum present (near crux)	
At least one pulmonary vein entering left atrium	
Ventricular chambers	
Two ventricles, approximately equal in size	
No ventricular wall hypertrophy	
Moderator band at right ventricular apex	
Ventricular septum intact (apex to crux)	
Atrioventricular junction and valves	
Intact cardiac crux	
Differential offsetting: tricuspid valve leaflet inserts on ventricular septum closer to cardiac apex than does mitral valve	

*Normal abdominal *situs*: implies normal position of atrial chambers (i.e. *situs solitus*).

Position abnormalities can also be secondary to fetal lung hypoplasia or agenesis⁷⁰. A shift of the axis to the left may also occur with fetal gastroschisis and omphalocele.

Normal heart rate and regular rhythm should be confirmed. The normal rate ranges from 120 to 160 beats per min (bpm). Skipped (or ectopic) beats are the most common rhythm disturbance. Often, these are benign and resolve spontaneously. In low-risk populations, they are not associated with an increased risk of structural fetal heart disease^{71,72}. However, frequent episodes

(more than every three to five beats) or a persistently irregular cardiac rhythm ($> 1-2$ weeks) are an indication for further assessment^{5,6,71,73-75}. Bradycardia, often associated with transducer pressure on the abdomen, is observed transiently in normal second-trimester fetuses. Persistent bradycardia (≤ 110 bpm) in a well fetus requires timely evaluation by a fetal cardiac specialist^{76,77}. Possible causes include frequent blocked atrial ectopic beats, atrioventricular block and sinus bradycardia^{78,79}. Repeated heart-rate decelerations during the third trimester can be caused by fetal hypoxia. Mild, transient tachycardia (160–180 bpm) can occur as a normal variant during fetal movement. Persistent tachycardia (≥ 180 bpm)^{78,80}, however, should be evaluated further for more serious tachydysrhythmias or fetal hypoxia.

Both atrial chambers normally appear similar in size and the foramen ovale flap moves within the left atrium. The lower rim of atrial septal tissue, the septum primum, should be present and forms part of the cardiac ‘crux’, the point at which the lower part of the atrial septum meets the upper part of the ventricular septum and where the atrioventricular valves insert. Pulmonary veins can often be seen entering the left atrium and, when technically feasible, visualization of at least one of these veins on B-mode is recommended. Although color flow can facilitate their visualization, this should not be considered mandatory. When used, color Doppler ultrasound should be displayed alongside B-mode images to avoid false-negative findings⁸¹.

The moderator band, a distinct muscle bundle that crosses the right ventricular cavity, is seen near the

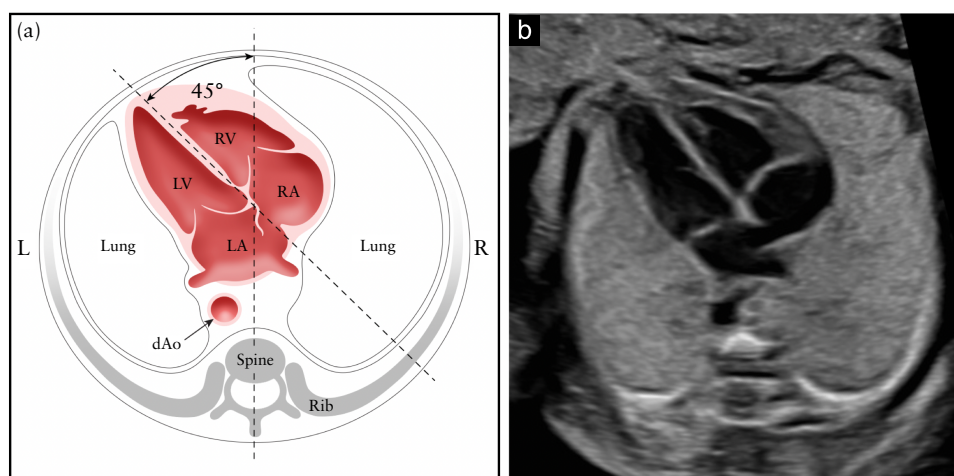


Figure 4 Determination of cardiac position and axis, shown in schematic diagram (a) and corresponding grayscale ultrasound image (b). Imaginary line drawn from spine posteriorly to sternum anteriorly divides thorax into two equal parts, left (L) and right (R). Normal fetal heart lies mainly on left, with cardiac apex pointing to left at an angle of $45 \pm 20^\circ$ in relation to anteroposterior axis of chest. dAo, descending aorta; LA, left atrium; LV, left ventricle; RA, right atrium; RV, right ventricle.

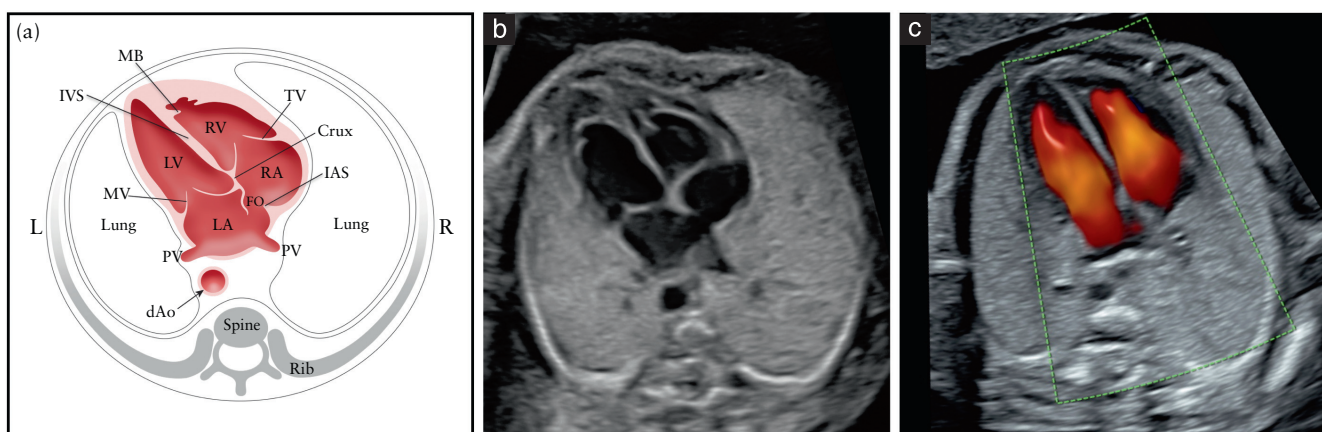

Figure 5 Schematic drawing (a) and corresponding grayscale (b) and color Doppler (c) ultrasound images of four-chamber view. Key elements of normal second-trimester four-chamber view include heart area no more than one-third of chest area, right- and left-sided structures approximately equal (in chamber size and wall thickness), patent foramen ovale (FO) with valve in left atrium (LA), intact cardiac ‘crux’ with normal offset of the two atrioventricular valves and intact interventricular septum (IVS). In (a) and (b), morphological right ventricle (RV) is identified by presence of moderator band (MB) and tricuspid valve (TV), with septal leaflet inserting in septum more apically compared with insertion of mitral valve (MV) (normal offset). Pulmonary veins (PV) are also seen to enter LA. On color Doppler (c), two separate blood inflows into ventricles can be seen during diastole. dAo, descending aorta; IAS, interatrial septum; L, left; LV, left ventricle; R, right; RA, right atrium.

apex and is helpful in identification of the morphological right ventricle. The left ventricular apex appears smooth and forms the apex of the heart. Both ventricles should appear similar in size and show no evidence of thickened walls. Although mild ventricular disproportion can occur as a normal variant in the third trimester of pregnancy, right–left asymmetry in midgestation warrants further examination⁸²; coarctation of the aorta, evolving hypoplastic left heart syndrome and anomalous pulmonary venous return can be important causes of this disparity^{83–85}.

The ventricular septum should be examined carefully for cardiac wall defects from the apex to the crux and, if possible, a sweep should be performed which starts at the most posterior part of the septum and moves towards the outflow tracts. Septal defects may be difficult to detect. The septum is best seen when the angle of insonation is perpendicular to it. When the ultrasound beam is directly parallel to the ventricular wall, a defect near the crux may be mistakenly suspected because of an acoustic ‘drop-out’ artifact. Small septal defects (1–2 mm) can be very difficult to confirm if the ultrasound imaging system fails to provide a sufficient degree of lateral resolution, especially if the fetal size and position are unfavorable. However, in most cases these are of limited clinical significance and may even undergo spontaneous closure *in utero*^{86,87}.

Two distinct atrioventricular valves (right-sided, tricuspid; left-sided, mitral) should be seen to open separately and freely. The septal leaflet of the tricuspid valve is inserted into the septum closer to the apex when compared with that of the mitral valve (i.e. normal offset). Abnormal alignment of the atrioventricular valves can be a key sonographic finding for cardiac anomalies such as atrioventricular septal defect.

Outflow-tract, three-vessel and three-vessel-and-trachea views

The left (LVOT) and right (RVOT) ventricular outflow-tract views and the three-vessel (3VV) and three-vessel-and-trachea (3VTV) views are now considered an integral part of the fetal cardiac screening examination. It is important to ascertain normality of the two great arteries, including connection to the correct ventricle, their size and their position relative to each other, and normal appearance and opening of the semilunar valves. A large obstetric ultrasound survey of over 18 000 fetuses⁸⁸ examined the practice of incorporating the four-chamber view and, when technically feasible, evaluation of the outflow tracts, into the routine 30-min second-trimester ultrasound examination. Most (93%) examinations that included an adequate four-chamber view were also associated with satisfactory evaluation of the outflow tracts. Non-visualization rates were 4.2% for the LVOT, 1.6% for the RVOT and 1.3% for both outflow tracts.

Examination of the ventricular outflow tracts and vessels requires, as a minimum, ascertainment that the great arteries are approximately equal in size. Any major discrepancy in their size should lead to further evaluation.

As they exit from their respective ventricles, three factors should be confirmed. First, in a normal LVOT, the first great artery exits from the left ventricle and its anterior wall is continuous with the ventricular septum. It does not bifurcate, indicating this to be the aorta. Second, in a normal RVOT, the great artery that exits the RV bifurcates, indicating this to be the pulmonary artery. Third, the two great arteries should cross each other (normal ‘crossover’).

In addition to the outflow-tract views, the closely related 3VV and 3VTV should be used to help detect anomalies involving the outflow tracts^{52,54,56,89}, aortic arch^{45,54,56,90} and systemic veins⁹¹, including persistent left superior vena cava^{92–94} and thymic anomalies^{95–97}. Abnormalities that may be picked up include transposition of the great arteries, tetralogy of Fallot and aortic and pulmonary stenosis. The more cephalad and angled 3VTV permits more detailed evaluation of the position of the aortic arch and ductus arteriosus and their relation to the trachea⁵⁵. It is particularly useful for detection of aortic arch abnormalities such as coarctation of the aorta, vascular rings and aberrant right subclavian artery⁹⁸.

Sonographic technique

Performing a transverse sweep with cephalad movement of the transducer from the four-chamber view towards the upper chest allows sequential assessment of the cardiac structures and provides the views necessary to ascertain normality of the outflow tracts and vessels: LVOT and RVOT views, 3VV and 3VTV⁹⁹ (Figures 1 and 2) (**GOOD PRACTICE POINT**). In an ideal examination, these views can be obtained with relative ease. When the fetal lie is unfavorable, additional examination time or a second examination may be necessary.

Typically, the outflow-tract and great-vessel views are obtained by parallel movement of the transducer towards the fetal head (sweep technique), accompanied by small adjustments in insonation angle, starting from a four-chamber view, to visualize the normal crossover of the aorta and main pulmonary artery at their origin. Details of the pulmonary artery bifurcation can also be seen. Alternatively, a variation in the method for evaluating the outflow tracts in the fetus has been described: the rotational technique⁴³. This starts from a four-chamber view of the heart, with the transducer first being rotated towards the fetal right shoulder. This technique, performed more easily when the interventricular septum is perpendicular to the ultrasound beam, may require slightly greater skill but optimizes visualization of the LVOT, especially the outlet part of the septum that is in continuity with the anterior wall of the aorta. It also allows visualization of the ascending aorta. With both techniques, once the LVOT view is obtained, the transducer is angled cephalad until the pulmonary artery is observed with a direction almost perpendicular to that of the aorta. The relative relationships of the RVOT and LVOT are best demonstrated using cine-clips rather than still frames.

The 3VV and 3VTV are additional views of the aorta and pulmonary artery and show their relationship with the superior vena cava and trachea. These views can be obtained by further cephalad movement of the transducer towards the fetal head from the RVOT, accompanied by small adjustments in insonation angle to obtain the best possible resolution for the different structures in each view. The ductal arch as well as the transverse aortic arch can also be imaged at this level^{52–55}.

Left ventricular outflow-tract (LVOT) view

The LVOT view confirms the presence of a great vessel originating from the morphological left ventricle (Figure 6) and from the center of the heart. Continuity should be documented between the ventricular septum and the anterior wall of this vessel to demonstrate integrity of the outlet septum. However, it is only the presence of the head and neck vessels originating from it that confirms this vessel as the aorta. The aortic valve should move freely and should not be thickened. It is possible to trace the aorta into its arch, from which three arteries originate into the neck. However, sagittal views of the aortic and ductal arches and assessment of the neck vessels are currently not considered part of the routine cardiac screening examination (Figure S1). The LVOT view helps to identify outlet ventricular septal defects and conotruncal as well as aortic valve abnormalities that are not visible in the four-chamber view.

Right ventricular outflow-tract (RVOT) view, three-vessel view (3VV) and three-vessel-and-trachea view (3VTV)

Describing the relationships between the various structures in the RVOT view, 3VV and 3VTV (Figures 7–9) is a sensitive means of describing many cardiac defects. Though initially described as specific still images, it is now recognized that the appearance in the axial plane of the

RVOT, branch pulmonary arteries and ductal and aortic arches represents a continuum of ‘views’ that may vary slightly depending on the orientation of the transducer, the fetal lie and the precise plane captured in a still frame (Figure 8). This assessment is likely to be more reliable during live scanning or on review of a cine-loop rather than from a series of still images alone⁶.

The RVOT view confirms the presence of a great vessel, the pulmonary artery, originating from the morphological right ventricle (Figures 7 and 8) and branching after a short course. The pulmonary valve should move freely and should not be thickened. The normal pulmonary artery courses towards the left of the more posterior ascending aorta, which is seen in cross-section. It is usually slightly larger than the ascending aorta during fetal life and crosses the ascending aorta anterior and cephalad to the LVOT at almost a right angle. At this level, the superior vena cava is seen to the right of the aorta.

The 3VV and 3VTV were described originally as a complement to the four-chamber view, with the aim of increasing the sensitivity of the cardiac screening examination. Yoo *et al.*⁵² described the 3VV to evaluate the pulmonary artery, ascending aorta and superior vena cava and their relative sizes and relationships (Figure 8). This involves an assessment of vessel number, size, alignment and arrangement. From left to right, the vessels are the pulmonary artery, aorta and right superior vena cava. The pulmonary artery is the most anterior vessel and the superior vena cava is the most posterior. Their relative diameters should decrease from left to right. Common abnormalities associated with a seemingly normal four-chamber view, such as complete transposition of the great arteries, tetralogy of Fallot, double outlet right ventricle, common arterial trunk and pulmonary atresia with ventricular septal defect, will typically be abnormal in the 3VV^{100,101}.

Yagel *et al.*⁵⁵ subsequently described the 3VTV, a view cephalad with respect to the 3VV, in which the

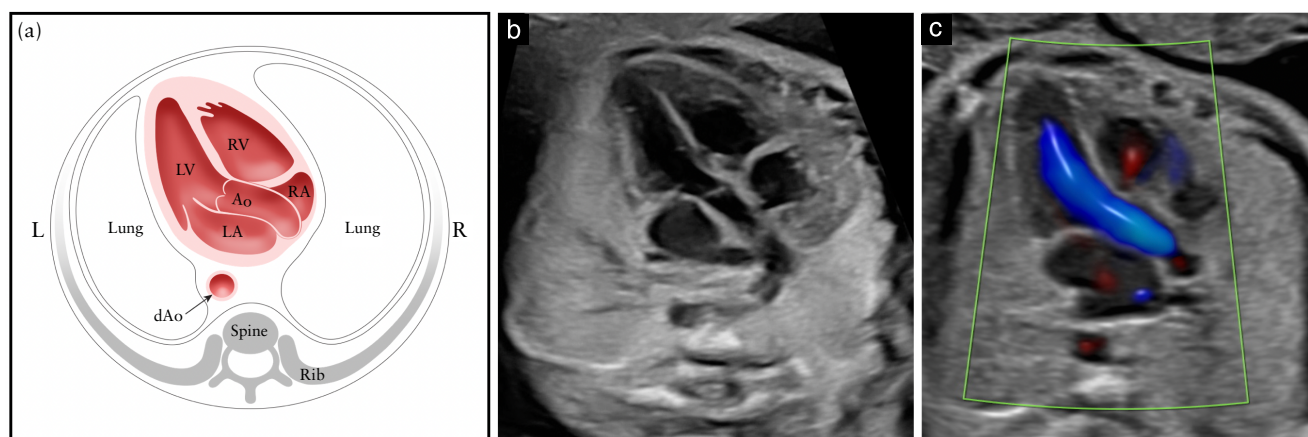


Figure 6 Schematic diagram (a) and corresponding grayscale (b) and color Doppler (c) ultrasound images of left ventricular outflow-tract view imaged from apical approach. This view shows vessel connected to left ventricle (LV). It is important to demonstrate continuity between interventricular septum and anterior wall of this vessel, which, in normal fetal heart, corresponds to proximal ascending aorta (Ao). Aortic valve should not be thickened and should be shown to open freely. (c) Color Doppler imaging during systole demonstrates laminar flow across Ao and along septo-aortic continuity. dAo, descending aorta; L, left; LA, left atrium; R, right; RA, right atrium; RV, right ventricle.

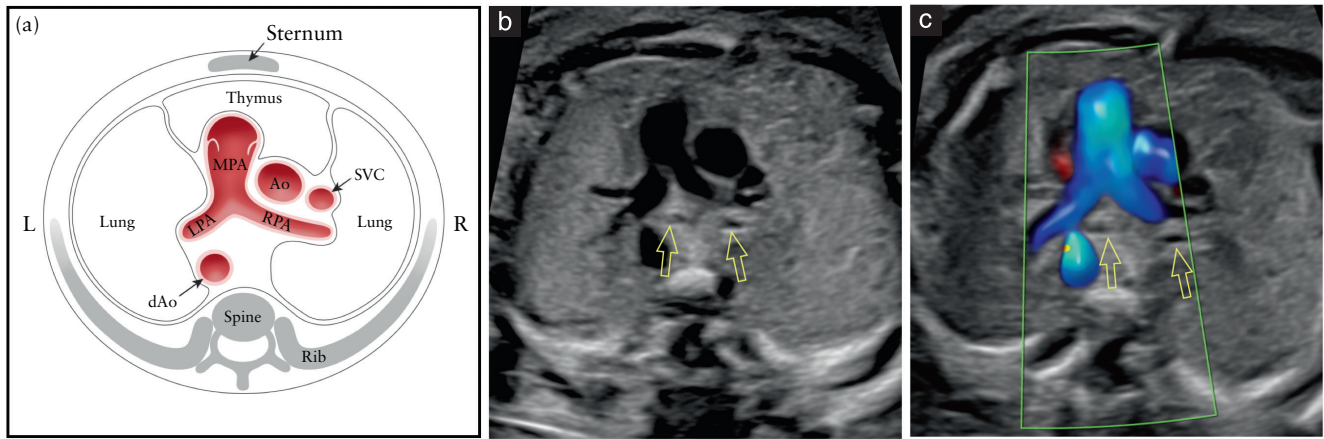


Figure 7 Schematic diagram (a) and corresponding grayscale (b) and color Doppler (c) ultrasound images of right ventricular outflow-tract view, which relates closely to three-vessel view. This view demonstrates not only main pulmonary artery (MPA) connected to right ventricle, but also ascending aorta (Ao) and superior vena cava (SVC). Pulmonary valve should not be thickened and should open freely. Bifurcation of MPA into both pulmonary branches (left (LPA) and right (RPA) pulmonary arteries) can be seen. It is important to note correct position and alignment of the three vessels as well as their relative size. MPA, to left, is largest of the three and most anterior, whereas SVC is smallest and most posterior. In (b) and (c), bronchial branches (open arrows) are seen. In (c), color Doppler demonstrates main MPA during systole, with its bifurcation into LPA and RPA. Note, between vessels and anterior thoracic wall, thymus can be identified as hypoechoic area. dAo, descending aorta; L, left; R, right.

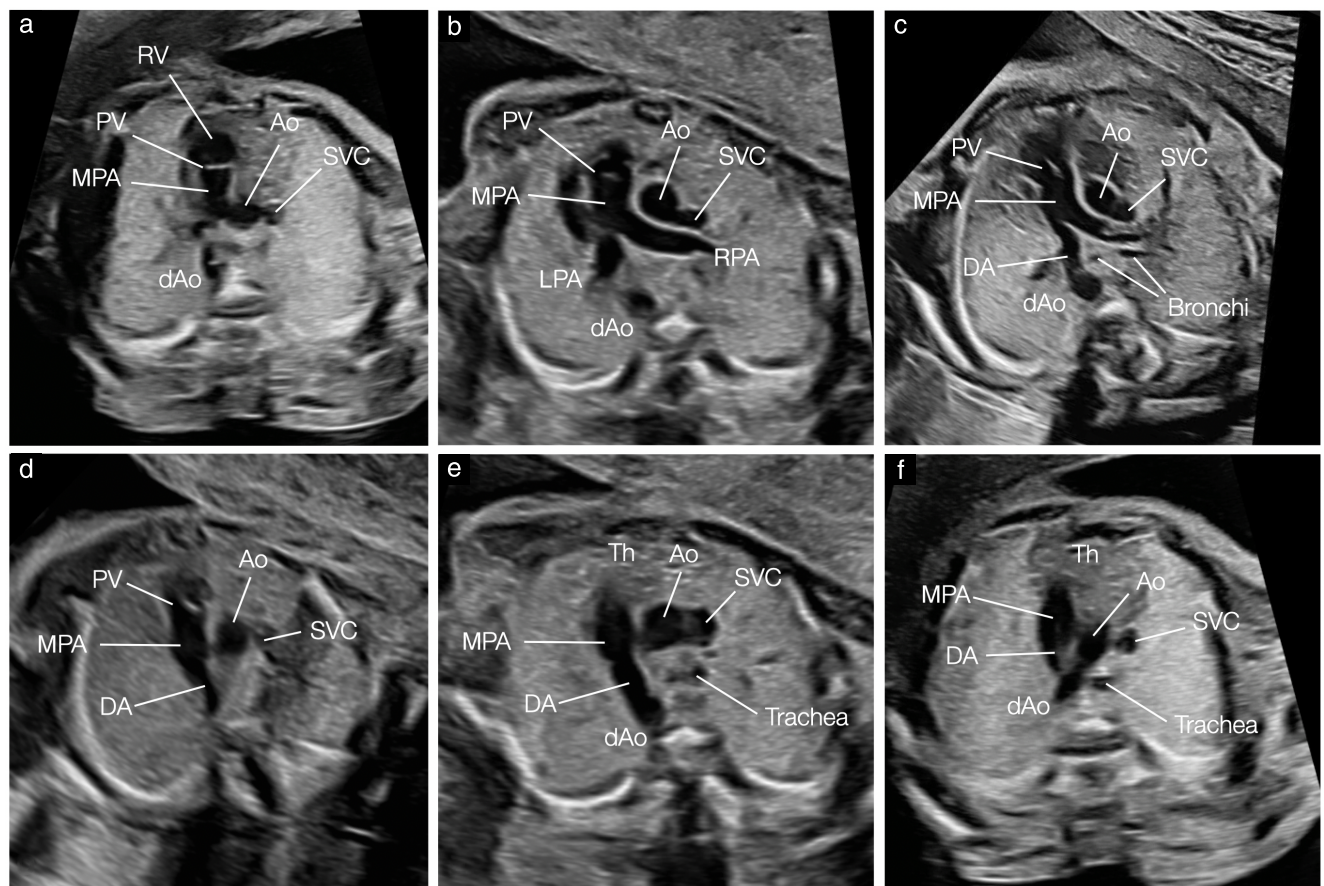


Figure 8 Variations of right ventricular outflow-tract and three-vessel views. In (a), right ventricle (RV) with pulmonary valve (PV) and main pulmonary artery (MPA) are seen, along with ascending aorta (Ao) and superior vena cava (SVC). In (b), slightly more cranial plane shows bifurcation of MPA into left (LPA) and right (RPA) pulmonary arteries. In (c), in even more cranial plane, MPA is seen in continuity with ductus arteriosus (DA) as it forms the ductal arch. In (d), DA is visualized together with PV, while, in (e), DA is seen in more cranial plane, without PV, and thymus (Th) starts to be visible. Trachea also starts to be seen, where, in lower planes (c), bronchi were visualized. In (f), three-vessel-and-trachea view shows both transverse aortic and ductal arches to left of trachea, and Th anterior to the great vessels. dAo, descending aorta.

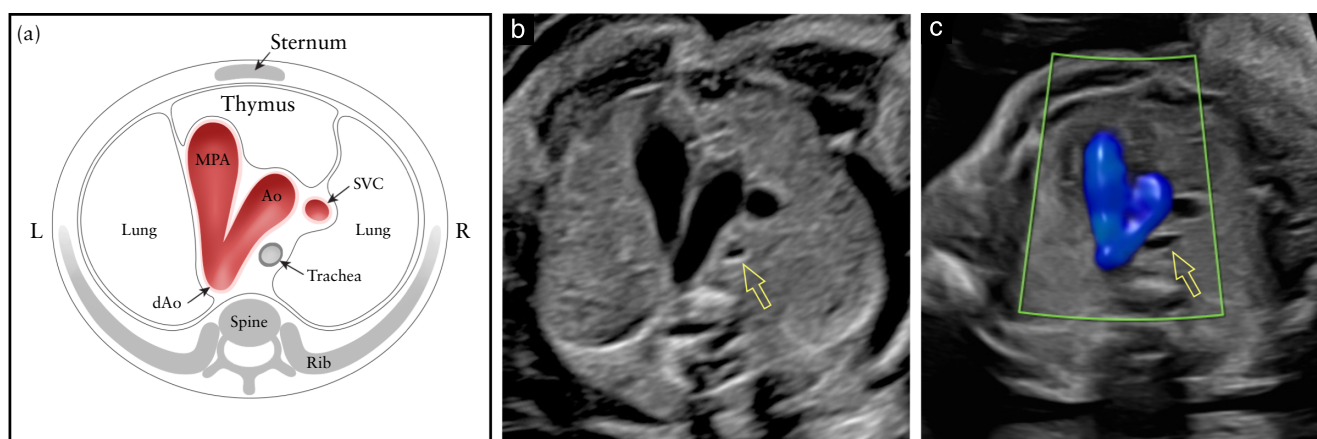


Figure 9 Schematic diagram (a) and corresponding grayscale (b) and color Doppler (c) ultrasound images of three-vessel-and-trachea view. In normal fetal heart, both aortic arch (Ao) and ductal arch, which extends from main pulmonary artery (MPA) to descending aorta (dAo) are located to left of trachea, in ‘V’-shaped configuration. In (b) and (c), relationship of transverse Ao with trachea (open arrow) is shown. In (c), color Doppler during systole demonstrates antegrade flow in ductal arch and Ao. Note, between the vessels and anterior thoracic wall, thymus can be identified as hypoechoic area. L, left; R, right; SVC, superior vena cava.

transverse aortic arch is visualized (‘aortic arch view’) and its relationship with the trachea emphasized (Figure 9). This view comprises a slightly oblique transverse plane that shows the main pulmonary artery in direct communication with the ductus arteriosus. The normal transverse aortic arch is positioned just to the right of the main pulmonary artery/ductal arch. The trachea can be identified as a hyperechoic ring surrounding a small fluid-filled space. The normal ductus arteriosus and aortic arch course to the left of the trachea and form an acute angle (‘V’-shape). The normal right superior vena cava and the normal thymus are also seen in this plane. The aortic arch is more cranial; therefore, to image both arches simultaneously may require some transducer adjustment from a true axial plane. The 3VTV is likely to enable detection of lesions such as coarctation of the aorta, right aortic arch and double aortic arch.

Anomalies diagnosed using the 3VV and 3VTV may inform counseling and management (e.g. indicating prenatal testing for 22q11 microdeletion) influencing planning of delivery location (e.g. in complete transposition of the great arteries) and immediate postnatal care (e.g. need for prostaglandin infusion) as well as enabling anticipation of potential airway issues from vascular compression¹⁰².

COLOR FLOW DOPPLER ULTRASOUND

Although the use of color flow Doppler ultrasonography is not considered mandatory in these Guidelines, becoming familiar with its use and adding it to routine screening is encouraged¹⁰³. Color flow mapping is an integral part of a fetal echocardiogram and its role in the diagnosis of CHD cannot be underestimated. It can be incorporated during routine screening if the operator feels competent with its use. In a normal fetal heart, color flow mapping will demonstrate antegrade flow across the atrioventricular and semilunar valves and great arteries. It may also facilitate imaging of the various cardiac structures. For

example, flow visualization in the aorta and ductal arches helps in identifying the ‘V-sign’ as well as highlighting abnormal blood-flow patterns, such as atrioventricular valve regurgitation and flow reversal in the ductus arteriosus and aortic arch. It may also constitute a valuable tool in the evaluation of cardiac anatomy in obese patients^{104,105} and may further improve detection rates of major CHD in low-risk pregnancies^{47,106}.

Optimal color Doppler settings include the use of a narrow color box positioned only over the area of interest for evaluation, rather than covering the entire two-dimensional image of the heart. Limiting the color box to a specific region-of-interest will optimize the frame rate and color image quality, which will allow display of flow across valves and vessels without image stuttering or real-time delay. During routine second-trimester screening, the color flow velocity scale should be set at *c.* 50–70 cm/s for intracardiac structures and vessels. This setting and low color flow persistence are usually incorporated in cardiac presets. However, the velocity scale should be set lower if interrogating venous structures (*c.* 15–25 cm/s) (Figure S2).

FETAL ECHOCARDIOGRAPHY

Fetuses identified as having, or suspected of having, an abnormality on routine cardiac ultrasound screening are candidates for a fetal echocardiogram^{5,6} (GOOD PRACTICE POINT). For fetuses with a significant risk factor for CHD, i.e. when their risk is elevated above that of the general population, fetal echocardiography is also indicated in addition to routine cardiac screening, dependent on factors such as local resources, clinical setting, examiner availability and results of screening (GOOD PRACTICE POINT). However, a high proportion of cases with a CHD detectable prenatally are patients without any risk factors or extracardiac anomalies, hence the importance of quality screening, with timely referral if this suggests an abnormality.

Healthcare practitioners should be familiar with common reasons for referral for comprehensive cardiac evaluation by fetal echocardiography^{5,6,107}. While precise estimates of risk are beyond the scope of this Guideline, a non-exhaustive list of common fetal and patient conditions associated with an increased risk of CHD is shown in Table 2⁶. For example, nuchal translucency thickness ≥ 3.5 mm at 11–14 weeks' gestation is an indication for a detailed cardiac evaluation^{108–110} even if the measurement subsequently falls within the normal range.

Table 2 Common indications for fetal echocardiography

Fetal factors	
Suspected cardiac structural anomaly	
Fetal extracardiac anomaly known to be associated with CHD*	
Suspected abnormality of cardiac function or cardiomegaly	
Hydrops fetalis	
Persistent fetal tachycardia (heart rate ≥ 180 bpm)	
Suspected heart block or persistent fetal bradycardia (heart rate ≤ 110 bpm)	
Frequent episodes or persistently irregular cardiac rhythm	
Nuchal translucency ≥ 3.5 mm	
Confirmed or suspected genetic abnormality	
Monochorionic twinning†	
Patient or familial disease or environmental exposure	
First-degree relative of fetus with CHD (parents, siblings, half-siblings)	
First- or second-degree relative with disease of Mendelian inheritance and history of childhood cardiac manifestations	
Pregestational diabetes, regardless of HbA1c level	
Anti-Ro/SSA antibodies	
Phenylketonuria (unknown status or periconceptual phenylalanine level > 10 mg/dL)	
Retinoid exposure	
Confirmed fetal infection (TORCH- and parvovirus-B19-positive)	
Other indications when fetal echo may be considered	
Second-degree relative of fetus with CHD	
Gestational diabetes diagnosed in first or early second trimester	
Nuchal translucency between 3.0 and 3.4 mm	
Selected teratogen exposure (e.g. paroxetine, carbamazepine, lithium, sodium valproate)	
Conception by IVF, including ICSI	
Use of ACE inhibitors (antihypertensive medication)	
Other considerations	
Though historical reports may suggest otherwise, there is insufficient evidence to show that risk of CHD is significantly over baseline for certain patient and fetal factors, including: patient obesity (BMI ≥ 35 kg/m ²), SSRI antidepressant exposure other than paroxetine, non-cardiac 'soft marker' for aneuploidy, abnormal serum analytes (e.g. α -fetoprotein level), isolated SUA, gestational diabetes diagnosed after second trimester, warfarin exposure, alcohol exposure, echogenic intracardiac focus, prenatal fever or viral infection with seroconversion only, isolated CHD in a relative further removed than second-degree to fetus.	

*For example, exomphalos, congenital diaphragmatic hernia, suspected esophageal atresia/gastrointestinal obstruction¹²⁴. †If resources allow (twins are also seen by fetal medicine specialists). ACE, angiotensin converting enzyme; anti-Ro/SSA, anti-Sjögren's-syndrome-related antigen-A; BMI, body mass index; CHD, congenital heart disease; HbA1c, hemoglobin A1c; ICSI, intracytoplasmic sperm injection; IVF, *in-vitro* fertilization; SSRI, selective serotonin reuptake inhibitor; SUA, single umbilical artery.

Fetal echocardiography is best performed by a trained specialist who is familiar with prenatal diagnosis of CHD as well as with the postnatal course, management and prognosis³. The purpose is to perform a comprehensive assessment of the fetal heart and, if an abnormality is encountered, to counsel parents about the diagnosis, long-term implications and outcome and discuss management options. Prenatal counseling following detection of a CHD should also take into account the high prevalence of maternal psychological distress¹¹¹ that is associated with the discovery of fetal CHD.

QUALITY ASSURANCE

When assessing quality, it is important to check various aspects of the cardiac screening examination to ensure completeness of information, including the image quality, acquisition of the standard viewing planes, appropriate interpretation of the recommended scanning views and complete documentation^{112,113}.

Good technical performance relies on optimal ultrasound settings, including the use of cardiac presets and appropriate magnification. This improves image quality and facilitates the operator's ability to recognize clearly the anatomic landmarks in the various recommended scanning planes. If color Doppler ultrasonography is utilized, the settings should be optimized and the velocity scale set according to the structures being mapped (Figures S1 and S2). One retrospective study of failed prenatal detection of CHD demonstrated that not meeting technical criteria contributed to about 50% of missed abnormalities²³. However, operator failure to recognize abnormal heart anatomy on a technically appropriate view accounted for another 31% of missed cases.

Continual quality assessment is extremely important for obstetrical ultrasound and fetal cardiac screening. An audit policy based on predetermined quality criteria for interpretation and rating of still images or clips is an important tool, the use of which is encouraged and may reduce the number of prenatal diagnostic errors, thus improving timely detection of CHD^{114–117}. ISUOG encourages each imaging practice to review annually local detection rates and diagnostic accuracy of CHD and to provide further training as needed.

EARLY FETAL CARDIAC SCREENING

Screening for CHD in the first trimester has been shown to be effective in low-risk populations¹¹⁸. However, it is neither performed routinely nor considered mandatory. In countries or centers in which this is possible, early screening can be carried out at the time of the nuchal translucency scan. Minimum requirements for early screening include visualization of the heart within the chest and ascertainment of regular rhythm³⁹. It should be borne in mind that, due to the small size of the fetal heart in early gestation, the success rate of visualization of the cardiac structures on detailed anatomic survey is significantly higher after 12 + 3 gestational weeks^{36,119,120}.

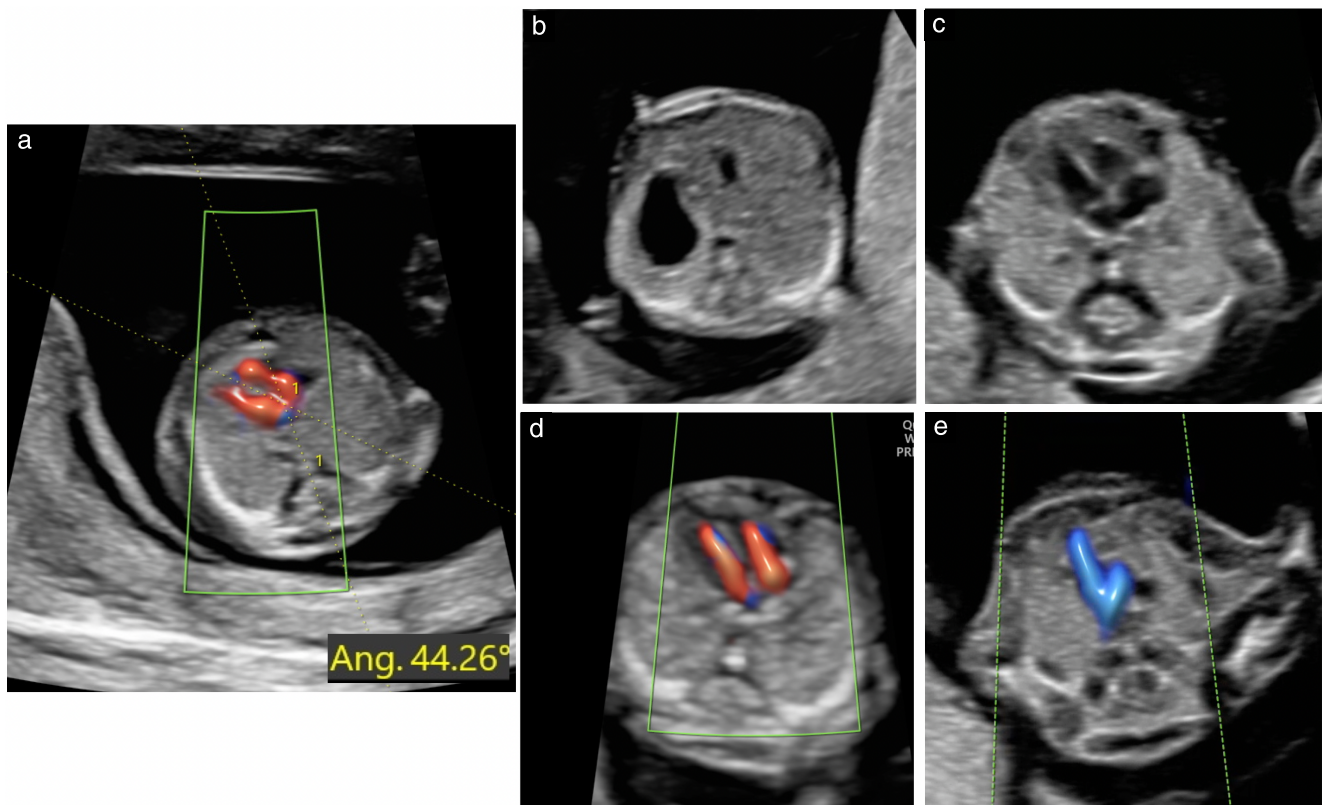


Figure 10 Cardiac examination in early gestation should focus on these selected planes, similar to second-trimester examination: (a) demonstration of cardiac axis (calipers), (b) abdominal view with demonstration of stomach on left side, (c) four-chamber view (grayscale), (d) four-chamber view (color Doppler) during diastole and (e) three-vessel-and-trachea view (color Doppler) during systole.

Though transvaginal transducers may be used, the recommended methodology includes use of high-frequency transabdominal transducers, owing to their higher resolution, and use of color and/or high-quality power Doppler (bidirectional flow mapping) in addition to grayscale imaging. Color and power Doppler ultrasound should be adjusted to prioritize the color signal over the grayscale, to enhance visualization of the blood flow across the small structures in the first-trimester fetal heart. Doppler should be used primarily for screening the four-chamber view and the 3VTV, for safety reasons. The most recent ISUOG safety statement suggests that the various Doppler modalities may be used routinely between 11 + 0 and 13 + 6 weeks for certain clinical indications, including screening for cardiac anomalies. Nevertheless, it is important to observe the displayed thermal index, which should be ≤ 1.0 , and the exposure time should be kept as short as possible (usually no longer than 5–10 min)¹²¹.

The following components are recommended as part of a detailed early cardiac screening examination³⁹ (Figure 10) (GOOD PRACTICE POINT).

(1) *Situs*, determined on grayscale imaging, to ascertain the normal position of the stomach and heart, both of which should be on the left side of the fetus. It is also important to assess the cardiac axis, as this is a useful marker for CHD¹²².

(2) Four-chamber view, displayed using grayscale and color and/or bidirectional power Doppler imaging.

Ideally, the spine is visualized posteriorly for adequate demonstration of biventricular filling.

(3) 3VTV, displayed using color and/or bidirectional power Doppler ultrasound, to demonstrate the left-sided aortic and ductal arches.

Visualization of left and right outflow tracts at this early gestational age is often challenging and prone to both false-negative and false-positive diagnosis. Hence, if early cardiac screening is performed at the time of the nuchal translucency scan, this should be based mainly on determining *situs* and obtaining the four-chamber view and 3VTV¹²³. Should any suspicion of CHD be raised at this scan, the patient should be referred for early fetal echocardiography.

GUIDELINE AUTHORS

J. S. Carvalho, Royal Brompton Hospital, Guy's & St Thomas' NHS Foundation Trust; and Fetal Medicine Unit, St George's University Hospitals NHS Foundation Trust and Cardiovascular Clinical Academic Group, Molecular and Clinical Sciences Research Institute, St George's, University of London, London, UK

R. Axt-Fliedner, Division of Prenatal Medicine & Fetal Therapy, Department of Obstetrics & Gynecology, Justus-Liebig-University Giessen, University Hospital Giessen & Marburg, Giessen, Germany

R. Chaoui, Center of Prenatal Diagnosis and Human Genetics, Berlin, Germany

J. A. Copel, Departments of Obstetrics, Gynecology & Reproductive Sciences, and Pediatrics, Yale School of Medicine, New Haven, CT, USA

B. F. Cuneo, Children's Hospital Colorado, The Heart Institute, Aurora, CO, USA

D. Goff, Pediatric Cardiology of Houston and Loma Linda University School of Medicine, Houston, TX, USA

L. Gordin Kopylov, Obstetrical Unit, Shamir Medical Center (formerly Assaf Harofeh Medical Center), Zerifin, Israel; and Sackler Faculty of Medicine, Tel Aviv University, Tel Aviv, Israel

K. Hecher, Department of Obstetrics and Fetal Medicine, University Medical Center Hamburg-Eppendorf, Hamburg, Germany

W. Lee, Department of Obstetrics and Gynecology, Baylor College of Medicine and Texas Children's Hospital, Houston, TX, USA

A. J. Moon-Grady, Clinical Pediatrics, UC San Francisco, San Francisco, CA, USA

H. A. Mousa, Fetal Medicine Unit, University of Leicester, Leicester, UK

H. Munoz, Obstetrics and Gynecology, Universidad de Chile and Clinica Las Condes, Santiago, Chile

D. Paladini, Fetal Medicine and Surgery Unit, IRCCS Istituto Giannina Gaslini, Genoa, Italy

F. Prefumo, Obstetrics and Gynecology Unit, IRCCS Istituto Giannina Gaslini, Genoa, Italy

E. Quarello, Image 2 Center, Obstetrics and Gynecologic Department, St Joseph Hospital, Marseille, France

J. Rychik, Fetal Heart Program at Children's Hospital of Philadelphia, and Perelman School of Medicine at University of Pennsylvania, Philadelphia, PA, USA

B. Tutschek, Pränatal Zürich, Zürich, Switzerland; and Medical Faculty, Heinrich Heine University, Düsseldorf, Germany

M. Wiechec, Department of Gynecology and Obstetrics, Jagiellonian University in Krakow, Krakow, Poland

S. Yagel, Department of Obstetrics and Gynecology, Hadassah Medical Center, Mt. Scopus and the Faculty of Medicine, Hebrew University of Jerusalem, Jerusalem, Israel

CITATION

These Guidelines should be cited as: 'Carvalho JS, Axt-Fliedner R, Chaoui R, Copel JA, Cuneo BF, Goff D, Gordin Kopylov L, Hecher K, Lee W, Moon-Grady AJ, Mousa HA, Munoz H, Paladini D, Prefumo F, Quarello E, Rychik J, Tutschek B, Wiechec M, Yagel S. ISUOG Practice Guidelines (updated): fetal cardiac screening. *Ultrasound Obstet Gynecol* 2023; **61**: 788–803.

ACKNOWLEDGMENT

The authors wish to thank Dr Frantisek Grochal, from Martin-Slovakia, for his time and expertise in producing the cardiac diagrams for these Guidelines.

REFERENCES

- Carvalho JS, Allan LD, Chaoui R, Copel JA, DeVore GR, Hecher K, Lee W, Munoz H, Paladini D, Tutschek B, Yagel S. ISUOG Practice Guidelines (updated): sonographic screening examination of the fetal heart. *Ultrasound Obstet Gynecol* 2013; **41**: 348–359.
- De Groot K, Vanhie E, Roets E, Ramaekers P, De Wilde H, Panzer J, Vandekerckhove K, Bove T, Francois K, Van Herck K, De Wolf D. Outcome after prenatal and postnatal diagnosis of complex congenital heart defects and the influence of genetic anomalies. *Prenat Diagn* 2017; **37**: 983–991.
- Lee W, Allan L, Carvalho JS, Chaoui R, Copel J, Devore G, Hecher K, Munoz H, Nelson T, Paladini D, Yagel S. ISUOG consensus statement: what constitutes a fetal echocardiogram? *Ultrasound Obstet Gynecol* 2008; **32**: 239–242.
- Rychik J, Ayres N, Cuneo B, Gotteiner N, Hornberger L, Spevak PJ, Van DV. American Society of Echocardiography guidelines and standards for performance of the fetal echocardiogram. *J Am Soc Echocardiogr* 2004; **17**: 803–810.
- Donofrio MT, Moon-Grady AJ, Hornberger LK, Copel JA, Sklansky MS, Abuhamad A, Cuneo BF, Huhta JC, Jonas RA, Krishnan A, Lacey S, Lee W, Michelfelder EC, Rempel GR, Silverman NH, Spray TL, Strasburger JF, Tworetzky W, Rychik J. Diagnosis and Treatment of Fetal Cardiac Disease: A Scientific Statement From the American Heart Association. *Circulation* 2014; **129**: 2183–2242.
- AIUM Practice Parameter for the Performance of Fetal Echocardiography. *J Ultrasound Med* 2020; **39**: E5–E16.
- Liu Y, Chen S, Zuhlke L, Black GC, Choy MK, Li N, Keavney BD. Global birth prevalence of congenital heart defects 1970–2017: updated systematic review and meta-analysis of 260 studies. *Int J Epidemiol* 2019; **48**: 455–463.
- Holland BJ, Myers JA, Woods CR, Jr. Prenatal diagnosis of critical congenital heart disease reduces risk of death from cardiovascular compromise prior to planned neonatal cardiac surgery: a meta-analysis. *Ultrasound Obstet Gynecol* 2015; **45**: 631–638.
- Tworetzky W, McElhinney DB, Reddy VM, Brook MM, Hanley FL, Silverman NH. Improved surgical outcome after fetal diagnosis of hypoplastic left heart syndrome. *Circulation* 2001; **103**: 1269–1273.
- Franklin O, Burch M, Manning N, Sleeman K, Gould S, Archer N. Prenatal diagnosis of coarctation of the aorta improves survival and reduces morbidity. *Heart* 2002; **87**: 67–69.
- Blyth M, Howe D, Gnanaprasam J, Wellesley D. The hidden mortality of transposition of the great arteries and survival advantage provided by prenatal diagnosis. *BJOG* 2008; **115**: 1096–1100.
- Kipps AK, Feuille C, Azakie A, Hoffman JL, Tabbutt S, Brook MM, Moon-Grady AJ. Prenatal diagnosis of hypoplastic left heart syndrome in current era. *Am J Cardiol* 2011; **108**: 421–427.
- van Velzen CL, Haak MC, Reijnders G, Rijlaarsdam ME, Bax CJ, Pajkrt E, Hruđa J, Galindo-Garre F, Bilardo CM, de Groot CJ, Blom NA, Clur SA. Prenatal detection of transposition of the great arteries reduces mortality and morbidity. *Ultrasound Obstet Gynecol* 2015; **45**: 320–325.
- van Velzen CL, Clur SA, Rijlaarsdam ME, Bax CJ, Pajkrt E, Heymans MW, Bekker MN, Hruđa J, de Groot CJ, Blom NA, Haak MC. Prenatal detection of congenital heart disease—results of a national screening programme. *BJOG* 2016; **123**: 400–407.
- Bonnet D, Coltri A, Butera G, Fermont L, Le Bidou J, Kachaner J, Sidi D. Detection of transposition of the great arteries in fetuses reduces neonatal morbidity and mortality. *Circulation* 1999; **99**: 916–918.
- Peyvandi S, De Santiago V, Chakkarapani E, Chau V, Campbell A, Poskitt KJ, Xu D, Barkovich AJ, Miller S, McQuillen P. Association of Prenatal Diagnosis of Critical Congenital Heart Disease With Postnatal Brain Development and the Risk of Brain Injury. *JAMA Pediatr* 2016; **170**: e154450.
- Khoshnood B, Lelong N, Houyel L, Bonnet D, Ballon M, Jouannic JM, Goffinet F, EPICARD Study group. Impact of prenatal diagnosis on survival of newborns with four congenital heart defects: a prospective, population-based cohort study in France (the EPICARD Study). *BMJ Open* 2017; **7**: e018285.
- Dolk H, Loane M, Garne E, European Surveillance of Congenital Anomalies Working Group. Congenital heart defects in Europe: prevalence and perinatal mortality, 2000 to 2005. *Circulation* 2011; **123**: 841–849.
- Quartermain MD, Pasquali SK, Hill KD, Goldberg DJ, Huhta JC, Jacobs JP, Jacobs ML, Kim S, Ungerleider RM. Variation in Prenatal Diagnosis of Congenital Heart Disease in Infants. *Pediatrics* 2015; **136**: e378–385.
- Sharland GK, Allan LD. Screening for congenital heart disease prenatally. Results of a 2 1/2-year study in the South East Thames Region. *BJOG* 1992; **99**: 220–225.
- DeVore GR, Medearis AL, Bear MB, Horenstein J, Platt LD. Fetal echocardiography: factors that influence imaging of the fetal heart during the second trimester of pregnancy. *J Ultrasound Med* 1993; **12**: 659–663.
- Tegnander E, Williams W, Johansen OJ, Blaas HG, Eik-Nes SH. Prenatal detection of heart defects in a non-selected population of 30,149 fetuses—detection rates and outcome. *Ultrasound Obstet Gynecol* 2006; **27**: 252–265.
- van Nisselrooij AEL, Teunissen AKK, Clur SA, Rozendaal L, Pajkrt E, Linskens IH, Rammeloo L, van Lith JMM, Blom NA, Haak MC. Why are congenital heart defects being missed? *Ultrasound Obstet Gynecol* 2020; **55**: 747–757.
- Carvalho JS, Mavrides E, Shinebourne EA, Campbell S, Thilaganathan B. Improving the effectiveness of routine prenatal screening for major congenital heart defects. *Heart* 2002; **88**: 387–391.
- Cuneo BF, Olson CA, Haxel C, Howley L, Gagnon A, Benson DW, Kaizer AM, Thomas JF. Risk Stratification of Fetal Cardiac Anomalies in an Underserved Population Using Telecardiology. *Obstet Gynecol* 2019; **134**: 1096–1103.
- Hautala J, Gissler M, Ritvanen A, Tekay A, Pitkanen-Argillander O, Stefanovic V, Sarkola T, Helle E, Pihkala J, Patila T, Mattila IP, Jokinen E, Rasanen J, Ojala T. The implementation of a nationwide anomaly screening programme improves prenatal

- detection of major cardiac defects: an 11-year national population-based cohort study. *BJOG* 2019; 126: 864–873.
27. Tegnander E, Eik-Nes SH, Johansen OJ, Linker DT. Prenatal detection of heart defects at the routine fetal examination at 18 weeks in a non-selected population. *Ultrasound Obstet Gynecol* 1995; 5: 372–380.
 28. Chaoui R. The four-chamber view: four reasons why it seems to fail in screening for cardiac abnormalities and suggestions to improve detection rate. *Ultrasound Obstet Gynecol* 2003; 22: 3–10.
 29. Tegnander E, Eik-Nes SH, Linker DT. Incorporating the four-chamber view of the fetal heart into the second-trimester routine fetal examination. *Ultrasound Obstet Gynecol* 1994; 4: 24–28.
 30. Kirk JS, Riggs TW, Comstock CH, Lee W, Yang SS, Weinhouse E. Prenatal screening for cardiac anomalies: the value of routine addition of the aortic root to the four-chamber view. *Obstet Gynecol* 1994; 84: 427–431.
 31. Achiron R, Glaser J, Gelernter I, Hegesh J, Yagel S. Extended fetal echocardiographic examination for detecting cardiac malformations in low risk pregnancies. *BMJ* 1992; 304: 671–674.
 32. Schwarzler P, Senat MV, Holden D, Bernard JP, Masroor T, Ville Y. Feasibility of the second-trimester fetal ultrasound examination in an unselected population at 18, 20 or 22 weeks of pregnancy: a randomized trial. *Ultrasound Obstet Gynecol* 1999; 14: 92–97.
 33. Achiron R, Rotstein Z, Lipitz S, Mashiach S, Hegesh J. First-trimester diagnosis of fetal congenital heart disease by transvaginal ultrasonography. *Obstet Gynecol* 1994; 84: 69–72.
 34. Yagel S, Weissman A, Rotstein Z, Manor M, Hegesh J, Anteby E, Lipitz S, Achiron R. Congenital heart defects: natural course and in utero development. *Circulation* 1997; 96: 550–555.
 35. Rustico MA, Benettoni A, D'Ottavio G, Fischer-Tamaro L, Conoscenti GC, Meir Y, Natale R, Bussani R, Mandruzzato GP. Early screening for fetal cardiac anomalies by transvaginal echocardiography in an unselected population: the role of operator experience. *Ultrasound Obstet Gynecol* 2000; 16: 614–619.
 36. Carvalho JS. Fetal heart scanning in the first trimester. *Prenat Diagn* 2004; 24: 1060–1067.
 37. Carvalho JS, Moscogo G, Tekay A, Campbell S, Thilaganathan B, Shinebourne EA. Clinical impact of first and early second trimester fetal echocardiography on high risk pregnancies. *Heart* 2004; 90: 921–926.
 38. Hugnon IC, Ghi T, Cook AK, Zosmer N, Allan LD, Nicolaidis KH. Fetal cardiac abnormalities identified prior to 14 weeks' gestation. *Ultrasound Obstet Gynecol* 2002; 20: 22–29.
 39. International Society of Ultrasound in Obstetrics and Gynecology; Bilardo CM, Chaoui R, Hyett JA, Kagan KO, Karim JN, Papageorgiou AT, Poon LC, Salomon LJ, Syngelaki A, Nicolaidis KH. ISUOG Practice Guidelines (updated): performance of 11–14-week ultrasound scan. *Ultrasound Obstet Gynecol* 2023; 61: 127–143.
 40. Paladini D, Vassallo M, Tartaglione A, Lapadula C, Martinelli P. The role of tissue harmonic imaging in fetal echocardiography. *Ultrasound Obstet Gynecol* 2004; 23: 159–164.
 41. Allan LD, Crawford DC, Chita SK, Tynan MJ. Prenatal screening for congenital heart disease. *Br Med J (Clin Res Ed)* 1986; 292: 1717–1719.
 42. Copel JA, Pilu G, Green J, Hobbins JC, Kleinman CS. Fetal echocardiographic screening for congenital heart disease: the importance of the four-chamber view. *Am J Obstet Gynecol* 1987; 157: 648–655.
 43. DeVore GR. The aortic and pulmonary outflow tract screening examination in the human fetus. *J Ultrasound Med* 1992; 11: 345–348.
 44. Achiron R, Rotstein Z, Hegesh J, Bronshtein M, Zimand S, Lipitz S, Yagel S. Anomalies of the fetal aortic arch: a novel sonographic approach to *in-utero* diagnosis. *Ultrasound Obstet Gynecol* 2002; 20: 553–557.
 45. Yoo SJ, Min JY, Lee YH, Roman K, Jaeggi E, Smallhorn J. Fetal sonographic diagnosis of aortic arch anomalies. *Ultrasound Obstet Gynecol* 2003; 22: 535–546.
 46. Barboza JM, Dajani NK, Glenn LG, Angtuaco TL. Prenatal diagnosis of congenital cardiac anomalies: a practical approach using two basic views. *Radiographics* 2002; 22: 1125–1137; discussion 1137–1138.
 47. Del BA, Russo S, Lacerenza N, Rinaldi M, Rinaldi G, Nappi L, Greco P. Four chamber view plus three-vessel and trachea view for a complete evaluation of the fetal heart during the second trimester. *J Perinat Med* 2006; 34: 309–312.
 48. Carvalho JS, Doya E, Freeman J, Clough A. Identification of fetal laterality and visceral situs should be part of routine fetal anomaly scans. In *World Congress of Pediatric Cardiology and Cardiac Surgery*. Momma K, Imai Y (eds). Futura Pub. Co.: Honolulu, Hawaii, 1997; 117.
 49. Salomon LJ, Alfirevic Z, Berghella V, Bilardo CM, Chalouhi GE, Da Silva Costa F, Hernandez-Andrade E, Malinger G, Munoz H, Paladini D, Prefumo F, Sotiriadis A, Toi A, Lee W. ISUOG Practice Guidelines (updated): performance of the routine mid-trimester fetal ultrasound scan. *Ultrasound Obstet Gynecol* 2022; 59: 840–856.
 50. Bromley B, Estroff JA, Sanders SP, Parod R, Roberts D, Frigoletto FD, Jr., Benacerraf BR. Fetal echocardiography: accuracy and limitations in a population at high and low risk for heart defects. *Am J Obstet Gynecol* 1992; 166: 1473–1481.
 51. Stumpflen I, Stumpflen A, Wimmer M, Bernaschek G. Effect of detailed fetal echocardiography as part of routine prenatal ultrasonographic screening on detection of congenital heart disease. *Lancet* 1996; 348: 854–857.
 52. Yoo SJ, Lee YH, Kim ES, Ryu HM, Kim MY, Choi HK, Cho KS, Kim A. Three-vessel view of the fetal upper mediastinum: an easy means of detecting abnormalities of the ventricular outflow tracts and great arteries during obstetric screening. *Ultrasound Obstet Gynecol* 1997; 9: 173–182.
 53. Yoo SJ, Lee YH, Cho KS. Abnormal three-vessel view on sonography: a clue to the diagnosis of congenital heart disease in the fetus. *AJR Am J Roentgenol* 1999; 172: 825–830.
 54. Vinals F, Heredia F, Giuliano A. The role of the three vessels and trachea view (3VT) in the diagnosis of congenital heart defects. *Ultrasound Obstet Gynecol* 2003; 22: 358–367.
 55. Yagel S, Arbel R, Anteby EY, Raveh D, Achiron R. The three vessels and trachea view (3VT) in fetal cardiac scanning. *Ultrasound Obstet Gynecol* 2002; 20: 340–345.
 56. Tongsong T, Tongprasert F, Srisupundit K, Luewan S. The complete three-vessel view in prenatal detection of congenital heart defects. *Prenat Diagn* 2010; 30: 23–29.
 57. Berg C, Gembruch U, Geipel A. Outflow tract views in two-dimensional fetal echocardiography - part ii. *Ultraschall Med* 2009; 30: 230–251.
 58. Freud LR, Moon-Grady A, Escobar-Diaz MC, Gotteiner NL, Young LT, McElhinney DB, Tworetzky W. Low rate of prenatal diagnosis among neonates with critical aortic stenosis: insight into the natural history *in utero*. *Ultrasound Obstet Gynecol* 2015; 45: 326–332.
 59. Yamamoto Y, Hornberger LK. Progression of outflow tract obstruction in the fetus. *Early Hum Dev* 2012; 88: 279–285.
 60. Bronshtein M, Gover A, Zimmer EZ. Sonographic definition of the fetal situs. *Obstet Gynecol* 2002; 99: 1129–1130.
 61. Carvalho JS, Kyle PM. Images in cardiovascular medicine. Situs inversus with complete transposition in the fetus: diagnostic antenatal sequential segmental analysis. *Circulation* 1997; 96: 4432–4433.
 62. Cordes TM, O'Leary PW, Seward JB, Hagler DJ. Distinguishing right from left: a standardized technique for fetal echocardiography. *J Am Soc Echocardiogr* 1994; 7: 47–53.
 63. Allan LD, Tynan MJ, Campbell S, Wilkinson JL, Anderson RH. Echocardiographic and anatomical correlates in the fetus. *Br Heart J* 1980; 44: 444–451.
 64. Cook AC, Yates RW, Anderson RH. Normal and abnormal fetal cardiac anatomy. *Prenat Diagn* 2004; 24: 1032–1048.
 65. Yoo SJ, Min JY, Lee YH. Normal pericardial fluid in the fetus: color and spectral Doppler analysis. *Ultrasound Obstet Gynecol* 2001; 18: 248–252.
 66. Brown DL, Cartier MS, Emerson DS, Shanklin DR, Smith WC, Felker RE. The peripheral hypoechoic rim of the fetal heart. *J Ultrasound Med* 1989; 8: 603–608.
 67. Comstock CH. Normal fetal heart axis and position. *Obstet Gynecol* 1987; 70: 255–259.
 68. Smith RS, Comstock CH, Kirk JS, Lee W. Ultrasonographic left cardiac axis deviation: a marker for fetal anomalies. *Obstet Gynecol* 1995; 85: 187–191.
 69. Shipp TD, Bromley B, Hornberger LK, Nadel A, Benacerraf BR. Levorotation of the fetal cardiac axis: a clue for the presence of congenital heart disease. *Obstet Gynecol* 1995; 85: 97–102.
 70. Abdullah MM, Lacro RV, Smallhorn J, Chitayat D, van der Velde ME, Yoo SJ, Oman-Ganes L, Hornberger LK. Fetal cardiac dextroposition in the absence of an intrathoracic mass: sign of significant right lung hypoplasia. *J Ultrasound Med* 2000; 19: 669–676.
 71. Copel JA, Liang RI, Demasio K, Ozeren S, Kleinman CS. The clinical significance of the irregular fetal heart rhythm. *Am J Obstet Gynecol* 2000; 182: 813–817.
 72. Bet BB, de Vries JM, Limpens J, van Wely M, van Leeuwen E, Clur SA, Pajkrt E. Implications of fetal premature atrial contractions: systematic review. *Ultrasound Obstet Gynecol* 2022; 60: 721–730.
 73. Simpson JL, Yates RW, Sharland GK. Irregular heart rate in the fetus: not always benign. *Cardiol Young* 1996; 6: 28–31.
 74. Cuneo BF, Strasburger JF, Wakai RT, Ovadia M. Conduction system disease in fetuses evaluated for irregular cardiac rhythm. *Fetal Diagn Ther* 2006; 21: 307–313.
 75. Carvalho JS. Risk stratification for irregular fetal heart rhythm: practical approach to management. *Ultrasound Obstet Gynecol* 2022; 60: 717–720.
 76. American College of Obstetricians and Gynecologists. ACOG Practice Bulletin No. 106: Intrapartum fetal heart rate monitoring: nomenclature, interpretation, and general management principles. *Obstet Gynecol* 2009; 114: 192–202.
 77. Carvalho JS. Primary bradycardia: keys and pitfalls in diagnosis. *Ultrasound Obstet Gynecol* 2014; 44: 125–130.
 78. Carvalho JS. Fetal dysrhythmias. *Best Pract Res Clin Obstet Gynaecol* 2019; 58: 28–41.
 79. Mitchell JL, Cuneo BF, Etheridge SP, Horigome H, Weng HY, Benson DW. Fetal heart rate predictors of long QT syndrome. *Circulation* 2012; 126: 2688–2695.
 80. Srinivasan S, Strasburger J. Overview of fetal arrhythmias. *Curr Opin Pediatr* 2008; 20: 522–531.
 81. Hazelzet T, Durand I, David N. [Total isolated anomalous pulmonary venous return: Are there any clues for prenatal screening?]. *Gynecol Obstet Fertil* 2015; 43: 541–548.
 82. Kirk JS, Comstock CH, Lee W, Smith RS, Riggs TW, Weinhouse E. Fetal cardiac asymmetry: a marker for congenital heart disease. *Obstet Gynecol* 1999; 93: 189–192.
 83. Sharland GK, Chan KY, Allan LD. Coarctation of the aorta: difficulties in prenatal diagnosis. *Br Heart J* 1994; 71: 70–75.
 84. Hornberger LK, Sanders SP, Rein AJ, Spevak PJ, Parness IA, Colan SD. Left heart obstructive lesions and left ventricular growth in the midtrimester fetus. A longitudinal study. *Circulation* 1995; 92: 1531–1538.
 85. Paladini D, Pistorio A, Wu LH, Mecariello G, Lei T, Tuo G, Donarini G, Marasini M, Xie HN. Prenatal diagnosis of total and partial anomalous pulmonary venous connection: multicenter cohort study and meta-analysis. *Ultrasound Obstet Gynecol* 2018; 52: 24–34.
 86. Paladini D, Palmieri S, Lamberti A, Teodoro A, Martinelli P, Nappi C. Characterization and natural history of ventricular septal defects in the fetus. *Ultrasound Obstet Gynecol* 2000; 16: 118–122.
 87. Axt-Fliedner R, Schwarze A, Smrcek J, Germer U, Krapp M, Gembruch U. Isolated ventricular septal defects detected by color Doppler imaging: evolution during fetal and first year of postnatal life. *Ultrasound Obstet Gynecol* 2006; 27: 266–273.
 88. Vetraino IM, Lee W, Bronsteen RA, Comstock CH. Sonographic evaluation of the ventricular cardiac outflow tracts. *J Ultrasound Med* 2005; 24: 566.
 89. Everwijn SMP, van Nisselrooij AEL, Rozendaal L, Clur SB, Pajkrt E, Hruđa J, Linskens IH, van Lith JM, Blom NA, Haak MC. The effect of the introduction of the three-vessel view on the detection rate of transposition of the great arteries and tetralogy of Fallot. *Prenat Diagn* 2018; 38: 951–957.

90. Bravo C, Gamez F, Perez R, Alvarez T, De Leon-Luis J. Fetal Aortic Arch Anomalies: Key Sonographic Views for Their Differential Diagnosis and Clinical Implications Using the Cardiovascular System Sonographic Evaluation Protocol. *J Ultrasound Med* 2016; 35: 237–251.
91. Karl K, Sinkovskaya E, Abuhamad A, Chaoui R. Intrathymic and other anomalous courses of the left brachiocephalic vein in the fetus. *Ultrasound Obstet Gynecol* 2016; 48: 464–469.
92. Galindo A, Gutierrez-Larraya F, Escibano D, Arbus J, Velasco JM. Clinical significance of persistent left superior vena cava diagnosed in fetal life. *Ultrasound Obstet Gynecol* 2007; 30: 152–161.
93. Durand I, Hazelzet T, Gillibert A, Parrod C, David N, El Youssef F, Brehin AC, Barre E. Outcomes following prenatal diagnosis of isolated persistent left superior vena cava. *Arch Cardiovasc Dis* 2022; 115: 335–347.
94. Lopes KRM, Bartsota M, Dougherty V, Carvalho JS. Single left superior vena cava: antenatal diagnosis, associated anomalies and outcomes. *Ultrasound Obstet Gynecol* 2022; 60: 640–645.
95. Chaoui R, Heling KS, Lopez AS, Thiel G, Karl K. The thymic-thoracic ratio in fetal heart defects: a simple way to identify fetuses at high risk for microdeletion 22q11. *Ultrasound Obstet Gynecol* 2011; 37: 397–403.
96. Paladini D. How to identify the thymus in the fetus: the thy-box. *Ultrasound Obstet Gynecol* 2011; 37: 488–492.
97. Karl K, Heling KS, Sarut Lopez A, Thiel G, Chaoui R. Thymic-thoracic ratio in fetuses with trisomy 21, 18 or 13. *Ultrasound Obstet Gynecol* 2012; 40: 412–417.
98. Anton T, Sklansky MS, Perez M, Pretorius DH. The Fetal 3-Vessel Views: An Illustrative Case-Based Tutorial. *J Ultrasound Med* 2019; 38: 3335–3347.
99. Yagel S, Cohen SM, Achiron R. Examination of the fetal heart by five short-axis views: a proposed screening method for comprehensive cardiac evaluation. *Ultrasound Obstet Gynecol* 2001; 17: 367–369.
100. Sun HY, Proudfoot JA, McCandless RT. Prenatal detection of critical cardiac outflow tract anomalies remains suboptimal despite revised obstetrical imaging guidelines. *Congenit Heart Dis* 2018; 13: 748–756.
101. Sklansky MS, Berman DP, Pruetz JD, Chang RK. Prenatal screening for major congenital heart disease: superiority of outflow tracts over the 4-chamber view. *J Ultrasound Med* 2009; 28: 889–899.
102. Jain S, Kleiner B, Moon-Grady A, Hornberger LK. Prenatal diagnosis of vascular rings. *J Ultrasound Med* 2010; 29: 287–294.
103. Chaoui R, McEwing R. Three cross-sectional planes for fetal color Doppler echocardiography. *Ultrasound Obstet Gynecol* 2003; 21: 81–93.
104. Paladini D. Sonography in obese and overweight pregnant women: clinical, medicolegal and technical issues. *Ultrasound Obstet Gynecol* 2009; 33: 720–729.
105. Sklansky M, Afshar Y, Anton T, DeVore GR, Platt L, Satou G. Guidance for fetal cardiac imaging in patients with degraded acoustic windows. *Ultrasound Obstet Gynecol* 2022; 59: 709–712.
106. Nadel AS. Addition of color Doppler to the routine obstetric sonographic survey aids in the detection of pulmonic stenosis. *Fetal Diagn Ther* 2010; 28: 175–179.
107. Small M, Copel JA. Indications for fetal echocardiography. *Pediatr Cardiol* 2004; 25: 210–222.
108. Mavrides E, Cobian-Sanchez F, Tekay A, Moscoso G, Campbell S, Thilaganathan B, Carvalho JS. Limitations of using first-trimester nuchal translucency measurement in routine screening for major congenital heart defects. *Ultrasound Obstet Gynecol* 2001; 17: 106–110.
109. Ghi T, Huggon IC, Zosmer N, Nicolaides KH. Incidence of major structural cardiac defects associated with increased nuchal translucency but normal karyotype. *Ultrasound Obstet Gynecol* 2001; 18: 610–614.
110. Hyett JA, Perdu M, Sharland GK, Snijders RS, Nicolaides KH. Increased nuchal translucency at 10–14 weeks of gestation as a marker for major cardiac defects. *Ultrasound Obstet Gynecol* 1997; 10: 242–246.
111. Rychik J, Donaghue DD, Levy S, Fajardo C, Combs J, Zhang X, Szwasz A, Diamond GS. Maternal psychological stress after prenatal diagnosis of congenital heart disease. *J Pediatr* 2013; 162: 302–307.e1.
112. Cabana MD, Rand CS, Powe NR, Wu AW, Wilson MH, Abboud PA, Rubin HR. Why don't physicians follow clinical practice guidelines? A framework for improvement. *JAMA* 1999; 282: 1458–1465.
113. Sklansky M, DeVore GR. Fetal Cardiac Screening: What Are We (and Our Guidelines) Doing Wrong? *J Ultrasound Med* 2016; 35: 679–681.
114. Salomon LJ, Winer N, Bernard JP, Ville Y. A score-based method for quality control of fetal images at routine second-trimester ultrasound examination. *Prenat Diagn* 2008; 28: 822–827.
115. Sairam S, Awadh AM, Cook K, Papageorgiou AT, Carvalho JS. Impact of audit of routine second-trimester cardiac images using a novel image-scoring method. *Ultrasound Obstet Gynecol* 2009; 33: 545–551.
116. Quarello E, Lafouge A, Fries N, Salomon LJ, CFEF. Basic heart examination: feasibility study of first-trimester systematic simplified fetal echocardiography. *Ultrasound Obstet Gynecol* 2017; 49: 224–230.
117. Letourneau KM, Horne D, Soni RN, McDonald KR, Karlicki FC, Fransoo RR. Advancing Prenatal Detection of Congenital Heart Disease: A Novel Screening Protocol Improves Early Diagnosis of Complex Congenital Heart Disease. *J Ultrasound Med* 2018; 37: 1073–1079.
118. Volpe P, Ubaldo P, Volpe N, Campobasso G, De Robertis V, Tempesta A, Volpe G, Rembouskos G. Fetal cardiac evaluation at 11–14 weeks by experienced obstetricians in a low-risk population. *Prenat Diagn* 2011; 31: 1054–1061.
119. Smrcek JM, Berg C, Geipel A, Fimmers R, Diedrich K, Gembruch U. Early fetal echocardiography: heart biometry and visualization of cardiac structures between 10 and 15 weeks' gestation. *J Ultrasound Med* 2006; 25: 173–182.
120. Yagel S, Cohen SM, Porat S, Daum H, Lipschuetz M, Amsalem H, Messing B, Valsky DV. Detailed transabdominal fetal anatomic scanning in the late first trimester versus the early second trimester of pregnancy. *J Ultrasound Med* 2015; 34: 143–149.
121. Salvesen K, Abramowicz J, Ter Haar G, Miloro P, Sinkovskaya E, Dall'Asta A, Marsal K, Lees C, Board of the International Society of Ultrasound in Obstetrics and Gynecology. ISUOG statement on the safe use of Doppler for fetal ultrasound examination in the first 13 + 6 weeks of pregnancy (updated). *Ultrasound Obstet Gynecol* 2021; 57: 1020.
122. Sinkovskaya ES, Chaoui R, Karl K, Andreeva E, Zhuchenko L, Abuhamad AZ. Fetal cardiac axis and congenital heart defects in early gestation. *Obstet Gynecol* 2015; 125: 453–460.
123. Wiehche M, Knafel A, Nocun A. Prenatal detection of congenital heart defects at the 11- to 13-week scan using a simple color Doppler protocol including the 4-chamber and 3-vessel and trachea views. *J Ultrasound Med* 2015; 34: 585–594.
124. Ghimire LV, Chou FS, Moon-Grady AJ. Risk of congenital heart disease is increased among newborns with non-cardiac congenital anomalies: survey-based analysis using 2016 Kids' Inpatient Database. *Ultrasound Obstet Gynecol* 2021; 57: 841–842.

SUPPORTING INFORMATION ON THE INTERNET

The following supporting information may be found in the online version of this article:



Figure S1 Sagittal views of aorta are part of fetal echocardiography, but, in some institutions, these views are required or recommended as part of screening obstetric examination. This can be achieved on both grayscale (a) and color Doppler or bidirectional power Doppler (b) imaging. In this view, the three aortic branches can be seen: brachiocephalic artery (1), left common carotid artery (2) and left subclavian artery (3).

Figure S2 Four-chamber view can be used to visualize two of the four pulmonary veins (open arrows) connecting with left atrium (LA). Examiners experienced with color Doppler can additionally use color or bidirectional power Doppler to visualize draining of these veins into LA. Note that distance between aorta and LA is small. dAo, descending aorta.

APPENDICES

Appendix 1 Checklist for cardiac screening

Upper abdomen			
	Stomach on left	<input type="checkbox"/> Yes	<input type="checkbox"/> No
Four-chamber view			
General	Heart on left, axis -45°	<input type="checkbox"/> Yes	<input type="checkbox"/> No
	Heart area $\leq \frac{1}{3}$ chest area	<input type="checkbox"/> Yes	<input type="checkbox"/> No
	Regular rhythm, rate 120–160 bpm	<input type="checkbox"/> Yes	<input type="checkbox"/> No
Atria	Approximately equal in size	<input type="checkbox"/> Yes	<input type="checkbox"/> No
	Patent foramen ovale; foramen ovale flap valve in left atrium	<input type="checkbox"/> Yes	<input type="checkbox"/> No
	At least one pulmonary vein entering left atrium	<input type="checkbox"/> Yes	<input type="checkbox"/> No
Atrioventricular junction	Two separate valves that open and close freely	<input type="checkbox"/> Yes	<input type="checkbox"/> No
	Tricuspid valve more apical than mitral valve (normal valve offset)	<input type="checkbox"/> Yes	<input type="checkbox"/> No
Ventricles	Approximately equal in size	<input type="checkbox"/> Yes	<input type="checkbox"/> No
	Moderator band at apex of right ventricle	<input type="checkbox"/> Yes	<input type="checkbox"/> No
	Septum appears intact	<input type="checkbox"/> Yes	<input type="checkbox"/> No
Left ventricular outflow-tract view			
	Vessel in continuity with ventricular septum and does not bifurcate	<input type="checkbox"/> Yes	<input type="checkbox"/> No
	Aortic valve leaflets not thickened, open and close freely	<input type="checkbox"/> Yes	<input type="checkbox"/> No
Right ventricular outflow-tract view/three-vessel view			
	Vessel arising from right ventricle is anterior to aorta and bifurcates	<input type="checkbox"/> Yes	<input type="checkbox"/> No
	Great arteries crossover	<input type="checkbox"/> Yes	<input type="checkbox"/> No
	Pulmonary valve leaflets are not thickened, open and close freely	<input type="checkbox"/> Yes	<input type="checkbox"/> No
Three-vessel-and-trachea view			
	V-sign (ductal and aortic arches to left of trachea)	<input type="checkbox"/> Yes	<input type="checkbox"/> No
	Ductal and aortic arches similar in size	<input type="checkbox"/> Yes	<input type="checkbox"/> No

Appendix 2 Grades of recommendation and levels of evidence used in ISUOG Guidelines

Classification of evidence levels

1++	High-quality meta-analyses, systematic reviews of randomized controlled trials or randomized controlled trials with very low risk of bias
1+	Well-conducted meta-analyses, systematic reviews of randomized controlled trials or randomized controlled trials with low risk of bias
1–	Meta-analyses, systematic reviews of randomized controlled trials or randomized controlled trials with high risk of bias
2++	High-quality systematic reviews of case–control or cohort studies or high-quality case–control or cohort studies with very low risk of confounding, bias or chance and high probability that the relationship is causal
2+	Well-conducted case–control or cohort studies with low risk of confounding, bias or chance and moderate probability that the relationship is causal
2–	Case–control or cohort studies with high risk of confounding, bias or chance and significant risk that the relationship is not causal
3	Non-analytical studies, e.g. case reports, case series
4	Expert opinion

Grades of recommendation

A	At least one meta-analysis, systematic review or randomized controlled trial rated as 1++ and applicable directly to the target population; or a systematic review of randomized controlled trials or a body of evidence consisting principally of studies rated as 1+ applicable directly to the target population and demonstrating overall consistency of results
B	Body of evidence including studies rated as 2++ applicable directly to the target population and demonstrating overall consistency of results; or extrapolated evidence from studies rated as 1++ or 1+
C	Body of evidence including studies rated as 2+ applicable directly to the target population and demonstrating overall consistency of results; or extrapolated evidence from studies rated as 2++
D	Evidence level 3 or 4; or evidence extrapolated from studies rated as 2+
Good practice point	Recommended best practice based on the clinical experience of the Guidelines development group
