

Original article

doi: 10.17223/25421379/26/4

METAPODIAL PATHOLOGY OF ANCIENT UNGULATES

Andrei V. Shpansky¹, Anastasia V. Aidos (Novik)², Larisa S. Sapunova³,
Sergei V. Saveliev⁴, Aleksei A. Bondarev⁵



^{1,2} National Research Tomsk State University, Tomsk, Russia

¹ V.S. Sobolev Institute of Geology and Mineralogy SB RAS, Novosibirsk, Russia

³ Cancer Clinic of Tomsk National Research Medical Centre SB RAS, Tomsk, Russia

⁴ Institute of Human Morphology the Russian Academy of Sciences, Moscow, Russia

⁵ Omsk regional branch of the Russian Geographical Society, Omsk, Russia.

¹ Shpansky@ggf.tsu.ru; andreypshpansky@yandex.ru

² novik.anastasia@mail.ru

⁴ embrains@hotmail.com

⁵ gilgamesh-lugal@mail.ru

Abstract. This report describes pathological changes of twelve metapodial bones of ancient large ungulates (*Bison priscus*, *Cervus elaphus*, *Megaloceros giganteus*, *Equus ex gr. gallicus*) from various sites in West Siberia. Two basic types of deteriorations were observed: proximal epiphyseal deformity resulting from arthrosis, and periosteal proliferations on diaphysis. All of these likely are related to trauma. The most probable causes of the injuries include unsuccessful hunting activity of cave lions and environment-associated sharp or blunt force.

Keywords: metapodial, traumatic pathology, periostosis, palaeoecology, predation, *Panthera spelaea*

Acknowledgments: Authors express a sincere gratitude to Dennis F. Lawler (Adjunct in paleopathology, Illinois State Museum; Adjunct Professor of Biology, Southern Illinois University; Associate Editor, International Journal of Paleopathology) for their help in analysis of the described cases of pathologic changes and proofreading. Authors are thankful to the head of radiology department of №2 of the Multipurpose centre of modern medicine "Evromed" D.A. Skripkin for the help in CT research, and the head of the "Arkhaika" studio N.V. Peristov for providing the samples from Ishym district of Omsk province for research.

Source of financing: The research was supported by RSF (project No. 22-17-00140).

For citation: Shpansky A.V., Aidos (Novik) A.V., Sapunova L.S., Saveliev S.V., Bondarev A.A. (2023) Metapodial pathology of ancient Ungulates. *Geosfernye issledovaniya – Geosphere Research*. 1. pp. 51–67. doi: 10.17223/25421379/26/4

Научная статья

УДК 569.6

doi: 10.17223/25421379/26/4

ПАТОЛОГИИ МЕТАПОДИЙ ДРЕВНИХ КОПЫТНЫХ

Андрей Валерьевич Шпанский¹, Анастасия Вячеславовна Айдос (Новик)²,
Лариса Станиславовна Сапунова³, Сергей Вячеславович Савельев⁴,
Алексей Анатольевич Бондарев⁵

^{1,2} Национальный исследовательский Томский государственный университет, Томск, Россия

¹ Институт геологии и минералогии им. В.С. Соболева СО РАН, Новосибирск, Россия

³ Онкологический диспансер Томского национального исследовательского медицинского центра СО РАН, Томск, Россия.

⁴ Институт морфологии человека РАН, Москва, Россия

⁵ Омское региональное отделение Русского географического общества, Омск, Россия

¹ Shpansky@ggf.tsu.ru; andreypshpansky@yandex.ru

² novik.anastasia@mail.ru

⁴ embrains@hotmail.com

⁵ gilgamesh-lugal@mail.ru

Аннотация. Описано 12 случаев патологических изменений на метаподиальных костях крупных копытных (*Bison priscus*, *Cervus elaphus*, *Megaloceros giganteus*, *Equus ex gr. gallicus*) мамонтовой фауны из местонахождений Западной Сибири. Изменения на костях двух типов – деформации проксимальных эпифизов в результате развития артрозов и раз-

растания на диафизах. Возникновение всех патологий связывается с травмированием животных. Наиболее вероятной причиной получения травм являются неудачные охоты *Panthera spelaea*.

Ключевые слова: метаподии, травматические патологии, периостит, палеоэкология, охоты, *Panthera spelaea*

Благодарности: Авторы выражают искреннюю благодарность Деннису Ф. Лоулеру (адъюнкт-профессор палеопатологии Государственного музея Иллинойса; адъюнкт-профессор биологии Университета Южного Иллинойса; заместитель редактора International Journal of Paleopathology) за его помощь в анализе описанных случаев патологических изменений и корректуре текста. Авторы выражают благодарность заведующему отделением лучевой диагностики № 2 МЦСМ «Евромед» Д.А. Скрипкину за помощь в проведении томографического исследования, руководителю студии «Архаика» Н.В. Перистову за предоставление коллекционных образцов (Усть-Ишимский р-н Омской области) для исследования.

Источник финансирования: Исследование выполнено при поддержке Российского научного фонда (проект № 22-17-00140).

Для цитирования: Shpansky A.V., Aidos (Novik) A.V., Sapunova L.S., Saveliev S.V., Bondarev A.A. (2023) Metapodial pathology of ancient Ungulates // Геосферные исследования. 2023. № 1. С. 51–67. doi: 10.17223/25421379/26/4

1. Introduction

Pathological changes occur rather frequently on teeth and postcranial bones of large fossil mammals, including Quaternary fauna. However, descriptions of such pathological changes for fossil mammals are rare in literature. Therefore, their causes have not been studied, despite the long history of this research [Moodie, 1923; Tasnadi-Kubacska, 1962; Rothschild, Martin, 1993]. The majority of the pathologies have been noted previously, either for teeth of *Mammuthus primigenius* (Blumenbach, 1799) from Siberia [Mashchenko, Shpansky, 2005; Shpansky, 2014a], or on the backbone of *Megaloceros giganteus* (Blumenbach, 1799) [Shpansky, 2014b], *M. primigenius*, and *Mammuthus trogontherii trogontherii* (Pohlig, 1885) [Bondarev, 2006; Shpansky et al. 2015b]. The unique case of an ankle (hock) joint fusion in *Mammuthus trogontherii chosaricus* Dubrovo, 1966 also has been described [Shpansky et al., 2015a]. In the latter, the cause of the bone ankyloses in this individual could have been the valgus subluxation of the pes, followed by purulent inflammation of the degenerating cartilage of the joint and a fusion of the adjacent articular surfaces. It is possible also that this feature occurred without purulence, since advanced arthrosis does not require infection and pus production. Fused fractures and osteoarthritis have been mentioned for metapodials of artiodactyls and horses [Gadjiev, Gadjiev, 1955; Yatsko, 1962; Skorik, 1979; Roberts et al., 2004; Udrescu, Van Neer, 2005; Dzierzecka et al., 2008; Thomas, Grimm, 2011; Bendrey, 2014; Salmi, Niinimäki, 2016], and tibia of the bison [Kierdorf et al., 2012], as results of different injuries.

In this report, we consider a case series of pathological changes on metapodials of large artiodactyls and horses, from the localities of West Siberia are considered in the present paper. The analysis of pathologies on the fossil material can help assessment of environmental

conditions, animal behaviour, and biotic relationships among different taxa in the ecosystems. One of the probable causes of the metapodial pathology of the Late Pleistocene large ungulates could be unsuccessful hunts of large carnivores that include, first of all, the cave lion, and probably cave hyena and wolf as well.

Institutional Abbreviation – PM TSU, Paleontological Museum of Tomsk State University (Tomsk); OSMHRS, Omsk State Museum of History and Regional Studies (Omsk).

2. Materials and methods

Twelve large ungulate metapodials with pathologies were selected from various localities in south-east of West Siberia: nine specimens from Krasniy Yar locality (Tomsk Province) and three specimens from Ust'-Ishym (Omsk Province). Eleven bones with completely fused epiphyses (listed below) are referred to as adult individuals. One specimen (PM TSU 5/3263) a juvenile. The specimens were chosen due to close geological ages (Late Pleistocene; Shpansky, Kuzmin, 2021), anatomical position in the skeleton (metapodials), similar changes in the bones (asymmetrical abnormal observations) and thus, perhaps common reasons for the pathology.

Bison priscus Bojanus: metacarpal PM TSU 5/3386; metatarsals PM TSU 5/3264, 5/4283, 5/5226, 5/3265, 5/3263, 5/2485 Krasniy Yar (Tomsk Province); OSMHRS 15914/1 PK 2254 (Ust'-Ishym district, Omsk Province).

Megaloceros giganteus Blumenbach: metacarpal PM TSU 5/3377 Krasniy Yar (Tomsk Province).

Cervus elaphus Linnaeus: metatarsal OSMHRS 15914/2 PK 2255 (Ust'-Ishym district, Omsk Province).

Equus ex gr. gallicus Prath: metatarsals PM TSU 5/5413, Krasniy Yar site (Tomsk Province), OSMHRS 15914/3 PK 2256 (Ust'-Ishym district, Omsk Province).

Several previously described similar distal limb pathologies of Pleistocene and recent ungulates have been

referred to for comparison: metatarsal of *Cervus elaphus* Linnaeus, 1758 [Gadjiev, Gadjiev, 1955]; metapodials of horses and moose [Skorik, 1979]; tibia of bison [Kierdorf et al., 2012]; metacarpals of the goat [Bendrey, 2014] and sheep [Thomas, Grimm, 2011]; and radii and metapodials of Late Pleistocene *Paracamelus* [Yatsko, 1962].

Methods. Evaluations included overall description of the bone and comparison with healthy analogues, assessment of typology of the remains, foci of pathological changes, and specific pathology characteristics (inner and outer changes in the bone, and morphometry). In the most complex cases, spiral computer tomography was applied to examine the internal bone structure. The same approach was used for a healthy bison bone (PM TSU 5/5117) for comparison.

Imaging studies were carried out using Computed Tomography (Siemens Emotion 6CT 2007E; Cancer Clinic of Tomsk National Research Medical Centre Siberian Branch of the Russian Academy of Sciences, Tomsk) and Siemens Somatom Definition Flash (Multi-purpose centre of modern medicine "Euromed", Omsk). The standard software was used in the processing of images. The thickness of the slice in the dorsal (axial) plane for specimens PM TSU 5/2485, 5/3263, 5/3264, 5/4283 was 1.0 mm; for PM TSU 5/3265 and 5/5117 is 0.8 mm; and for OSMHRS 15914/1 PK 2254 is 0.4 mm. Post-processing included modelling of images in sagittal and transversal planes, and 3D reconstructions in the InVesalius 3.0 program. Measurements of bones and pathologies were made using a calliper with accuracy to 0.1 mm. Dimensional characteristics of abnormal bones were compared with a representative series of similar "normal" bones of *Bison priscus*, *Equus ex gr. gallicus*, *Megaloceros giganteus*, and *Cervus elaphus* from Krasniy Yar (Tomsk Province).

Palaeoecological analysis was based on (a) physical and geographical features of the environment at the end of the Late Pleistocene in the territory of West Siberian Plane; (b) on the anatomy and exterior features of the large ungulates that we evaluated; and (c) on comparative typology of pathological changes on the studied bones, including sizes, shapes, positions of changes on the bones, and anatomical position of the pathological bones in the skeleton. On this bases were developed several hypotheses regarding the possible causes for the pathological changes.

Panthera spelaea (Goldfuss, 1810) was the largest and the most active carnivore of Mammoth fauna. Observations of the modern lion (*Panthera leo* (Linnaeus, 1758) were used as an ecological analogue. Hunting strategies and attacks on victims of the modern African lion were examined by one of the authors (S.V. Saveliev) in the territory of Kruger National Park (Republic

of South Africa) in 1998-1999. Documentary video materials were used to support our evaluations. The strategy of modern lions' hunting was described briefly by Kingdon [1977]. Topographic distribution of trauma to giraffes, according to frequency of lion attacks, was presented on the materials from Serengeti National Park [Strauss, Packer, 2013]. The analysis of cave lion hunting techniques was carried out considering the natural conditions in the Late Pleistocene in the south of West Siberian Plane, and morphology and appearance of the hunting objects (*Bison priscus*, *Megaloceros giganteus* and *Equus ex gr. gallicus*). The data considering the hunting of cave lions, gathered by R. Guthrie [1990] during the study of the bison "Blue Babe" carcass from Alaska in 1979, were used in the palaeoecological analysis. Collagen radiocarbon age of that specimen is 36,425 BP (QC-891), estimated Blue Babe's age-at-death to be 8 to 9 years.

3. Results

In our view, a probable important cause of the lesions was hunting activities of large predators, although other environment-sourced trauma do remain a part of the differential diagnoses as well.

3.1. Description of bones

Bison priscus: Left metatarsal (Fig. 1) PM TSU 5/3386. The bone has two local lesions of the cortical layer. One of them is thin, linearly elongated, roller-shaped, oriented perpendicular to the long axis on the dorsal surface of the diaphysis proximal third. The lesion is 31 mm long and 10 mm wide. The second lesion is oval-shaped (33 × 18 mm). It is located in the middle of the diaphysis, medially to the dorsal longitudinal groove, oriented along the diaphysis. The distance between the two lesions is 27 mm. The overall sizes of the bone correspond to male individual of the average size from Krasniy Yar (Table 1).

Right metatarsal (Fig. 2) PM TSU 5/3264. A round-shaped lesion on the lateral side in the middle third of diaphysis is 44 mm in diameter.

Right metatarsal (Fig. 3) PM TSU 5/4283. An oval-shaped lesion is on the lateral side in the middle third of diaphysis (45 × 37 mm).

Left metatarsal (Fig. 4) PM TSU 5/5226. The diaphysis carries the longitudinal ridge-shaped lesion on the left side. It extends from the distal epiphyseal suture up to the first third of the diaphysis length (42 × 15 mm).

Left metatarsal (Fig. 5) PM TSU 5/3265. The bone has a large oval-shaped lesion. The length is 96 mm, the transverse diameter is 79 mm. The surface on the medial side is smooth, while on the medio-plantar it is tuberos with developed grooves and ridges. The joint surface is not deformed (Fig. 5, d).

Left metatarsal (Fig. 6) PM TSU 5/3263 from a semi-adult animal, aged 2–3 years. The distal epiphysis is not fused, but nevertheless the bone is large. Its length without the distal epiphysis is comparable to one of the adult, also measured on the distal end of the diaphysis. The proximal part of the bone is deformed due to remodelling of the upper part of diaphysis and proximal epiphysis. Most of the changes occurred on the dorsal and medial sides. Articular surfaces are rimmed (photo d) suggesting a degree of osteoarthritis. The joint facet for centrotarsale is concave and surrounded by the heavy hyperostosis of the cortical layer. Joint surfaces are smooth.

Left metatarsal (Fig. 7) PM TSU 5/2485. The distal part of the bone is damaged; lateral and medial condyles were broken during the burial process or thereafter. The proximal part reveals deformity. There is a large knob-shaped mass on the medial side. The dorsal and lateral parts of the epiphysis are greatly widened and flattened. It appears that the fusion process between the metatarsale III–IV and centrotarsale may have started, as suggested by the lack of the joint facet with centrotarsale and the tuberculous finely serrated surface of the proximal end. There appears to have been significant loss of overlying joint cartilage. The width of the proximal end on the outer edge of the lesion is 88 mm, while the diaphysis width (42.5 mm) is typical for the average male individuals (Table 2).

Right metatarsal (Fig. 8) OSMHRS PK 2254. The bone reveals an oval-shaped lesion along the long axis of the diaphysis (60 × 25 mm). The lesion is located dorsolaterally on the proximal half of the diaphysis. Its upper margin is 65 mm from the proximal end of the bone, and it is convex more laterally than dorsally. It reaches the maximum height (around 4.5–5 mm relative to the intact bone surface) at 80–86 mm from the proximal end of the bone. The bone surface also reveals a poorly defined ridge that stretches above the lesion along the lateral side of the diaphysis. The edge of the lesion is smooth, straight along the dorsal groove and penetrating into the groove up to 2 mm, forming a slightly visible shelf. There is a poorly defined longitudinal crest on the medial edge of the dorsal groove at the same level of the lesion, which probably is a part of the pathological process. The total width of the diaphyseal lesion, including this crest, is 34 mm. There are two vessel foramina about 1 mm in diameter each on the proximal margin along the longitudinal axis of the bone. The lateral surface of the lesion is furrowed with thin transverse grooves.

General parameters of *B. priscus* metatarsals are listed in the table 2. All of the bones are comparable to the male individuals from Krasniy Yar locality (Tomsk Province) [Shpansky et al., 2016].

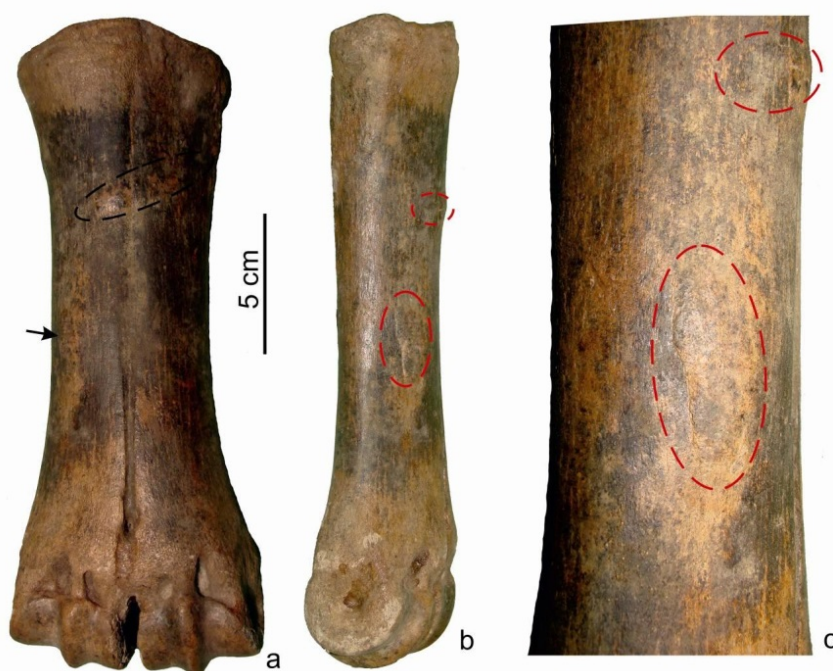

Fig. 1. Metacarpal of *Bison priscus* PM TSU 5/3386 from Krasniy Yar (Tomsk Province)
 a – dorsal view; b – medial view; c – diaphysis with marked areas of hyperostosis

Рис. 1. Пястная кость *Bison priscus* ПМ ТГУ 5/3386 из Красного Яра (Томская область)
 а – вид сзади; б – вид медиальный; в – диафиз с отмеченными участками гиперостоза

Table 1

Metacarpals of *Bison priscus* from Krasniy Yar (Tomsk Province)

Таблица 1

Промеры метакарпальных костей *Bison priscus* из Красного Яра (Томская область)

Measurements, mm	Pathology	Normal [Shpansky et al., 2016]		
	PM TSU 5/3386 left	♀, PM TSU 8/16 left, 8/38 right	♀, PM TSU, n = 41	♂, PM TSU, n = 94
Largest length	232	236	220–249	217.5–261
Media-lateral width of the proximal end	82.5	83, 84	70–83	76.6–103
Largest transversal width of the proximal end	45	46.5, 47	38.5–49.5	42–60
The smallest media-lateral width of the diaphysis	57.4	45, 45.4	43–52	50–67
Media-lateral width of the distal end	89.6	84.5, 86	74–90	80–108
Transversal width of the distal end	44	45, 46	37.3–47	39.5–57
Index of breadth of the diaphysis (4 : 1)	24.7	19.1, 19.2	17.9–22	22.2–27.4

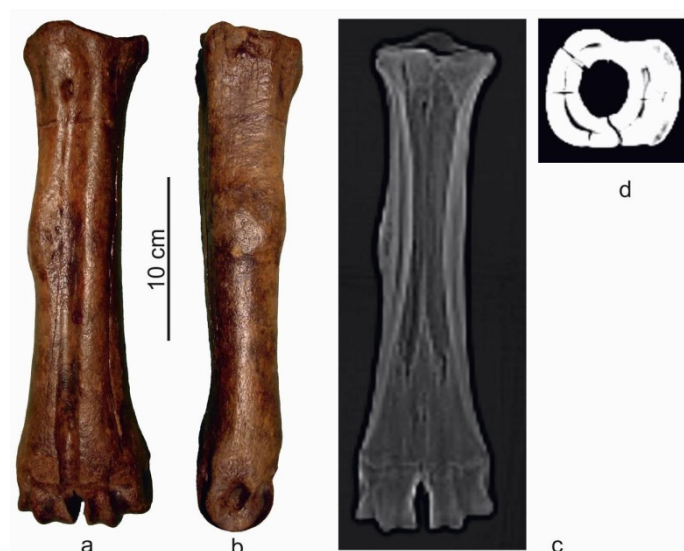

Fig. 2. Metacarpal of *Bison priscus* PM TSU 5/3264 from Krasniy Yar (Tomsk Province)

a – dorsal view; b – lateral view; the fragment of CT image: c – in frontal plane; d – in axial plane

Рис. 2. Пястная кость *Bison priscus* ПМ ТГУ 5/3264 из Красного Яра (Томская область)

a – вид сзади; b – вид сбоку; фрагмент КТ-изображения: c – во фронтальной плоскости; d – в осевой плоскости

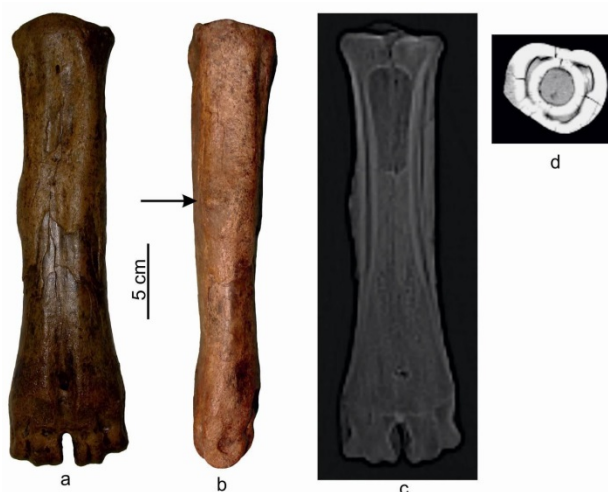

Fig. 3. Metatarsal of *Bison priscus* PM TSU 5/4283 from Krasniy Yar (Tomsk Province)

a – dorsal view; b – lateral view; c – the fragment of CT image in axial plane

Рис. 3. Плюсна *Bison priscus* ПМ ТГУ 5/4283 из Красного Яра (Томская область)

a – вид сзади; b – вид сбоку; фрагмент КТ-изображения: c – во фронтальной плоскости; d – в осевой плоскости

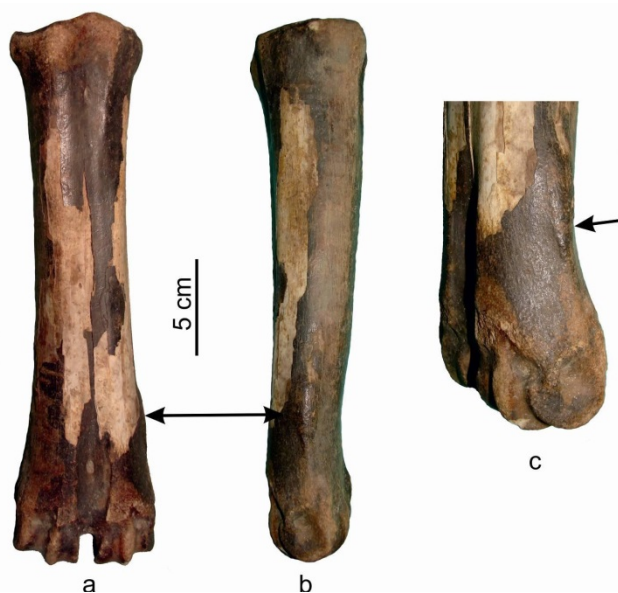
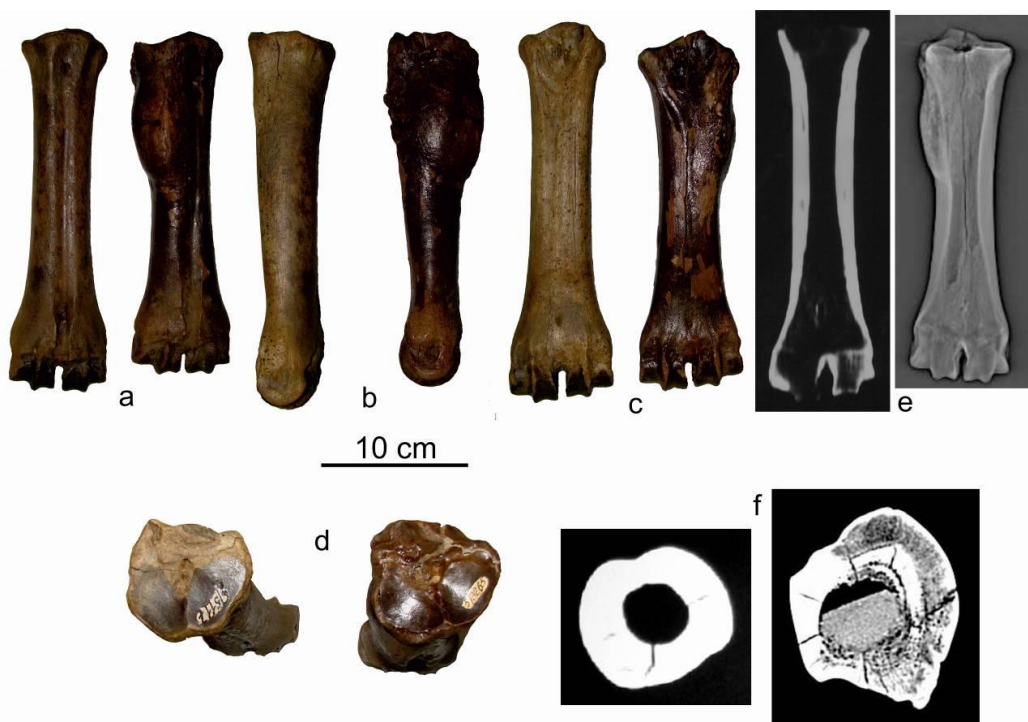


Fig. 4. Metatarsal of *Bison priscus* PM TSU 5/5226 from Krasniy Yar (Tomsk Province)
 a – dorsal view; b – lateral view; c – lateral side of the distal part

Рис. 4. Плюсна *Bison priscus* ПМ ТГУ 5/5226 из Красного Яра (Томская область):
 а – вид сзади; и – вид сбоку; с – боковая сторона дистальной части



**Fig. 5. Metatarsals of *Bison priscus* PM TSU 5/3265 (a₂–f₂)
 и PM TSU 5/5117 (a₁–f₁) from Krasniy Yar (Tomsk Province)**
 a – dorsal view; b – medial view; c – plantar view; d – proximal view; CT image fragment: e – in frontal plane; f – in axial plane

**Рис. 5. Плюсневые кости *Bison priscus* ПМ ТГУ 5/3265 (a₂–f₂) и ПМ ТГУ 5/5117 (a₁–f₁)
 из Красного Яра (Томская область)**
 а – вид сзади; б – медиальный вид; с – подошвенный вид; д – проксимальный вид; Фрагмент КТ-изображения: е – во фронтальной плоскости; ф – в осевой плоскости

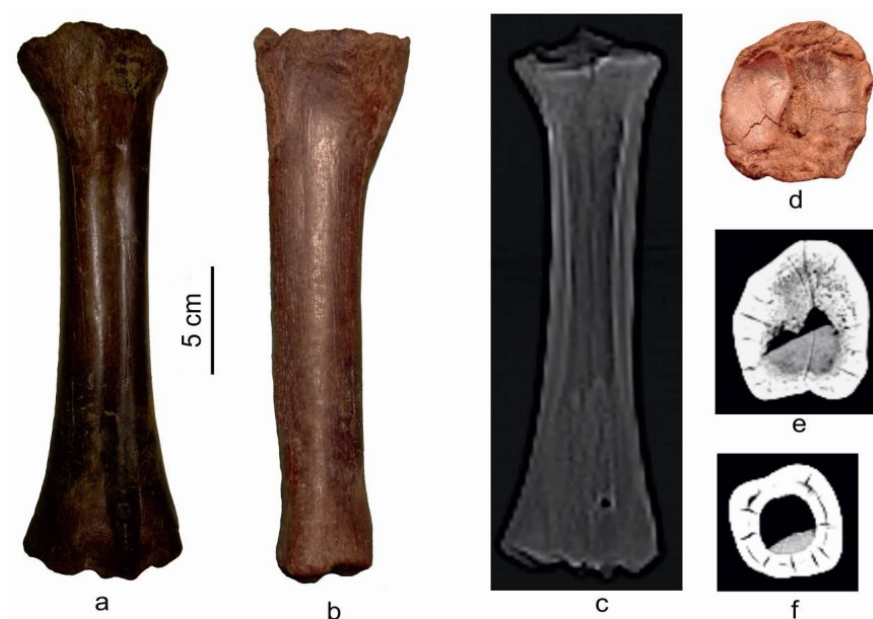


Fig. 6. Metatarsal of *Bison priscus* PM TSU 5/3263 from Krasniy Yar (Tomsk Province)

a – dorsal view; b – medial view; d – proximal view; CT image fragment: c – in frontal plane; in axial plane: e – in proximal part of the diaphysis; f – in the middle of diaphysis

Рис. 6. Плюсна *Bison priscus* ПМ ТГУ 5/3263 из Красного Яра (Томская область)

a – вид сзади; b – вид медиальный; d – вид проксимальный; фрагмент КТ-изображения: c – во фронтальной плоскости; в аксиальной плоскости: e – в проксимальной части диафиза; f – в середине диафиза

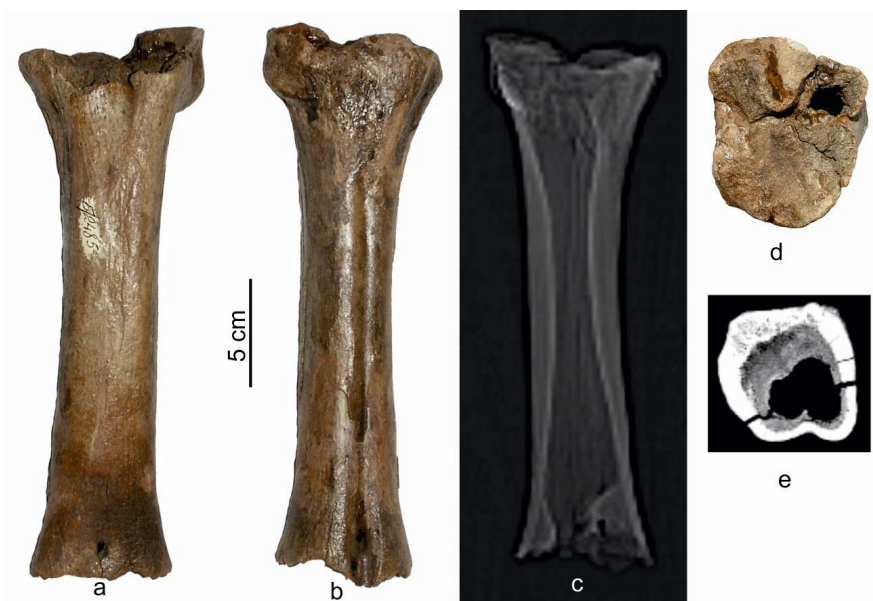

Fig. 7. Metatarsal of *Bison priscus* PM TSU 5/2485 from Krasniy Yar (Tomsk Province):

a – plantar view; b – dorsal view; d – proximal view; CT image fragment: c – in frontal plane; e – proximal part of the diaphysis in axial plane

Рис. 7. Плюсна *Bison priscus* ПМ ТГУ 5/2485 из Красного Яра (Томская область)

a – вид спереди; b – вид сзади; d – вид проксимальный; фрагмент КТ-изображения: c – во фронтальной плоскости; e – проксимальная часть диафиза в аксиальной плоскости

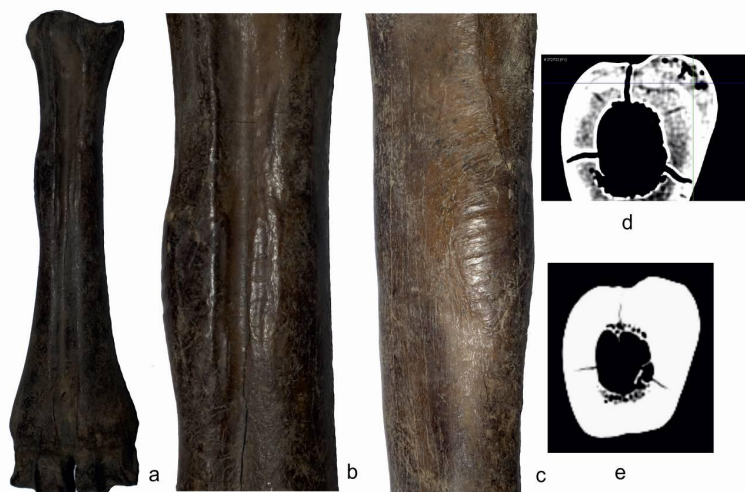


Fig. 8. Metatarsal of *Bison priscus* OSMHRS 15914/1 PK 2254 from Ust'-Ishym district (Omsk Province)

a – dorsal view; b – the area of diaphysis with hyperostosis, dorsal view; c – lateral view; CT image fragment in axial plane: d – in the area of hyperostosis; e – below the hyperostosis

Рис. 8. Плюсна *Bison priscus* OSMHRS 15914/1 ПК 2254 из Усть-Ишимского района (Омская область)

a – вид сзади; b – область диафиза с гиперостозом, вид сзади; c – вид сбоку; фрагмент КТ-изображения в осевой плоскости: d – в области гиперостоза; e – ниже гиперостоза

Table 2

Metatarsals of *Bison priscus* from Krasniy Yar (Tomsk Province)

Таблица 2

Промеры метатарсальных костей *Bison priscus* из Красного Яра (Томская область)

Measurements, mm	Pathological							Normal	
	Krasniy Yar (Tomsk province) PM TSU						Omsk province	Krasniy Yar (Tomsk Province) PM TSU	
	5/3264	5/4283	5/5226	5/3265	5/3263	5/2485	OSMHRS 15914/1 PK 2254	♂ n = 94	♀ n = 45
Largest length	300.5	300	293	284	C259	C267	280.5	258.2–335.7	262–311
Media-lateral width of the proximal end	71.5	67	67	75.3	63	88	57.7	56–78	53.1–69.4
Largest transversal width of the proximal end	67	60.5	65.5	70	67,5		57.2	58–77.5	51–66
The smallest media-lateral width of the diaphysis	47.4	53.5	46,5	48	39	42,5	36.5	41–58	34.3–43.5
Media-lateral width of the distal end	84	83	78.6	85	C72		76.3	63.5–93	66.5–81.5
Transversal width of the distal end	46	43	44.3	47.5	C41.5		41.5	40.6–55	36–49
Index of breadth of the diaphysis (4:1)	15.8	17.8	15.9	16.9			13.0	14.4–18.3	12.1–14.8

Megaloceros giganteus: left metatarsal PM TSU 5/3377 of an adult animal (Fig. 9). The bone bears a broad oval-shaped lesion on the medial side of the diaphysis, on its lower third. The lesion spreads on the dorsal side, closing the dorsal groove in four places with intermittent bone bridges. The lesion (54 × 42 mm) is located 180 mm from the proximal bone end and

110 mm from the distal end. The post-burial damage to the bone involves absence of the palmar wall of the diaphysis. The diaphysis cavity, opened by the damage, does not reveal morphological abnormalities of the internal structure in the area of the outer bone lesion (Fig 9, b). The overall size of the specimen is very large, compared with specimens from localities in West

Siberia south-east, exceeding the sizes of isolated bones from giant deer from the Krasniy Yar locality and from the skeleton of the male individual from Dzambul (Table 3), dated $43\,600 \pm 550$ ka BP (OxA-20250) [Shpansky, 2014b].

Cervus elaphus: left metatarsal (Fig. 10) OSMHRS 15914/2 PK 2255. The bone has a deformity of the proximal part on the dorsal and partially lateral surface of the diaphysis and proximal epiphysis. It is wide, with maximal size on the dorsal edge of the centrotarsale facet up to 9 mm, and 5 mm on its lateral edge, covering two-thirds of length of the facet's lateral edge. The lesion along the dorsal edge of the facet for tarsale 2+3 is 3.5 mm wide and does not cover the medial surface of the bone. The lesion rises above the surface of the joint facets up to 6–7 mm, thus probably restricting joint mobility. The proximal end is uneven, smooth, and could have been in contact with an analogous centrotarsale lesion. The dorsal longitudinal groove reaches the normal length at the distance of 45 mm from the proximal edge of the bone (including the lesion). Above this point, it is more flat and less easily seen. Because of the deformity of the proximal epiphysis, the proximal metatarsal canal is obliterated. The joint facets of the proximal epiphysis are coarsely denticulated and appear to have increased prominence of the articular margins. The facet for centrotarsale is widened medially and its medial edge is lifted and sharpened. Rough

proximal epiphyseal, metaphyseal, and articular bone suggests joint injury, resulting in severe osteophyte rimming of articular surfaces: articular and periarticular osteoarthritis. Linear dimensions of OSMHRS 15914/2 PK 2255 are comparable to metatarsals of fossil red deer from Krasniy Yar (Novosibirsk Province) [Vasiliev, Ovodov, 2013] (Table 4).

Equus ex gr. gallicus: left metatarsal PM TSU 5/5413 of the adult animal (Fig. 11). There is an oval-shaped lesion of the cortical layer on the dorso-lateral side of the diaphysis above its middle part. The lesion is oriented lengthwise. The distance from the distal end of the bone to the lesion is 150 mm, and 90 mm from the proximal bone end to the lesion. The surface is rough and tuberos. The length is 50 mm, and its width is 25 mm. Below this first lesion is a second one. It is 40 mm from the first, is shorter and comb-shaped, and is located on the dorso-lateral-side, across the epiphysis. Its length is 25 mm, and width is 9 mm. The dorsal surface of the bone reveals thin (about 1 mm in width), longitudinal grooves that are rare on the plantar surface. These changes may have occurred after the death of the animal, as a result of dissolution of the bone surface. Similar features were observed on some bones without pathologies including specimens from horses and other mammals from the Krasniy Yar locality. There are no visible changes in the proportions of the specimen PM TSU 5/5413.

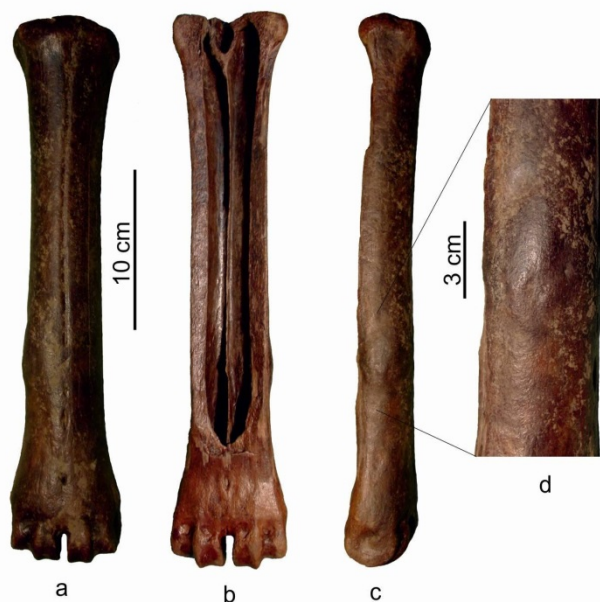

Fig. 9. Metacarpal of *Megaloceros giganteus* PM TSU 5/3377 from Krasniy Yar (Tomsk Province)

a – dorsal view; b – palmar view; c – medial view; d – diaphysis with hyperostosis on the medial side

Рис. 9. Пястная кость *Megaloceros giganteus* ПМ ТГУ 5/3377 из Красного Яра (Томская область)

a – вид сзади; b – вид с пальмарной стороны; c – вид медиальный; d – диафиз с гиперостозом на медиальной стороне




Fig. 10. Metatarsal of *Cervus elaphus* OMK 15914/2 ПК 2255 from Ust'-Ishym district (Omsk Province)

a – dorsal view; b – proximal view

Рис. 10. Плюсовая кость *Cervus elaphus* OSMHRS 15914/2 ПК 2255 из Усть-Ишимского района (Омская область)

a – вид сзади; b – вид проксимальный

Table 3

Metacarpals of *Megaloceros giganteus* from localities of West Siberia

Таблица 3

Промеры метакарпальных костей *Megaloceros giganteus* из местонахождений Западной Сибири

Measurements, mm	Pathological	Normal	
	Krasniy Yar (Tomsk Province) PM TSU 5/3377 left	Dzhambul (Pavlodar Province) POIKM KP 7191 [Shpansky, 2014b]	Krasniy Yar (Tomsk Province) PM TSU, n = 5 [Shpansky, 2011]
Largest length	347	335	322–343
Media-lateral width of the proximal end	71.7	73	60.5–67.7
Largest transversal width of the proximal end	C42	51.4	40–42.8
The smallest media-lateral width of the diaphysis	46.5	44.9	36–41
Media-lateral width of the distal end	75	72.1	67–68.6
Transversal width of the distal end	43	43.5	40–41.4

Table 4

Metatarsals of *Cervus elaphus* from localities of West Siberia

Таблица 4

Промеры метатарсальных костей *Cervus elaphus* из местонахождений Западной Сибири

Measurements, mm	Pathological	Normal	
	OSMHS 15914/2 PK 2255	Krasniy Yar (Novosibirsk Province) [Vasilev, Ovodov, 2013]	Khakassia, Grot of Proskuryakov
Largest length	C250	365–5	330–352.3 (341.7)
Media-lateral width of the proximal end	52.8	43,5–52.2 (49.2)	43–54.1 (48.6)
Largest transversal width of the proximal end	56.5	47–56.5 (51.8)	49–57,4 (52.9)
The smallest media-lateral width of the diaphysis	33.2	33	26,7–33.1 (29.9)




Fig. 11. Metatarsal of *Equus ex gr. gallicus* PM TSU 5/5413 и from Krasniy Yar (Tomsk Province)
a – dorsal view; b – dorso-lateral view; c – diaphysis on plantarolateral side

Рис. 11. Плюсна *Equus ex gr. gallicus* ПМ ТГУ 5/5413 и из Красного Яра (Томская область)
а – вид сзади; б – вид сзади сбоку; с – диафиз на плантарно-боковой стороне

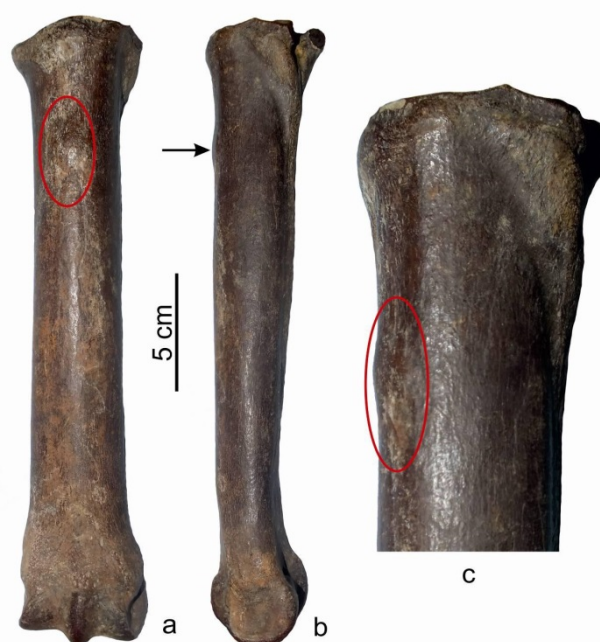

Fig. 12. Metatarsal of *Equus ex gr. gallicus* OMK 15914/3 ПК 2256 from Ust'-Ishym district (Omsk Province)
a – dorsal view; b – lateral view; c – proximal part with hyperostosis, latero-dorsal view

Рис. 12. Плюсна *Equus ex gr. gallicus* OSMHRS 15914/3 ПК 2256 из Усть-Ишимского района (Омская область)
а – вид сзади; б – вид сбоку; с – проксимальная часть с гиперостозом, вид сбоку

Metatarsals of *Equus ex gr. gallicus* from localities of Western SiberiaПромеры метатарсальных костей *Equus ex gr. gallicus* из местонахождений Западной Сибири

Measurements, mm	Pathological		Normal
	Krasniy Yar (Tomsk Province) PM TSU 5/5413	OSMHRS 15914/3 PK 2256	Krasniy Yar (Tomsk o Province) PM TSU, <i>n</i> = 60
Largest length	289	271	263.3–305.0
Media-lateral width of the proximal end	57.2	56.8	45.4–62.7
Largest transversal width of the proximal end	49.6	47.0	41.0–54.0
The smallest media-lateral width of the diaphysis	38.8	37.8	32.5–43.0
Media-lateral width of the distal end	52.8	55.3	50.0–62.3
Transversal width of the distal end	40.0	41.4	37.0–46.4

Left metatarsal (Fig. 12) OSMHRS 15914/3 PK 2256. The bone possesses an irregular-rounded lesion (18 × 19 mm) on the proximal part of the diaphysis, on its dorsal side. The upper edge is 41 mm below the proximal bone end. The height relative to the joint surface is 2–3 mm. The surface is tuberos. Measurements of metatarsals of horses are presented in Table 5.

3.2. Imaging studies

Bones with evident pathologies were imaged using computed tomography; these included PM TSU 5/2485, 5/3263, 5/3264, 5/3265, 5/4283, OSMHRS 15914/1 PK 2254 and a healthy specimen PM TSU 5/5117.

The right metatarsal PM TSU 5/4283 revealed filling of the medullary canal by cancellous bone, from the distal metaphysis to the level of the upper third of the diaphysis (Fig. 3, c). The proximal part of the medullary canal is hollow. A separation of the cortical layer into two parts is observed on the upper diaphysis, approximately at the level of the middle thickness of the compact bone (Fig. 3, c, d). The separation is observed along the full circle of the diaphysis. The most prominent separation occurs on the lateral and medial sides of the diaphysis. The space inside the separated compact tissue is filled with cancellous bone. The semi-fusiform lesion has maximal height of 10 mm above the surface of the diaphysis, and it is associated with the focal lesion in the middle third of the diaphysis, on its lateral side. There is a lamellar separation of the cortical layer along the outer part of the compact layer from the latero-plantar side in the area of the lesion maximum.

The appearance of the pathological changes of the right metatarsal PM TSU 5/3264 are very similar to PM TSU 5/4283. The semi-fusiform lesion [on 5/3264] (the maximal height is 12 mm above the surface of the diaphysis) formed by the area of the focal lesion in the middle third of the diaphysis, on its lateral side, which led to the local hyperostosis of the cortical layer. The changes of the endosteum are not mentioned because the

free volume of the medullary canal is preserved (Fig. 2, c). The cancellous bone is developed on the level of the distal epiphysis and corresponds to normal bone (Fig. 5, e). The compact tissue of the epiphysis has a longitudinal separation from the medial and lateral sides. The medial separation above the outer lesion splits to mediadorsal and medioplantar. On the lateral side, the gap inside the separated compact tissue is filled by cancellous bone, while from the medial, especially the medioplantar, it is not filled. The separation comprises middle and proximal parts of the bone from the lower edge of the lesion to the proximal epiphysis.

The outer changes on PM TSU 5/3265 (Fig. 5, e, f) are the most developed of the presented set. The imaging study revealed a significant development of the spongy bone in the upper third of the medullary canal (75 mm). Looks like thinning of cortex under the lesion, and a somewhat radiating pattern on image 'f'. Also present is a discreet external margin. I wonder if this was a benign tumor or maybe ossifying fibrous tissue. Filling of the distal medullary canal by spongy bone starts along the plantar wall of the diaphysis, gradually increasing in volume, and filling the cavity of the medullary canal by $\frac{3}{4}$ in its proximal part (Fig. 5, e, f). The cancellous bone in the proximal half of the medullary canal is fine-pored in the center, while along the periphery, near the walls the compact bone, it becomes coarse. The cortical layer on the upper third of the diaphysis was resorbed from the inside. It is permeated with large canals and large pores (Fig. 5, f). The maximum replacement is observed from the medioplantar side. The longitudinal separation of the compact bone, as in the PM TSU 5/4283 and 5/3264, is not observed. The replacement of compact bone by cancellous bone (from distal to proximal part) starts from the dorsal side, close to outer part of the compact bone, then it spreads deep into the compact, becoming coarse it covers the plantar side (Fig. 5, f).

CT imaging of OSMHRS 15914/1 PK 2254, PM TSU 5/3263, and 5/2485 showed absence of internal changes of the diaphysis. The filling of the medullary canal by cancellous bone in PM TSU 5/2485 is on the level of normal bones (Fig. 7, c). Changes involve only the proximal epiphysis and upper half of the diaphysis (Fig. 7, d, e). In PM TSU 5/3263 the distal part of the medullary canal is filled by the trabecular bone as in the normal bones, but the rest of the diaphysis is still present as a thin layer along the plantar wall up to 3–5 mm (Fig. 6, f). The changes involve the proximal epiphysis and the adjacent diaphysis (Fig. 6, e). The cortical layer is getting considerably thinner on the dorsal side and becomes porous. In OSMHRS 15914/1 PK 2254 the spongy bone also presented in the upper two-thirds of the medullary canal and forms a layer (up to 3–5 mm) along the plantar and dorsal walls (Fig. 8, e). The changes of the cortical layer in the middle part of the diaphysis have more features in common with metatarsals PM TSU 5/3264 and 5/4283. In these three specimens, the volume of the spongy bone in the proximal part of the medullary canal gradually increases, filling two-thirds of the volume on the level of the lesion. The proximal part of the diaphysis in the area of development of the lesion is characterized by replacement of the compact tissue by the spongy on the dorsal side. The development of the process is from the inside of compact layer out.

3.3. Evaluation of bone lesions by localization and morphology

The observations may be divided into two groups: the first one includes metatarsals of *B. priscus* with proximal lesions (PM TSU 5/3263 and 5/2485) and a metatarsal of *Cervus elaphus* (OSMHRS 15914/2 PK 2255) with analogous deformity. The second group unites the rest of metatarsals with changes located on diaphysis.

We presume that injury of the rear limb in the area of tarsal joint characterizes the first group. This led to the following changes of the bone tissue and development of osteoarthritis. The specimen PM TSU 5/2485 clearly shows the development of ankylosis of tarsal joint as a result of osteoarthritis. Fig. 7 a, d shows that proximal epiphysis does not remain its natural articular surface. It confirms our hypothesis about complete ankylosis and joint immobility. Earlier [Shakalov, 1952] etiological bases for osteoarthritis in the majority were considered to be different infectious diseases. It may also happened as a result of external damage of the bone. Similar cases of osteoarthritis were mentioned by F.K. Skorik [1979] on carpal and tarsal joints of horses from the archeological sites of Ukraine [Skorik, 1979] and Poland [Dzierzecka et al., 2008]. The osteoarthritis with partial ankylosis, observed as a bony bridges and gaps of the joints, developed in the area of bone accretion. Devel-

oped exostoses are mostly observed on lateral sides, which allows author to connect these pathologies with legs traumas of horses [Skorik, 1979].

Metatarsals PM TSU 5/3263 and OSMHRS 15914/2 PK 2255 preserved the articular surfaces for centrotarsale and tarsale 2+3 (Fig. 6, 10), of joints is absent in spite of their considerable deformation and the presence of marginal exostoses. These features allow us to diagnosis the general condition of osteoarthritis in these joints. A similar case of pathology was described for a *C. elaphus* metatarsale from Binagady locality [Gadjiev, Gadjiev, 1955]. Osteoartheses emerge as a result of damage of cartilaginous areas of the articular surfaces. According to Shakalov [1952], osteoartheses of hock joint emerge as a result of chronic micro-traumas of the joint facets by constant sliding and compression of joint surfaces under the effect of animals' body mass in conditions of high load of limbs on uneven, hard, or slimy ground.

Metapodials of the second group (PM TSU 5/3377, 5/3386, 5/3264, 5/4283, 5/5226, 5/3265, 5/5413, OSMHRS 15914/1 PK 2254, OSMHRS 15914/3 PK 2256) reveal overgrowths, at relatively consistent foci. Metacarpals of bison (PM TSU 5/3386) and giant deer (PM TSU 5/3377) are affected mainly on the dorsomedial side of the bone. Metatarsals of bison and horses, except for PM TSU 5/3265, have lesions on the dorso-lateral side. Almost all of the described metatarsal lesions are located in the middle or proximal part of the diaphysis (Fig. 13). While metapodial diaphysis lack foci for muscle attachments, tendons are present, such as those of extensors ext. digitorum longus and ext. digitorum brevis on the dorsal aspect [Gambaryan et al., 1979]. Most of the lesions are rounded or broad oval-shaped. In PM TSU TTY 5/5226 and 5/3386 they present as smooth rollers. The lesions tend to be are flattened, tuberos, or smooth. We suggest that common outer similarity for specimens PM TSU 5/5226 and 5/3386, could suggest similar causes. Probably, animals got deep cut or puncture, accompanied by periostosis and varied healing morphologies.

PM TSU 5/3265 is presumed to be damaged on the distal bases of m. peroneus tertius, which attachment on the dorsomedial side of the metatarsal bone proximal end in bisons [Gambaryan et al., 1979] coincides with the lesion on this bone. This lesion could be termed enthesiophyte or plural enthesiophytes. Together with the damage to the joint capsule, an inflammatory process can result in bone proliferation, loss, and deformity.

A metacarpal from a giant deer (PM TSU 5/3377) with opened diaphysis shows absence of changes from the inside. Non-specific mostly smooth periosteal reaction, from environmental trauma or from a bite wound that may have resulted in a periosteal hematoma or infection.

Metacarpals of bison (PM TSU 5/3264, 5/4283, OSMHRS 15914/1 PK 2254) and horses (PM TSU 5/5413, OSMHRS 15914/3 PK 2256) are similar in external and internal pathological manifestations and lesion spatial localizations. Their most probable source is periosteal reaction that in turn could be caused by single injuries, wounds and bruises with damage to bone periosteum, perhaps complications resulting from periosteal hematoma, more severe inflammation, or infection, followed by organization and healing with morphological alterations.

Analogous cases of periostosis resulting from metapodials injury were mentioned by A. Skorik [1979] in *Alces alces* L. specimens from Medieval. Pathologies of two metacarpals were attributed to bone fractures: in specimen P-29 there is a fracture with slight displacement and deformity. In specimen P-28 there is a closed fracture without displacement. A larger series of 11 metacarpals and 14 metatarsals with periostosis in camels *Paracamelus alexejevi* Hav. was described by I. Yatsko [1962] from karst caves of Odessa. A similar case of hematoma development on the metatarsal bone has been described in a modern reindeer from the Taimyr Peninsula [Salmi, Niinimäki, 2016]. Pathological changes in metapodials described by these authors are analogous to the listed.

4. Discussion

4.1. Exterior and some morphological features of Late Pleistocene bison, deer and horses

Bison priscus inhabited the territory of the West Siberian Plane during the Late Pleistocene. It was a large animal. Withers height for females was up to 1.8 m, the weight is suggested to have been 700–900 kg. Males were more massive: withers height reached 2–2.2 m and the weight was up to 1 300–1 700 kg. Horn spread for females could be up to 100 cm (including horn covers, and 70 cm without them). Male horn spread could reach 150 cm (including horn covers, and 90–110 cm without them) [Shpansky et al., 2016]. Bison of the Middle Pleistocene even larger. Animals were covered with thick dense hair with guard hairs up to 30 cm in length [Flerow, 1979; Guthrie, 1990]. “Body in the winter fur is covered by long hairs, except for limbs below the forearm and heel, where the hair is shorter, straight” [Flerow, 1979]. The most dense and long hair was developed on the neck and shoulders, forming a kind of mane. “Beard and hanging hairs on the lower side of the neck and chest are very long. The length of hairs of the beard is up to 750 mm, while in neck hanging hairs are 500 mm. Hair on the neck and ventral side of the body is formed on the stomach, front, and rear of hind limbs from the stifle to the hock joint. Its length on the stom-

ach is about 200 mm, while on the limbs it is 150–200 mm. Limbs below the hock and metacarpal joints bear short, almost straight hairs, with awn length 35–40 mm” [Flerow, 1979; p. 76]. The snout of the animal is wide, nostrils are large.

The giant deer (*Megaloceros giganteus*) is the largest Quaternary deer. Its withers height for males could reach 1.7 m, weight up to 700–800 kg. Horn spread for old males could reach 3.5 m [Shpansky, 2014b]. There are no available corpses of these animals to date, therefore the distribution of fur on their bodies is hypothetical. We presume that the thickest and longest fur also was in the area of neck and the shoulder girdle.

The red deer (*Cervus elaphus*) is significantly smaller, but nevertheless the male individuals of some modern populations of Siberia can reach the weight of 400 kg, while the sizes of fossil deer from localities of West Siberia south-east were 10 % larger than modern ones [Vasiliev, Ovodov, 2013]. The integument of Late Pleistocene Asian red deer is unknown definitely. Probably, it was close or identical to the modern representatives of the Caspian red deer (*Cervus elaphus sibiricus*) from Altai or East Siberia. An important ecological feature of the modern red deer is its forest habitat. The Late Pleistocene deer of West Siberia inhabited the food-plain thicket of bushes and trees. These conditions are considerably more difficult for the movement of animals.

Horses (*Equus ex gr. gallicus*) inhabited the territory of West Siberia. This horse was a large, high-limbed animal, capable of high-speed movements. The withers height for male individuals could reach up to 1.4–1.6 m.

In order to facilitate further analysis and comparison, we present some characteristics for large African cavi-corns, which to some extent are ecological analogues for *Bison priscus*, *Megaloceros giganteus*, and *Cervus elaphus* also are prey for African lions. They are presented by eland *Taurotragus oryx* Pallas, 1766, big kudu *Tragelaphus strepsiceros* Pallas, 1776, roan antelope *Hippotragus equinus* Diesmarest, 1804, blue wildebeest *Connochaetes taurinus* Zimmermann, 1780 and African buffalo *Syncerus caffer caffer* Sparrman, 1779. Eland is the biggest and massive antelope, whose mass for males reaches 1 ton (400–600 kg for females), and withers height is 1.6–1.8 m. Other antelopes with relative large sizes have a considerably smaller mass. A roan antelope is about 300 kg, with withers height of males 1.6 m. Wildebeest is very close to Bovine by its exterior. The withers height for males is up to 1.5 m and the weight is 250 kg. Females are smaller, their withers height is 1.35 and weight is around 180 kg. The neck is covered with mane and long hairs on the underside. A big kudu is much smaller: male’s withers height is about 1.4 m and the weight is up to 250 kg. African buffalo is bigger than wildebeest and more massive. Its withers height for

males is up to 1.8 m (usually 1.5–1.6 m) and body length 3–3.4 m. Weight of the adult male is 600 kg. The biggest old males can be up to 900–1,000 kg. All of the listed species have relatively poor pelage. Thus, males of *Bison priscus* excels big African cavicorn by their weight and protection. Giant and red deer does not have direct morphological analogues in the modern African fauna. According to their constitution, biotope. ecology, they are close to eland, kudu and partially giraffe. An ecological analogue of the Late Neopleistocene horse can be a zebra. There are two species of zebra in the African savannah: *Equus grevyi* Oustalet, 1882 and *Equus quagga* Boddaert, 1785. Grévy's zebra is a little bigger. Its weight is 350–430 kg, body length is 3 m, and withers height is about 1.4 m. Burchell's zebra has a more compact body (withers height is 1.2–1.4 m, length is 2–2.4 m) and relatively wide hoof, its weight is 290–340 kg.

Given data show that the ungulates that lived during the Late Pleistocene on the territory of West Siberian Plain were very large and significantly superior to their ecological analogues from African savannah.

4.2. Probable causes of the outer injury of ungulates

Metapodial bones of ungulates are not well-protected from mechanical trauma because the overlying muscle mass is small, compared to humerus, radius, femur, or tibia. Hind limbs are significantly weaker than forelimbs, in both muscle and bone mass. Hair covering on the distal extremities also is much shorter than on the shoulders [Flerov, 1979]. Therefore, the impact force on distal extremities was relatively high. As a result, injury-related hematomas, open wounds, haemorrhage, direct periosteal damage, and soft tissue injury involving ligaments and joint capsules, all would be more likely. Thus, post-healing complications would be expected to be more common also.

One possible source of distal limb trauma in ungulates could be running into, or tripping over, obstacles in the environment (i.e. trunks of fallen trees). A second possible group of causes could be lower limb trauma induced by Palaeolithic humans. Finally, attacks by large predators must be considered (for example, cave lions).

The first and the second causes are doubtful. Lesions of the cortical layer on the specimens PMTSU 5/3386 and 5/5226 do not have the characteristic shape of hit by a blunt object. They have linearly elongated shape of the cortical layer hyperostosis, which is more consistent with the cutting or scarring effect on the soft tissue and periosteum. Position of bone outgrowth on the majority of specimens is significantly shifted laterally, which is also contradicts to dorsal effect on the bone, occurred because of the hit on obstacles. In addition, described lesions of metapodial diaphysis were mention on ani-

mals (bison, giant deer, horse) inhabited in open landscapes and, probably, avoided the forest areas, where their movements would be difficult.

A throw of the stick by a Palaeolithic man, focused to hit limbs of bison, large deer horse as a hunting strategy also looks doubtful, including the physical reasons. In order to cause the serious trauma (fracture or joint damage) or knock down a large animal like bison or giant deer, it requires very powerful and accurate throw. In the Late Palaeolithic man possessed very effective throwing spears. Therefore, it is doubtful the man used this technique of hunting, having the opportunity to hit the animal in the chest or abdomen.

The third cause – the attack of the large predator seems most likely. Modern African lions usually jump over the back of the large artiodactyls (wildebeest, buffalo, giraffe) in the hunt of pride. Asphyxiation is carried out by grabbing the victim's her muzzle or neck. A different strategy was observed during the hunt for giraffe on the territory of Kruger National park (RSA). The main concept of the lion hunt of three prides included not the driven hunt, well known from the literature, but in single ambushes [Estes, 1997]. In order to fulfil this, the predator had been hiding along the daily migration zones of victims and suddenly attacked from ambush. At the same time, fixation on the body of a prey never happened. Lions tried to break the prey's limb with one stroke and quickly run back. With a little luck the neck of the victim throttled immediately. Only third to fourth attack was successful.

In Late Pleistocene animals were covered with a thick and long fur, so the first way to attack (jumping on the back of the victim or the capture of the neck) was less effective. The mouth of a predator was filled by the hair (especially long on the neck), while the claws even punching the skin, were ineffective due to the fat layer and powerful muscular frame of victim. Capture the muzzle and asphyxiation of the animal is possible only when the victim is passive (in a static position), it is not in a motion. To fulfil the capture the victim should be stopped. The similar attack is reconstructed accurately by Guthrie [1990] on the frozen corpse of Bison «Blue Babe», found in Alaska. The bison really had serious damages of the facial bones of the skull. Blood clots are marked in the muzzle of bison, i.e. heart continued to pump blood, and thus the damage was in his lifetime, that proves the asphyxiation of victim by the predator. At the same time, Guthrie mentioned scratches on metapodials, which are, probably, the marks of lion's paw hit on the limb of the victim.

It was not easy to reach the neck of the horned animal (bison, red or giant deer) immediately. A prey was protected by the powerful horns that could repel the attack. Bison's and, probably, giant deer's neck were covered by

a thick mane (Fig. 13, a). It can be assumed that hit in the legs was the most effective way to stop and immobilize the victim. The described techniques of hunting of modern African lions for the big prey like giraffe show the causes of the most probable trauma of limbs. High frequency of modern lions' failed attacks on the big animals allows to presume the analogous genesis of the studied pathologies and regenerative processes. In large artiodactyls the most vulnerable areas for lions attacks were distal

ends of limbs, especially hind ones, being less protected and thin. Described traumas were gained in the result of clinging of the front paw of the predator on the limbs of ungulates to knock them down and possibly break metapodial, thereby immobilize the animal. Distribution of pathologies on metapodials of ungulates shows that hits on hindlimbs of bison and horse occurred at a height of 30 to 50 cm from the ground, while the hit on forelimbs happened 30–35 cm from the ground (Fig. 13).

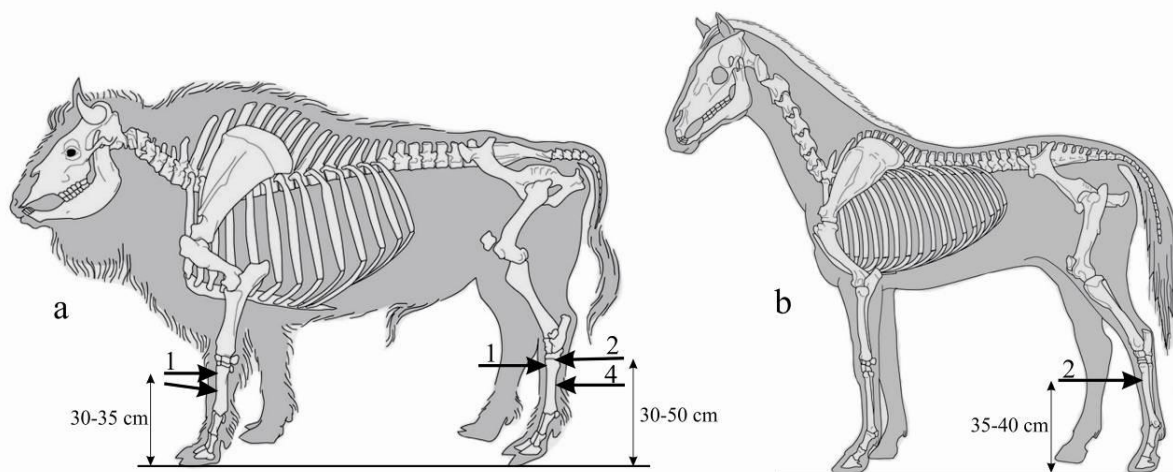


Fig. 13. The scheme of pathologies distribution on skeletons of bison (a) and horse (b)

Digits above the arrows represent the number of mentioned pathologies in this part of the skeleton

Рис. 13. Схема распределения патологий на скелетах бизона (a) и лошади (b)

Цифры над стрелками обозначают количество упомянутых патологий в этой части скелета

The habitat of the cave lion in West Siberian Plain had a set of specific features, comparing with African savannah. A hunting strategy of cave lion on the vast open areas of West Siberia with tundra-steppe landscapes differs from one of the modern African lion in savannah. Crouching and attack from the ambush at short distance were especially difficult in the cold season. In winter the herbage became sparse, trampled, and predator movement became more visible. Therefore, in our point of view, the cases of *Panthera spelaea* hunt on the large ungulates in the form of attack from the distance of several tens of meters were the most probable. It caused the necessity of persecution the prey, and thus attack of the predator from behind directing victim's legs to stop it. N.K. Vereshchagin [1971] pointed on the higher speed skills of cave lions.

Posture and amplitude of the hind limbs in motion of extant forest *Bison bonasus* and steppe *Bison bison* (analogue to *B. priscus*) are well-studied with the help of video and analysed in details [Gambaryan, Sukhanov, 1979]. In steppe-dwellers *B. priscus* and *B. bison* amplitude of motion and angles of hind limb deflection in the fulcrum is less than in the forest-dweller *B. bonasus*.

Such differences shows more upright position of the distal part of the hind limb relative to the ground in the steppe forms. Distal part of the limbs of *B. bonasus* is closer to the ground during the movement (in the moment of at the moment of touchdown and lift-off). Kierdorf et al. [2012] described the healed fracture of tibia of *B. menneri* which is a forest form of the bison. Authors suspect that the cause of it could be uneven or slippery ground, a large predator (i.e. *Homotherium crenatidens* or *Megantereon cultridens adroveri*) hunting not excluded. Predator's paw hit from the lateral side on the hind limb of bison. Striking above the ankle joint led to the fracture of tibia. Thus, the hit on the limbs was an effective way of hunting of cave lions for large Pleistocene ungulates. The studied specimens prove that not all of the hunts were successful and some animals survived the attack and could live for long enough after a heavy trauma. Attribution of all specimens to the males could be an indirect evidence for unsuccessful attack of the cave lions, as the causes for pathologies. A relatively large male individuals with a more powerful skeleton could survive after the predators' attack.

In spite of the series of the studied material from Krasniy Yar locality, its relation of “injured” bones to the total volume of the set of *B. priscus* is not high. There is only one case for overall quantity of 144 metacarpal specimens, which is 0.7 %. For 159 specimens of metatarsals, there are 6 cases of pathologies revealed, which is 3.8 %. There is only one case of pathology on metatarsal for *Equus ex gr. gallicus* from Krasniy Yar (1.7 %) for the total number of 60 specimens. Materials from Omsk Province are presented by isolated specimens and do not reflect the real frequency of pathology

occurrence. The rare occurrence of pathologies of the hit genesis on the fore limbs can be explained by visual control of the front sector, that allowed to avoid traumas even on the high speed. Cases of pathological changes on the other long bones (humerus, radius, femur and tibia) of the ungulates are not revealed in our materials. This feature is also unusual, because veterinary data show that tibial fractures for the cattle may reach 40–50 % of the total number of long bones fractures [Gangl et al., 2006; Ahmed, Al-Sobayil, 2012] while the portion of metapodial damage is 10–13 %.

References

- Ahmed, A.F., Al-Sobayil, F.A. Fractures in young, single-humped camels (*Camelus dromedarius*) // Turk. J. Vet. Anim. Sci. 2012. V. 36(1). pp. 1–8.
- Bendrey R. Care in the community? Interpretations of a fractured goat bone from Neolithic Jarmo // Iraq. International Journal of Paleopathology. 2014. V. 7. pp. 33–37.
- Bondarev, A.A. *Deformatsii pozvonkov Mammuthus sp.* [Deformations of *Mammuthus sp.* Vertebrae] // Trudy Zoologicheskoy Komissii ORO RGO. 2006. V. 3. pp. 121–125. In Russian
- Dzierzecka M., Charuta A., Kobryn H. Pathological changes of Horse bones in the Middle Ages in Poland – photographic records // Bull. Vet. Institute Pulawu. 2008. V. 52. pp. 689–694.
- Estes R.D. The Behavior Guide to African Mammals. Russel Friedman Books. South Africa. 1997. P. I-XXII, 611 p.
- Flerow C.C. *Sistematicheskoye polozheniye Bison v semeystve Bovidae. V kn.: Evropeyskiy bizon. Morfologiya, sistematika, evolyutsiya, ekologiya.* [Systematic status of Bison within the family Bovidae]. In: European Bison. Morphology, Systematics, Evolution, Ecology. Moscow: Nauka Publishers. 1979. pp. 9–127. In Russian:
- Gadzhiev G.V., Gadzhiev D.V. *Materialy k izucheniyu paleopatologii binagadinskih kopytnykh* [Materials of paleopathology research of Binagadinsk ungulates] // DAN AzSSR. 1955. V. 11(4). pp. 267–272. In Russian
- Gambaryan P.P., Gudkov V.M., Sukhanov V.B. *Skeletnyye myshtsy. V kn.: Evropeyskiy bizon. Morfologiya, sistematika, evolyutsiya, ekologiya* [Skeletal muscles. In: European Bison. Morphology, Systematics, Evolution, Ecology]. Moscow: Nauka Publishers. 1979. pp. 196–291. In Russian
- Gambaryan P.P., Sukhanov V.B. *K biomekhanike dvigatel'nogo apparata zubrov. V kn.: Evropeyskiy bizon. Morfologiya, sistematika, evolyutsiya, ekologiya* [On biomechanics of European bison locomotory apparatus. In: European Bison. Morphology, Systematics, Evolution, Ecology]. Moscow: Nauka Publishers. 1979. pp. 292–327.
- Gangl M., Grulke S., Serteyn D., Touati K. Retrospective study of 99 cases of bone fractures in cattle treated by external coaptation or confinement // Veterinary Record. 2006. V. 158. pp. 264–268.
- Guthrie R.D. Frozen Fauna of the Mammoth steppe. The Story of Blue Babe. University Chicago Press. Chicago and London. 1990. 367 p.
- Kierdorf U., Kahlke R.-D., Flohr S. Healed fracture of the tibia in a bison (*Bison menneri* Sher, 1997) from the late Early Pleistocene site of Untermassfeld (Thuringia, Germany) // International Journal of Paleopathology. 2012. V. 2. pp. 19–24.
- Kingdon J. East African Mammals. An Atlas of Evolution in Africa. V. 3, Part A: Univ. Chicago. 1977. 476 p.
- Mashchenko E.N., Shpansky A.V. Abnormal Dental Morphology in the Mammoth *Mammuthus primigenius* Blumenbach, 1799 // Paleontological Journal. 2005. V. 39(1). pp. 93–100.
- Moodie R.L. Palaeopathology. Illinois press. 1923. 567 p.
- Roberts C.A., Alves Cardoso F., Bernofsky K., Henderson C., Jakob T., Plomp K., Ponce P., Sharman J., Spenser R. Palaeopathology: Studying the origin, Evolution and Frequency of disease in Human remains from archaeological sites // Archaeology. 2004.
- Rothschild B.M., Martin L.D. Paleopathology. Disease in the Fossil Record. Boca Raton, CRC Press. 1993.
- Salmi A.-K., Niinimäki S. Enteseal changes and pathological lesion in draught reindeer skeletons – Four case studies from present-day Siberia // International Journal of Paleopathology. 2016. V. 14. pp. 91–99.
- Shakalov K.I. *Bolezni konechnostey loshadi* [Limbs' diseases of horse]. Moscow: Sel'hozgiz. 1952. 450 p. In Russian
- Shpansky A.V. The giant deer *Megaloceros giganteus* (Blum.) (Mammalia, Artiodactyla) from the southeastern West Siberian Plain // Bulletin of Moscow Society of Naturalists, Geological series, 2011. V. 86(1), pp. 18–30. In Russian
- Shpansky A.V. Variations in teeth morphology in woolly mammoth *Mammuthus primigenius* (Blumenbach, 1799) (Mammalia, Elephantidae) // Trudy ZIN. 2014a. V. 318. No. 1. pp. 24–33. In Russian
- Shpansky A.V. Skeleton of the Giant Deer *Megaloceros giganteus giganteus* (Blumenbach, 1803) (Mammalia, Artiodactyla) from the Irtysh Region near Pavlodar // Paleontological Journal. 2014b. V. 48(5). pp. 534–550.
- Shpansky A.V., Kuzmin Y.V. The MIS 3 megafauna of the southeastern West Siberia and the possibility of late survival of steppe mammoth (*Mammuthus trogontherii chosaricus*) // Radiocarbon. 2021. V. 63. No. 2. pp. 575–584.
- Shpansky A.V., Sapunova L.S., Pilyukova A.V. A Traumatic Case in the Mammoth *Mammuthus trogontherii chosaricus* Dubrovo 1966 Elephant // Quaternary International. 2015a. V. 379. pp. 82–88.
- Shpansky A.V., Svyatko S.V., Reimer P.J., Titov S.V. Findings of *Bison priscus* Bojanus (Artiodactyla, Bovidae) skeletons in Western Siberia // Russian Journal of Theriology. 2016. V. 15(2). pp. 100–120.
- Shpansky A.V., Vasiliev S.K., Pecherskaya K.O. The Steppe Elephant *Mammuthus trogontherii* (Polig) from the Irtysh Region Near Omsk // Paleontological Journal. 2015b. V. 49(3). pp. 304–325.

- Skorik A.F. *Eksperiment po analizu sluchayev osteopatologii u iskopayemykh mlekopitayushchikh* [A trial to analyse cases of osteopathologies in fossil mammals] // *Vestnik zoologii*. [Bulletin of Zoology]. 1979. No. 3. pp. 63–66. In Russian
- Strauss M.K.L., Packer C. Using claw marks to study lion predation on giraffes of the Serengeti // *Journal of Zoology*. 2013. V. 289. pp. 134–142.
- Tasnadi-Kubacska A. *Paleopathology*. Jena: Veb Gustav Fischer Verlag. 1962. 269 p.
- Thomas R., Grimm J. The role of age, sex and body weight in the formation of “buttresses” on sheep metatarsals // *International Journal of Paleopathology*. 2011. V. 1. pp. 121–125.
- Udrescu M., Van Neer W. Looking for human therapeutic intervention in the healing of fractures of domestic animals. In: Davies J., Fabic M., Mainland I., Richards M., Thomas R. (Eds.), *Diet and Health in Past Animal Populations. Current Research and Future Directions. Proceedings of the 9th ICAZ Conference, Durham 2002*. Oxbow Books, Oxford, 2005. pp. 24–33.
- Yatsko I.Ya. *Sledy bolezney na iskopayemykh skeletakh pliotsenovykh verbyudov iz karstovykh peshcher v okrestnostyakh Odessy* [Traces of diseases on fossil skeletons of Pliocene camels from karst caves in the vicinity of Odessa] // *Tr. Odesskiy gosudarstvennyy universitet* [Tr. Odessa State University]. 1962. V. 152. Geological and geographical sciences. No. 8. pp. 34–45. Table I–II. In Russian
- Vasiliev S.K., Ovodov N.D. *Blagorodnyy olen' (Cervus elaphus cf. sibiricus) v yuzhnoy chasti Zapadnoy i Tsentral'noy Sibiri v pozdnem pleystotsene i golotsene* [Red deer (*Cervus elaphus* cf. *sibiricus*) in the Southern part of Western and Central Siberia during the Late Pleistocene and Holocene] // *Zoological Journal*. 2013. V. 92. No. 9. pp. 1031–1045. In Russian
- Vereshchagin N.K. *Peshchernyye l'vy Golarctiki* [The Cave Lions of Holarctics] // *Materialy po faunam antropogena SSSR* [Materials on the anthropogenic fauna of the USSR]. Leningrad: Nauka. 1971. pp. 123–199. In Russian

Information about the authors:

Shpansky A.V., Dr. Sci. (Geol-Miner.), Professor, Department of Palaeontology and Historical Geology, Geology and Geography Faculty, National Research Tomsk State University, Tomsk, Russia; V.S. Sobolev Institute of Geology and Mineralogy SB RAS, Novosibirsk, Russia.

E-mail: Shpansky@ggf.tsu.ru

Aidos (Novik) A.V., postgraduate student, Department of Palaeontology and Historical Geology, Geology and Geography Faculty, National Research Tomsk State University, Tomsk, Russia.

E-mail: novik.anastasia@mail.ru

Sapunova L.S., radiologist, Cancer Clinic of Tomsk National Research Medical Centre, Siberian Branch of the Russian Academy of Sciences, Tomsk, Russia.

Saveliev S.V., Dr. Sci. (Biology), Professor, Institute of Human Morphology the Russian Academy of Sciences, Moscow, Russia.

E-mail: embrains@hotmail.com

Bondarev A.A., Omsk regional branch of the Russian Geographical Society, Omsk, Russia.

E-mail: gilgamesh-lugal@mail.ru

Contribution of the authors:

Shpansky A.V. – general concept, morphological and morphometric analyses, paleoecological reconstructions, fundraising.

Aidos (Novik) A.V. – morphometric analysis, preparation of illustrations and tables.

Sapunova L.S. – carrying out computed X-ray tomography, description of CT images and analysis of the causes of pathologies.

Saveliev S.V. – formal analytics.

Bondarev A.A. – morphometric analysis of a part of the material, preparation of illustrations.

The authors declare no conflicts of interests.

Информация об авторах:

Шпанский А.В., доктор геол.-минер. наук, профессор кафедры палеонтологии и исторической геологии, геолого-географический факультет, Национальный исследовательский Томский государственный университет, Томск, Россия. Институт геологии и минералогии им. В.С. Соболева СО РАН, Новосибирск, Россия.

E-mail: Shpansky@ggf.tsu.ru, andreyspansky@yandex.ru

Айдос (Новик) А.В., аспирант, кафедра палеонтологии и исторической геологии, геолого-географический факультет, Национальный исследовательский Томский государственный университет, Томск, Россия.

E-mail: novik.anastasia@mail.ru

Сапунова Л.С., рентгенолог, онкологический диспансер Томского национального исследовательского медицинского центра СО РАН, Томск, Россия.

Савельев С.В., доктор биологических наук, профессор, Институт морфологии человека РАН, Москва, Россия.

E-mail: embrains@hotmail.com

Бондарев А.А., Омское региональное отделение Русского географического общества, Омск, Россия.

E-mail: gilgamesh-lugal@mail.ru

Вклад авторов:

Шпанский А.В. – общая концепция, морфологический и морфометрический анализы, палеоэкологические реконструкции, привлечение финансирования.

Айдос (Новик) А.В. – морфометрический анализ, подготовка иллюстраций и таблиц.

Сапунова Л.С. – проведение компьютерной рентгеновской томографии, описание КТ-снимков и анализ причин возникновения патологий.

Савельев С.В. – формальный анализ.

Бондарев А.А. – морфометрический анализ части материала, подготовка иллюстраций.

Авторы заявляют об отсутствии конфликта интересов.

Статья поступила в редакцию 24.01.2022; одобрена после рецензирования 04.11.2022; принята к публикации 13.03.2023

The article was submitted 24.01.2021; approved after reviewing 04.11.2022; accepted for publication 13.03.2023