



## Case report

Bilateral hip septic arthritis caused by nontyphoidal *Salmonella* group D in a 16-year-old girl with COVID-19: A case report

Mohammadreza Salehi<sup>a</sup>, Seyed Mohammad Kazem Nourbakhsh<sup>b</sup>,  
 Mohammad Vahedian Ardakani<sup>c</sup>, Alireza Abdollahi<sup>d</sup>, Pegah Afarinesh Khaki<sup>e</sup>,  
 Amir Aliramezani<sup>e,\*</sup>

<sup>a</sup> Department of Infectious Diseases and Tropical Medicines, Imam Khomeini Hospital Complex, Tehran University of Medical Sciences, Tehran, Iran

<sup>b</sup> Department of Pediatrics, Pediatric Hematology and Oncology Section, Imam Khomeini Hospital Complex, Tehran University of Medical Sciences, Tehran, Iran

<sup>c</sup> Department of Orthopedics, Joint Reconstruction Research Centre, Imam Khomeini Hospital Complex, Tehran University of Medical Sciences, Tehran, Iran

<sup>d</sup> Department of Pathology, Imam Khomeini Hospital Complex, Tehran University of Medical Sciences, Tehran, Iran

<sup>e</sup> Central Laboratory, Imam Khomeini Hospital Complex, Tehran University of Medical Sciences, Tehran, Iran



## ARTICLE INFO

## Keywords:

Bacteremia

Hip joint

Nontyphoidal *Salmonella*

Bilateral septic arthritis

COVID-19

## ABSTRACT

**Introduction and importance:** Nontyphoidal *Salmonella* infection can lead to gastroenteritis, enteric fever, and bacteremia. However, joint infections due to this bacterium are rare, and usually associated with immunosuppressive disorders.

**Case presentation:** A 16-year-old girl, with a recent history of acute lymphocytic leukemia (ALL) presented with bacteremia, and bilateral hip pain after COVID-19 symptoms. Clinical presentation, laboratory features and imaging showed bilateral nontyphoidal *Salmonella* septic arthritis. We administered antibiotics, based on antibiotic susceptibility pattern of the isolated *Salmonella*.

**Clinical discussion:** The case is presented because reports of bilateral hip joint infection due to nontyphoidal *Salmonella* are rare especially after COVID-19. When the patient presents with joint discomfort, the clinician should think infection especially in immunocompromised hosts.

**Conclusion:** It illustrates successful management of septic arthritis requires prompt clinical diagnosis, microorganism identification, administration of appropriate systemic antibiotics and hip joint surgery.

## 1. Introduction

*Salmonella* is the leading cause of foodborne bacterial diseases which is enteropathogenic and enteroinvasive organism and it consists of a large heterogeneous group of gram negative bacilli that mainly affect humans and animals [1]. Salmonellosis causes four types of clinical diseases: gastroenteritis, enteric fever, septicaemia with or without suppurative lesions and also the carrier state [2]. Bacteremia is a constant feature of enteric fever and its dissemination may lead to localized infection in other organs even in the bones and joints [3]. *Salmonella* arthritis is a rare joint disorder which occurs infrequently and accounting for approximately 1% of all septic cases [4]. The organism that causes septic arthritis is almost invariably a nontyphoidal *Salmonella* species and usually presents as one of the metastatic infections in children and adolescents following earlier bacteremia episodes [5].

Clinical presentations of nontyphoidal *Salmonella* infection are

mainly variable, including gastroenteritis, septic arthritis, osteomyelitis, and endovascular infection [6]. But, when compared with other Gram-negative bacteria, nontyphoidal *Salmonella* is a less common etiologic factor for septic arthritis [7]. However, underlying states such as malignancy, hemoglobinopathy, diabetes, human immunodeficiency virus (HIV) infection, surgical operations, and other immune suppressive conditions predispose a patients to *Salmonella* arthritis [8]. In this report, we describe a case of bilateral hip septic arthritis due to nontyphoidal *Salmonella* after COVID-19 in a young patient with acute lymphocytic leukemia (ALL).

## 2. Case presentation

## 2.1. Patient information

A 16-year-old girl was admitted in a hospital three times in our

\* Corresponding author.

E-mail address: [aliramezaniamir@gmail.com](mailto:aliramezaniamir@gmail.com) (A. Aliramezani).

hospital from March to December 2021.

First episode: she (Weight: 78 kg and body mass index: 28 and basal surface area: 1.8) was received induction chemotherapy diagnosed with acute lymphoblastic leukemia (ALL) in March 2021 and chemotherapy based on an ALL high risk protocol with administration of high dose prednisolone (60 mg/m<sup>2</sup>/day/for 4 weeks), intravenous injection of vincristine (1.5 mg/m<sup>2</sup>/week/for 4 weeks), daunorubicin (25 mg/m<sup>2</sup>/week/for 4 weeks) and Pegylated-asparaginase (2500unit/m<sup>2</sup>/stat), oral usage of mercaptopurine and methotrexate, and finally intrathecal prescription of methotrexate, cytarabine and hydrocortisone.

Second episode: the patient was stabilized with consolidation and intensification and her leukemia was in remission, using mercaptopurine, weekly usage of methotrexate and peg-asparaginase, and monthly regime including vincristine and prednisolone. After two months, she referred to the hospital with diarrhea and also experiencing of complaints of abdominal pain, fever (37.8 °C) for 7 days and sepsis. Four days later, she showed COVID-19 symptoms such as headache, sore throat, cough, tiredness and loss of taste and smell. Ultimately his COVID-19 RT PCR from nasopharyngeal swab was positive. The patient developed intermittent dry cough and shortness of breath and underwent CT scan of the lungs (Fig. 1). According to pulmonary involvement and COVID-19 national guideline, the patient took remdesivir (20 mg stat and 100 mg daily/IV) and dexamethasone (8 mg dial/IV for 5-days) and was discharged in good general condition.

Third episode: the last episode started with restriction of movements, difficulty to bear weight on the both hip joints with sudden onset of fever, pain and tenderness was present over the pubic symphysis. The pain was more severe on the right side. She eventually admitted to hospital again and her hip MRI (Fig. 2) revealed bilateral joint effusion and femoral head bone destruction. Blood culture was sent to and she underwent joint fluid drainage (pus drained and cultured) in the operating room with general sedation. Because of the hip joint destruction due to prolonged exposure to nontyphoidal *Salmonella*, it was decided to perform a two-stage revision surgery (Fig. 3) and femoral prostheses made of antibiotic-loaded cement implanted in both hips. Clinical features of the patient were mentioned in Table 1.

## 2.2. Diagnostic assessment

Blood culture was performed via BACT/ALERT system (BioMeriux, France) and then processed according to standard protocol yielded Gram

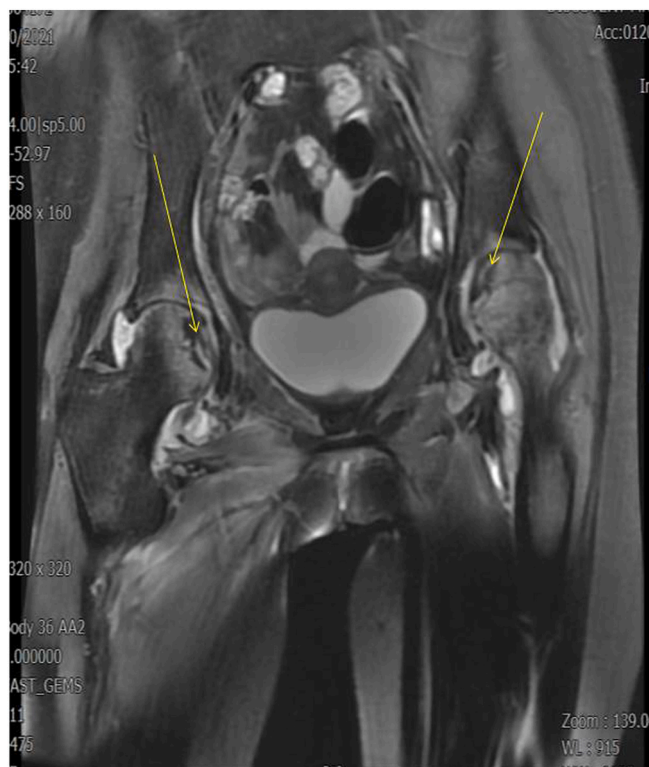


Fig. 2. Magnetic resonance imaging (MRI) shows septic arthritis of the bilateral hip joints.

negative, non-lactose fermenting, catalase and H<sub>2</sub>S positive, oxidase negative and motile bacilli was confirmed by Gram negative biochemical panel through VITEK 2 instrument (BioMeriux, France). The organism was then identified as nontyphoidal *Salmonella* serogroup D through *Salmonella* group polyclonal antibodies. Antibiotic susceptibility testing of this organism for ampicillin (10 µg), ciprofloxacin (5 µg), cotrimoxazole (25 µg), ceftriaxone (30 µg), cefotaxime (30 µg) and imipenem (10 µg) (MAST, France) were obtained from standard disc diffusion method and was verified by VITEK 2 instrument, as well. In addition, synovial fluid culture and Gram stain smears of hip joints

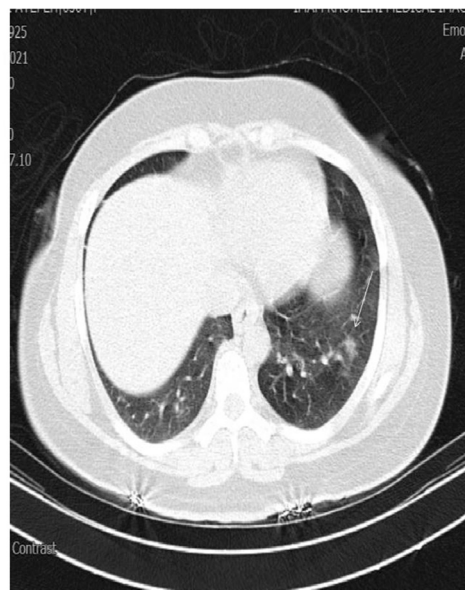
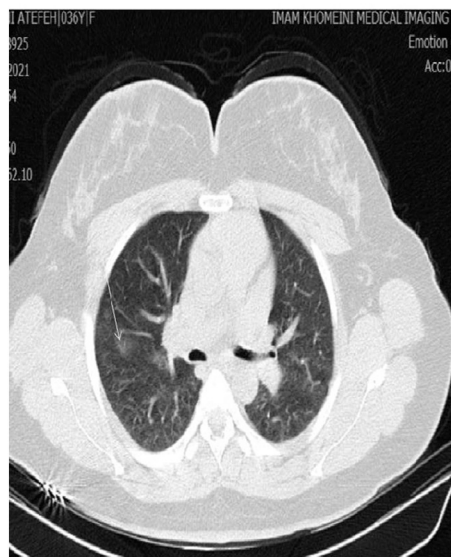
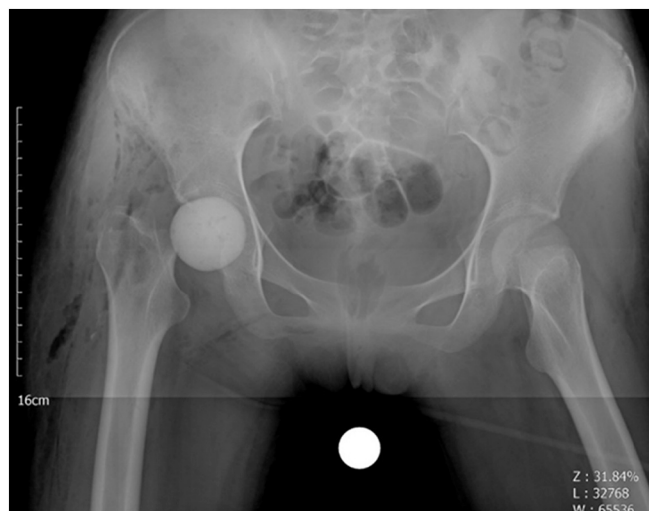


Fig. 1. Lungs CT scan of the patient during COVID-19.



**Fig. 3.** Three weeks post-operation radiography of the patient. Arthrotomy and irrigation and debridement were done for her left side and first stage of total hip replacement for her right side.

**Table 1**  
Laboratory findings related to the patient.

Index	Episode			
	First episode	Second episode	Third episode	Normal range (unit)
Hemoglobin	7	8.9	11	12–16 g/dL
WBC <sup>a</sup>	1.5	6	3	4–10 ( $10^3$ )
RBC <sup>b</sup>	2.19	3.46	3.73	4.2–5.5 ( $10^3$ )
Platelet	135	467	489	150–450 ( $10^3$ )
ESR <sup>c</sup>	58	95	20	<20 mm/h
Serum creatinine	0.6	0.6	0.4	0.5–1 mg/dL
CRP <sup>d</sup>	85	166	22	<20 mg/L
Glucose	–	414	52	<10 mg/dL
Protein	–	1900	43	<3 G/dL
LDH <sup>e</sup>	–	2376	27	<480 U/L

<sup>a</sup> White blood cell.

<sup>b</sup> Red blood cell.

<sup>c</sup> Erythrocyte sedimentation rate.

<sup>d</sup> C-reactive protein.

<sup>e</sup> Lactate dehydrogenase.

aspirates showed the same Gram-negative bacilli recognized before. It was identified as nontyphoidal *Salmonella* serogroup D with the same susceptibility pattern. Antero-posterior radiography and magnetic resonance imaging (MRI) was done for both hips. MRI evaluation showed classic findings of femoral head avascular necrosis as bone marrow edema and serpiginous lines of abnormal signal in the superior and medial aspect of the both femoral heads (Fig. 2). It showed active inflammation without cartilage damage on the left side and cartilage destruction on the right side. Other signs of joint space infection like large amount of joint effusion, synovial thickening and enhancement, inflammation of peri-articular soft tissues especially adductor and gluteal muscles were also seen in both patient's hips. Besides that, osteomyelitis was observed on her right side on the both sides of the hip joint.

### 2.3. Therapeutic intervention

The initial treatment included 14 days of intravenous ceftriaxone (1 g daily) before step down to oral cotrimoxazole (500 mg daily) for 3 weeks and ciprofloxacin for 10 days. On 10th day, drainage was deemed necessary and hip joints surgery took place 3 weeks after therapy. For

her left side arthrotomy and irrigation and debridement were done. We didn't find any cartilage destruction in the left hip. Besides that, she underwent 1st stage of two-stage total hip arthroplasty for her right side and antibiotic cement was installed (Fig. 3). Intra-operative cultures of both hips were also positive for *Salmonella* group D. For treatment of COVID-19 complications, remdesivir (200 mg IV), dexamethasone and tazocin was administrated for 7 days.

### 2.4. Follow up and outcomes

The patient was discharged after third episode of admission and was followed up for 2 months. She had no pain on her left hip and had excellent hip joint motion at three weeks without disturbance while standing and walking. Planning for 2nd stage of total hip arthroplasty has been done for her right side. The successful treatment of *Salmonella* septic arthritis usually requires prolonged antibiotic therapy, typically for at least 4 to 6 weeks. After 6 weeks of antibiotic treatment, her laboratory features fortunately declined to the normal ranges.

Our work is compliant with the SCARE Guidelines 2020 criteria [9].

## 3. Discussion

*Salmonella* is a genus of Gram negative bacilli, and one of the major causes of bacteremia followed by enteric fever [10]. Septic arthritis is a rare consequence of *Salmonella* bacteremia, and is an even more rare joint disorder, and can be caused by various pathogenic microorganisms, including bacteria, viruses, and fungi [11]. This joint infection can cause numerous problems to the patients ranging from joint damage, bone erosion, osteomyelitis, fibrosis, sepsis, or even death. The rate of case fatality for this disorder can reach over 10%, comparable to the fatality rate for other community-acquired infections such as pneumonia [12].

Nontyphoidal *Salmonella* causes an estimated over 1 million infections ranging from gastroenteritis, enteric fever, and bacteremia per year worldwide and generally transmitted via fecal-oral route [13]. Although, hematogenous spread is probably the most frequent cause of *Salmonella* septic arthritis, this type of infection is rarely encountered and is frequently asymmetric [14]. Etiologic organism of this type of infection mainly varies by age and *Staphylococcus aureus* is the most common causative pathogen identified in all age groups followed by group A streptococcus, *Haemophilus influenzae* type b, *Streptococcus pneumoniae*, and *Brucella melitensis* [15].

In this study, the patient experienced hip pain that increased during regular motion after second discharge from hospital, but due to her immunocompromised status and lack of fever, the clinicians did not initially consider the possibility of a septic arthritis. In such cases, a septic arthritis should be considered first in the differential diagnosis and immune-deficient patients with painful joints should be closely followed if symptoms persist. The laboratory features of the patient illustrated that the erythrocyte sedimentation rate (ESR) and C-reactive protein (CRP) of the patient elevated during first and especially second episodes of infections. Also, glucose, protein and lactate dehydrogenase (LDH) of synovial fluid aspirated from both hips raised significantly during second episode of infection and decreased during third episode of hospital admission.

In the present case, there was a history of malignancy and bacteremia three month before the joint involvement and also a history of COVID-19, approximately two months prior to this. The continuous ill health and the ALL state may be the underlying cause for this joint infection. Furthermore, the effective treatment for *Salmonella* septic arthritis contains of antibiotic therapy, aspiration of the joint and surgical intervention if the joint cannot be sufficiently aspirated. Cephalosporins are the choice drug for salmonellosis and in our patient, we conducted antibiotic susceptibility testing, which aided the selection of suitable antibiotics for successful eradication of the nontyphoidal *Salmonella* infection.

#### 4. Conclusion

This case report illustrates the unusual presentation of nontyphoidal *Salmonella* septic arthritis in a patient with underlying disease. Antibiotic treatment and surgical intervention should be initiated by the time the clinical diagnosis is made. Correct diagnosis and successful treatment in this case in addition to hip arthroplasty with the use of a prosthesis and prolonged antimicrobial therapy can be considered in the management of bilateral hip joint destruction and have saved the patient life.

#### Provenance and peer review

Not commissioned, externally peer-reviewed.

#### Ethical approval

Not applicable.

#### Funding

This research did not receive any specific grant from funding agencies in the public, commercial, or not-for-profit sectors.

#### Author contribution

- MS, SN, SM, AA, MV, FM were the clinical advisors of the study.
- PA made the bibliographic research.
- AA wrote a draft, reviewed and edited the manuscript.

#### Guarantor

Amir Aliramezani.

#### Consent

A written consent has been obtained from the patient.

#### Registration of research studies

N/A.

#### Declaration of competing interest

There are no conflicts of interest to declare for this article.

#### References

- [1] S.L. Foley, T.J. Johnson, S.C. Ricke, R. Nayak, J. Danzeisen, *Salmonella* pathogenicity and host adaptation in chicken-associated serovars, *Microbiol. Mol. Biol. Rev.* 77 (April) (2013) 582–607.
- [2] F.N. Qamar, W. Hussain, S. Qureshi, *Salmonellosis including enteric fever*, *Pediatr. Clin. N. Am.* 69 (January) (2022) 65–77.
- [3] T. Hennedige, D.S. Bindl, A. Bhasin, S.K. Venkatesh, *Spectrum of imaging findings in salmonella infections*, *AJR Am. J. Roentgenol.* 198 (June) (2012). W534-W9.
- [4] M. Shanthi, U. Sekar, K. Sridharan, *Septic arthritis of Hip caused by Salmonella typhi: a case report*, *Case Rep. Infect. Dis.* 2012 (2012), 464527.
- [5] A. Kurniawan, I.P. Sitorus, T. Loho, W.D. Hutami, *A rare case of septic arthritis of the knee caused by salmonella typhi with preexisting typhoid fever in a healthy, immunocompetent child—a case report*, *Int. J. Surg. Case Rep.* 78 (2021) 76–80.
- [6] M.H. Gharib, S. Alebbi, F. Rashid, M.F. Elhaj, F.Z. Zahirb, S.A. Emadi, *Salmonella-related septic arthritis in an immunocompetent adult: a case report*, *Cureus* 14 (January) (2022).
- [7] E. Uygur, K. Reddy, F.Ü. Özkan, S. Söylemez, Ö. Aydin, S. Şenol, *Salmonella enteritidis septic arthritis: a report of two cases*, *Case Rep. Infect. Dis.* 2013 (2013), 642805.
- [8] J. Dower, D.P. Lerner, T. Geva, K. Wener, *The risk of immunosuppression: a case of Salmonella meningitis*, *Case Rep. Infect. Dis.* 2018 (2018), 4874575.
- [9] R.A. Agha, T. Franchi, C. Sohrabi, G. Mathew, for the SCARE Group, *The SCARE 2020 guideline: updating consensus Surgical CAse REport (SCARE) guidelines*, *Int. J. Surg.* 84 (2020) 226–230.
- [10] S.-K. Eng, P. Pusparajah, N.-S. Ab Mutalib, H.L. Ser, K.-G. Chan, L.H. Lee, *Salmonella: a review on pathogenesis, epidemiology and antibiotic resistance*, *Front. Life Sci.* 8 (March) (2015) 284–293.
- [11] J.J. Ross, *Septic arthritis*, *Infect. Dis. Clin. N. Am.* 19 (April) (2005) 799–817.
- [12] A.D. Iliadis, M. Ramachandran, *Paediatric bone and joint infection*, *EFORT Open Rev.* 2 (January) (2017) 7–12.
- [13] O. Gal-Mor, *Persistent infection and long-term carriage of typhoidal and nontyphoidal salmonellae*, *Clin. Microbiol. Rev.* 32 (January) (2019) e00088-18.
- [14] N. Le Saux, *Diagnosis and management of acute osteoarticular infections in children*, *J. Paediatr. Child Health* 23 (May) (2018) 336–343.
- [15] M.E. Shirliff, J.T. Mader, *Acute septic arthritis*, *Clin. Microbiol. Rev.* 15 (April) (2002) 527–544.