

5-1-2023

Compound Odontoma:Diagnosis and treatment: Case report

Georgina El Ghoule
Saint Joseph University

Bassam Salameh

Wassim AL MANHAL
Saint Joseph University

Follow this and additional works at: <https://digitalcommons.aaru.edu.jo/iajd>



Part of the [Oral and Maxillofacial Surgery Commons](#), and the [Oral Biology and Oral Pathology Commons](#)

Recommended Citation

El Ghoule, Georgina; Salameh, Bassam; and AL MANHAL, Wassim (2023) "Compound Odontoma:Diagnosis and treatment: Case report," *International Arab Journal of Dentistry*. Vol. 14: Iss. 1, Article 11.

Available at: <https://digitalcommons.aaru.edu.jo/iajd/vol14/iss1/11>

This Case Report is brought to you for free and open access by Arab Journals Platform. It has been accepted for inclusion in International Arab Journal of Dentistry by an authorized editor. The journal is hosted on [Digital Commons](#), an Elsevier platform. For more information, please contact rakan@aar.edu.jo, marah@aar.edu.jo, u.murad@aar.edu.jo.

COMPOUND ODONTOMA: A CLINICAL CASE PRESENTATION

Georgina el Ghoul¹ | Bassam Salameh² | Wassim El Manhal³

Abstract: Odontomas are asymptomatic benign odontogenic tumors, generally discovered fortuitously, or when a tooth failed to erupt. They are mainly composed of enamel and dentin, cement and pulp tissue can also be present in variable amounts. In 2005, the World Health Organization classified two main types of odontoma, an amorphous and irregular mass of calcified dental tissues as complex odontoma and multiple miniature tooth-like structures as compound odontoma. This article is a case presentation of a compound odontoma diagnosed for an eleven year old girl upon a routine radiography, making it a lesion of childhood /adolescence. A retro-alveolar radiography of the anterior maxilla revealed a radiopaque mass with prominent external margins surrounded by a thin radiolucent rim in close contact with the root of the permanent right central incisor. In this case a surgical excision of the lesion was performed in order to prevent any risk of root resorption for the tooth in close contact. The results achieved indicate that the early diagnosis of odontomas allows the adoption of a less complex and inexpensive treatment and ensures better prognosis. A histological evaluation is imperative in order to confirm the exact diagnosis of odontoma.

Key words: Compound odontoma, odontogenic benign tumor, Tooth-like, Maxilla.

Corresponding author:

Georgina el Ghoul. E-mail: georginaelghoule@gmail.com

Conflicts of interest:

The authors declare no conflicts of interest.

1. Department of Periodontology, Faculty of Dental Medicine, Saint Joseph University of Beirut, Beirut Lebanon. georginaelghoule@gmail.com

2. DDS, Master in Periodontology. dr.dassamsalameh@hotmail.com

3. Department of Oral Pathology, Clinical Professor and Co-Director of Cranio-Facial Research Laboratory, Faculty of Dental Medicine, Saint Joseph University ,Beirut Lebanon. Wassim.manhal@usj.edu.lb

ODONTOME COMPOSÉ: PRESENTATION D'UN CAS

Résumé: Les odontomes sont des tumeurs odontogéniques bénignes, asymptomatiques, généralement découverts fortuitement ou lors du retard de l'éruption d'une dent. Ils sont principalement composés d'email, de dentine avec parfois présence d'une quantité variable de ciment et du tissu pulpaire.

En 2005, L'Organisation Mondiale de Santé (OMS) classe les odontomes en 2 types principaux: type complexe constitué d'une masse irrégulière de tissus dentaires calcifiés et organisés de façon anarchique, type composé renferme de multiples fragments de petites dents.

Cet article est une présentation d'un cas d'odontome composé diagnostiqué fortuitement chez une patiente de 11 ans à l'occasion d'un examen radiographique de routine. La majorité de cas apparaissent avant l'âge de 20 ans, ce qui les rendent des lésions d'enfance/ adolescence. Une radiographie rétro-alvéolaire révèle la présence d'une masse radio-opaque entourée d'un halo radioclaire au niveau de la région antéro-maxillaire et en contact intime avec la racine de l'incisive centrale permanente supérieure droite. L'excision chirurgicale de la lésion a été performée afin d'éviter tout risque de résorption de la dent en contact. Les résultats obtenus confirment que le diagnostic précoce des odontomes permet l'adoption d'un traitement facile et peu coûteux assurant le meilleur pronostic. Une évaluation histologique s'avère impérative afin de confirmer le diagnostic de l'odontome.

Mots clés: Odontome composé, tumeur bénigne odontogène, en forme de dent, maxillaire.

Introduction

Compound odontomas are benign odontogenic neoplasms that can produce all the tissue found in a mature tooth (enamel, dentin, cementum, and pulp) [1,2,3]. They are more common in the anterior region of the maxilla, the etiology is unknown [4]. However, a medical history of trauma and infection at the place of the lesion could be a reason for its appearance [5]. They are asymptomatic, have slow growth and rarely exceed the size of a tooth, and can cause expansion of the cortical bone if they grow large [6].

The aim of this case report is to describe a minimally invasive surgical technique to remove a compound odontoma localized in the anterior maxilla and to be harmless to the root of the teeth in contact. The purpose of this procedure is to preserve as much as possible the surrounding bone tissue in order to promote healing and cause less discomfort to the patient during postoperative time.

Case report

An eleven year old female showed up for a routine dental examination. She did not have a positive medical history of any hereditary disease. Intraoral examination revealed normal eruption of the four maxillary permanent incisors, perfectly formed and well arranged. Clinically, there was no detectable swelling or bone expansion in the maxilla (Fig. 1a, 1b). A retro-alveolar radiography revealed a lesion of the anterior maxilla (Figure 2a). Neither the patient nor her parents could recall any history of oral trauma, pain or swelling in the area. A careful evaluation with panoramic (Fig. 2b) and CBCT X-Rays (Fig. 3), revealed a palatal position of a calcified collection of tooth-like structures in the center of a well-defined unilocular radiolucent lesion apical to the right upper permanent incisors. According to

clinical and radiographic examinations, provisional diagnosis considered the lesion as odontoma. The removal of the mass under local anesthesia was planned to prevent any risk of root resorption for the tooth in close contact. The patient had a single dose of amoxicillin(500mg) 1 hour before surgery. Surgery was performed under local anesthesia (2% mepivacaine with 1:100,000 epinephrine) injected in the palatal gingiva from the right canine to the left lateral incisor. A full-thickness mucoperiosteal palatal flap was raised between the upper right canine to the left upper lateral incisor and bone was removed using the PIEZO SURGICAL device (Mectron) instead of the use of the traditional burs or saws. The piezo-technology provides micrometric cuts for minimally invasive surgery with maximum surgical precision, and no risk to damage the soft tissue. This technique offers maximum intra-operative visibility, the cavitation effect of the ultrasonic movements leads to a blood free surgical site. This surgical technique with maximum precision and control, facilitates not only the surgery itself, but reduces postoperative discomfort for the patient at the same time [7,3]. The OT7 piezo surgical insert was used to perform bone removal until the multiple structures of the odontoma were exposed, then easily enucleated from its bony bed with a surgical curette. The wound was carefully irrigated with physiological solution, the flap was repositioned and sutured with 4/0 silk non-resorbable sutures (Fig. 4a, 4b). The specimen

consisted of several malformed tooth-like structures. Tissues were fixed with formalin 10 % and sent for anatomopathological evaluation.

The postoperative period was uneventful. Postoperative treatment consisted of amoxicillin (500mg/3 times/day for 5 days), paracetamol (500mg twice a day for 2 days) with mouthwash, warm water and salt. Sutures were removed 10 days later. The gross surgical specimen consisted of 4 malformed tooth-like structures (Fig. 4c). Tissue was decalcified, and went through various chemical steps (dehydration and dissolving of fat) in preparation for embedding into a paraffin block. The paraffin blocks are placed on a special machine that uses an extremely sharp knife (Leica microtome) to shave every thin piece of tissue of about 4 micrometers in thickness. The thin pieces are placed on a glass slide and stained with Hematoxylin and eosin, also known as H&E. It is a combination of basic stain (Hematoxylin) and an acidic stain (eosin). This reacts with acidic and basic cellular components on the slide to give, respectively, purple and pink colors to the tissues. H&E stained material showed under Leica optic microscope at the 40x magnification a mass of tooth-like structures composed of dentin and cementum with centrally located loose fibrous tissue, representing pulp tissue (Fig. 5a). A Small amount of enamel matrix was identified. Proper patient care should include careful clinical and radiological follow-up (Fig. 5b ,6).

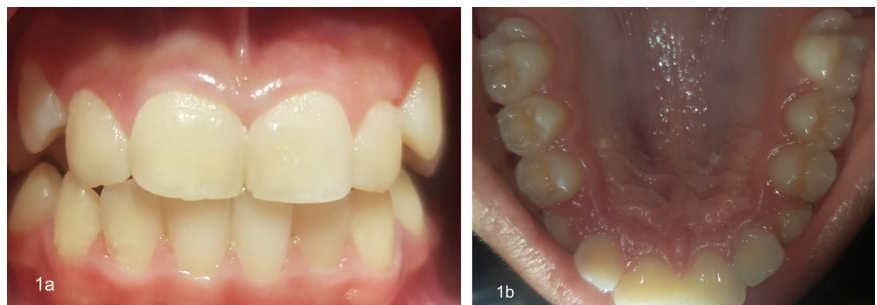


Fig. 1a, 1b: Intra oral view before surgery

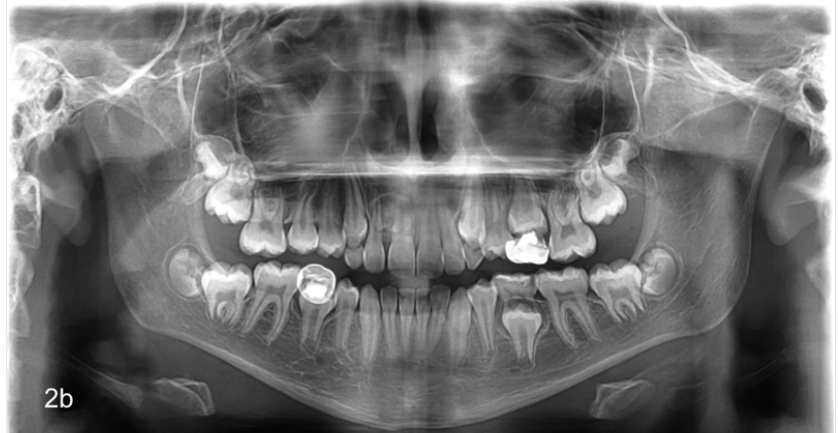
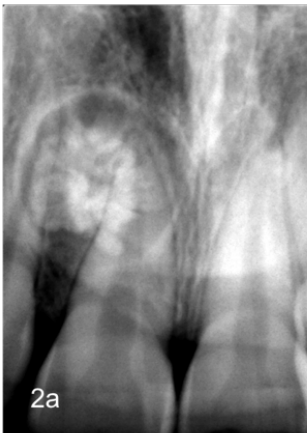
Fig. 2a: A small cluster of tooth-like structures surrounded by a narrow radiolucent zone.
 Fig. 2b: Panoramic X-Ray showed multiple radiopaque structures compatible with a provisional diagnosis of compound odontoma.

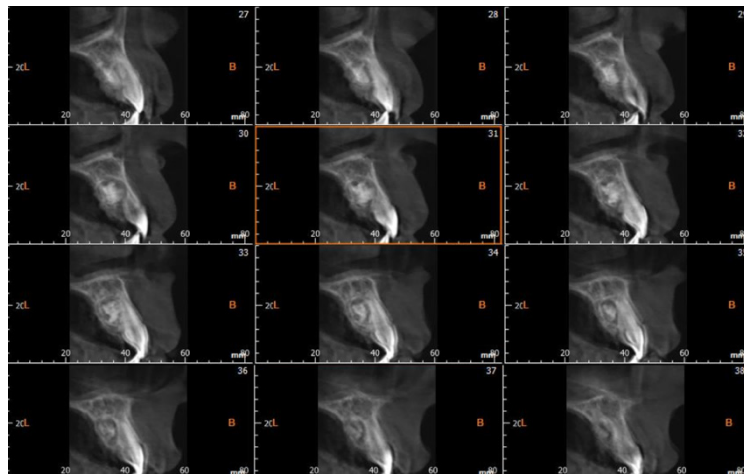


Fig. 3: A CBCT view performed in order to define the extension of the lesion and the anatomical topography, showing the odontoma positioned palatally to the upper right permanent incisors.

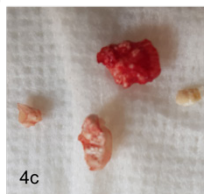
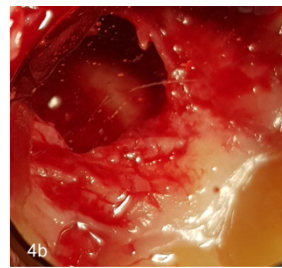
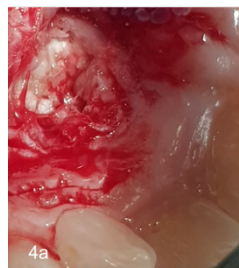

Fig. 4a: Mucoperiosteal flap reflection and bone removal.
 Fig. 4b: Surgical site after removal of compound odontoma.
 Fig. 4c: Surgical specimen consisting of four malformed tooth like structures.

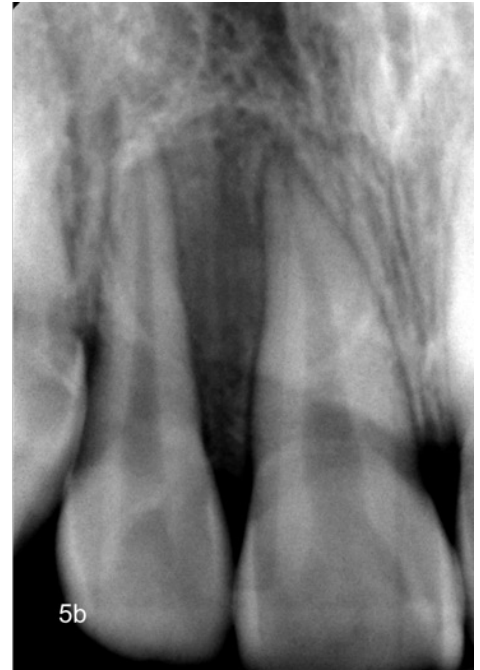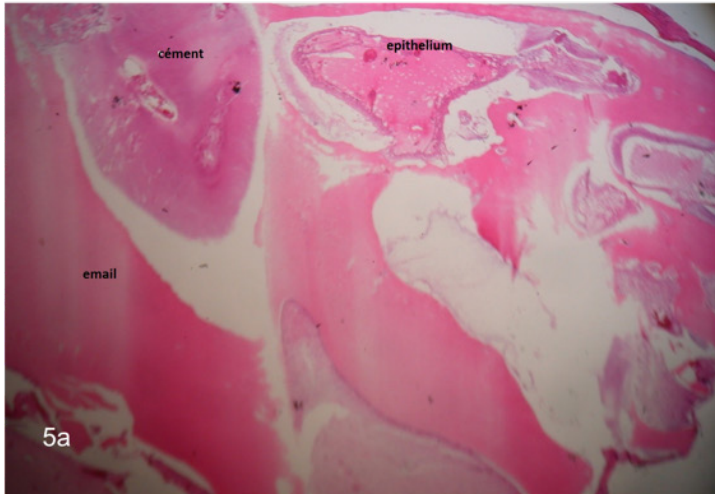


Fig. 5a: Histological section, Hematoxylin and eosin stain.
Fig. 5b: Retroalveolar X-Ray one month post surgery.

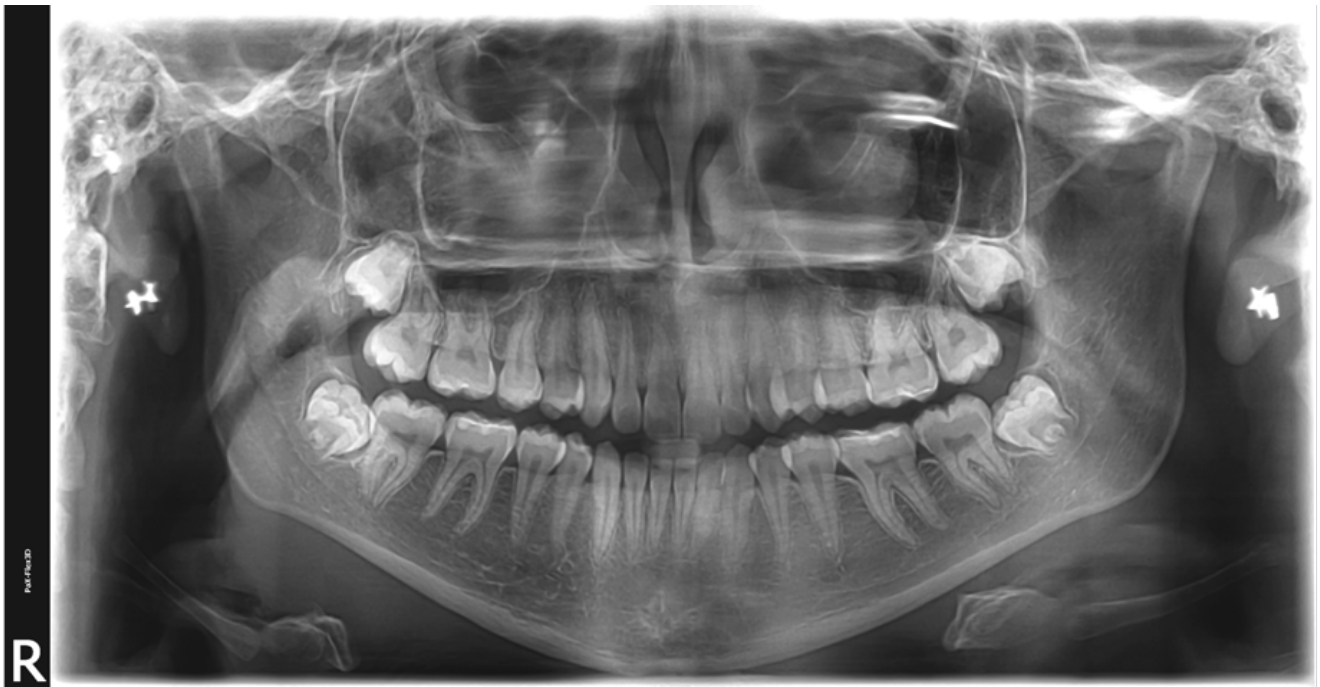

Fig. 6: Panoramic X-Ray showed no recurrence four years later.

Discussion

Odontomas are the most common types of benign odontogenic tumors [6]. They are considered to be developmental anomalies and are usually asymptomatic, painless, slow growing, often discovered during routine radiography or when X-Rays are taken to determine the reason when a permanent tooth or multiple teeth fail to erupt [8]. They can be associated with changes such as malformation, impaction, delayed eruption, malposition, cyst formation, displacement, resorption of the adjacent teeth, and expansion of the cortical plate, they have a non aggressive characteristic. Symptoms that may be present include numbness in the lower lip, frontal headaches, swelling in the affected areas, and facial asymmetry [9,10]. They may be found at any age; but most of the reported cases have occurred before the age of 30; however, most are detected in the first two decades of life, and the mean age at the time of diagnosis is 14 years as in the present case. Males are affected more than females with the ratio of 1.5 : 1 to 1.6 : 1. Rarely, an odontoma may erupt into the oral cavity. They are generally small; however, they may occasionally grow large resulting in bone expansion of the jaw [2,5,11].

The etiology of odontomas is not clearly understood. However, several researchers have reported various etiological factors, including local trauma, infection, family history, and genetic mutation. Hitchen (1971) has also suggested that they are inherited from a mutant gene or interference, possibly postnatal, with the genetic control of tooth development [12].

Based on their gross and radiographic features, odontomas are subdivided into compound and complex types. Complex odontomas are less common than the compound variety in the ratio 1:2

[13]. Compound odontomas tend to occur between teeth as a calcified tissue that recapitulates the organization of a normal tooth, small tooth-like structures of varying size and shape surrounded by a narrow radiolucent zone, while complex type appears as a disorganized mass of hard odontogenic tissue, a conglomeration of dentin, enamel and cementum with no anatomic resemblance to a tooth which is also surrounded by a narrow radiolucent rim [2,14]. Both types are made up of enamel matrix, dentin, cementum and dental pulp surrounded by a dental follicle or cyst. Compound odontomas appear as a collection of small teeth, leaving few entities in the radiographic differential diagnosis except perhaps a supernumerary tooth [14]. Whereas complex odontoma may be radiographically confused with an osteoma or other calcified bone lesion. Both have radiolucent rims, representing dental follicular tissue or, less commonly, a dentigerous cyst [2,14,6]. The compound type is more commonly found in the anterior maxilla, as in the present case, while the complex one tends to favor the molar regions of either jaw [15].

Histologically, the compound odontoma is not a diagnostic dilemma, it recapitulates the organization of a normal tooth contained in a fibrous matrix. However, mature enamel is lost during the decalcification processing and will not be seen on conventional hematoxylin and eosin stained slides, but a varying amount of enamel matrix are often present. Pulp tissue may be seen in the coronal and root portions of the toothlike structures [5]. Loose, myxoid connective tissue with odontogenic epithelial rests may be seen in close association with the lesion, and most often represents normal dental follicular tissue. A thin fibrous capsule, or occasionally, a cyst wall, is also seen surrounding the lesion [3].

The complex odontoma consists primarily of a disordered mixture of odontogenic tissues [2], often spherical in shape, consisting largely of mature tubular dentin. The decalcified section shows a disorganized mass of dentine intermixed with some pools of enamel matrix or immature enamel. Small islands of eosinophilic-staining epithelial ghost cells are present in about 20% of complex odontoma. A thin layer of cementum is often present on the periphery of the mass. A dentigerous cyst may arise from the epithelial lining of the fibrous capsule of the complex odontoma.

A differential diagnosis must rule out:

- The ameloblastic fibro-odontoma, a rare odontogenic tumor contains ameloblastomatous component and odontoma-like elements. This neoplasm appears to occur in younger patients and either jaw can be affected and frequently confused with an odontoma that is in its early stages of development. Clinically; Pain, delayed eruption of teeth, and expansion of the affected bone. Radiographically; radiolucent lesion, a destructive process that contains calcified structures may resemble miniature teeth. Histologically; the ameloblastic component is mixed with immature or more mature dental tissue resembling the appearance of a compound odontoma. High risk of recurrences after local curettage [1,14,16].
- The calcifying odontogenic cyst (Gorlin Cyst) is a developmental cyst that arises from tooth-forming epithelium. Pericoronal lesions develop from reduced enamel epithelium of the dental follicle. It occurs with about equal frequency in the maxilla and the mandible. The mean age is 30 years. Calcifying odontogenic cysts that are asso-

ciated with odontomas tend to occur in younger patients, with a mean age of 17 years [17]. Radiographic features: A circumscribed unilocular lesion with local or diffuse calcifications or tooth-like densities producing a mixed radiolucent-radiopaque appearance [17,18]. The radiolucent lesions are often associated with an unerupted tooth, most often a canine. May cause erosion of the roots of adjacent teeth, and can be associated with cortical expansion. Microscopic examination of the lesion is necessary to confirm the diagnosis. The prognosis for the patient with a Calcifying odontogenic cyst is good after surgical enucleation; only a few cases of recurrences have been reported [19].

- The calcifying epithelial odontogenic tumor (Pindborg tumor), a benign neoplasm that arises from the reduced enamel epithelium that lines the dental follicle or from remnants of the dental lamina. More common in adults with no sex predilection. A painless, slow-growing swelling is the most common presenting sign, cortical expansion may be present. Radiographically, the tumor exhibits a unilocular or multilocular lesion with focal or diffuse calcifications producing a mixed radiolucent-radiopaque appearance, commonly associated with an impacted tooth, most often a mandibular molar. Microscopic examination of the lesion is necessary to confirm the diagnosis. Surgical resec-

tion is the treatment of choice, a recurrence rate of about 15% has been reported [1,20].

Conclusion

Treatment for an odontoma is a complete surgical removal with any associated soft tissues [21,22]. Recurrences do not occur. Orthodontic treatment may be indicated to correct any malocclusion [2,23]. Radiographically, the compound odontoma appears as a collection of tooth-like structures of varying size and shape surrounded by a narrow radiolucent zone. They are treated by simple local excision, and the prognosis is excellent

References

1. Ahmed SAM, Muyidi HM, Mashraqi MM, Mashi MH, Ali FM. An unusual case report of impacted deciduous mandibular canine due to compound odontoma. *J Evolution Med Dent Sci* 2020;9:170-72.
2. Nelson BL, Thompson LDR. Compound Odontoma. *Head Neck Pathol.* 9 June 2010;4(4):290-1.
3. Neville B, Damm D, Allen C, Chi A, Oral and Maxillofacial Pathology- Fourth Edition.
4. TORUL D., KESKIN M., GUN S., ODABASI D., 2020: Complex-Compound Odontoma: A Rare Clinical Presentation.-ODONTOS-Int. J. Dental Sc., 22-1 (January-April): 23-28.
5. Soluk Tekkesin M, Pehlivan S, Olgac V, Aksakallı N, Alatlı C. Clinical and histopathological investigation of odontomas: review of the literature and presentation of 160 cases. *J Oral Maxillofac Surg.* June 2012;70(6):1358-61.
6. Shekar S., Rao R. S., Gunasheela B., Supriya N. Erupted compound odontoma. *J Oral Maxillofac Pathol.* 2009;13(1):47-50. 2.
7. Gleizal A, Li S, Pialat JB, Béziat JL. Transcriptional expression of calvarial bone after treatment with low-intensity ultrasound: An in vitro study. *Ultrasound Med Biol.* 2006;32(10):1569-1574.
8. Mupparapu M., Singer S. R., Rinaggio J. Complex odontoma of unusual size involving the maxillary sinus: report of a case and review of CT and histopathologic features. *Quintessence Int.* 2004;35(8):641-5
9. Kuta AJ, Worley CM, Kaugars GE. Central cemento ossifying fibroma of the maxillary sinus: a review of six cases. *AJNR Am J Neuroradiol.* 1995;16(6):1282-6
10. Shah S, Kim JE, Huh KH, Yi WJ, Heo MS, Lee SS. Recurrent osteoblastoma of the maxilla. *Dentomaxillofac Radiol.* mai 2013;42(5):20100263.
11. Vercellotti T, Stacchi C, Russo C, Rebaudi A, Vincenzi G, Pratella U, Baldi D, Mozzati M, Monagheddu C, Sentineri R, Cuneo T, Di Alberti L, Carossa S, Schierano G. Ultrasonic implant site preparation using piezosurgery: a multicenter case series study analyzing 3,579 implants with a 1-to 3-year follow-up. *Int J Periodontics Restorative Dent.* 2014 jan-feb;34(1):11-18.
12. A D Hitchin. The aetiology of the calcified composite odontomas. *Br Dent J.* 1971.Br Dent J. 1971 June 1;130(11):475-82.
13. Singia M, Verma KP, Goyal T, Kakkar A, Ahuja L. Compound odontoma in primary dentition- A case report. *J Oral Med Oral Surg Oral Pathol Oral Radiol* 2017; 3: 62-4.
14. Gedik R, Müftüoğlu S. Compound Odontoma: Differential Diagnosis and Review of Literature. *West Indian Med J. déc* 2014;63(7):793-5.
15. Tejasvi M. L. A., Babu B. B. Erupted compound odontomas: a case report. *J Dent Res Dent Clin Dent Prospects.* 2011;5(1):33-6.
16. Sanjai K, Pandey B, Shivalingaiah D, Kumar HM. Odontoameloblastoma: A report of a rare case. *J Oral Maxillofac Pathol.* 2018;22(2):254-9.
17. Tejasvi M. L. A., Babu B. B. Erupted compound odontomas: a case report. *J Dent Res Dent Clin Dent Prospects.* 2011;5(1):33-6
18. Constantino Ledesma-Montes, Robert J Gorlin, Mervyn Shear, Finn Praetorius, Adalberto Mosqueda-Taylor, Mario Altini, Krishnan Unni, Oslei Paes de Almeida, Roman Carlos-Bregni, Elias Romero de leon, Vince Phillips, Wilson Delgado-Azañero, Abelardo Meneses-Garcia. International collaborative study on ghost cell odontogenic tumours: calcifying cystic odontogenic tumour, dentinogenic ghost cell tumour and ghost cell odontogenic carcinoma. *J Oral Pathol Med.* 2008 May;37(5):302-8
19. Richard H. Swan, Glen D.Houston, Stephen P. Moore. Peripheral Calcifying Odontogenic Cyst (Gorlin Cyst) - Swan - 1985 - *Journal of Periodontology.* Volume 56, issue 6,340-343.
20. Singh N, Sahai S, Singh S, Singh S - Natl J. Calcifying epithelial odontogenic tumor (Pindborg tumor). *Maxillofac Surg.* 2011 jul;2(2):225-7
21. Amailuk P, Grubor D. Erupted compound odontoma: case report of a 15-year-old Sudanese boy with a history of traditional dental mutilation. *Br. Dent J.* 2008;204(1):11-4.
22. Barba LT, CamposDM, Rascon MMN, BarreraVAR, Rascón AN. Descriptive aspects of odontoma: literature review. *Revista Odontologica Mexicana* 2016;20;265-69.
23. Hamada M, Okawa R, Nishiyama K, Nomura R, Uzuwa N, Nakano K. Compound Odontoma Removed by Endoscopic Intraoral Approach: Case Report. *Dent J (Basel).* 7 July 2021;9(7):81.