




RESEARCH ARTICLE

Spontaneous Haemoperitoneum in Pregnancy: Nationwide Surveillance and Delphi Audit System

Anneke M. F. Schreurs^{1,2,*}  | Evelien M. Overtoom^{3,*}  | Marjon A. de Boer^{2,4} |
 Lisette E. E. van der Houwen^{1,2} | Marit C. I. Lier^{1,2} | Thomas van den Akker^{5,6} |
 Jerome Cornette⁷ | Tatjana E. Vogelvang⁸ | Ingrid C. M. Beenackers⁹ | Ageeth N. Rosman¹⁰  |
 Jacques W. M. Maas¹¹ | David J. Heineman¹² | Martijn J. J. Finken^{2,13} | Jan J. J. de Vries¹⁴ |
 Nicole B. Burger¹⁵ | Timme P. Schaap³ | Kitty W. M. Bloemenkamp³ | Velja Mijatovic^{1,2}

¹Department of Reproductive Medicine, Amsterdam UMC, Vrije Universiteit Amsterdam, Amsterdam, the Netherlands

²Amsterdam Reproduction and Development Research Institute, Amsterdam, the Netherlands

³Department of Obstetrics, Division Woman and Baby, Birth Centre Wilhelmina's Children Hospital, University Medical Centre Utrecht, Utrecht, the Netherlands

⁴Department of Obstetrics and Gynaecology, Amsterdam UMC, Vrije Universiteit Amsterdam, Amsterdam, the Netherlands

⁵Department of Obstetrics and Gynaecology, Leiden University Medical Centre, Leiden, the Netherlands

⁶Athena Institute, VU University, Amsterdam, the Netherlands

⁷Department of Obstetrics and Fetal Medicine, Erasmus MC, Rotterdam, the Netherlands

⁸Department of Obstetrics and Gynaecology, Diaconessenhuis, Utrecht, the Netherlands

⁹Department of Anaesthesiology, Division Vital Functions, Wilhelmina's Children Hospital, University Medical Centre Utrecht, Utrecht, the Netherlands

¹⁰Perined, Utrecht, the Netherlands

¹¹Department of Obstetrics and Gynaecology and GROW – School for Oncology and Reproduction, Maastricht UMC+, Maastricht, the Netherlands

¹²Department of Surgery and Cardiothoracic Surgery, Amsterdam UMC, Vrije Universiteit Amsterdam, Amsterdam, the Netherlands

¹³Department of Paediatric Endocrinology, Emma Children's Hospital, Amsterdam UMC, Vrije Universiteit Amsterdam, Amsterdam, the Netherlands

¹⁴Department of Radiology, Amsterdam UMC, Vrije Universiteit Amsterdam, Amsterdam, the Netherlands

¹⁵Department of Gynaecology, Amsterdam UMC, University of Amsterdam, Amsterdam, the Netherlands

Correspondence

A.M.F. Schreurs, Amsterdam UMC, Vrije Universiteit Amsterdam, De Boelelaan 1117, 1081 HV Amsterdam, the Netherlands.
 Email: a.schreurs@amsterdamumc.nl

Abstract

Objective: To evaluate the incidence, diagnostic management strategies and clinical outcomes of women with spontaneous haemoperitoneum in pregnancy (SHiP) and reassess the definition of SHiP.

Design: A population-based cohort study using the Netherlands Obstetric Surveillance System (NethOSS).

Setting: Nationwide, the Netherlands.

Population: All pregnant women between April 2016 and April 2018.

Methods: This is a case study of SHiP using the monthly registry reports of NethOSS. Complete anonymised case files were obtained. A newly introduced online Delphi audit system (DAS) was used to evaluate each case, to make recommendations on improving the management of SHiP and to propose a new definition of SHiP.

Main outcome measures: Incidence and outcomes, lessons learned about clinical management and the critical appraisal of the current definition of SHiP.

*These authors contributed equally to this work.

This is an open access article under the terms of the [Creative Commons Attribution-NonCommercial](https://creativecommons.org/licenses/by-nc/4.0/) License, which permits use, distribution and reproduction in any medium, provided the original work is properly cited and is not used for commercial purposes.

© 2023 The Authors. *BJOG: An International Journal of Obstetrics and Gynaecology* published by John Wiley & Sons Ltd.

Results: In total, 24 cases were reported. After a Delphi procedure, 14 cases were classified as SHiP. The nationwide incidence was 4.9 per 100 000 births. Endometriosis and conceiving after artificial reproductive techniques were identified as risk factors. No maternal and three perinatal deaths occurred. Based on the DAS, adequate imaging of free intra-abdominal fluid, and identifying and treating women with signs of hypovolemic shock could improve the early detection and management of SHiP. A revised definition of SHiP was proposed, excluding the need for surgical or radiological intervention.

Conclusions: SHiP is a rare and easily misdiagnosed condition that is associated with high perinatal mortality. To improve care, better awareness among healthcare workers is needed. The DAS is a sufficient tool to audit maternal morbidity and mortality.

KEY WORDS

ART, endometriosis, fetal morbidity, maternal morbidity, NethOSS, obstetric surveillance system, SHiP

1 | INTRODUCTION

Spontaneous haemoperitoneum in pregnancy (SHiP) is a rare, but life-threatening complication of pregnancy, characterised by the occurrence of intra-abdominal haemorrhage without prior trauma. Incidental cases of SHiP have been described in the literature for over a century. It was not until recently that SHiP was proposed as a diagnosis of relevance to consider.¹ The variety of cases characterised as SHiP in the literature is significant. In a Delphi study conducted by the International Network of Obstetric Survey Systems (INOSS), SHiP was defined as ‘Spontaneous (nontraumatic) intraperitoneal haemorrhage during pregnancy and up to 42 days postpartum, requiring surgical intervention or embolization, and excluding ectopic pregnancy, uterine rupture and caesarean section associated bleeding’.² SHiP predominantly occurs in the third trimester but has been described throughout the entire pregnancy and postpartum period.³ SHiP usually presents with a sudden onset of abdominal pain accompanied by a decrease in haemoglobin level. If the diagnosis is delayed or the haemorrhage is severe, SHiP may lead to severe complications, such as maternal hypovolemic shock, emergency surgery, perinatal death and even maternal death. Moreover, SHiP events may have a profound psychological impact.⁴

The exact incidence of SHiP is unknown. To date, over 170 cases of SHiP have been reported, many of which are single case reports.^{1,5–12} Over the years, several risk factors for SHiP have been suggested, such as endometriosis and artificial reproductive techniques (ART).^{1,3,13,14} It is estimated that 0.3% of women with endometriosis who conceived with ART develop SHiP over the course of pregnancy, but high-quality prospective population-based data are lacking.^{15,16} Given the limited data about SHiP, recommendations for the diagnosis and management of SHiP are not supported by robust evidence. Although the first cases emerging in the literature appeared to be managed predominantly by surgery, a recent case series suggests that expectant, conservative management might be more appropriate in selected cases.⁷ As imaging techniques are improving, the need for surgery

to establish a diagnosis is now decreasing. When the maternal and fetal conditions are stable, expectant management might be considered.⁷ However, the consensus definition of SHiP proposed by INOSS does not include women who were managed expectantly, without surgery or embolisation.² As SHiP may still be present without such interventions, it is questionable whether this consensus definition is appropriate for future use.

The objectives of this present study were to: (i) audit reported cases of SHiP in the Netherlands prospectively and evaluate the incidence, clinical outcomes, and diagnostic and management strategies; and (ii) reassess the definition of SHiP based on prospective data.

2 | METHODS

2.1 | Data set

Data were used from the Netherlands Obstetric Surveillance System (NethOSS), a prospective national registration study that was performed in the Netherlands between April 2016 and April 2018. All Dutch hospitals with an obstetrician-led maternity ward were contacted through a monthly email in this period and asked to report ‘every spontaneous intra-abdominal bleeding occurring during pregnancy or in the postpartum period (up to 42 days postpartum) that is not the result of trauma or extra-uterine pregnancy’ or to reply with ‘nothing to report’.

Upon receiving a case notification, reporting hospitals were contacted to supply complete (anonymised) case file copies to NethOSS.

2.2 | Delphi audit system

All cases were summarised using a uniform format and then distributed to an audit panel consisting of 15 members. The audit panel included two consultant obstetrician-gynaecologists from the Dutch Working Group on

Endometriosis, a special interest group (SIG) of the Dutch Society of Obstetrics & Gynaecology (NVOG), five consultant obstetrician-gynaecologists from the Dutch Working Group on Maternal Diseases and Perinatology, three residents from Obstetrics & Gynaecology, an anaesthetist and member of the audit committee for maternal mortality and morbidity (AMSM), a paediatrician, a surgeon, a radiologist and a midwife who is involved in NethOSS research.

The audit panel was asked to evaluate cases using a newly introduced technique for auditing medical cases: an online Delphi audit system (DAS).¹⁷ During the DAS process, the audit panel was asked to answer the same audit questions per case using a 5-point Likert scale. Open-ended questions were used to specify the outcomes. Audit questions aimed to identify possible difficulties in diagnosing and managing SHiP. Audit questions are presented in Appendix S1. Where in the past, (inter)national registrations of obstetric cases primarily presented data on incidence with an overview of all cases and outcomes, we also aimed to investigate the lessons learned from the cases.^{18–21}

Three rounds of audit were performed. In the first round, all audit questions were answered, with an option to add explanatory comments. For each case, auditors could indicate that not enough information was present to answer the question or that the question was not applicable. Using the answers, a rate of agreement (RoA) was calculated:

$$\text{RoA} = \frac{(\text{strongly})\text{agree} - (\text{strongly})\text{disagree}}{(\text{strongly})\text{agree} + (\text{strongly})\text{disagree} + \text{undecided}} \times 100,$$

where RoA > 70% was defined as reaching consensus. When the RoA for an audit question did not exceed 70%, this question was resubmitted to the audit panel in the next round. Twelve auditors completed the first round of the audit (Figure 1). In the second round, comments from the first round were shown. Providing an additional comment or explanation to each answer was encouraged. Questions that seemed inapplicable for a case were removed or redefined. One auditor discussed the cases of the second round face-to-face with one of the researchers. Ten auditors completed the second audit round. For questions that did not yield consensus (RoA < 70%) in the second round, a third and final online consensus meeting was organised. In the third round, all questions that did not lead to consensus were marked and discussed. Nine auditors joined the third audit round. Next to the audit of the cases, two additional topics were added to the final round. First, the definition of SHiP was discussed by the expert panel and then an adjusted definition of SHiP was defined after consensus, based on the critical appraisal of the data collected for all included cases. Second, the strategies for diagnosis and management were also evaluated, and the expert panel agreed on care improvements and recommendations related to these strategies.

2.3 | Outcome measures

Outcome measures were population-based incidence of SHiP, characteristics and clinical outcomes of SHiP, and lessons learned regarding diagnosis and management. Furthermore, the current definition of SHiP as proposed by the INOSS consortium was discussed in the online consensus meeting and adaptations were suggested.²

2.4 | Ethics statement

NethOSS registrations are part of the National Perinatal Registry foundation in the Netherlands (Perined). Perined is granted administrative permission to access patient information from medical files held in the Netherlands if the information is anonymised. All pregnant women are included unless they had specifically requested to be excluded. Ethical approval was granted by the Institutional Review Board of University Medical Centre Utrecht (ref. 14–127). All procedures performed in studies involving human participants were in accordance with the ethical standards of the institutional and/or national research committee and with the World Medical Association Declaration of Helsinki or comparable ethical standards.²²

3 | RESULTS

3.1 | Incidence of SHiP

Between April 2016 and April 2018, 327 195 births were registered in Perined, the Dutch register for perinatal registrations and perinatal audit. In total, 24 potential cases of SHiP were registered prospectively with NethOSS by Dutch obstetric units. Four cases were excluded: three cases were registered incorrectly (as stated by the reporting clinician after requesting additional information) and hospital records could not be retrieved for the remaining case, despite multiple attempts to obtain these. In total, 20 cases were presented to the audit panel.

After the first audit round, the auditors agreed that a diagnosis of SHiP was justified in 11 women (Figure 1). They did not agree on a diagnosis of SHiP for the other nine women. After the second audit round, the auditors agreed that a diagnosis of SHiP was justified for three of these nine women and that a diagnosis of SHiP was unjustified for three women. They did not agree on a diagnosis of SHiP for another three women. In the third audit round, which was the online consensus meeting, a diagnosis of SHiP was discussed for these three remaining cases. In the third round, the auditors agreed that a diagnosis of SHiP was not justified for these three women. After three audit rounds, 14 women with 16 births, including two twin pregnancies, were diagnosed with SHiP, resulting in an incidence of SHiP of 4.9 per 100 000 births in the Netherlands.

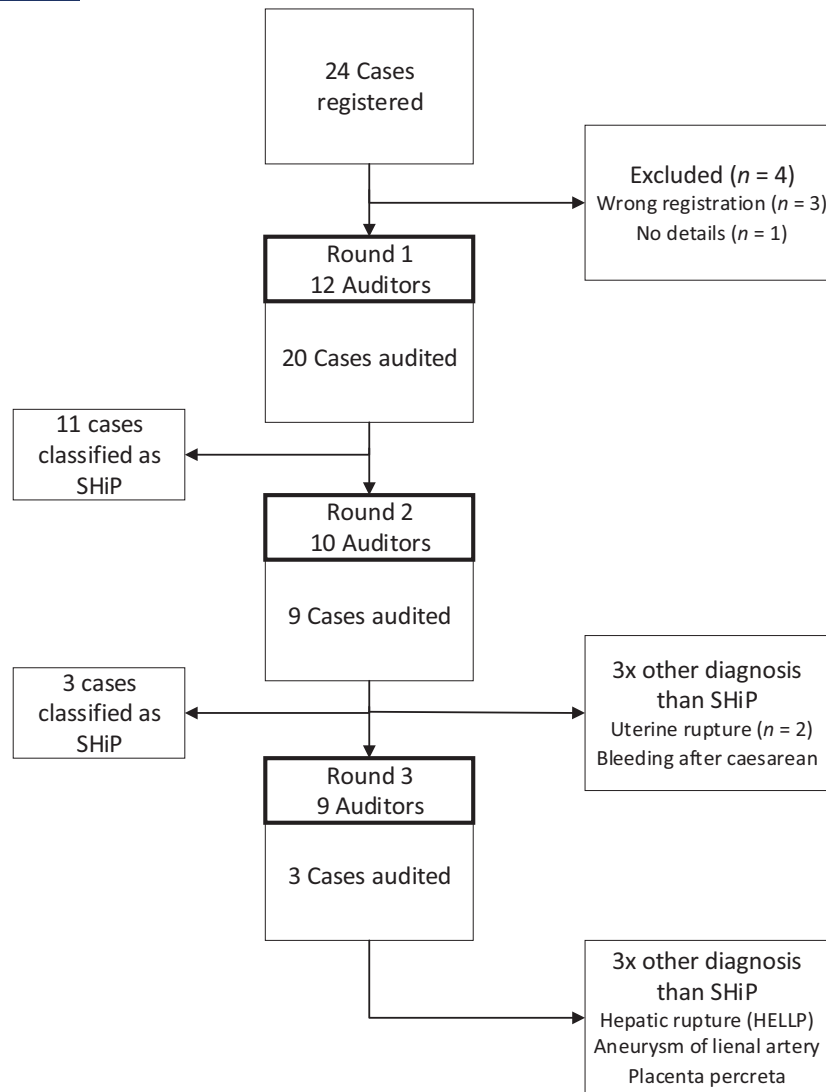


FIGURE 1 Audit of SHiP cases.

3.2 | Maternal outcomes

The median age was 36 years (range 26–39 years). Eight women were nulliparous and two women were pregnant with twins. SHiP occurred from 6 weeks of gestation up to 9 days postpartum. Two pregnancies were conceived with intrauterine insemination (IUI) and three pregnancies were conceived with in vitro fertilisation/intra-cytoplasmic sperm injection (IVF/ICSI). The medical files of four out of 14 women mentioned a diagnosis of endometriosis prior to SHiP and one woman was diagnosed with endometriosis during the planned caesarean section a few weeks after SHiP. Five of 14 women conceived by ART, three of whom had also been diagnosed with endometriosis. No patient delay of importance was reported in the time to diagnosis of SHiP. Almost all women presented with (acute) abdominal pain, two women presented with hypovolemic shock and two women presented with collapse. The initial differential diagnosis entailed abdominal bleeding in only

three women with SHiP. Abdominal ultrasound was used in all women and eight underwent additional imaging techniques. Imaging findings are presented in Table 1. In six women, surgical intervention was performed, five of whom had an emergency caesarean section because of their clinical condition surrounding SHiP (Table 2). One woman had a laparoscopy, and two women underwent embolisation. The median blood loss in the six women for whom surgery was performed was 1950 mL (range 1000–16 500 mL). Of all 14 women, six received a blood transfusion and six required admission to an intensive care unit (ICU). There was no maternal mortality.

3.3 | Perinatal outcomes

Table 2 presents the perinatal outcomes. There were five preterm births at <37 weeks of gestation, with two very preterm births at <32 weeks of gestation. Eight out of 16

TABLE 1 Clinical summary of SHiP cases – diagnostics.

Diagnosics	n/N
Diagnostic measures	
Lab	7/13
CTG	2/13
TVUS	4/13
US	13/13
CT	4/13
CTA	2/13
MRI	4/13
Abdominal paracentesis	2/13
Lab findings	
Hb drop	7/7
Imaging findings	
Process lower abdomen	4/13
Fetal bradycardia	3/11
Free fluid	8/13
Abdominal paracentesis finding: blood	2/2

Note: N is presented for all cases that the specific information is known.

Abbreviations: CT, computed tomography scan; CTA, computed tomography angiography; CTG, cardiotocography; MRI, magnetic resonance imaging; TVUS, transvaginal ultrasound; US, ultrasound.

neonates were admitted to the neonatal intensive care unit (NICU). Three perinatal deaths occurred: one fetal and two neonatal deaths. One term neonate died, most likely through birth asphyxia. Another premature neonate died as a result of persistent pulmonary hypertension of the neonate (PPHN) and was later diagnosed with a genetic condition. The intrauterine demise in a term fetus was most likely caused by hypoxia.

3.4 | Delphi: Recommendations for diagnosis and management

The audit panel agreed that most cases were managed appropriately even though SHiP was often not included in the differential diagnosis: intra-abdominal haemorrhage was considered in the initial differential diagnosis of only three women. The audit panel recommended that more awareness around SHiP is generated so that the appropriate diagnostic and management strategies are applied rapidly. This could reduce maternal and fetal morbidity. To increase such awareness, SHiP should be part of the differential diagnosis in cases with signs of abdominal pain, especially in women with a history of endometriosis or ART, and in cases of maternal haemodynamic compromise without the presence of other causes. An assessment for the presence of intra-abdominal free fluid is an essential part of the workup and should be repeated if symptoms deteriorate.

Overall recommendations for diagnosis from the audit panel are summarised in [Box 1](#).

TABLE 2 Clinical summary of SHiP cases – treatment and outcomes.

Treatment	n/N
Intervention	
Expectant management	6/14
Caesarean section	5/14
Laparoscopy	1/14
Embolisation	2/14
Hysterectomy	1/14
Treatment bleeding	
Expectant management	5/14
No active bleeding found	3/14
Tamponade/sutures	3/14
Embolisation	3/14
Bleeding site	
Unknown	5/14
Not found	4/14
Uterine artery	3/14
Broad ligament	2/14
Estimated blood loss (mL, range)	1000– 16 500
Blood transfusion	6/12
ICU admittance	6/12
Gestational age at delivery (weeks)	27 ⁺² –40 ⁺⁵
Mode of delivery	
Vaginal birth	6/14
Elective caesarean section	1/14
Emergency caesarean section	7/14
NICU admittance	8/15 ^a
Mortality	
Maternal mortality	0/14
Perinatal mortality	3/14

Note: N is presented for all cases that the specific information is known.

Abbreviations: ICU: intensive care unit; NICU, neonatal intensive care unit.

^aA total of 16 children born in 14 pregnancies, with outcome unknown for one child.

Recommendations from the audit panel considering the management of SHiP were that the focus should be on stabilising a patient in acute situations using modified early obstetric warning scores (MOEWS) and early signs of fetal distress, such as tachycardia upon cardiotocography (CTG). Staff and residents could be trained better in (obstetric) advanced life support, to identify and manage hypovolemic shock sooner. Expectant management is possible when SHiP is the most likely diagnosis and vital signs are stable in the presence of close monitoring, but a low threshold for surgery should be considered in case of an unstable maternal or fetal condition, despite adequate replacement of fluids and blood products.

The overall recommendations for the management of SHiP from the audit panel are summarised in [Box 2](#).

BOX 1 Recommendations for diagnosing SHiP

	Be aware of a pre-existing diagnosis of endometriosis and mode of conception
Medical history	
Physical examination	Careful physical examination should be performed – tenderness of the abdomen is abnormal and should be investigated further when current diagnosis does not suffice
Vital parameters	Register vital parameters and be aware of early and subtle signs of hypovolemic shock
Advanced life support	Medical staff should be sufficiently trained in (obstetric) advanced life support
Laboratory tests	Monitor haemoglobin levels
Differential diagnosis	Include SHiP in the differential diagnosis of acute abdominal pain
Imaging	Always assess the presence of free fluid and other extrauterine abnormalities in addition to routine fetal and placental assessment in case of abdominal pain Consider MRI and/or CTA in unexplained abdominal pain with free intra-abdominal fluid and stable maternal and fetal condition
Multidisciplinary meeting	In case of no clear diagnosis a multidisciplinary meeting should be organised, including a radiologist
Abdominal paracentesis	It is not necessary to confirm the presence of abdominal blood with paracentesis – imaging is usually sufficient in differentiating between blood and other fluids

BOX 2 Recommendations for management of SHiP

	Medical staff should be sufficiently trained in (obstetric) advanced life support
Advanced life support	
Treat hypovolemic shock	Identify and manage hypovolemic shock as quickly as possible
Surgical treatment	Surgical treatment might be necessary when there are signs of active bleeding or when the fetal condition is deteriorating
Expectant management	Expectant management can be considered when vital signs are stable, depending on gestational age, and with close monitoring of maternal and fetal condition. During multidisciplinary meetings with a radiologist, surgeon, anaesthetist and/or paediatrician, a management plan can be made

radiological intervention, the audit panel discussed the need for redefining SHiP to include cases without a surgical or radiological intervention.

The proposed new definition of SHiP, as discussed and agreed upon in the third Delphi audit round, is as follows: 'SHiP is a diagnosis by exclusion: spontaneous (nontraumatic) intraperitoneal haemorrhage during pregnancy and up to 42 days postpartum most likely originating from the peritoneum' (Box 3). Furthermore, the audit panel proposed that SHiP could not originate from organ bleeding (including ectopic pregnancies in tubes and arteriovenous malformation).

4 | DISCUSSION

This study represents the first prospective study on SHiP, showing an incidence of 4.9 cases per 100 000 births in the Netherlands. No women died, but there were three perinatal deaths, two of which were directly related to the SHiP event. This is in line with maternal and perinatal outcomes presented in previous systematic reviews.^{1,3} The main points of improvement found during the DAS were: (i) SHiP should be included in the differential diagnosis of acute abdominal pain during pregnancy, specifically in women with a history of endometriosis or ART; (ii) the presence of intra-abdominal blood should be evaluated using abdominal ultrasound; and (iii) women should be monitored closely for signs of hypovolemic shock, which should be managed promptly. Furthermore, a revision of the definition for SHiP is proposed, in which the need for

3.5 | Definition of SHiP

The DAS process revealed that the consensus definition of INOSS did not cover all cases that were classified as SHiP by the audit panel.² Six out of 14 women with SHiP, as identified by the audit panel, were not picked up by the definition of SHiP proposed by INOSS.² In these women, SHiP was diagnosed by imaging in combination with a significant drop in haemoglobin level. The conditions were managed expectantly, without resorting to surgical or radiological intervention. As the INOSS definition requires surgical or

BOX 3 Proposed new definition of SHiP

New definition of SHiP	SHiP is a diagnosis by exclusion: spontaneous (nontraumatic) intraperitoneal haemorrhage during pregnancy and up to 42 days postpartum most likely originating from the peritoneum
------------------------	--

surgical intervention or embolisation is removed. Where previous researchers stated that all SHiP cases should be treated surgically and that expectative management has no place,²³ our results show that in selected women an expectant management with close monitoring of vital signs is justified.⁷ The new definition includes cases of SHiP that are diagnosed based on imaging and laboratory assessment, in absence of other diagnoses. These cases were managed expectantly, because the clinical condition did not require immediate intervention.

NethOSS is a well-known registration system of obstetric complications with a high compliance of registrations from obstetric wards in the Netherlands.²⁴ However, under-reporting cannot be excluded. Furthermore, the registrations of SHiP are partly based on retrospective recall of SHiP, as reported by the reporting clinicians when responding to the monthly call for the registration of cases. Although recall may induce uncertainty, the monthly nature of the calls probably made this impact very limited. Reducing misdiagnosis and missing registrations can only be accomplished by increasing an awareness of SHiP among healthcare providers.

This study confirms earlier studies showing that endometriosis and ART are risk factors for developing SHiP, as the number of women with endometriosis or conceiving after IVF/ICSI in our case series was tenfold the estimated number based on the general pregnant population.^{1,3,7,13} It is estimated that around 2%–11% of women in their reproductive years suffer from endometriosis, and that around 3.2% of all infants born in the Netherlands are conceived after IVF/ICSI.^{25–28}

As the incidence of SHiP is low and women often present themselves quickly after symptoms start, it is not advised to counsel all pregnant women with a history of endometriosis or ART on the risk of SHiP, as this may cause unnecessary worrying during pregnancy. Likewise, no additional antenatal monitoring is advised in the current international guideline on endometriosis.¹⁶

The early recognition of hypovolemic shock should get more attention in the regular crew resource management (CRM) training and scenario-based team training that are often organised in the field of obstetrics and gynaecology. A combination of both training systems seems to improve teamwork, communication and patient safety.²⁹

Ultrasound, computed tomography (CT) and magnetic resonance imaging (MRI) are used to identify free fluid in

the abdominal cavity. Vaginal ultrasound has been shown to consistently identify even small volumes of abdominal free fluid.³⁰ For abdominal ultrasound, an extended focused assessment with sonography in trauma (eFAST) examination can be used to detect intra-abdominal free fluid.³¹ However, intra-abdominal free fluid seems to have been often missed during ultrasound investigation in our included cases. The abdominal ultrasound was often performed as a point-of-care ultrasound (POCUS) by residents in gynaecology, focusing on the pregnancy and overlooking any causes of abdominal pain not originating from the uterus. A check for free fluid by the resident or gynaecologist, or consultation of a radiologist trained to systematically assess the complete abdominal cavity and to detect intra-abdominal free fluid, should be routinely performed.

Given the fast and easy access and the absence of radiation load and risk of contrast-induced nephropathy, current guidelines advise the use of ultrasound as a first step in imaging a stable patient presenting with acute abdominal pain.^{32,33} MRI can be considered when ultrasound is inconclusive, as it does not use radiation.^{34,35} The downsides of MRI are the need for specific expertise to assess the images and that MRI is not always available in an emergency setting.³⁶ Furthermore, the use of gadolinium as a contrast agent should be limited when possible.^{33,37} Computed tomography (CT) should be considered as a diagnostic tool even in pregnant women when the diagnosis is unclear, when MRI is not available or when the patient's vitals do not allow a wait for MRI.^{33–35} An advantage of CT is the ability to determine the most likely origin of the haemorrhage. The fetal exposure to radiation during CT is estimated at 9 mGy, which is below the advised maximum allowed dose for fetuses.^{33,38}

This was the first study on nationwide obstetric complications that used an online DAS. Overall, the audit panel was satisfied with the use of the DAS. Although the number of questions audited required a considerable time commitment from all auditors, the response rate and involvement of the auditors was high. Using an online DAS has several benefits. The answers to the audit questions are processed anonymously. The auditors were therefore able to give indiscriminate feedback on the cases without social pressure. Furthermore, by presenting the audit panel with the statistical outcomes and an overview of all (anonymous) feedback responses on the cases, the auditors were better informed on different opinions within the team. The iteration of the questions that did not yield consensus gave the audit panel the opportunity to change their opinion anonymously.¹⁷ Using the RoA, the level of agreement could be calculated, adding strength to the conclusions. Finally, the online system simplified the logistics, as the participants in the audit panel did not have to travel for an audit meeting and the questions could be answered at any chosen time. A disadvantage of the system was that the audit panel had to answer all predefined audit questions for each case in the first audit round to avoid any bias of the researchers. The number of questions in each round was therefore high, as was the time required for the auditors. An improvement for the future would be to critically

review all questions on relevance in a small audit panel first, to minimise the load of questions provided for all auditors.

It could have been valuable to include patients in the audit panel, as a patient's view could also give new insights on the cases and the auditing of diagnosing and treating SHiP. Recent research showed that SHiP had a severe impact on women and their partners, with high scores on the impact of event scale questionnaire for the effect on bonding, reliving SHiP and the need for psychological help.^{4,39} Involving patients in the audit panel could have led to more advice on counselling and supporting women undergoing SHiP.

5 | CONCLUSION

SHiP is a severe pregnancy complication with a high risk of emergency surgery, preterm birth and perinatal death. More awareness of SHiP and treatment of hypovolemic shock should be given. In some women, expectant management might be feasible based on clinical and radiological findings. We propose a revised definition of SHiP that excludes the need for surgical interventions and/or embolisation.

AUTHOR CONTRIBUTIONS

EMO, MAdB, MCIL, ANR, TPS, KWMB and VM contributed to the design of the trial. AMFS and EMO organised the data acquisition. Data were processed by AMFS and EMO. Interpretation of the data was performed by MAdB, LEEvdH, ML, Tvda, JC, TEV, ICMB, ANR, JWMM, DJH, MJJF, JJJdV, NBB, KWMB and VM. AMFS and EMO drafted the article, which was critically revised by all authors. All authors approved the final version for publication.

ACKNOWLEDGEMENTS

The authors thank the local coordinators of all Dutch hospitals affiliated with NethOSS. Furthermore, the authors thank Perined and the Netherlands Audit Committee Maternal Mortality and Morbidity (Auditcommissie Maternale Sterfte en Morbiditeit, AMSM) for facilitating this study and facilitating the birth registration and audit in the Netherlands.

FUNDING INFORMATION

One received.

CONFLICT OF INTEREST STATEMENT

None declared.

DATA AVAILABILITY STATEMENT

Data available on request due to privacy/ethical restrictions.

ORCID

Anneke M. F. Schreurs  <https://orcid.org/0000-0001-9736-0632>

Evelien M. Overtom  <https://orcid.org/0000-0001-6454-4531>

Ageeth N. Rosman  <https://orcid.org/0000-0003-3751-2950>

REFERENCES

1. Brosens IA, Fusi L, Brosens JJ. Endometriosis is a risk factor for spontaneous hemoperitoneum during pregnancy. *Fertil Steril*. 2009;92(4):1243–5.
2. Schaap T, Bloemenkamp K, Deneux-Tharaux C, Knight M, Langhoff-Roos J, Sullivan E, et al. Defining definitions: a Delphi study to develop a core outcome set for conditions of severe maternal morbidity. *BJOG*. 2019;126(3):394–401.
3. Lier MCI, Malik RF, Ket JCF, Lambalk CB, Brosens IA, Mijatovic V. Spontaneous hemoperitoneum in pregnancy (SHiP) and endometriosis – a systematic review of the recent literature. *Eur J Obstet Gynecol Reprod Biol*. 2017;219:57–65.
4. Schreurs A, Lier M, Koning D, Brals C, De Boer MA, Lambalk CB, et al. Severe psychological impact and impaired quality of life after a spontaneous haemoperitoneum in pregnancy in women with endometriosis and their partners. *Facts Views Vis Obgyn*. 2021;13(2):159–68.
5. Hodgkinson CP, Christensen RC. Hemorrhage from ruptured utero-ovarian veins during pregnancy; report of 3 cases and review of the literature. *Am J Obstet Gynecol*. 1950;59(5):1112–7.
6. Ginsburg KA, Valdes C, Schnider G. Spontaneous utero-ovarian vessel rupture during pregnancy: three case reports and a review of the literature. *Obstet Gynecol*. 1987;69(3 Pt 2):474–6.
7. Lier M, Malik RF, van Waesberghe J, Maas JW, van Rumpst-van de Geest DA, Coppus SF, et al. Spontaneous haemoperitoneum in pregnancy and endometriosis: a case series. *BJOG*. 2017;124(2):306–12.
8. Palaia I, Bardhi E, Boccia SM, Pecorini F, Musella A, Panici PB. Severe hemoperitoneum due to endometriosis in a non-pregnant woman under dienogest therapy: a case report. *Gynecol Endocrinol*. 2019;1-2:211–2.
9. Goncalves D, Teixeira M, Rodrigues R, Braga J. Spontaneous hemoperitoneum in pregnancy. *Acta Med Port*. 2019;32(11):730–2.
10. Naeh A, Bruchim I, Hallak M, Gabbay-Benziv R. Endometriosis-related hemoperitoneum in late pregnancy. *Isr Med Assoc J*. 2019;21(8):557–9.
11. Nitahara K, Sasaki M, Ichikawa S, Tsuji K, Yoshida Y. Rupture of perivascular epithelioid cell neoplasm at 34 weeks' gestation: a non-endometriosis case of spontaneous hemoperitoneum in pregnancy. *J Obstet Gynaecol Res*. 2018;45:709–13.
12. Huang LY, Hsu PY, Chiang CT, Chen HW, Wu MH. Endometriosis-related spontaneous hemoperitoneum in the early second trimester: a case report. *Taiwan J Obstet Gynecol*. 2021;60(2):328–30.
13. Brosens IA, Lier MC, Mijatovic V, Habiba M, Benagiano G. Severe spontaneous hemoperitoneum in pregnancy may be linked to in vitro fertilization in patients with endometriosis: a systematic review. *Fertil Steril*. 2016;106(3):692–703.
14. Golfier F, Pleyne L, Bolze PA. Spontaneous hemoperitoneum in pregnancy: a life-threatening maternal and fetal complication of endometriosis. *J Gynecol Obstet Hum Reprod*. 2022;51(7):102415.
15. Benaglia L, Reschini M, La Vecchia I, Candotti G, Somigliana E, Vercellini P. Endometriosis and spontaneous hemoperitoneum in pregnancy: evaluation of the magnitude of the risk in women becoming pregnant via in vitro fertilization. *Fertil Steril*. 2021;115(4):1023–8.
16. Members of the Endometriosis Guideline Core G, Becker CM, Bokor A, Heikinheimo O, Horne A, Jansen F, et al. ESHRE guideline: endometriosis. *Hum Reprod Open*. 2022;2022(2):hoac009.
17. Rowe G, Wright G. The Delphi technique as a forecasting tool: issues and analysis. *Int J Forecasting*. 1999;15(4):353–75.
18. Schaap TP, van den Akker T, Zwart JJ, van Roosmalen J, Bloemenkamp KWM. A national surveillance approach to monitor incidence of eclampsia: The Netherlands obstetric surveillance system. *Acta Obstet Gynecol Scand*. 2019;98(3):342–50.
19. Overtom EM, Rosman AN, Zwart JJ, Vogelvang TE, Schaap TP, van den Akker T, et al. SARS-CoV-2 infection in pregnancy during the first wave of COVID-19 in The Netherlands: a prospective nationwide population-based cohort study (NethOSS). *BJOG*. 2022;129(1):91–100.
20. Vandenbergh G, Bloemenkamp K, Berlage S, Colmorn L, Deneux-Tharaux C, Gissler M, et al. The international network of obstetric

- survey systems study of uterine rupture: a descriptive multi-country population-based study. *BJOG*. 2019;126(3):370–81.
21. Budhram S, Vannevel V, Botha T, Chauke L, Bhoora S, Balie GM, et al. Maternal characteristics and pregnancy outcomes of hospitalized pregnant women with SARS-CoV-2 infection in South Africa: an international network of obstetric survey systems-based cohort study. *Int J Gynaecol Obstet*. 2021;155(3):455–65.
 22. World Medical Association. World medical association declaration of Helsinki: ethical principles for medical research involving human subjects. *JAMA*. 2013;310(20):2191–4.
 23. Markou GA, Fysekidis M. Spontaneous hemoperitoneum during pregnancy. Is there any place for a wait and see approach in the absence of maternal hypovolemic shock or fetal distress? *Eur J Obstet Gynecol Reprod Biol*. 2018;225:260–1.
 24. Knight M, INOSS. The international network of obstetric survey systems (INOSS): benefits of multi-country studies of severe and uncommon maternal morbidities. *Acta Obstet Gynecol Scand*. 2014;93(2):127–31.
 25. Shafrir AL, Farland LV, Shah DK, Harris HR, Kvaskoff M, Zondervan K, et al. Risk for and consequences of endometriosis: a critical epidemiologic review. *Best Pract Res Clin Obstet Gynaecol*. 2018;51:1–15.
 26. Zondervan KT, Becker CM, Missmer SA. Endometriosis. *N Engl J Med*. 2020;382(13):1244–56.
 27. CBS S. [cited 2023 June 05]. Available from: <https://www.cbs.nl/nl-nl/visualisaties/dashboard-bevolking/bevolkingsgroei/geboren-kinderen#:~:text=In%202019%20werden%20169%20680,in%201946%20zelfs%20284%20duizend>
 28. degynaecoloog.nl. [cited 2023 June 05]. Available from: <https://www.degynaecoloog.nl/wp-content/uploads/2021/02/IVFlandelijk2019.pdf>
 29. Wong D, Tai C-M. Simulation training in obstetrics and gynaecology. *Hong Kong J Gynaecol Obstet Midwifery*. 2020;20(2):101–8.
 30. Khalife S, Falcone T, Hemmings R, Cohen D. Diagnostic accuracy of transvaginal ultrasound in detecting free pelvic fluid. *J Reprod Med*. 1998;43(9):795–8.
 31. Netherton S, Milenkovic V, Taylor M, Davis PJ. Diagnostic accuracy of eFAST in the trauma patient: a systematic review and meta-analysis. *CJEM*. 2019;21(6):727–38.
 32. Lameris W, van Randen A, van Es HW, van Heeswijk JP, van Ramshorst B, Bouma WH, et al. Imaging strategies for detection of urgent conditions in patients with acute abdominal pain: diagnostic accuracy study. *BMJ*. 2009;338:b2431.
 33. Gynecologists TACoOa. Committee Opinion No. 723 summary: guidelines for diagnostic imaging during pregnancy and lactation. *Obstet Gynecol*. 2017;130(4):933–4.
 34. Gans SL, Pols MA, Stoker J, Boermeester MA, Expert steering group. Guideline for the diagnostic pathway in patients with acute abdominal pain. *Dig Surg*. 2015;32(1):23–31.
 35. Cartwright SL, Knudson MP. Diagnostic imaging of acute abdominal pain in adults. *Am Fam Physician*. 2015;91(7):452–9.
 36. Leeuwenburgh MM, Wiarda BM, Bipat S, Nio CY, Bollen TL, Kardux JJ, et al. Acute appendicitis on abdominal MR images: training readers to improve diagnostic accuracy. *Radiology*. 2012;264(2):455–63.
 37. Garcia-Bournissen F, Shrim A, Koren G. Safety of gadolinium during pregnancy. *Can Fam Physician*. 2006;52:309–10.
 38. Bazzurini L, Ornaghi S, Colciago E, Penati C, di Gennaro F, Passoni P, et al. Endometriosis-related spontaneous hemoperitoneum in pregnancy: a case series. *J Obstet Gynaecol Res*. 2023;49(2):744–52.
 39. Horowitz M, Wilner N, Alvarez W. Impact of event scale: a measure of subjective stress. *Psychosom Med*. 1979;41(3):209–18.

SUPPORTING INFORMATION

Additional supporting information can be found online in the Supporting Information section at the end of this article.

How to cite this article: Schreurs AMF, Overtoom EM, de Boer MA, van der Houwen LEE, Lier MCI, van den Akker T, et al. Spontaneous Haemoperitoneum in Pregnancy: Nationwide Surveillance and Delphi Audit System. *BJOG*. 2023;00:1–9. <https://doi.org/10.1111/1471-0528.17556>