

See discussions, stats, and author profiles for this publication at: <https://www.researchgate.net/publication/369492243>

# SOFT TISSUE PERFUSION EVALUATION ALGORITHM IN THE SCHEME OF GUNSHOT DEFECTS “CLOSURE”

Article in *World of Medicine and Biology* · January 2023

DOI: 10.26724/2079-8334-2023-1-83-169-173

CITATIONS

0

READS

5

7 authors, including:



**Igor Anatoliyovich Lurin**

National Academy of Medical Sciences of Ukraine

55 PUBLICATIONS 46 CITATIONS

[SEE PROFILE](#)



**Serhii Tertyshnyi**

military medical clinical center of the southern region

38 PUBLICATIONS 9 CITATIONS

[SEE PROFILE](#)



**Oksana M. Popova**

Military medical clinical center of Eastern region

40 PUBLICATIONS 6 CITATIONS

[SEE PROFILE](#)

Some of the authors of this publication are also working on these related projects:



War related limb amputation [View project](#)



Sonographic signs of colon injury for penetrating gunshot abdominal trauma [View project](#)

I.P. Khomenko, I.A. Lurin<sup>1</sup>, V.V. Nehoduiko<sup>2,3</sup>, S.V. Tertishnyi<sup>4,5</sup>,  
O.M. Popova<sup>6</sup>, R.S. Vastyanov<sup>5</sup>, B. Weis<sup>7</sup>

National Academy of Medical Sciences of Ukraine, Kyiv

<sup>1</sup>State Scientific Institution “Scientific and Practical Center of Preventive and Clinical Medicine” of the State Administration of Affairs, Kyiv; <sup>2</sup>Military Medical Clinical Center of the Northern Region, Ministry of Defense of Ukraine, Kharkiv; <sup>3</sup>Kharkiv National Medical University, Kharkiv  
<sup>4</sup>Military Medical Clinical Center of the Southern Region Ministry of Defense of Ukraine, Odesa  
<sup>5</sup>Odesa National Medical University, Odesa; <sup>6</sup>Military Medical Clinical Center of the Eastern Region, Ministry of Defense of Ukraine, Dnipro; <sup>7</sup>Hospital Charite, Berlin, Germany

## SOFT TISSUE PERFUSION EVALUATION ALGORITHM IN THE SCHEME OF GUNSHOT DEFECTS “CLOSURE”

e-mail: tertishnyi.sergey@gmail.com

The purpose of the study was to determine indicators for the soft tissue perfusion evaluation in the scheme of gunshot defects “closure” using a variety of flaps from V–Y and Keystone till “propeller” and free flaps. A thermal imaging camera FLIR C2 with an integrated temperature gauge was used to obtain thermometric images together with a digital photograph of the scanned anatomical area. Microcirculation in damaged tissues plays an important role in wound substrate and the future flap in certain anatomical structure viability ensuring. That’s why its important to determine the features of the soft tissues perfusion fire transformation and the place of the corresponding blood supply from where it is possible to “raise” the flap in the future. The original dynamic multimodal concept using DDT and sonographic evaluation of soft tissue perfusion allows to look at the specific gunshot wound changes in a new way and to plan strategically the optimal path of reconstructive-plastic recovery. The thermographic and sonographic criteria uniqueness for soft tissue perfusion assessing in the context of large gunshot defects closing are reliable and objective, allow to assess the condition of the future wound bed and edges. They can be used not only to evaluate the wound before closing the defect but also to correct further tactics in the large defects or wounds treatment that do not heal for a long time.

**Key words:** dynamic digital thermography, sonographic evaluation of soft tissue perfusion, perforator vessels, gunshot wound reconstruction.

I.П. Хоменко, І.А. Лурін, В.В. Негодуйко, С.В. Тertiшний, О.М. Попова,  
Р.С. Вастьянов, Б. Вайс

## АЛГОРИТМ ОЦІНКИ ПЕРФУЗІЇ М'ЯКИХ ТКАНИН У СХЕМІ «ЗАКРИТТЯ» ВОГНЕПАЛЬНИХ ДЕФЕКТІВ

Метою дослідження є визначення показників перфузії м'яких тканин в схемі «закриття» вогнепальних дефектів під час використання різноманітних клаптів від V–Y та Кейстоуна до пропелерних та вільних клаптів. Для отримання термометричних зображень разом із цифровою фотографією сканованої анатомічної ділянки автори використовували тепловізійну камеру FLIR C2 з вбудованим датчиком температури. Мікроциркуляція в ушкоджених тканинах відіграє важливу роль у забезпеченні життєздатності ранового субстрата та майбутнього клаптя у вказаній анатомічній структурі, і тому існує необхідність визначити особливості вогнепальної трансформації перфузії в м'яких тканинах, місця відповідного кровопостачання, звідки в майбутньому можливо «підняти» клапоть. Запропонована нами оригінальна динамічна мультимодальна концепція за рахунок ДЦТ та сонографічної оцінки перфузії м'яких тканин дозволяє по-новому подивитись на специфічні зміни, притаманні вогнепальному ураженню та стратегічно спланувати оптимальний шлях реконструктивно-пластичного відновлення. Унікальність термографічних та сонографічних критеріїв оцінки перфузії м'яких тканин в контексті закриття великих вогнепальних дефектів є надійними та об'єктивними, дозволяють оцінити стан майбутнього ложа та країв рани. Вони можуть бути застосовані не тільки для оцінки рани перед закриттям дефекту, але і для корекції подальшої тактики при лікуванні великих дефектів або ран, що довго не загоюються.

**Ключові слова:** динамічна цифрова термографія, сонографічна оцінка перфузії м'яких тканин, перфораторні судини, реконструкція вогнепальної рани

*The study is a fragment of the research project “Development of modern methods of diagnosis and treatment of purulent-septic complications in combat surgical trauma”, state registration No 0120U101834*

The damaged anatomical area restoration after a gunshot wound is a difficult task due to the lack of adequate blood supply to the damaged area and the secondary changes present in the surrounding tissues. Comorbid pathology presence in the form of diabetes mellitus, cardiovascular diseases, micro- and macroangiopathies can worsen sometimes the conditions for subsequent reconstruction. Surgical options may be limited even in young persons due to anatomical features in cases of large extremity defects where skin-subcutaneous or skin-fascial flaps may be limited by the anatomical arch of rotation and the general principles of a 2:1 flap length-to-base ratio [3, 8]. This together with blood supply decrease reduces the resistance of “transferred” tissues to the bacterial flora of the wound during the postoperative period [6].

The flaps proposed by plastic surgeons for restoration were raised superficially in relation to the deep fascia during surgical interventions on the limbs [7]. The vascular plexuses peculiarities diagnostics using a dye on anatomical preparations demonstrated that fascial plexuses have connections with subcutaneous plexuses and sometimes with vascular plexuses below the level of the deep fascia. This opinion confirmed that the reconstructive base – the vascular component – can be located below the deep fascia [7, 11]. Knowing this surgeons developed a large number of flaps for the lower extremities with perforating vessels as the “keys” for them. To identify the perforating vessels soft tissue perfusion sonographic evaluation was used.

The basic step in the perforant identification was a portable Doppler system which initially allowed to make the preoperative planning and intraoperative control. But among the portable unidirectional Doppler fluorometric analysis advantages there was also a disadvantage in the form of their preferential use on the body [3, 5]. One could succeed to establish the blood flow direction during diagnostic monitoring but it was impossible to determine the vessel’s diameter and calculate the blood flow voluminar and velocities characteristics which is extremely important before surgery. Such an optional misadvantages in the flaps’ “key” led to postoperative complications rate increase [5, 11].

The use of ultrasound systems with the ability to assess low-speed blood flow can avoid a number of complications and risks [10] but this imposes a number of requirements in ultrasound diagnostics for the specialist qualification [5, 7]. The next stage in the evolution of the diagnostic plan for perforating vessels is CT angiography which gives a clear idea of the spatial anatomical location, the size of the vessel, its direction and relationship with the surrounding anatomical structures [15].

The purpose of the study was to determine indices for the soft tissue perfusion evaluation in the scheme of gunshot defects “closure” using a variety of flaps from V–Y and Keystone till “propeller” and free flaps.

**Materials and Methods.** 76 wounded servicemen with the limbs soft tissues gunshot defects were treated at the bases of the Military Medical Clinical Centers (MMCC) of the Northern, Eastern and Southern regions of the Command of the Medical Forces of the Armed Forces of Ukraine. These patients were randomized into 2 groups – the control group consisted of 44 people (58 %) in which diagnostic, therapeutic and post-operative observations were performed according to generally accepted protocols. The second clinical group consisted of 32 people (42%) with limbs soft tissues gunshot defects in which diagnostic procedures we involved the technique of dynamic digital thermography (DDT).

We used the following indications for patients inclusion into the clinical group: by time – up to 4 hrs from the moment of injury; according to the ambient temperature – not lower than 20 oC; according to the temperature in the room 20-22 oC (in the warm and transitional period of the year); by humidity – in the range from 17.375 mm Hg till 19.927 mm Hg; lack of a directed source of artificial heat aimed at the human body. For full reliability of the temperatures’ characteristics the temperature measurements were done at 6 or more points. Thermometers were placed on tripods along the diagonal section of the room at 3 points at a height of 0.2 m from the floor and at 3 points at a height of 1.5 m from the floor with a thermographic survey of the room.

DDT technique was used in the wounded treatment at the II level of medical support (advanced surgical group – dressing room for the wounded with soft tissues gunshot defects of small size – up to 2 cm<sup>2</sup> and the anti-shock ward for the wounded with medium (up to 125 cm<sup>2</sup>) and large defects (125–1000 cm<sup>2</sup>) and for wounded of severe and moderate severity), the III and the IV levels of medical support (MMCC and National Military Medical Clinical Center Main Military Clinical Hospital, respectively).

An additional requirement for DDT was scanning together with contralaterally located (usually intact) anatomical structures and without outer clothing. The working distance of diagnostic observation was 25 cm and 50 cm from the wound.

A thermal imaging camera FLIR C2 (“Flir Systems Inc”, USA) with an integrated temperature gauge was used to obtain thermometric images together with a digital photograph of the scanned anatomical area.

We scanned wound surfaces and surfaces of surrounding soft tissues, performed comparative thermography with a control assessment of an undamaged adjacent anatomical site at all levels of medical support in the Armed Forces of Ukraine. The perforant both final location or “exit” on the wound surface was confirmed by a temperature fluctuation with indices of  $\pm 0.75$ – $1.27$  oC. The wound surface has a temperature range from 33.2 oC to 27.2 oC. The color palette from the wound surface was within the classical established limits of the FLIR C2.

Results of the study and their discussion. Using DCT it was easy and convenient to identify temperature patterns for venous (white) and arterial perfusion (red) as it was noted in the case where the fasciotomy was performed. A clinical example of patient K.'s wound surface thermographic background change is given (fig. 1).




Fig. 1. Remote thermal imaging observation in the anti-shock advanced surgical group before surgery: A - the side projection of right forearm thermal imaging observation (working distance 25 cm), B - thermography of the left forearm (working distance 25 cm).

In the conditions of the anti-shock advanced surgical group after a gunshot fragment blind wound of the flexor surface of the distal third of the right shoulder and the right forearm proximal part the primary surgical treatment of gunshot wounds of the right shoulder and right forearm, fasciotomy of the shoulder and forearm was performed under general anesthesia. Thermal imaging control after the end of the surgical intervention showed a temperature increase in the right upper limb distal parts at the level of the palm flexor surface from 23.1 °C to 33.1 °C (fig. 2).

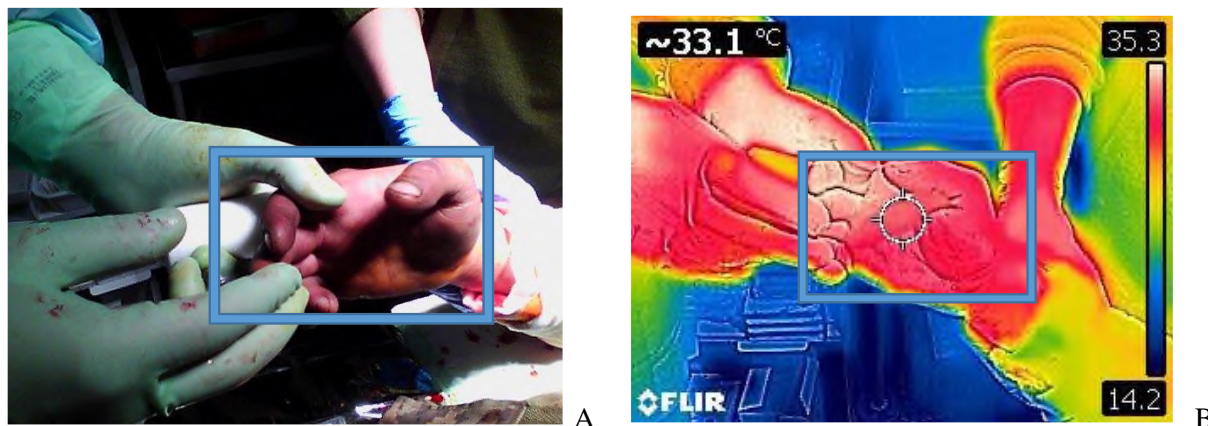


Fig. 2. Remote thermal imaging observation in the anti-shock advanced surgical group after surgery: A - photo of the lateral projection thermal imaging observation of the right forearm (working distance 25 cm) after surgery; B - thermography of the left forearm (working distance 25 cm) after surgery.

The thermographic transformation of venous and arterial perforants “islands” on the wound surface of the right upper extremity was immediately noticeable. The segment of the upper extremity was divided into three areas during observation: shoulder, forearm and hand. The perforants of the brachial segment correspond to the first anatomical zone, the perforants of the radial and ulnar arteries correspond to the second anatomical zone (forearm), the perforants of the palmar and dorsal vascular plexuses correspond to the third anatomical zone (hand). Each anatomical zone had interconnected vascular plexuses (clusters). The cluster at shoulder level was set within 20–25 cm, forearm 12–17 cm, within the hand 5–10 cm.

When comparing the efficacy of the reconstructive surgical interventions we carried out in patients of two selected groups, the advantage was revealed in the patients of the second – clinical – group which was expressed in an affected limb functional activity faster recovery, in a significant reduction in the frequency of postoperative complications, in a significant reduction in the postoperative period duration as well as in reducing the time and cost of treatment during the postoperative period.

Microcirculation in damaged tissues plays an important role in wound substrate and the future flap in certain anatomical structure viability ensuring. That's why its important to determine the features of the soft tissues perfusion fire transformation and the place of the corresponding blood supply from where it is possible to “raise” the flap in the future. The original dynamic multimodal concept using DDT and

sonographic evaluation of soft tissue perfusion allows to look at the specific gunshot wound changes in a new way and to plan strategically the optimal path of reconstructive-plastic recovery (fig. 3).

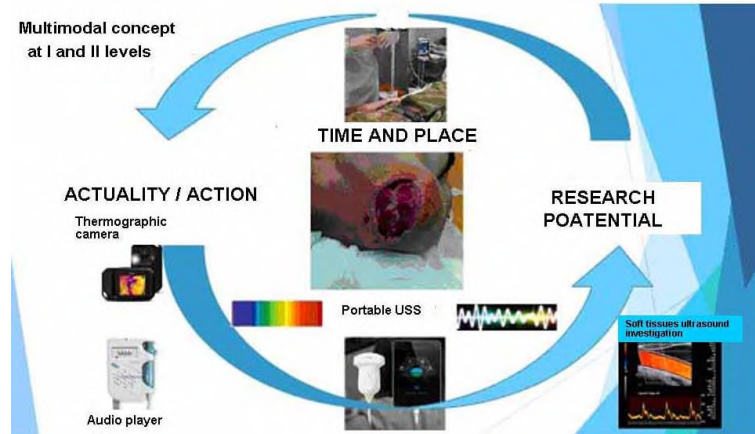


Fig. 3. Schematic representation of the dynamic multimodal concept of DDT and sonographic evaluation of soft tissue perfusion.

tissues gunshot defects at all levels of medical care in the Armed Forces of Ukraine were proved.

Our concept of DDT using and sonographic monitoring of the gunshot wounds microcirculation is a modern approach to the problem. It reveals more effective comparing with the only diagnostic thermometry using in soft tissue gunshot damages [2]. Its use may help to consider an alternative to the classic attitude approach in the surgical treatment of soft tissues gunshot defects [9]. In this aspect, let us emphasize the fact that determining the objective sonographic index of gunshot damage with soft tissue defects and the deadline for plastic surgery of such defects is a difficult task, especially considering that the bulk of classifications and criteria were developed for this purpose based on burn defects and damage. At the same time, gunshot defects have a number of specific features that are often not taken into account, but they play a key role in the flap integration, the potential complications development and therefore determine the success of the entire reconstruction process. We consider the following features among all above-mentioned: (a) a zone of molecular shock formed during a gunshot wound which makes ineffective tissue respiration for a long time after receiving the injury; (b) long-term spasm of precapillary sphincters as a result of endothelial dysfunction which is formed as a result of kinetic energy one-moment transfer; (c) microthrombosis extending to a considerable depth from the site of immediate injury which is associated with microcavitation that occurs in a gunshot wound. As a result, there is a discrepancy between the clinical picture and the real tissue perfusion which requires a more careful assessment.

The original DDT combination with soft tissue perfusion sonographic monitoring may not only be new but also in most cases – the most optimal factor for making a decision on the soft tissues gunshot defects further “closure” especially of medium and large sizes according to [1].

Our technique is considered portable, cheap and adapted for all levels of medical care in the current conditions with X-ray control of the vascular bed [4, 14]. It is easy to use during the pre-, intra-, and postoperative periods as it does not depend on the central power supply and allows examination of all anatomical structures of the human body. An additional advantage of our algorithm is that it can be applied to all parts of the human body taking into account individual anatomical variations.

We should note that this technique use as a single study requires not only experience but also the postulates of reconstructive and plastic surgery understanding. This technique during the diagnostic observation of the gunshot wound surface allows to remotely identify the “keys” – perforant arteries and veins, to reduce the time of surgical intervention due to dynamic screening and, as a result of the obtained positive thermal imaging indicators, to preserve a larger volume of the wound substrate by  $20\pm 5\%$ . The clinical example of the upper limb gunshot wound is an element of a new “alternative” view on the gunshot wound evaluation with soft tissue defects formation, which in the future, with the acquisition of experience, will allow to implement these results in other fields. Another diagnostic component – the assessment of perfusion in transformed soft tissues – should be added to confirm the multimodal concept hypothesis relevance during the diagnosis and soft tissue defects reconstructive restoration.

Therefore, the thermographic and sonographic criteria uniqueness for soft tissue perfusion assessing in the context of large gunshot defects closing are reliable and objective, allow to assess the condition of the future wound bed and edges. They can be used not only to evaluate the wound before closing the defect but also to correct further tactics in the large defects or wounds treatment that do not heal for a long time.

Thus, our original complementary concept of the algorithm based on the actual results of observation can be considered as a new definition of the soft tissues viability. With an additional analysis of previous observations of perforant vessels identification our results agree with the data [12, 13] who studied perforant vessels of the lower extremities. In the presented algorithm and established sequence, a useful, new substantiated method of monitoring and staged control during the reconstruction of soft



## Conclusions

1. The developed original complementary concept of DDT using and sonographic monitoring of gunshot wounds microcirculation represents a new definition of soft tissue viability.

2. Such an integrative approach to soft tissue gunshot defects restoration has the following advantages – its use allow the reach the affected limb functional activity faster recovery, to decrease the frequency of postoperative complications, to decrease the postoperative period duration and to reduce the time and cost of treatment during the postoperative period.

3. The original method of DDT combination with soft tissue perfusion sonographic monitoring may not only be new but also in most cases – the most optimal factor for making a decision on the soft tissues gunshot defects further “closure” especially of medium and large sizes. An additional advantage of our algorithm is that it can be applied to all parts of the human body.

4. The thermographic and sonographic criteria uniqueness for soft tissue perfusion assessing in the context of large gunshot defects closing are reliable and objective, allow to assess the condition of the future wound bed and edges.

5. They can be used not only to evaluate the wound before closing the defect but also to correct further tactics in the large defects or wounds treatment that do not heal for a long time

*Prospects for furthers researches include a comprehensive clinical investigation of the proposed original method of DDT together with soft tissue perfusion sonographic monitoring efficacy in patients with large square of wound defects and in long-persisting soft tissues wound defects*

## References

1. Korol SO, Khomenko IP, Matviychuk BV, Ustinova LA. Khirurhichna taktyka likuvannya poranenykh z vohnepalnymy ushkodzhennyamy stehna na vsikh rivnyakh medychnoho zabezpechennya. Klinichna khirurhiya. 2019; 5(86): 22–26 DOI: <https://doi.org/10.26779/2522-1396.2019.05.22> [in Ukrainian]
2. Lurin IA, Boyko VV, Humenyuk KV, Zamyatin PM, Khoroshun EM, Mykhaylov IF, et al. Pokaznyky intensyvnosti rentheno flyuorestsentsiyi vmistu kapsul metalevykh oskolkiv mjakykh tkanyn u poranenykh iz vybukhovoyu i vohnepalnoyu travmoyu. Medytsyna nevidkladnykh staniv. 2022; 18(3): 49–55. DOI: <https://doi.org/10.22141/2224-0586.18.3.2022.1491> [in Ukrainian]
3. Deldar R, Merle C, Attinger CE, Evans KK. Soft tissue coverage of lower extremity defects: pearls and pitfalls in the chronic wound population. Plastic and Aesthetic Research. 2022; 9: 13. doi: <http://dx.doi.org/10.20517/2347-9264.2021.100>
4. Ettinger KS, Morris JM, Alexander AE, Nathan JM, Arce K. Accuracy and Precision of the Computed Tomographic Angiography Perforator Localization Technique for Virtual Surgical Planning of Composite Osteocutaneous Fibular Free Flaps in Head and Neck Reconstruction. J Oral Maxillofac Surg. 2022; 80(8): 1434–1444. doi: 10.1016/j.joms.2022.03.018.
5. González Martínez J, Pérez AT, Vega MG, Nuñez-Villaveiran T. Preoperative Vascular Planning of Free Flaps: Comparative Study of Computed Tomographic Angiography, Color Doppler Ultrasonography, and Hand-Held Doppler. Plast Reconstr Surg. 2020; 146(2): 227–237. doi: 10.1097/PRS.0000000000006966.
6. Guriev SO, Tanasienko PV, Panasenko SI, Martynkovskiy IP, Fil AYU. Clinical characteristics of lower limb wounds in injured people in the result of modern military operations. World of Medicine and Biology. 2020; 1(71): 40–44. DOI 10.26724/2079-8334-2020-1-71-40-44
7. Haertsch P. The surgical plane in the leg. Br J Plast Surg. 1981; 34: 464–469.
8. Horodova-Andrieieva TV, Liakhovskiy VI, Sydorenko AV. Influence of vacuum instillations with intravenous introduction of nitrogen oxide donators on the healing of purulent soft tissue wounds. World of Medicine and Biology. 2022; 2(80): 43–47. DOI: 10.26724/2079-8334-2022-2-80-43-47
9. Jordan DJ, Malahias M, Hindocha S, Juma A. Flap decisions and options in soft tissue coverage of the lower limb. Open Orthop J. 2014; 8: 423–432. doi: 10.2174/1874325001408010423
10. Khomenko IP, Tertysnyi SV, Vastyanov RS, Talalayev KO. Soft tissues gunshot defects ultrasound investigation use in reconstructive-restorative surgery. World of Medicine and Biology. 2021; 3(77): 169–174. DOI 10.26724/2079-8334-2021-3-77-169-174
11. Shandalov Y, Egozi D, Koffler J, Dado-Rosenfeld D, Ben-Shimol D, Freiman A, et al. An engineered muscle flap for reconstruction of large soft tissue defects. Proceedings of the National Academy of Sciences. 2014; 111(16): 6010–6015. doi: <https://doi.org/10.1073/pnas.1402679111>
12. Sharad PP. Using a Thermal Imaging Camera to Locate Perforators on the Lower Limb. Archives of Plastic Surgery. 2017; 44(3): 243–247. doi: 10.5999/aps.2017.44.3.243
13. Sur YJ, Morsy M, Mohan AT, Zhu L, Michalak GJ, Lachman N, et al. Three-Dimensional Computed Tomographic Angiography Study of the Interperforator Flow of the Lower Leg. Plast Reconstr Surg. 2016; 137(5): 1615–1628. doi: 10.1097/PRS.0000000000002111.
14. Ultrasound-based imaging to detect early changes of hard and soft tissue around immediately placed implants with or without soft tissue augmentation <https://clinicaltrials.gov/ct2/show/NCT05330702>
15. Weum S, Lott A, de Weerd L. Detection of Perforators Using Smartphone Thermal Imaging. Plast Reconstr Surg. 2016; 138(5): 938–940. DOI: 10.1097/PRS.0000000000002718

Стаття надійшла 28.02.2022 р.