

This is a provisional PDF only. Copyedited and fully formatted version will be made available soon.

REPORTS OF PRACTICAL ONCOLOGY AND RADIOTHERAPY

ISSN: 1507-1367

e-ISSN: 2083-4640

Stereotactic body radiation therapy to the spine: contouring the cauda equina instead of the spinal cord is more practical as the organ at risk

Authors: Osamu Tanaka, Takuya Taniguchi, Shuto Nakaya, Kousei Adachi, Takuji Kiryu, Chiyoko Makita, Masayuki Matsuo

DOI: 10.5603/RPOR.a2023.0040

Article type: Research paper

Published online: 2023-06-14

This article has been peer reviewed and published immediately upon acceptance. It is an open access article, which means that it can be downloaded, printed, and distributed freely, provided the work is properly cited.

Stereotactic body radiation therapy to the spine: contouring the cauda equina instead of the spinal cord is more practical as the organ at risk

Running head: Contouring in SBRT for the spine

10.5603/RPOR.a2023.0040

Osamu Tanaka¹, Takuya Taniguchi¹, Shuto Nakaya¹, Kousei Adachi¹, Takuji Kiryu¹,
Chiyoko Makita², Masayuki Matsuo²

¹*Department of Radiation Oncology, Asahi University Hospital, Gifu City, Gifu, Japan*

²*Department of Radiology, Gifu University Hospital, Gifu City, Gifu, Japan*

Corresponding author: Osamu Tanaka, M.D., Department of Radiation Oncology, Asahi University Hospital, 3-23 Hashimoto-cho, Gifu City, Gifu, 500-8523, Japan, tel: +81-58-253-8001, fax: +81-58-253-5165; e-mail: c.bluered@gmail.com

Abstract

Background: Stereotactic body radiotherapy (SBRT) is recognized as a curative treatment for oligometastasis. The spinal cord becomes the cauda equina at the lumbar level, and the nerves are located dorsally. Recently, a consensus has been reached that the cauda equina should be contoured as an organ at risk (OAR). Here, we examined the separate contouring benefits for the spinal canal versus the cauda equina only as the OAR.

Materials and methods: A medical physicist designed a simulation plan for 10 patients with isolated lumbar metastasis. The OAR was set with three contours: the whole spinal canal, cauda equina only, and cauda equina with bilateral nerve roots. The prescribed dose for the planning target volume (PTV) was 30 Gy/3 fx.

Results: For the constrained QAR doses, D90 and D95 were statistically significant due to the different OAR contouring. The maximum dose (D_{max}) was increased to the spinal canal when the cauda equina max was set to ≤ 20 Gy, but dose hotspots were observed in most cases in the medullary area. The D_{max} and PTV coverage were negatively

correlated for the cauda equina and the spinal canal if D_{\max} was set to ≤ 20 Gy for both.

Conclusions: A portion of the spinal fluid is also included when the spinal canal is set as the OAR. Thus, the PTV coverage rate will be poor if the tumor is in contact with the spinal canal. However, the PTV coverage rate increases if only the cauda equina is set as the OAR.

Key words: stereotactic body radiotherapy; organs at risk; cauda equina; spinal cord; vertebral metastasis

Introduction

Stereotactic body radiotherapy (SBRT) for spinal metastasis is performed under strict fixation and image guidance. This technique is also combined with intensity-modulated radiotherapy to reduce the dose received by the spinal cord while irradiating tumors with a high radiation dose [1, 2]. Randomized controlled trials (RCTs) for painful spinal metastases have reported about the superiority of SBRT over conventional irradiation [3–7]. Thus, SBRT is expected to become the standard treatment for painful spinal metastases in the future [8, 9].

Conventionally, the spinal canal is the organ at risk (OAR) during the delivery of SBRT, and radiation plans are therefore designed to minimize the dose delivered to this region. At the lumbar spine level, the cauda equina is the nerve in the spinal canal [6, 7, 10–12]. The cauda equina bundle location on the dorsal side of the spinal canal can be recognized easily using the T2-weighted magnetic resonance imaging (MRI) and computed tomographic (CT) myelography [13–20]. The cauda equina nerve is located on the dorsal side of the spinal canal, even when an image is taken in the prone position. The nerve roots on both sides are also present in the same position.

The range of movement of the cauda equina nerve in the spinal canal is within 1 mm during the interaction and intrafraction of treatment. Therefore, for tumors that are in contact with the spinal canal, if only the cauda equina nerve is recognized as the OAR, it is expected that the treatment plan will change compared to cases in which the conventional spinal canal is used as the OAR. In this study, we investigated how the tumor coverage increased when only the cauda equina nerve was used as the OAR compared to when the entire spinal canal was used.

Materials and methods

Patients

A medical physicist created a simulation plan for 10 patients with isolated lumbar metastasis. The simulation test was not reported on the hospital's website, and individual patient consent was not obtained because the test used archived images from patients' medical records.

Data from five men and five women were included; their average age of was 77.9 years. Prostate (four patients), lung (three patients), breast (two patients), and rectal (one patient) cancer were the primary lesions. The targeted vertebral bones were L1 (two cases), L2 (two cases), L3 (three cases), and L5 (three cases). The lesions were at one (three cases), two (two cases), three (four cases), and six sites (one case) [6], according to the classification by Cox et al. (Fig. 1A).

The positional relationship between the spinal cord (the cauda equina in the lumbar vertebra) and tumor following the Epidural Spinal Cord Compression (ESCC) scale was 0 (three cases), 1a (two cases), 1b (two cases), 1c (two cases), and 3 (one case; Figure 1B) [21]. Compression fracture cases were not included.

Radiotherapy setting

A radiation oncologist contoured the gross target volume (GTV), added a 1-mm margin, and used it as the clinical target volume (CTV). The part between the CTV and cauda equina that overlapped was cut off. The planning target volume (PTV) was set in the same range as the CTV.

The entire spinal canal, cauda equina with bilateral nerve roots, or cauda equina alone were contoured. The cauda equina is smaller than the spinal canal and is located on the dorsal side, which is distant from the vertebral body (Fig. 1C).

The treatment plan used a 6 MV without a flattening filter-free X-ray beam, the volumetric modulated arc therapy technique, and Monte Carlo dose-to-medium calculations. Moreover, we used a clinical method with high PTV coverage.

For tumors, GTV was obtained via the fusion of MRI and CT. CTV had a 1-mm margin from GTV, and PTV had a 0-mm margin from CTV. OAR (+1 mm) had a

margin of 1 mm from the OAR. For sites where the tumor GTV overlaps the OAR (+1 mm), the OAR was set at a 0 -mm margin so that the tumor GTV could achieve D95. Thus, the tumor GTV and OAR were in contact.

In our simulation study, the internal margin (ITV) was not considered. Because we were targeting only the lumbar spine, we believed that the effects of, for example, respiratory movements would be small. Alignment was performed using cone-beam CT. However, in clinical practice, ITV may be necessary for areas that, for example, may be affected by respiration (e.g., thoracic spine).

A medical physicist devised a radiation treatment plan, which was later approved by a radiation oncologist, with the PTV and OAR set up in this way. The prescribed dose was 30 Gy/3 fx. The constrained doses for the OAR are presented in Table 1 [22]. We examined the degree to which the PTV coverage rate diverged between the spinal canal set as the OAR versus the cauda equina only. Tumor location and coverage rate were also calculated.

Statistical analyses

D80, D90, and D95 were calculated as the dose covering 80%, 90%, and 95% of the PTV volume, respectively. V80, V90, and V100 are the percentages of volume of the PTV and CTV that receive 80%, 90%, and 100% of the prescribed dose, respectively. D_{mean} (the mean dose received by the organ) and D_{max} (the maximum dose received by the organ) were calculated within the PTV. The D_{max} , D_{min} (minimum dose), D_{mean} (the volume of the organ receiving that dose), and other relevant dose–volume data were calculated for each OAR. The correlation between the PTV and D_{max} was presented as scatter plots and tested with Pearson’s correlation coefficient. A p -value of <0.05 was judged to be statistically significant (BellCurve for Excel Social Survey Research Information Co. Ltd., Tokyo, Japan).

Results

Planning target volume coverage

Setting the cauda equina only resulted in better coverage than the other OAR settings (Fig. 2) for D95, D90, and D80. The difference was not significant for the D80 setting

(canal, cauda equina with nerve roots, and cauda equina were 28.8, 31.0, and 32.1 Gy, respectively). However, at D90 (canal, cauda equina with nerve roots, and cauda equina were 25.2, 28.6, and 31.0 Gy, respectively) and D95 (canal, cauda equina with nerve roots, and cauda equina were 22.2, 26.9, and 29.3 Gy, respectively), the differences in OAR contouring settings were statistically significant.

The space between the cauda equina and vertebral body improved PTV coverage when the tumor was located within the vertebral body. Conversely, the coverage was poor due to the tumor proximity to the cauda equina when the tumor was located in the vertebral arch (Fig. 1C).

Comparison between the spinal canal and cauda equina only

The ASTRO guidelines state that the radiation limit of the cauda equina is ≤ 20 Gy [12]. When the D_{\max} of the cauda equina was set to ≤ 20 Gy, dose hotspots were observed in the medullary area as the spinal canal D_{\max} increased. Figure 3 shows that when the D_{\max} of the spinal canal was limited to 20 Gy, the PTV D95 decreased inversely (correlation coefficient [$R = -0.8517$]) with the decrease in the D_{\max} of the OAR. If the D_{\max} was set to ≤ 20 Gy for the cauda equina and spinal canal, the D_{\max} and PTV coverage were negatively correlated (correlation coefficient [$R = -0.6627$]).

Part of the spinal fluid also becomes the OAR when the spinal canal is considered the OAR. Thus, the PTV coverage rate was poor if the tumor was in contact with the spinal canal. However, the PTV rate increased if the cauda equina alone was considered the OAR.

Discussion

Stereotactic body radiotherapy efficacy

Spinal SBRT is not a simple treatment and can lead to serious adverse events if performed poorly [1–5]. Additionally, spinal SBRT requires more effort for treatment planning and irradiation than normal irradiation. Having an appropriately trained staff to perform accurate SBRT for patients with painful spinal metastases is also important [13–17].

Several RCTs have suggested that local therapy for oligometastasis may prolong survival [1, 2]. Additional RCTs are currently under way. While treatment can be surgical or radiation based, safely performed SBRT [8, 9] and radiation therapy may be more common in local therapy for oligometastasis in the future because surgery is highly invasive, especially for spinal metastases. Reports of SBRT are also increasing, with good results [12, 20]. However, although trial endpoints can vary, in general, the range of local control is 80–96% at 1 year. These results suggest a superior outcome for local control when compared with conventional external beam radiation therapy (EBRT), with reported control rates ranging from 61% to 86% at 1 year [23–25].

Rades et al. has evaluated patients with metastatic spinal cord compression to compare the results of short- and long-course radiotherapy. In their results, the progression-free survival (PFS) rate at 12 months was 72% after the long course and 55% after the short course ($p = 0.034$). Long-course EBRT significantly improved PFS [24].

For pain management, multiple systematic reviews have shown that the overall pain response rate for conventional EBRT is ~60%, with corresponding complete response rates ranging from 0% to 24% [25–28]. However, other SBRT literature has reported high complete response rates, ranging from 46% to 92% [29–32, 20].

In a Phase II/III Radiation Therapy Oncology Group (RTOG) study, patients with up to three separate spinal cord metastases were randomized to SBRT with conventional EBRT at 8 Gy in one fraction and single fractions at 16 or 18 Gy [33]. The feasibility of successfully delivering image-guided SBRT in this trial setting has been reported [34]. The primary objective of the Phase III component of the trial was to assess the pain response rate, as measured by the 11-point Numerical Pain Scale 3 months after the start of the trial. More recently, a multicenter Phase II RCT of conventional EBRT in 5 fractions versus 20 Gy in 2 fractions versus SBRT in doses of 24 Gy has been reported [34]. The study results may provide better quality outcome data for spinal SBRT in de novo metastasis. At 3 months, 40 of 114 (35%) patients in the SBRT group and 16 of 115 (14%) patients in the EBRT group had a complete pain response (risk ratio, 1.33; 95% confidence interval, 1.14–1.55; $p = 0.0002$) [33].

RCTs have reported that SBRT had a better pain-relieving effect than normal

irradiation for spinal metastases [35]. Sahgal et al. also reported a better outcome for SBRT (24 Gy/2 fx) over normal irradiation (20 Gy/5 fx) for painful spinal metastasis treatment [22]. However, in the RTOG 0631 study, SBRT (16–18 Gy as a single dose) was not superior to normal irradiation (8 Gy as a single dose) in painful spinal metastases [20]. The dose of radiation varies depending on the facility. Schipani et al. [36] prescribed 18 Gy/1 fx and found a 92% local control rate, whereas Yamada et al. [37] prescribed 18–24 Gy/1 fx and found a 90% local control rate. According to Chang et al. [38], irradiation at 30 Gy/5 fx and 27 Gy/3 fx reduced pain from 60% to 36%. Wang et al. [39] reported a 2-yr progressive free survival rate of 72.4% after 27–30 Gy/3 fx irradiation. Amdur et al. [40] discovered 95% local control at 15 Gy/1 fx in a Phase 2 study. We simulated at 30 Gy/3 fx, but planning for 1 fx and 5 fx would be interesting. Therefore, spinal SBRT usefulness remains controversial, even in multicenter studies. However, one meta-analysis has shown that SBRT may be more effective, suggesting that it could be applied more widely to treat vertebral body metastasis in the future.

The standard treatment for spinal metastases is decompression surgery to remove as much of the tumor as possible, followed by postoperative normal irradiation at 30 Gy for 10 fractions. However, evidence of SBRT's effectiveness has accumulated, and surgery has improved to a minimally invasive spinal cord separation followed by radical SBRT [1–5]. Spinal cord separation creates a space between the spinal cord and tumor, and curettage is a minimally invasive method [5,41]. The dose to the spinal cord and cauda equina nerve can be reduced even if the tumor is in contact with the spinal canal if this space can be provided.

Contouring

The cauda equina and intrathecal spinal nerve roots distal to the natural taper of the true meningeal sac are at risk of radiation injury when performing SBRT. The cauda equina is the major dose-limiting organ because injury can lead to paralysis and loss of bladder and bowel function. Because it is not usually possible to precisely delineate individual nerve roots, the thecal sac (TS) has been used as a surrogate contour. Several challenges exist with this approach, and overestimating the TS contour can limit dose exposure to

adjacent diseased tissue [42–44].

Not all facilities can perform surgery; therefore, it is necessary to offer high-precision radiotherapy to improve patient outcomes without surgery while minimizing radiation-caused neuritis. TS contouring differs among radiation oncologists [8]. No significant difference was found between the spinal canal and cauda equina for PTV D80 (29 Gy vs. 32 Gy, respectively). Alternatively, for PTV D95, a significant difference was observed between the spinal canal and cauda equina (22 and 29 Gy, respectively). Improving the coverage of the PTV increases the D_{\max} of the OAR. The longer the distance between PTV and OAR, the better the PTV coverage and lower the OAR dose. If PTV and OAR are in contact, the coverage of PTV will be lowered because the OAR dose is limited.

Unless the dose actually delivered to the PTV covers 95% of that as prescribed, tumor control is impossible. Thus, if the spinal canal is restricted, the coverage of the PTV is reduced considerably. High coverage of PTV D95 is important for effective tumor control.

Recent studies on oligometastasis have shown that it is highly possible that cancer can be cured by radical treatment for bone metastasis [1, 2]. The spinal canal at the lumbar level contains the dural matter and spinal fluid in addition to the cauda equina. The spinal fluid is a liquid and not an OAR. Therefore, only the cauda equina should be the OAR. The cauda equina is located on the dorsal side in the supine and prone positions and exits from the spinal cavity as a nerve root. Using only the cauda equina can increase the coverage rate, which was ~17% better than that of the spinal cord. A 17% lower coverage rate can lead to a lower local control rate, which is insufficient to destroy tumors. Thus, OAR contouring should be considered for the cauda equina because tumors recur if they are not removed.

In clinical practice, finding a tolerable dose for using the spinal cord as the OAR can be a problem, but the dose is meaningless if the tumor cannot be controlled by protecting the OAR. For individual patients, physicians can choose a treatment with a level of radiation injury of < 5% or can allow the cauda equina to be the primary constraint of the OAR and allow a 50% chance of injury to it. Sometimes, the tumor and OAR are connected. To prevent the onset of myelitis, PTV overlaps with OAR (cauda

equina), so PTV's D95 coverage is reduced whereas OAR is prioritized. In this case, it is imperative to inform the patient that tumor compression of the spinal cord is likely because the tumor is likely to be out of control. The recommendations of ICRU62 [45] should be followed in delineating the target volume, with an additional volume, here referred to as PTV_prescribe, recommended to account for the spinal cord's proximity. If cauda equina is present, surgery should also be considered. In our study, we observed ~17% coverage difference between the spinal cord and cauda equina for PTV D95. This difference is related to the local control rate, and future studies are needed to determine the degree of spinal cord injury. For the optimal dose fractionation schedule, spinal SBRT has been delivered via schedules ranging from a single fraction (8–24 Gy) to hypofractionated regimes, such as 30 Gy (5 fx), 24–27 Gy (2–3 fx), and 35 Gy (5 fx). However, no definite evidence to recommend one regime over another currently exists [1, 2, 4, 7].

Previously, interobserver variability in contouring the lower lumbar spine and TS has suggested a unified consensus [8]. However, no studies have examined the benefits of subdividing the OAR. In our study, using the cauda equina alone as the OAR improved PTV coverage by 17%. Thus, if PTV coverage is reduced by reducing the dose to the OAR, tumor control is also reduced. Therefore, we believe that a comparative study targeting patient safety will be necessary in the future.

Conclusions

This study design is based on a simulation that spinal fluid can withstand a dose of 30 Gy/3 fx (BED10 = 60 Gy, BED3 = 130 Gy). Spinal fluid is a circulating fluid, and no previous study has reported that a restricted dose should be used for it. Additionally, spinal fluid may be able to withstand a 30 Gy/3 fx dose as currently there are no reports of brain fluid being ruptured by brain stereotactic radiosurgery.

There is almost only cerebrospinal fluid in the spinal canal in the area where the cauda equina is present. If the entire spinal cord is set as the OAR, the vertebral body (PTV) covered by 95% of the prescribed dose cannot be achieved. An increasing number of studies have reported that SBRT can be used to rescue patients with oligometastasis. Although our study was only a simulation examination, when

considering tumor control, setting only the cauda equina as the OAR is realistic because the rescue rate is higher, especially when a tumor has invaded the bone margin. Cauda equina should be given top priority as an OAR. The spinal canal is a range that includes spinal fluid and has little clinical significance.

Conflicts of interest

The authors declare that they have no competing interests.

Funding

This publication was prepared without any external source of funding.

Ethical permission

Ethical approval was not necessary for the preparation of this article.

References

1. Chang JH, Gandhidasan S, Finnigan R, et al. Stereotactic Ablative Body Radiotherapy for the Treatment of Spinal Oligometastases. Clin Oncol (R Coll Radiol). 2017; 29(7): e119–e125, doi: [10.1016/j.clon.2017.02.004](https://doi.org/10.1016/j.clon.2017.02.004), indexed in Pubmed: [28237218](https://pubmed.ncbi.nlm.nih.gov/28237218/).
2. Silva SR, Gliniewicz A, Martin B, et al. Oligometastatic Disease State Is Associated with Improved Local Control in Patients Undergoing Three or Five Fraction Spine Stereotactic Body Radiotherapy. World Neurosurg. 2019; 122: e342–e348, doi: [10.1016/j.wneu.2018.10.044](https://doi.org/10.1016/j.wneu.2018.10.044), indexed in Pubmed: [30326310](https://pubmed.ncbi.nlm.nih.gov/30326310/).
3. Zhang HR, Li JK, Yang XG, et al. Conventional Radiotherapy and Stereotactic Radiosurgery in the Management of Metastatic Spine Disease. Technol Cancer Res Treat. 2020; 19: 1533033820945798, doi: [10.1177/1533033820945798](https://doi.org/10.1177/1533033820945798), indexed in Pubmed: [32757820](https://pubmed.ncbi.nlm.nih.gov/32757820/).
4. Rijken J, Crowe S, Trapp J, et al. A review of stereotactic body radiotherapy for the spine. Phys Eng Sci Med. 2020; 43(3): 799–824, doi: [10.1007/s13246-020-00889-w](https://doi.org/10.1007/s13246-020-00889-w), indexed in Pubmed: [32588201](https://pubmed.ncbi.nlm.nih.gov/32588201/).
5. Redmond KJ, Lo SS, Fisher C, et al. Postoperative Stereotactic Body Radiation Therapy (SBRT) for Spine Metastases: A Critical Review to Guide Practice. Int J Radiat Oncol

- Biol Phys. 2016; 95(5): 1414–1428, doi: [10.1016/j.ijrobp.2016.03.027](https://doi.org/10.1016/j.ijrobp.2016.03.027), indexed in Pubmed: [27479724](https://pubmed.ncbi.nlm.nih.gov/27479724/).
6. Cox BW, Spratt DE, Lovelock M, et al. International Spine Radiosurgery Consortium consensus guidelines for target volume definition in spinal stereotactic radiosurgery. *Int J Radiat Oncol Biol Phys.* 2012; 83(5): e597–e605, doi: [10.1016/j.ijrobp.2012.03.009](https://doi.org/10.1016/j.ijrobp.2012.03.009), indexed in Pubmed: [22608954](https://pubmed.ncbi.nlm.nih.gov/22608954/).
 7. Redmond KJ, Robertson S, Lo SS, et al. Consensus Contouring Guidelines for Postoperative Stereotactic Body Radiation Therapy for Metastatic Solid Tumor Malignancies to the Spine. *Int J Radiat Oncol Biol Phys.* 2017; 97(1): 64–74, doi: [10.1016/j.ijrobp.2016.09.014](https://doi.org/10.1016/j.ijrobp.2016.09.014), indexed in Pubmed: [27843035](https://pubmed.ncbi.nlm.nih.gov/27843035/).
 8. Dunne EM, Lo SS, Liu MC, et al. Thecal Sac Contouring as a Surrogate for the Cauda Equina and Intracanal Spinal Nerve Roots for Spine Stereotactic Body Radiation Therapy (SBRT): Contour Variability and Recommendations for Safe Practice. *Int J Radiat Oncol Biol Phys.* 2022; 112(1): 114–120, doi: [10.1016/j.ijrobp.2021.08.023](https://doi.org/10.1016/j.ijrobp.2021.08.023), indexed in Pubmed: [34454046](https://pubmed.ncbi.nlm.nih.gov/34454046/).
 9. Dunne EM, Sahgal A, Lo SS, et al. International consensus recommendations for target volume delineation specific to sacral metastases and spinal stereotactic body radiation therapy (SBRT). *Radiother Oncol.* 2020; 145: 21–29, doi: [10.1016/j.radonc.2019.11.026](https://doi.org/10.1016/j.radonc.2019.11.026), indexed in Pubmed: [31874346](https://pubmed.ncbi.nlm.nih.gov/31874346/).
 10. Milano MT, Usuki KY, Walter KA, et al. Stereotactic radiosurgery and hypofractionated stereotactic radiotherapy: normal tissue dose constraints of the central nervous system. *Cancer Treat Rev.* 2011; 37(7): 567–578, doi: [10.1016/j.ctrv.2011.04.004](https://doi.org/10.1016/j.ctrv.2011.04.004), indexed in Pubmed: [21571440](https://pubmed.ncbi.nlm.nih.gov/21571440/).
 11. Schaub SK, Tseng YD, Chang EL, et al. Strategies to Mitigate Toxicities From Stereotactic Body Radiation Therapy for Spine Metastases. *Neurosurgery.* 2019; 85(6): 729–740, doi: [10.1093/neuros/nyz213](https://doi.org/10.1093/neuros/nyz213), indexed in Pubmed: [31264703](https://pubmed.ncbi.nlm.nih.gov/31264703/).
 12. Ling DC, Flickinger JC, Burton SA, et al. Long-Term Outcomes After Stereotactic Radiosurgery for Spine Metastases: Radiation Dose-Response for Late Toxicity. *Int J Radiat Oncol Biol Phys.* 2018; 101(3): 602–609, doi: [10.1016/j.ijrobp.2018.02.035](https://doi.org/10.1016/j.ijrobp.2018.02.035), indexed in Pubmed: [29678526](https://pubmed.ncbi.nlm.nih.gov/29678526/).

13. Sasaki M, Nakamura M, Mukumoto N, et al. Dosimetric impact of translational and rotational setup errors for spine stereotactic body radiotherapy: A phantom study. *Med Dosim.* 2018; 43(4): 320-326, doi: [10.1016/j.meddos.2017.10.009](https://doi.org/10.1016/j.meddos.2017.10.009), indexed in Pubmed: [29217331](https://pubmed.ncbi.nlm.nih.gov/29217331/).
14. Amoush A, Long H, Subedi L, et al. Dosimetric effect of multileaf collimator leaf width on volumetric modulated arc stereotactic radiotherapy for spine tumors. *Med Dosim.* 2017; 42(2): 111-115, doi: [10.1016/j.meddos.2017.01.007](https://doi.org/10.1016/j.meddos.2017.01.007), indexed in Pubmed: [28457723](https://pubmed.ncbi.nlm.nih.gov/28457723/).
15. Li W, Sahgal A, Foote M, et al. Impact of immobilization on intrafraction motion for spine stereotactic body radiotherapy using cone beam computed tomography. *Int J Radiat Oncol Biol Phys.* 2012; 84(2): 520-526, doi: [10.1016/j.ijrobp.2011.12.039](https://doi.org/10.1016/j.ijrobp.2011.12.039), indexed in Pubmed: [22401920](https://pubmed.ncbi.nlm.nih.gov/22401920/).
16. Kim S, Jin H, Yang H, et al. A study on target positioning error and its impact on dose variation in image-guided stereotactic body radiotherapy for the spine. *Int J Radiat Oncol Biol Phys.* 2009; 73(5): 1574-1579, doi: [10.1016/j.ijrobp.2008.12.023](https://doi.org/10.1016/j.ijrobp.2008.12.023), indexed in Pubmed: [19306754](https://pubmed.ncbi.nlm.nih.gov/19306754/).
17. Huang L, Djemil T, Zhuang T, et al. Treatment plan quality and delivery accuracy assessments on 3 IMRT delivery methods of stereotactic body radiotherapy for spine tumors. *Med Dosim.* 2019; 44(1): 11-14, doi: [10.1016/j.meddos.2017.12.009](https://doi.org/10.1016/j.meddos.2017.12.009), indexed in Pubmed: [29429794](https://pubmed.ncbi.nlm.nih.gov/29429794/).
18. Zeng KL, Myrehaug S, Soliman H, et al. Stereotactic Body Radiotherapy for Spinal Metastases at the Extreme Ends of the Spine: Imaging-Based Outcomes for Cervical and Sacral Metastases. *Neurosurgery.* 2019; 85(5): 605-612, doi: [10.1093/neuros/nyy393](https://doi.org/10.1093/neuros/nyy393), indexed in Pubmed: [30169694](https://pubmed.ncbi.nlm.nih.gov/30169694/).
19. Chan MW, Thibault I, Atenafu EG, et al. Patterns of epidural progression following postoperative spine stereotactic body radiotherapy: implications for clinical target volume delineation. *J Neurosurg Spine.* 2016; 24(4): 652-659, doi: [10.3171/2015.6.SPINE15294](https://doi.org/10.3171/2015.6.SPINE15294), indexed in Pubmed: [26682603](https://pubmed.ncbi.nlm.nih.gov/26682603/).
20. Ryu S, Pugh SL, Gerszten PC, et al. RTOG 0631 phase 2/3 study of image guided stereotactic radiosurgery for localized (1-3) spine metastases: phase 2 results. *Pract*

- Radiat Oncol. 2014; 4(2): 76–81, doi: [10.1016/j.prr.2013.05.001](https://doi.org/10.1016/j.prr.2013.05.001), indexed in Pubmed: [24890347](https://pubmed.ncbi.nlm.nih.gov/24890347/).
21. Bilsky MH, Laufer I, Fourney DR, et al. Reliability analysis of the epidural spinal cord compression scale. *J Neurosurg Spine*. 2010; 13(3): 324–328, doi: [10.3171/2010.3.SPINE09459](https://doi.org/10.3171/2010.3.SPINE09459), indexed in Pubmed: [20809724](https://pubmed.ncbi.nlm.nih.gov/20809724/).
22. Sahgal A, Chang JH, Ma L, et al. Spinal Cord Dose Tolerance to Stereotactic Body Radiation Therapy. *Int J Radiat Oncol Biol Phys*. 2021; 110(1): 124–136, doi: [10.1016/j.ijrobp.2019.09.038](https://doi.org/10.1016/j.ijrobp.2019.09.038), indexed in Pubmed: [31606528](https://pubmed.ncbi.nlm.nih.gov/31606528/).
23. Rades D, Stalpers LJA, Veninga T, et al. Evaluation of five radiation schedules and prognostic factors for metastatic spinal cord compression. *J Clin Oncol*. 2005; 23(15): 3366–3375, doi: [10.1200/JCO.2005.04.754](https://doi.org/10.1200/JCO.2005.04.754), indexed in Pubmed: [15908648](https://pubmed.ncbi.nlm.nih.gov/15908648/).
24. Rades D, Lange M, Veninga T, et al. Preliminary results of spinal cord compression recurrence evaluation (score-1) study comparing short-course versus long-course radiotherapy for local control of malignant epidural spinal cord compression. *Int J Radiat Oncol Biol Phys*. 2009; 73(1): 228–234, doi: [10.1016/j.ijrobp.2008.04.044](https://doi.org/10.1016/j.ijrobp.2008.04.044), indexed in Pubmed: [18539406](https://pubmed.ncbi.nlm.nih.gov/18539406/).
25. Mizumoto M, Harada H, Asakura H, et al. Radiotherapy for Patients With Metastases to the Spinal Column: A Review of 603 Patients at Shizuoka Cancer Center Hospital. *Int J Radiat Oncol Biol Phys*. 2011; 79(1): 208–213, doi: [10.1016/j.ijrobp.2009.10.056](https://doi.org/10.1016/j.ijrobp.2009.10.056), indexed in Pubmed: [20418024](https://pubmed.ncbi.nlm.nih.gov/20418024/).
26. Campos S, Presutti R, Zhang L, et al. Elderly patients with painful bone metastases should be offered palliative radiotherapy. *Int J Radiat Oncol Biol Phys*. 2010; 76(5): 1500–1506, doi: [10.1016/j.ijrobp.2009.03.019](https://doi.org/10.1016/j.ijrobp.2009.03.019), indexed in Pubmed: [19540056](https://pubmed.ncbi.nlm.nih.gov/19540056/).
27. Chow E, Harris K, Fan G, et al. Palliative radiotherapy trials for bone metastases: a systematic review. *J Clin Oncol*. 2007; 25(11): 1423–1436, doi: [10.1200/JCO.2006.09.5281](https://doi.org/10.1200/JCO.2006.09.5281), indexed in Pubmed: [17416863](https://pubmed.ncbi.nlm.nih.gov/17416863/).
28. Chow E, Zeng L, Salvo N, et al. Update on the systematic review of palliative radiotherapy trials for bone metastases. *Clin Oncol (R Coll Radiol)*. 2012; 24(2): 112–124, doi: [10.1016/j.clon.2011.11.004](https://doi.org/10.1016/j.clon.2011.11.004), indexed in Pubmed: [22130630](https://pubmed.ncbi.nlm.nih.gov/22130630/).

29. Nguyen QN, Shiu AS, Rhines LD, et al. Management of spinal metastases from renal cell carcinoma using stereotactic body radiotherapy. *Int J Radiat Oncol Biol Phys.* 2010; 76(4): 1185-1192, doi: [10.1016/j.ijrobp.2009.03.062](https://doi.org/10.1016/j.ijrobp.2009.03.062), indexed in Pubmed: [19632064](https://pubmed.ncbi.nlm.nih.gov/19632064/).
30. Anand AK, Venkadamani G, Punnakal AU, et al. Hypofractionated stereotactic body radiotherapy in spinal metastasis - with or without epidural extension. *Clin Oncol (R Coll Radiol).* 2015; 27(6): 345-352, doi: [10.1016/j.clon.2015.01.035](https://doi.org/10.1016/j.clon.2015.01.035), indexed in Pubmed: [25726363](https://pubmed.ncbi.nlm.nih.gov/25726363/).
31. Ryu S, Jin R, Jin JY, et al. Pain control by image-guided radiosurgery for solitary spinal metastasis. *J Pain Symptom Manage.* 2008; 35(3): 292-298, doi: [10.1016/j.jpainsymman.2007.04.020](https://doi.org/10.1016/j.jpainsymman.2007.04.020), indexed in Pubmed: [18215498](https://pubmed.ncbi.nlm.nih.gov/18215498/).
32. Gerszten PC, Burton SA, Ozhasoglu C, et al. Radiosurgery for spinal metastases: clinical experience in 500 cases from a single institution. *Spine (Phila Pa 1976).* 2007; 32(2): 193-199, doi: [10.1097/01.brs.0000251863.76595.a2](https://doi.org/10.1097/01.brs.0000251863.76595.a2), indexed in Pubmed: [17224814](https://pubmed.ncbi.nlm.nih.gov/17224814/).
33. Sahgal A, Myrehaug SD, Siva S, et al. trial investigators. Stereotactic body radiotherapy versus conventional external beam radiotherapy in patients with painful spinal metastases: an open-label, multicentre, randomised, controlled, phase 2/3 trial. *Lancet Oncol.* 2021; 22(7): 1023-1033, doi: [10.1016/S1470-2045\(21\)00196-0](https://doi.org/10.1016/S1470-2045(21)00196-0), indexed in Pubmed: [34126044](https://pubmed.ncbi.nlm.nih.gov/34126044/).
34. Tseng CL, Soliman H, Myrehaug S, et al. Imaging-Based Outcomes for 24 Gy in 2 Daily Fractions for Patients with de Novo Spinal Metastases Treated With Spine Stereotactic Body Radiation Therapy (SBRT). *Int J Radiat Oncol Biol Phys.* 2018; 102(3): 499-507, doi: [10.1016/j.ijrobp.2018.06.047](https://doi.org/10.1016/j.ijrobp.2018.06.047), indexed in Pubmed: [30003994](https://pubmed.ncbi.nlm.nih.gov/30003994/).
35. Thibault I, Chang EL, Sheehan J, et al. Response assessment after stereotactic body radiotherapy for spinal metastasis: a report from the SPIne response assessment in Neuro-Oncology (SPINO) group. *Lancet Oncol.* 2015; 16(16): e595-e603, doi: [10.1016/S1470-2045\(15\)00166-7](https://doi.org/10.1016/S1470-2045(15)00166-7), indexed in Pubmed: [26678212](https://pubmed.ncbi.nlm.nih.gov/26678212/).

36. Schipani S, Wen W, Jin JY, et al. Spine radiosurgery: a dosimetric analysis in 124 patients who received 18 Gy. *Int J Radiat Oncol Biol Phys.* 2012; 84(5): e571–e576, doi: [10.1016/j.ijrobp.2012.06.049](https://doi.org/10.1016/j.ijrobp.2012.06.049), indexed in Pubmed: [22975607](https://pubmed.ncbi.nlm.nih.gov/22975607/).
37. Yamada Y, Bilsky MH, Lovelock DM, et al. High-dose, single-fraction image-guided intensity-modulated radiotherapy for metastatic spinal lesions. *Int J Radiat Oncol Biol Phys.* 2008; 71(2): 484–490, doi: [10.1016/j.ijrobp.2007.11.046](https://doi.org/10.1016/j.ijrobp.2007.11.046), indexed in Pubmed: [18234445](https://pubmed.ncbi.nlm.nih.gov/18234445/).
38. Chang EL, Shiu AS, Mendel E, et al. Phase I/II study of stereotactic body radiotherapy for spinal metastasis and its pattern of failure. *J Neurosurg Spine.* 2007; 7(2): 151–160, doi: [10.3171/SPI-07/08/151](https://doi.org/10.3171/SPI-07/08/151), indexed in Pubmed: [17688054](https://pubmed.ncbi.nlm.nih.gov/17688054/).
39. Wang X, Rhines L, Shiu A, et al. Stereotactic body radiation therapy for management of spinal metastases in patients without spinal cord compression: a phase 1–2 trial. *Lancet Oncol.* 2012; 13(4): 395–402, doi: [10.1016/s1470-2045\(11\)70384-9](https://doi.org/10.1016/s1470-2045(11)70384-9), indexed in Pubmed: [22285199](https://pubmed.ncbi.nlm.nih.gov/22285199/).
40. Amdur RJ, Bennett J, Olivier K, et al. A prospective, phase II study demonstrating the potential value and limitation of radiosurgery for spine metastases. *Am J Clin Oncol.* 2009; 32(5): 515–520, doi: [10.1097/COC.0b013e318194f70f](https://doi.org/10.1097/COC.0b013e318194f70f), indexed in Pubmed: [19528790](https://pubmed.ncbi.nlm.nih.gov/19528790/).
41. Alghamdi M, Sahgal A, Soliman H, et al. Postoperative Stereotactic Body Radiotherapy for Spinal Metastases and the Impact of Epidural Disease Grade. *Neurosurgery.* 2019; 85(6): E1111–E1118, doi: [10.1093/neuros/nyz349](https://doi.org/10.1093/neuros/nyz349), indexed in Pubmed: [31506671](https://pubmed.ncbi.nlm.nih.gov/31506671/).
42. Chen X, LeCompte MC, Gui C, et al. Deviation from consensus contouring guidelines predicts inferior local control after spine stereotactic body radiotherapy. *Radiother Oncol.* 2022; 173: 215–222, doi: [10.1016/j.radonc.2022.05.035](https://doi.org/10.1016/j.radonc.2022.05.035), indexed in Pubmed: [35667571](https://pubmed.ncbi.nlm.nih.gov/35667571/).
43. Hardcastle N, Bignell F, Nelms B, et al. The challenge of planning vertebral body SBRT: Optimizing target volume coverage. *Med Dosim.* 2020; 45(3): 302–307, doi: [10.1016/j.meddos.2020.02.005](https://doi.org/10.1016/j.meddos.2020.02.005), indexed in Pubmed: [32295749](https://pubmed.ncbi.nlm.nih.gov/32295749/).

44. Dumas M, Laugeman E, Sevak P, et al. Technical Note: Comparison of the internal target volume (ITV) contours and dose calculations on 4DCT, average CBCT, and 4DCBCT imaging for lung stereotactic body radiation therapy (SBRT). *J Appl Clin Med Phys*. 2020; 21(11): 288–294, doi: [10.1002/acm2.13041](https://doi.org/10.1002/acm2.13041), indexed in Pubmed: [33044040](https://pubmed.ncbi.nlm.nih.gov/33044040/).
45. ICRU Report 62: Prescribing, Recording and Reporting Photon Beam Therapy (Report 62). 1999.

Figure 1. **A.** Pretreatment T1-weighted magnetic resonance imaging (MRI). The International Spine Radiosurgery Consortium anatomic classification system for the consensus target volume for spine radiosurgery [35]. Metastasis in Segments 1, 2, and 3 in the lumbar bone is adjusted for the spinal canal. However, no deformation of the spinal canal is recognized; **B.** Pretreatment T2-weighted MRI. The tumor is in contact with the dural matter but without deformation, corresponding to 1a in the Epidural Spinal Cord Compression (ESCC) scale classification. Radiation oncologists contoured the spinal canal, cauda equina, and bilateral nerve roots; **C.** Treatment planning computed tomography (CT) with contouring planning target volume (PTV) and organs at risk (OARs). The tumor has invaded the vertical body edge and cannot cover the PTV due to the dose limitation in the spinal canal. PTV D95 is 20.9 Gy; **D.** Treatment planning CT with contouring PTV and OARs. The PTV D95 is 28.3 Gy because the cauda equina instead of the spinal canal was set as the OAR. High doses are irradiated to the dural matter and spinal fluid, but the dose to the cauda equina is within constraints; **E.** T1-weighted MRI at 6 months after radiotherapy for bone metastasis. The tumor signal intensity is returned to normal. No change is observed in the other organs; **F.** The prescribed dose percentage covers X% of the volume (DX). The DX in **C** and **D** are indicated by dose color washes, and the four color levels correspond to D80–D100

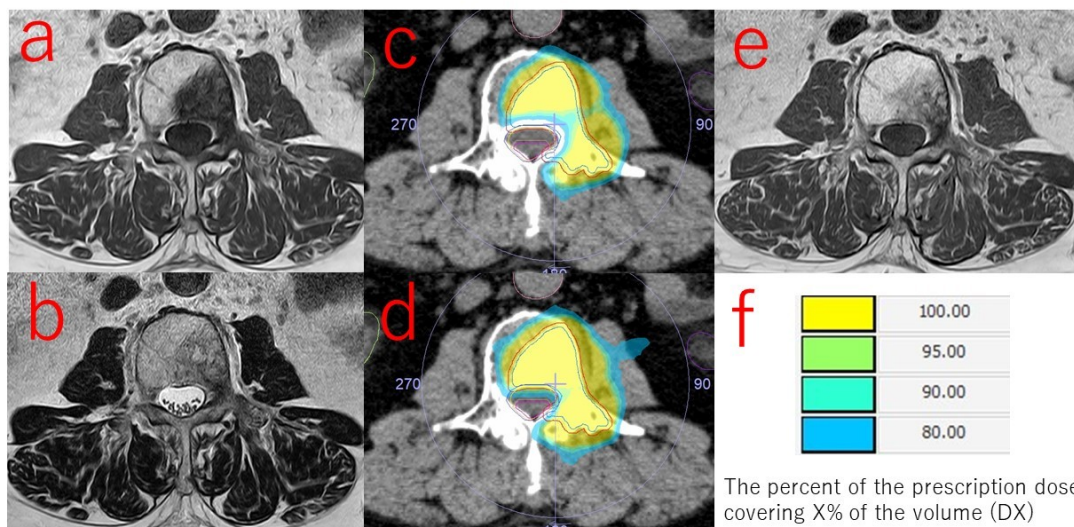


Figure 2. A planning target volume (PTV) with a margin of a few millimeters from the tumor (GTV). The area where the PTV overlaps the organ at risk (OAR) is subtracted from the PTV. The OAR was contoured by radiation oncologists in three ways: spinal canal, cauda equina and nerve roots, and cauda equina only. The prescribed PTV dose was 30 Gy/3 fx. The PTV coverage rate for each OAR was compared at 80% (D80), 90% (D90), and 95% (D95) doses. **A.** The average PTV D80 was 28.8 Gy, and no statistically significant difference was observed in the cases in which the cauda equina + nerve roots (N) or the cauda equina only were used as the OAR; **B.** The average D90 of the PTV was 25.3 Gy, which was significantly different from that of the cauda equina + nerve roots (28.7 Gy) and the cauda equina only (30.8 Gy) as the OAR (for both contours, $p < 0.05$); **C.** The average PTV D95 was 22.2 Gy, which was significantly different from that of the cauda equina + nerve roots (26.9 Gy) and the cauda equina only (29.4 Gy) as the OAR (for both contours, $p < 0.05$)

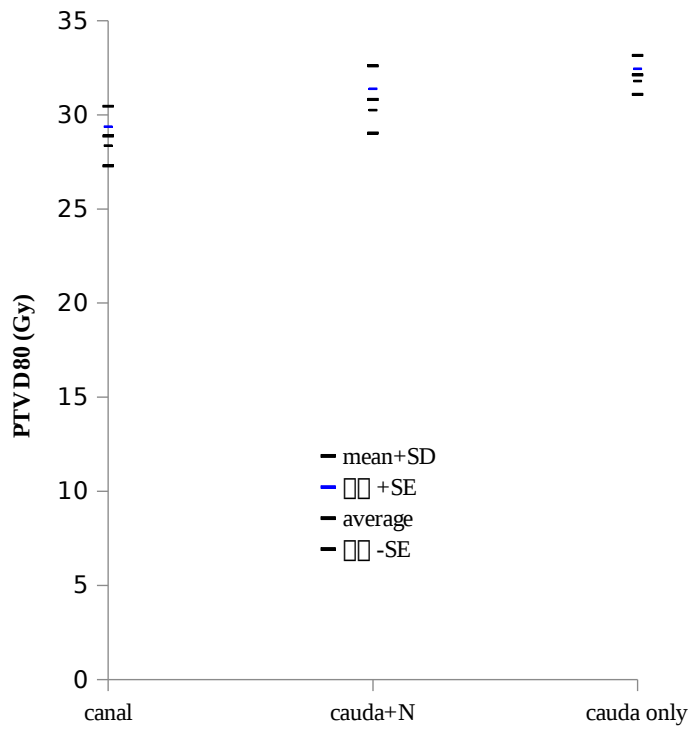


Figure 2a

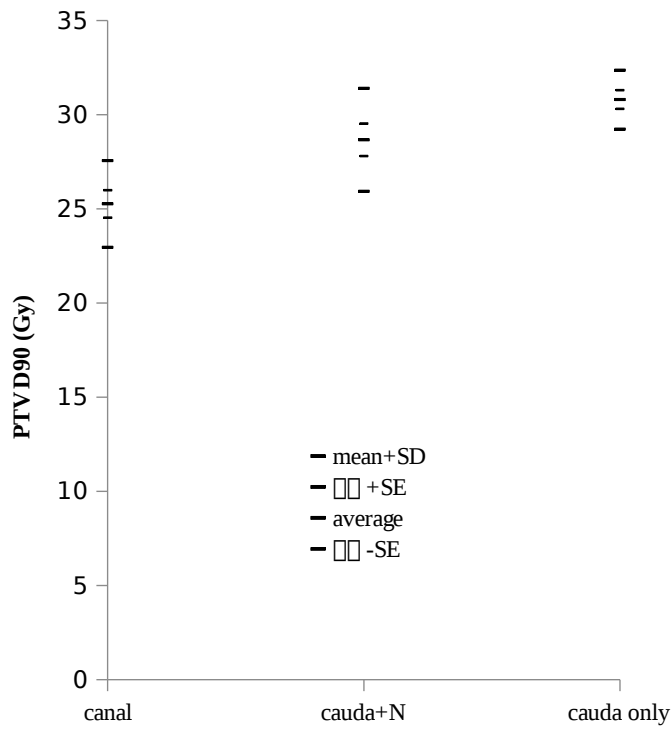


Figure 2b

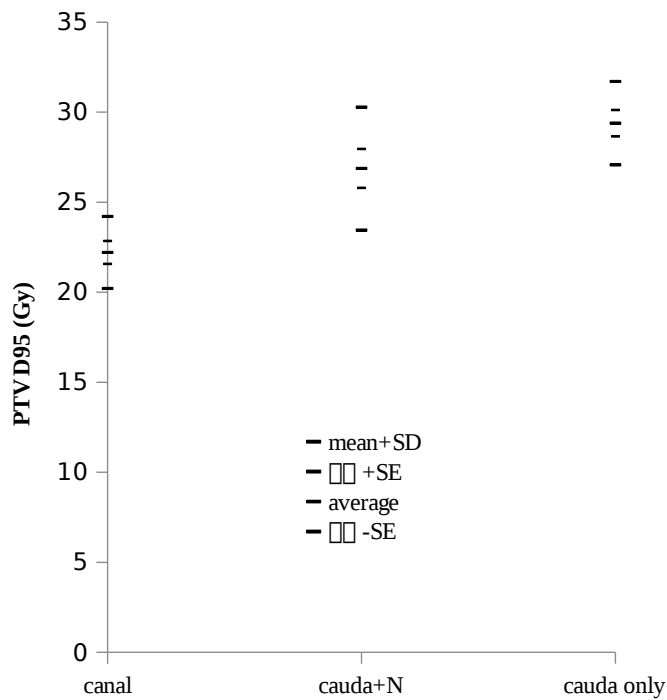


Figure 2c

Figure 3. A. Correlation coefficient ($R = -0.8517$) between Gy and 95% planning target volume (PTV) coverage when the spinal canal is set as the organ at risk (OAR) ($D_{\max} < 20$ Gy); **B.** The correlation coefficient ($R = -0.6627$) between Gy and 95% PTV coverage when the cauda equina is set as the OAR ($D_{\max} < 21$ Gy)

Effects of OAR contouring on PTV D9

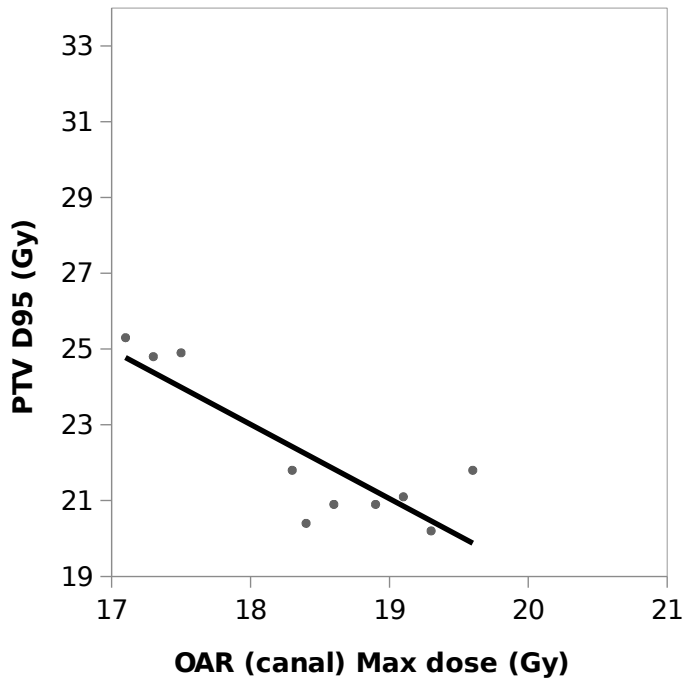


Figure 3a.

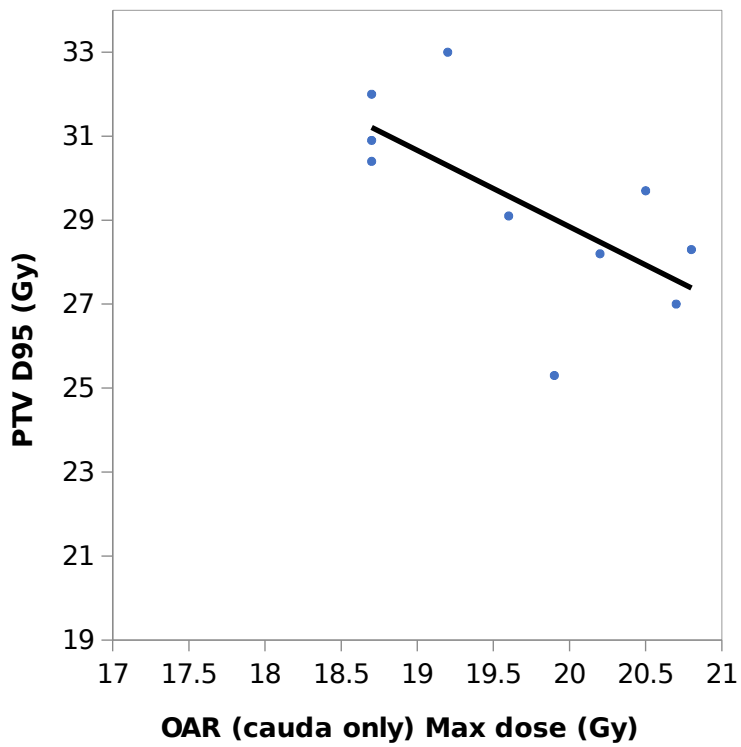


Figure 3b

Table 1. Dose constraints for organs at risk [30 Gy/3 fx for planning target volume (PTV)]

Organs at risk		Optimal [Gy]	Mandatory [Gy]
Spinal canal* (including medulla)	D_{\max} (0.1 cc)	< 20	< 20
	D1 cc	< 12	–
Cauda equina	D_{\max} (0.1 cc)	–	< 20
	D5 cc	–	< 20
Nerve root(s)	D_{\max} (0.1 cc)	–	< 20

D_{\max} — maximum dose received by the organ