



Perspectives on cortical connectivity in ischaemic stroke

Cătălina Elena Bistriceanu^{1,2}, Victor Constantinescu^{1,2}, Iulian Stoleriu³, Dan Iulian Cuciureanu^{1,4}

¹Neurology Department, Faculty of Medicine, University of Medicine and Pharmacy, Iasi, Romania

²Elytis Hospital Hope, Iasi, Romania

³Faculty of Mathematics, "Alexandru Ioan Cuza" University, Iasi, Romania

⁴"Prof. Dr. N. Oblu" Neurosurgery Clinical Emergency Hospital, Iasi, Romania

Key words: cortical connectivity, ischaemic stroke, electroencephalography

To the Editors

The neurological deficit of a stroke is not only the consequence of the focal lesion, but also the result of the disruption in connections with other areas. The analysis of brain connectivity provides new insights into post-stroke recovery mechanisms, as well as means of assessing the extent of the damage [1, 2].

Post-stroke electroencephalography (EEG) studies have demonstrated a reduction in intrahemispheric functional connectivity in various networks of the lesioned hemisphere after stroke, and this pattern has been shown to be associated with poor function. More pronounced low-frequency activity (delta or theta frequency activity) in the lesioned hemisphere and higher frequency activity (alpha or beta activity) in the contralesional hemisphere may create a higher interhemispheric imbalance. This may be associated with poor function and the restoration of balance may be associated with improved recovery after stroke [3].

Stroke leads to an early reduction of connectivity in the motor network. With recovery time, connectivity increases and can reach the same levels as in healthy participants. The increase in connectivity is correlated with functional motor gains. The analysis of changes in connectivity patterns may lead to a better understanding of these compensatory mechanisms in the brain after stroke [4].

EEG functional connectivity analysis can be performed using sLORETA (standardised low resolution electromagnetic tomography software). This is a linear inverse solution for EEG signals that have no localisation bias in the presence

of measurement and biological noise. The electric potential differences from EEG can estimate the current density vector field on the cortex in LORETA [5].

We report below some observations regarding network reorganisation in two cases of ischaemic stroke with an early good outcome. Informed consent was acquired from both patients.

We firstly report the case of a 74-year-old man who was admitted to the neurological department for sudden onset of weakness in his left limbs of two days' duration. He had a history of alcohol drinking, but there were no known additional vascular risk factors.

Neurological examination revealed left hemiparesis (Muscle Strength Rating Scale 4.5/5 upper limb and 4/5 lower limb, left Babinski sign) and mild dysarthria with an NIHSS (National Institutes of Health Stroke Scale) score of 5 points. A CT (computed tomography) scan performed in the accident and emergency department revealed an ischaemic acute stroke in the right anterior cerebral artery territory (Fig. 1 A).

Routine blood exam was unremarkable, and cardiovascular investigations revealed atrial fibrillation.

We performed an EEG in a resting state condition, in an isolated room, with closed eyes for 20 minutes on the fifth day after symptoms onset. Electroencephalographic signals were measured from 32 electrodes positioned according to the augmented International 10-20 system. The data was analyzed with MATLAB software, using scripts based on the EEGLAB toolbox. Detection and rejection of the artifacts were completed through ICA (independent component analysis). We selected the components that had brain source (Fig. 1 B).

Address for correspondence: Cătălina Elena Bistriceanu, Elytis Hospital Hope, Iasi, Romania; e-mail: catalina_nastac@yahoo.com

Received: 12.02.2023 Accepted: 30.03.2023 Early Publication Date: 05.05.2023

This article is available in open access under Creative Commons Attribution-Non-Commercial-No Derivatives 4.0 International (CC BY-NC-ND 4.0) license, allowing to download articles and share them with others as long as they credit the authors and the publisher, but without permission to change them in any way or use them commercially.

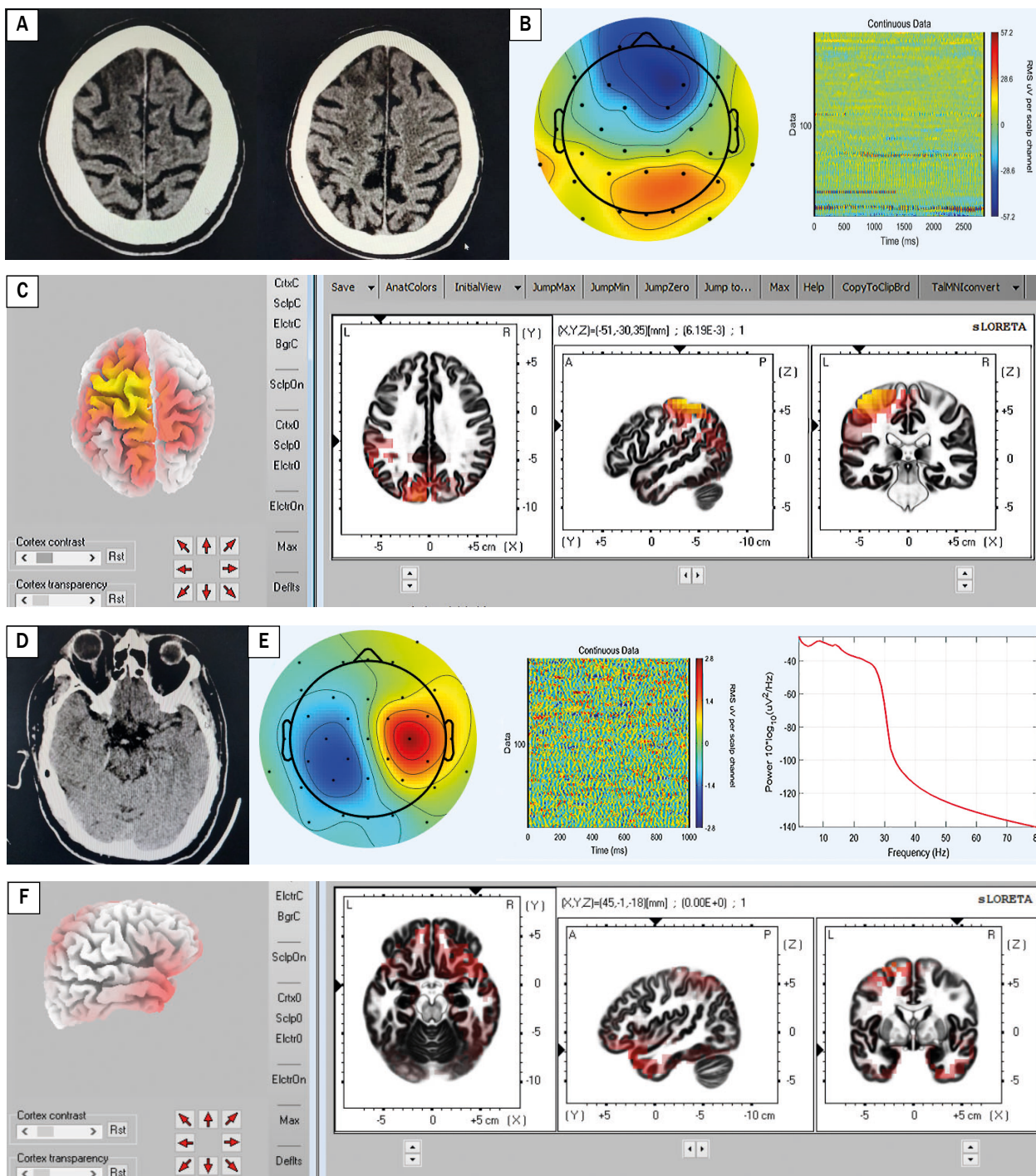


Figure 1. A. Axial CT reveals acute hypodensity in right anterior cerebral artery; B. Independent component analysis in MATLAB-EEGLAB for Patient 1; C. sLORETA algorithm for independent component chosen for Patient 1; D. Axial CT reveals acute hyperdense thrombus in M2 segment of left middle cerebral artery; E. Independent component analysis in MATLAB-EEGLAB for Patient 2; F. sLORETA algorithm for independent component chosen for Patient 2. CT – computed tomography; sLORETA – standardised low resolution electromagnetic tomography software

We used sLORETA to compute the cortical electrical distribution from the scalp potentials measured at the electrode sites (Fig. 1 C). We detected an increased distribution of electrical sources in the contralateral hemisphere (non-lesioned hemisphere – frontoparietal area).

We now report the second case: a 51-year-old man was admitted to the neurological department for sudden onset of weakness in his right limbs and expressive aphasia, of four hours' duration. He had a history of cigarette smoking, hypertension and dyslipidemia.

The neurological examination revealed right hemiparesis (strength was 4+ out of 5 on the right hand and 4+ out of 5 on the right foot, right Babinski sign) and motor aphasia with an NIHSS score of 6 points. A CT scan performed in the accident and emergency department revealed an acute hyperdense thrombus in the M2 segment of the left middle cerebral artery (Fig. 1 D). The ASPECTS (Alberta Stroke Program Early CT Score) was 10 points. The routine blood exam was unremarkable. During hospitalisation, the NIHSS score decreased to 1 point after intravenous (IV) thrombolysis. The cerebral CT performed one day after IV thrombolysis confirmed a small recent hypodense parietal area. Cardiovascular investigations during hospitalisation detected atrial fibrillation.

We performed a resting state EEG of 20 minutes' duration on the fifth day of hospitalisation, and we analysed the signals in MATLAB-EGLAB (Fig. 1 E). We removed the artifacts and we selected the components corresponding to brain electrical dipoles.

We further investigated the cortical electrical distribution of scalp potentials in sLORETA and we detected an increased distribution of electrical sources in the contralateral temporal area (non-lesioned hemisphere) and the ipsilateral frontal area (Fig. 1 F).

These two clinical cases raise questions regarding the ability of the brain to reorganise its connections and the utility of assessing early clinical outcomes in acute stroke patients.

Recent studies have focused on connectivity after stroke in order to find predictive biomarkers in stroke recovery. This represents an active research area in neuroscience and this could be a new insight in the domain of rehabilitation. In the context of incomplete knowledge of network reorganisation after stroke and its importance in clinics, further research studies are required to validate the importance of connectomics in this disabling disorder.

Analysing recovery studies of resting state functional connectivity of stroke participants and comparing them to

a control group, functional connectivity measures have shown decreases in at least some nodes or networks. When recovery occurs spontaneously, or is supported by therapy or training, connectivity increases over time [4]. Rehabilitative training (e.g. virtual reality as a therapeutic strategy can engage certain sensory and motor circuits) that indirectly affects the flow of information through brain connectomes and circuit-level plasticity may have a positive impact on stroke patients [1]. Studying functional connectivity in acute stroke, and finding early predictive biomarkers that are reliable enough in clinical practice to guide individualised rehabilitative training, represents a promising direction for future research.

Conflicts of interest: *None.*

Funding: *None.*

References

1. Silasi G, Murphy TH. Stroke and the connectome: how connectivity guides therapeutic intervention. *Neuron*. 2014; 83(6): 1354–1368, doi: [10.1016/j.neuron.2014.08.052](https://doi.org/10.1016/j.neuron.2014.08.052), indexed in Pubmed: [25233317](https://pubmed.ncbi.nlm.nih.gov/25233317/).
2. Pichiorri F, Petti M, Caschera S, et al. An EEG index of sensorimotor interhemispheric coupling after unilateral stroke: clinical and neurophysiological study. *Eur J Neurosci*. 2018; 47(2): 158–163, doi: [10.1111/ejn.13797](https://doi.org/10.1111/ejn.13797), indexed in Pubmed: [29247485](https://pubmed.ncbi.nlm.nih.gov/29247485/).
3. Keser Z, Buchl SC, Seven NA, et al. Electroencephalogram (EEG) with or without Transcranial Magnetic Stimulation (TMS) as biomarkers for post-stroke recovery: a narrative review. *Front Neurol*. 2022; 13: 827866, doi: [10.3389/fneur.2022.827866](https://doi.org/10.3389/fneur.2022.827866), indexed in Pubmed: [35273559](https://pubmed.ncbi.nlm.nih.gov/35273559/).
4. Desowska A, Turner DL. Dynamics of brain connectivity after stroke. *Rev Neurosci*. 2019; 30(6): 605–623, doi: [10.1515/revneuro-2018-0082](https://doi.org/10.1515/revneuro-2018-0082), indexed in Pubmed: [30768425](https://pubmed.ncbi.nlm.nih.gov/30768425/).
5. Pascual-Marqui RD. Standardized low-resolution brain electromagnetic tomography (sLORETA): technical details. *Methods Find Exp Clin Pharmacol*. 2002; 24 Suppl D: 5–12, indexed in Pubmed: [12575463](https://pubmed.ncbi.nlm.nih.gov/12575463/).